

Received: 2019.09.02
Accepted: 2019.11.06
Published: 2020.01.30

e-ISSN 1941-5923
© Am J Case Rep, 2020; 21: e919828
DOI: 10.12659/AJCR.919828

Phenytoin Seizure Prophylaxis Therapy Resulting in Severe Thrombocytopenia After Brain Tumor Debulking Surgery

Authors' Contribution:
Study Design A
Data Collection B
Statistical Analysis C
Data Interpretation D
Manuscript Preparation E
Literature Search F
Funds Collection G

AEF 1 **Rawan M. Al Ghamdi**
BCD 2 **Alaa N. Turkistani**
BD 3 **Haitham Ben Ali**

1 Department of Pharmacy, King Fahad Specialist Hospital, Dammam, Saudi Arabia
2 Department of Neurosurgery, King Fahad Specialist Hospital, Dammam, Saudi Arabia
3 Department of Neurosurgery, King Fahad Specialist Hospital, Dammam, Saudi Arabia

Corresponding Author: Rawan M. Al Ghamdi, e-mail: rawanalghamdi@yahoo.com
Conflict of interest: None declared

Patient: Male, 40-year-old
Final Diagnosis: Phenytoin-induced thrombocytopenia
Symptoms: Thrombocytopenia
Medication: Phenytoin
Clinical Procedure: Tumor debulking surgery
Specialty: Neurosurgery

Objective: Challenging differential diagnosis


Background: Phenytoin is an antiepileptic drug that is usually prescribed as a prevention treatment for tonic-clonic seizures or partial seizures, and as a prophylaxis for the neurosurgical related seizures. Phenytoin administration has several drawbacks; one drawback phenytoin-induced thrombocytopenia, which is a rare and significant adverse event. We report a rare adverse event after phenytoin prophylaxis therapy after a brain tumor debulking surgery, which resulted in severe unpredicted thrombocytopenia.

Case Report: A 40-year-old male with no known health problems started to have an on/off headaches and loss of memory. Clinical investigations revealed a right frontal brain lesion. On the first day of admission, the patient was managed on neurosurgical seizure prophylaxis therapy of 100 mg intravenous phenytoin every 8 hours and 4 mg oral dexamethasone every 6 hours. On the fifth day of hospital admission, the patient underwent tumor debulking surgery. Twenty-four hours post-surgery, the patient's platelet level dropped to $26 \times 10^9/L$. Severe thrombocytopenia was managed first by transfusion of 17 units of platelets and by cessation of intravenous phenytoin plus the starting of 500 mg levetiracetam orally twice daily. Further management included infusion of 34 grams (0.4 g/kg) intravenous immunoglobulin (IVIG) over 5 days. Five days later, the patient gradually recovered with a platelet count of $239 \times 10^9/L$.

Conclusions: Phenytoin-induced thrombocytopenia is considered a rare event, but it has life-threatening consequences. The first and cornerstone management of this event is the cessation of phenytoin, followed by consideration of appropriate management based on the level of thrombocytopenia severity, and avoiding concomitant therapy of phenytoin and the use of dexamethasone as neurosurgical-related seizure prophylaxis.


MeSH Keywords: Anticonvulsants • Neurosurgery • Phenytoin • Thrombocytopenia

Full-text PDF: <https://www.amjcaserep.com/abstract/index/idArt/919828>

 2765

 1

 2

 25



Background

Drug-induced thrombocytopenia (DIT) has long been an issue of great interest in a wide range of studies since the 19th century. It was first reported in 1865 by Vipian [1], who reported it in quinine treated patients as a clinical manifestation of purpura. The incidence of DIT in critically ill patients is around 25%, while the overall rate is around 10 cases per million of population per year [2]. The causative drugs of DIT have different incidence rates. Anticonvulsants have been reported in the literature as one of the most notable classes of drugs associated with a possible cause of DIT; George et al. published criteria and level of evidence for establishing a causative relationship in DIT purpura [2]. Pedersen et al. reported incidence of DIT with anticonvulsants was around 0.96 per 100 000 prescriptions per year [3]. The Blackburn et al. [4] cohort study reported that anticonvulsant drug induced thrombocytopenia incidence rate per 100 000 prescriptions differed between each class of drug. The incidence rate of thrombocytopenia was 0.5 per 100 000 prescriptions of carbamazepine and 1.1 per 100 000 prescriptions of phenytoin, while the rate was much higher with phenobarbital of about 4.2 per 100 000 prescriptions [4].

Phenytoin-induced thrombocytopenia was reported for the first time in 1986 by Brown et al. in a case report of a 35-year-old male with a dropped platelet counts of $15 \times 10^9/L$ after 2 weeks of phenytoin initiation [5]. Although the frequency of this phenomenon is rare, because of its seriousness, it is a significant concern. Generally, thrombocytopenia is defined mainly as a platelet count lower than or equal to $100 \times 10^9/L$ and clinically manifested as petechiae, purpura, and in severe cases, may lead to hemorrhage [4]. Markers for the prediction of DIT pathogenesis have been widely investigated and found to be either immune-related or nonimmune-related [2,6]. Historically, it was assumed to be nonimmune related as a result of selective suppression of the bone marrow and thus affecting the megakaryocyte hematopoietic cell lineage population. Later, this assumption was changed based on comparisons of the mechanism of myelosuppression that resulted from chemotherapeutic agents as a dose-dependent depletion of the circulating platelets with the phenytoin-induced thrombocytopenia which is a non-dose dependent adverse event. Moreover, myelosuppression occurs in a slow time course, while case reports of phenytoin-induced thrombocytopenia found that platelet depletion occurred after 1 to 4 weeks after the initiation of therapy and in some rare cases it occurred within 24 hours [2,5–7]. This provides support for an immune mediated mechanism of phenytoin-induced thrombocytopenia. The aim of this paper was to highlight a case report of a phenytoin-induced thrombocytopenia and discuss the predisposing factors to this rare and severe adverse event.

Case Report

The objective for case reporting: unpredicted phenytoin-induced thrombocytopenia

A 40-year-old male with no known health problems started to have an on/off headache and loss of memory. He was referred from another hospital with a history of a new-onset right-sided tonic-clonic seizure followed by a loss of consciousness; during the admission he had a seizure attack 3 times. After the initial investigation, a computed tomography (CT) scan and brain magnetic resonance imaging (MRI) showed a right frontal brain lesion. Left frontal craniotomy and tumor debulking surgery were conducted by our neurosurgery team on the fifth day after his admission. The patient was started on management therapy at the time of admission, which included supportive care and medication management. Medication management included 100 mg intravenous phenytoin every 8 hours and 4 mg oral dexamethasone every 6 hours as neurosurgical-related seizure prophylaxis, as the patient had a prior history of seizures. Other medications included amlodipine 5 mg orally daily, labetalol 10 mg intravenously, pantoprazole 40 mg orally daily, and paracetamol 1000 mg intravenously.

Before surgery, the patient's vitals were stable except an abnormality in a central nervous system (CNS) CT scan and related signs and symptoms. Twenty-four hours post-surgery, the patient was clinically stable and had no spontaneous hemorrhaging, but his laboratory findings showed severe thrombocytopenia with a level of $26 \times 10^9/L$. A neurology team consultation transfused the patient with 17 units of platelets and tapering of the intravenous phenytoin was as follow: 100 mg twice daily for 2 days, then 100 mg once daily for the next 2 days as well as starting the patient on levetiracetam 500 mg orally twice daily (Figure 1). The patient's phenytoin level post-surgery was equal to 6.3, while the adjusted level was 10.2. Twenty-four hours after the recommended management, the patient had not improved, and his platelet count was $24 \times 10^9/L$. Another neurology consultation recommended infusion of 34 grams (0.4 g/kg) of intravenous immunoglobulin (IVIg) over 5 days. Within 5 days of IVIg management, the patient was gradually recovering, and his daily platelet count improved: 55, 109, 168, and $239 \times 10^9/L$. Since admission, the dexamethasone dose was 4 mg orally every 6 hours then titrated to the fourth-day post-surgery as follow: 4 mg orally every 8 hours for 1 day, then 4 mg orally every 12 hours for 2 days, then 2 mg orally every 12 hours for 1 day.

Clinical investigation revealed a diagnosis of isolated thrombocytopenia after ruling out any other considerations as there was neither excessive bleeding intraoperatively nor exposure to heparin before surgery and his 4T score was equal to 3, which indicated a low probability for heparin-induced

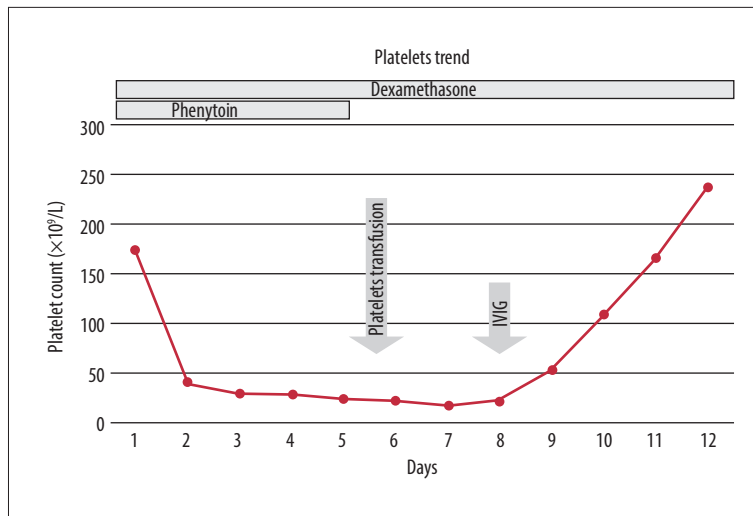


Figure 1. Platelet trend. Phenytoin was started from the first day of admission. Within 12 days, platelet counts demonstrated a gradual descending trend. After administration of platelet transfusion and intravenous immunoglobulin (IVIG) (1 mg/kg) for 5 consecutive days, there was a progressive and complete recovery.

thrombocytopenia. Moreover, other cell lines were preserved, and peripheral blood film showed thrombocytopenia with giant and large platelets indicating a functioning bone marrow with peripheral platelet destruction. A high probability of phenytoin-induced thrombocytopenia was considered as the patient was started on phenytoin 5 days before surgery along with dexamethasone. Finally, the patient was discharged home with stable vitals and with a platelet count of $239 \times 10^9/L$.

Discussion

Phenytoin is an antiepileptic drug used as a preventive treatment for tonic-clonic seizures or partial seizures, and as a prophylaxis for neurosurgical-related seizures which occur in a 20% to 40% of brain tumors patients [8]. Despite its value for this group of patients, phenytoin has several drawbacks; one is phenytoin-induced thrombocytopenia which is a rare and significant adverse event.

A thorough diagnosis of drug-induced thrombocytopenia (DIT) relies on a full clinical history, including any prescriptions or herbal medications. After that, a clinical and laboratory investigation needs to be performed to confirm the assumption of DIT; however, there are obstacles that can hinder the laboratory investigations for many reasons, which are related to the scarcity of their reproducibility and validity [9]. After all, careful clinical history and physical examination with the exclusion of any differential diagnosis is the cornerstone of DIT diagnosis.

Several studies have discussed a clinical approach for diagnosing DIT. Arnold et al. [9] proposed a practical approach to diagnose a suspected case of DIT. The elements of the diagnosis approach included: 1) the presence of severe thrombocytopenia characterized by nadir count of $20 \times 10^3/\mu L$, 2) presence of bleeding complications, 3) onset of DIT within 5 to 10

days of first-time drug exposure, or within hours of consecutive exposures, and 4) previous exposures to drugs with DIT reactions history [9]. The main clinical picture of DIT includes blood blisters in the oral mucous membrane and sometimes severe gastrointestinal bleeding or intracranial hemorrhage, and petechiae in the limbs and trunk [10].

A systematic understanding of how phenytoin contributes to adverse effects is key to patient management. The main metabolic pathway of phenytoin is aromatic hydroxylation, which is later catalyzed by the cytochrome P450 monooxygenases enzymes (CYP2C9 and CYP2C19), thus forming oxide products. Arene oxides are one of the toxic products that should be detoxified by an oxidative reaction driven by epoxides hydrolase enzyme. This enzyme, once inhibited by any causative factor – either by an inherited genetic defect in its production or drug-induced inhibition reaction – will lead to an accumulation of the toxic metabolite arene oxide, which then acts as a hapten and forms a covalent bond with macromolecules, such as platelets. This immunological reaction will induce a platelet specific drug-dependent antibody which recognizes the membrane glycoprotein complexes for fibrinogen or von Willebrand factor (GP IIB-IIIa or GP I_B-V-IX) on the platelets. This reaction will lead to platelets destruction and thus cause thrombocytopenia [7,11].

A search of the literature revealed that few studies have been published that discuss and report on drug-induced inhibition reaction to epoxides hydrolase enzyme to certain drugs. Although, there was a significant interaction reported between phenytoin and synthetic glucocorticoids, specifically dexamethasone. Simmons et al. studied the induction of oxidase system by synthetic glucocorticoids, and showed a 50% decline in the transcription of the epoxide hydrolase gene and 90% depression in intranuclear epoxide hydrolase RNA levels after a single injection of dexamethasone. This notable depression in the

enzyme level was detectable within 24 to 72 hours post-injection [12]. Another contributory drug in inhibiting epoxide hydrolase is cimetidine, a class of H₂-receptor antagonist, which has been discussed and reported in studies as well [6,13,14].

The risk of thrombocytopenia varies between different anti-epileptics. Verrotti et al. reviewed anticonvulsants drugs and hematological disease and found the relative risk of various hematological disorders related to each anticonvulsant drug. Most of the searched literature showed an increased risk of hematological diseases, including thrombocytopenia, with the use of conventional anticonvulsants [15]. Although, this was considered rare with clonazepam and phenytoin, and less frequent with carbamazepine [16]. On the contrary, the occurrence of thrombocytopenia was found to be more prevalent with primidone and valproic acid, which occurred from 5% to 60% of cases [15,17,18].

Phenytoin-induced thrombocytopenia was reported for the first time in 1986 by Brown et al., in the case of a 35-year-old male with a dropped platelet counts of $15 \times 10^9/L$ after 2 weeks of phenytoin initiation [5]. In 1987, Yue et al. reported 2 cases of severe phenytoin-induced thrombocytopenia. The first case was for a 22-year-old male admitted to the hospital for a cerebellar vermis tumor resection. Preoperatively, the patient was administered a combination of 4 mg dexamethasone every 6 hours, 200 mg cimetidine every 6 hours, and 100 mg phenytoin every 8 hours. After 5 days, the patient's clinical picture deteriorated; there was a petechia and petechial hemorrhage all over his limbs and trunk, and his platelet count was $28 \times 10^9/L$. The patient was managed immediately by prompt discontinuation of cimetidine and 12 units of platelet transfusion. His platelet count increased to $135 \times 10^9/L$ but then suddenly dropped to $42 \times 10^9/L$ within 24 hours. At this point, phenytoin was discontinued, but the patient became unconscious with bilateral rigidity, and after 2 weeks he died due to brain stem compression. The second case was a 68-year-old male admitted for a right frontal craniotomy tumor excision. Preoperatively, the patient was started on intravenous combination therapy of 4 mg dexamethasone every 6 hours, 200 mg cimetidine every 6 hours, and 100 mg phenytoin every 8 hours. The third day after the operation, the patient developed generalized petechial hemorrhage all over his limbs with a platelet count of $35 \times 10^9/L$. Phenytoin and cimetidine were stopped immediately and his platelet counts recovered within 2 weeks. Unfortunately, the patient became bedridden with left hemiplegia and died 2 months later [19].

In 1997, Holtzer et al. reported a case of phenytoin-induced thrombocytopenia: a 36-year-old female admitted to the hospital for a right frontal craniotomy tumor resection. Postoperatively, 100 mg phenytoin every 8 hours and 4 mg dexamethasone every 6 hours. On the fifth-day post-surgery,

her platelet count dropped to $6 \times 10^9/L$, and phenytoin concentration was 20 mg/L, but there were no signs of bleeding. Immediate management options included consideration of discontinuation of phenytoin and a 6-unit infusion of platelets as a transfusion. Instead of phenytoin, 60 mg of phenobarbital 3 times daily was given. The subsequent platelet count was $32 \times 10^9/L$, and due to some concerns regarding bleeding, another 6 units of platelets were transfused. MRI revealed hematoma and an additional 24 units of platelets was transfused. After the last transfusion, the platelet count increased to $52 \times 10^9/L$, and this was considered a small improvement. Further management included IVIG infusion of 45 g (1 g/kg) over 2 days. After 2 days, the platelet count increased to $89 \times 10^9/L$ and then to $141 \times 10^9/L$. On the tenth-day post-surgery, the patient had recovered and was discharged home with a platelet count of $255 \times 10^9/L$ [20].

In 2007, Thorning et al. reported a fatal case of phenytoin-induced thrombocytopenia with intracranial hemorrhage. A 66-year-old female was admitted for intracranial tumor resection; as preoperative neurosurgical prophylaxis, she was started on 300 mg phenytoin once daily with 4 mg dexamethasone every 6 hours. Five days later, the patient developed a left-sided intracranial hemorrhage and a platelet count of $2 \times 10^9/L$. The patient immediately was managed by discontinuation of phenytoin along with a platelet transfusion. After 3 days, the patient's platelets were maintained at over $80 \times 10^9/L$. The patient had a second operation for a bone flap removal. Unfortunately, the patient died 5 days after the second operation due to brainstem compression [13].

In 2018, Lau et al. reported a case of a 20-year-old female who was on phenytoin 100 mg dose, 3 times per day, as seizure prophylaxis along with 4 mg dexamethasone taken 3 times daily to control cerebral edema. After 2 weeks, the clinical picture revealed a hematochezia and petechiae spots on the upper limbs, as well as a drop in her platelet count to $47 \times 10^9/L$ indicating thrombocytopenia. The patient was managed by immediate discontinuation of phenytoin and changed to 200 mg sodium valproate twice daily with 7 units of platelet transfusion as she had an increased risk of intracranial hemorrhage. After 3 weeks, the patient recovered with a platelet count of $113 \times 10^9/L$ [21]. All these similar reported cases in the literature are summarized in Table 1.

The crucial step for DIT management is the discontinuation of the offending drug [22]. Therefore, the binding of the drug-dependent antibody to platelets will be prohibited while the antibodies may remain in the blood for several months or years after drug discontinuation [9,22]. Other approaches for DIT management include transfusion of red blood cells/platelets, plasmapheresis, and infusion of high dose corticosteroids [6,9,22]. Based on 2 essential aspects, we can consider

Table 1. Summary of similar case reports in the literature [6,14,20–22].

Study	Sex/age (years)	Neurosurgical prophylaxis medications	Platelets level ($\times 10^9/L$)	Onset of thrombocytopenia after phenytoin	Management	Time of platelet recovery	Outcome
1986 Brown et al. [5]	Male/35	150 mg oral phenytoin 3 times per day	15	2 weeks	2 doses of phenytoin were withheld; phenytoin therapy was resumed at a lower dose (100 mg, 3 times daily).	5 days	Recovered
1987 Yue et al. [19]	Male/68	Intravenous combination therapy of 4 mg dexamethasone every 6 hours, 200 mg cimetidine every 6 hours, and 100 mg phenytoin every 8 hours	35	3 days	Phenytoin and cimetidine were stopped immediately	2 weeks	Left hemiplegia; died 2 months later
1987 Yue et al. [19]	Male/22	4 mg dexamethasone every 6 hours 200 mg cimetidine every 6 hours 100 mg phenytoin every 8 hours	28	5 days	Discontinuation of cimetidine and 12 units of platelet transfusion; after 24-hours phenytoin was discontinued	2 weeks	Died due to brain stem compression
1997 Holtzer et al. [20]	Female/36	100 mg phenytoin every 8 hours 4 mg dexamethasone every 6 hours	6	5 days	Discontinuation of phenytoin and 36 units of platelet transfusion given separately based on platelet count. 60 mg of phenobarbital 3 times per day was given instead of phenytoin. 45 g (1 g/kg), immune globulin (IVIG) was taken over 2 days.	10 days	Recovered
2007 Thorning et al. [13]	Female/66	300 mg phenytoin taken once daily with 4 mg dexamethasone every 6 hours	2	5 days	Discontinuation of phenytoin and platelets transfusion	3 days	Died due to brainstem compression

Table 1 continued. Summary of similar case reports in the literature [6,14,20–22].

Study	Sex/age (years)	Neurosurgical prophylaxis medications	Platelets level ($\times 10^9/L$)	Onset of thrombocytopenia after phenytoin	Management	Time of platelet recovery	Outcome
2018 Lau et al. [21]	Female/20	100 mg phenytoin 3 times per day 4 mg dexamethasone 3 times per day	47	2 weeks	Discontinuation of phenytoin; changed to 200 mg sodium valproate 2 times daily with 7 units of platelet transfusion	3 weeks	Recovered

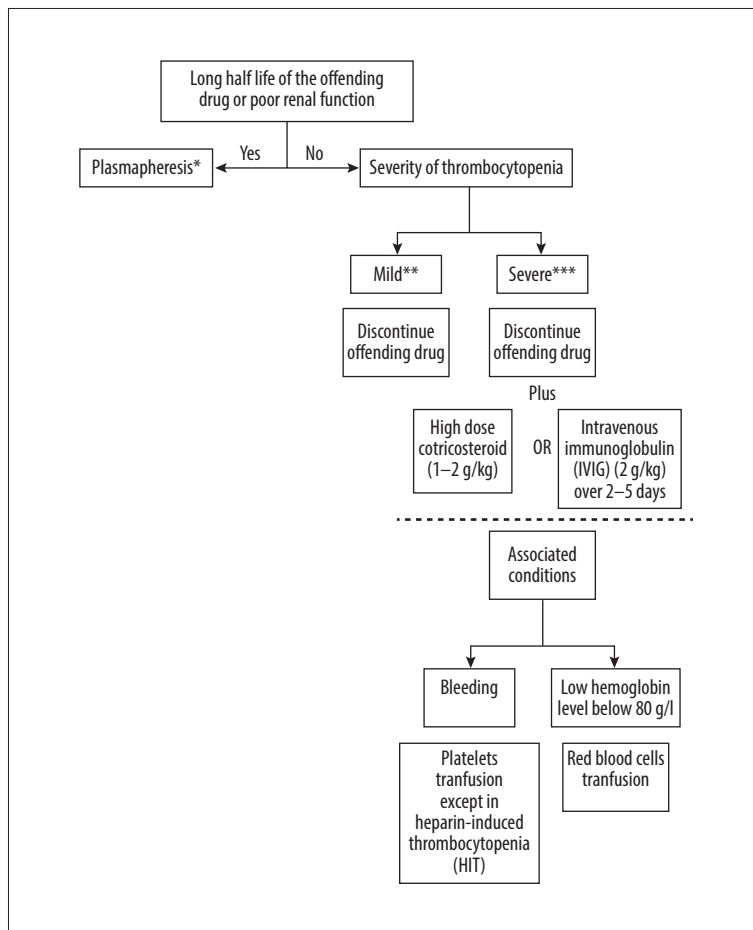


Figure 2. Illustrate management of drug-induced thrombocytopenia [2,10,23,26–28]. * There wasn't enough evidence in the practice. ** Platelet level between 70 to $150 \times 10^9/L$. *** Platelet level less than $20 \times 10^9/L$.

the best approach to management. First is the half-life of the offending drug, the usual recovery range of time is from 1 to 10 days after drug discontinuation but if the half-life is prolonged or there is poor renal function, then the recovery may last up to 2 weeks [23]. In this scenario, the most appropriate management, theoretically, is plasmaphereses, although there is not enough evidence to support this approach as there are no randomized controlled trials that have studied the effect

of plasmaphereses for thrombotic disorders [24]. The second aspect is the level of severity of thrombocytopenia; in a case of mild thrombocytopenia with a platelet level between 70 to $150 \times 10^9/L$, the discontinuation of the offending drug is the only management to consider [22,25]. In a severe case of thrombocytopenia with a platelet count of less than $20 \times 10^9/L$, it is better to add one more approach after discontinuation of the offending drug, which is usually infusion of either a high

dose of corticosteroid at 1 to 2 g/kg, except dexamethasone in a case of phenytoin-induced thrombocytopenia to avoid the drug-drug interaction, or administration of IVIG with a dose of 2 g/kg over 2 to 5 days [22]. In a case of an increased risk of bleeding, then consider platelet transfusion, but caution should be used if the patient is suspected of having heparin-induced thrombocytopenia. In such a case, a platelet transfusion may add a “fuel to the fire” and increases the risk of thrombotic complications [23]. In the case of a drop in the hemoglobin level below 80 g/L, along with thrombocytopenia, then red blood cell transfusions should be considered [2,9,22,25]. DIT management is summarized in Figure 2.

Conclusions

Up to now, DIT has been considered a rare condition that carries dangerous consequences. Knowing the offending drugs that are a risk for thrombocytopenia should be considered prior to excluding all differential diagnosis of thrombocytopenia; and after that, categorizing the level of thrombocytopenia is essential

References:

1. Vipan WH: Quinine as a cause of purpura. *Lancet*, 1865; 86(2184): 37
2. George JN, Raskob GE, Shah SR et al: Drug-induced thrombocytopenia: A systematic review of published case reports. *Ann Intern Med*, 1998; 129(11): 886–90
3. Pedersen-Bjergaard U, Andersen M, Hansen PB: Drug-induced thrombocytopenia: Clinical data on 309 cases and the effect of corticosteroid therapy. *Eur J Clin Pharmacol*, 1997; 52(3): 183–89
4. Blackburn SC, Oliart AD, Garcia Rodriguez LA, Perez Gutthann S: Antiepileptics and blood dyscrasias: A cohort study. *Pharmacotherapy*, 1998; 18(6): 1277–83
5. Brown JJ, Chun RW: Phenytoin-induced thrombocytopenia. *Pediatr Neurol*, 1986; 2(2): 99–101
6. Aster RH, Bougie DW: Drug-induced immune thrombocytopenia. *N Engl J Med*, 2007; 357(6): 580–87
7. Pandey M, Yarlagadda L: Drug-induced thrombocytopenia: A less known interaction. *Blood Coagul Fibrinolysis*, 2012; 23(8): 778–80
8. Koubeissi M: Do we need seizure prophylaxis for brain tumor surgery? *Epilepsy Curr*, 2014; 14(1): 24–25
9. Arnold DM, Nazi I, Warkentin TE et al: Approach to the diagnosis and management of drug-induced immune thrombocytopenia. *Transfus Med Rev*, 2013; 27(3): 137–45
10. Aster RH, Reese JA, Li X et al: Identifying drugs that cause acute thrombocytopenia: An analysis using 3 distinct methods. *Blood*, 2010; 116(12): 2127–33
11. Spielberg SP, Gordon GB, Blake DA et al: Predisposition to phenytoin hepatotoxicity assessed *in vitro*. *N Engl J Med*, 1981; 305(13): 722–27
12. Simmons DL, Mcquiddy P, Kasper CB: Induction of the hepatic mixed-function oxidase system by synthetic glucocorticoids. *J Biol Chem*, 1987; 262(1): 326–32
13. Thorning G, Raghavan K: Fatal phenytoin-induced thrombocytopenia in a neurosurgical patient. *Eur J Anaesthesiol*, 2007; 24(10): 897–98
14. Arbiser JL, Goldstein AM, Gordon D: Thrombocytopenia following administration of phenytoin, dexamethasone and cimetidine: A case report and a potential mechanism. *J Intern Med*, 1993; 234(1): 91–94
15. Verrotti A, Scaparrotta A, Grosso S et al: Anticonvulsant drugs and hematological disease. *Neurol Sci*, 2014; 35(7): 983–93
16. Veall RM, Hogarth HC: Letter: Thrombocytopenia during treatment with clonazepam. *Br Med J*, 1975; 4(5994): 462
17. Nasreddine W, Beydoun A: Valproate-induced thrombocytopenia: A prospective monotherapy study. *Epilepsia*, 2008; 49(3): 438–45
18. Gerstner T, Teich M, Bell N et al: Valproate-associated coagulopathies are frequent and variable in children. *Epilepsia*, 2006; 47(7): 1136–43
19. Yue CP, Mann KS, Chan KH: Severe thrombocytopenia due to combined cimetidine and phenytoin therapy. *Neurosurgery*, 1987; 20(6): 963–65
20. Holtzer CD, Reisner-Keller LA: Phenytoin-induced thrombocytopenia. *Ann Pharmacother*, 1997; 31(4): 435–37
21. Lau EF, Shanmugam H, Mazlan M: Phenytoin-induced severe thrombocytopenia post dexamethasone co-administration in a patient with intracerebral haemorrhage. *Journal of Health and Translational Medicine (JUMMEC)*, 2018; 21(2): 31–34
22. Nguyen TC, Stegmayr BG, Busund R et al: Plasma therapies in thrombotic syndromes. *Int J Artif Organs*, 2005; 28(5): 459–65
23. Gauer RL, Braun MM: Thrombocytopenia. *Am Fam Physician*, 2012; 85(6): 612–22
24. Hackett T, Kelton JG, Powers P: Drug-induced platelet destruction. *Semin Thromb Hemost*, 1982; 8(2): 116–37
25. Murphy MF, Stanworth SJ, Estcourt L: Chapter 20: Thrombocytopenia and platelet transfusion. In: Simon TL, McCullough J, Snyder EL et al. (eds.), *Rossi's Principles of Transfusion Medicine*, 5th Ed. Hoboken (NJ): Wiley-Blackwell, 2016; 235–44

to specify the most appropriate management. Moreover, drug-drug interaction with phenytoin metabolism carries a massive risk for increasing the incidence of thrombocytopenia. There are only a few reported cases indicating the drugs which interfere with the phenytoin metabolism and thus leading to phenytoin-induced thrombocytopenia. The most significant and crucial management for and DIT is the discontinuation of the offending drug and consideration of other management approaches, as needed. Counseling DIT affected patient to avoid the offending drug in the future is mandatory to prevent any recurrence or further hospital admissions.

Acknowledgements

We acknowledge the Neurosurgery Department Coordination Office in our hospital for assistance acquiring patient data.

Conflict of interest

None.