



Original Article

Role of intraoperative computed tomography scanner in modern neurosurgery – An early experience

Mohammad Ashraf^{1,2}, Nabeel Choudhary³, Syed Shahzad Hussain³, Usman Ahmad Kamboh³, Naveed Ashraf³

¹3rd Year Medical Student, University of Glasgow, Wolfson School of Medicine, Glasgow, Scotland, United Kingdom, ²Visiting Medical Student, Allama Iqbal Medical College, Department of Neurosurgery, Jinnah Hospital, Lahore, Pakistan, ³Department of Neurosurgery, Allama Iqbal Medical College, Jinnah Hospital, Lahore, Pakistan.

E-mail: *Mohammad Ashraf - mohammad_5676@hotmail.com; Nabeel Choudhary - doc.nabeel@gmail.com; Syed Shahzad Hussain - drshahzadns@yahoo.com; Usman Ahmad Kamboh - usmanschemer644@hotmail.com; Naveed Ashraf - drnashraf@yahoo.com



***Corresponding author:**

Mohammad Ashraf,
Wolfson School of Medicine,
University of Glasgow,
Glasgow-G12 8QQ, Scotland,
United Kingdom.

mohammad_5676@hotmail.com

Received : 22 May 2020

Accepted : 16 July 2020

Published : 15 August 2020

DOI

10.25259/SNI_303_2020

Quick Response Code:



ABSTRACT

Background: Intraoperative imaging addresses the limitations of frameless neuronavigation systems by providing real-time image updates. With the advent of new multidetector intraoperative computed tomography (CT), soft tissue can be visualized far better than before. We report the early departmental experience of our intraoperative CT scanner's use in a wide range of technically challenging neurosurgical cases.

Methods: We retrospectively analyzed the data of all patients in whom intraoperative CT scanner was utilized. Out of 31 patients, 24 (77.4%) were cranial and 8 (22.6%) spinal cases. There were 13 male (41.9%) and 18 (58.1%) female patients, age ranged from 1 to 83 years with a mean age of 34.29 years \pm 17.54 years. Seven patients underwent spinal surgery, 2 cases were of orbital tumors, and 16 intra-axial brain tumors, including 5 low-grade gliomas, 10 high-grade gliomas, and 1 colloid cyst. There were four sellar lesions and two multiloculated hydrocephalus.

Results: The intraoperative CT scan guided us to correct screw placement and was crucial in managing four complex spinal instabilities. In intracranial lesions, 59% of cases were benefitted due to intraoperative CT scan. It helped in the precise placement of ventricular catheter in multiloculated hydrocephalus and external ventricular drain for a third ventricular colloid cyst.

Conclusion: Intraoperative CT scan is safe and logistically and financially advantageous. It provides versatile benefits allowing for safe and maximal surgery, requiring minimum changes to an existing neurosurgical setup. Intraoperative CT scan provides clinical benefit in technically difficult cases and has a smooth workflow.

Keywords: Intraoperative computed tomography scan, Image-guided neurosurgery, Glioma surgery, Spine surgery, Multiloculated hydrocephalus, Third ventricular colloid cyst

INTRODUCTION

Intraoperative imaging modalities are important tools in the armamentarium of modern neurosurgeons as these greatly have helped overcome the challenges faced by traditional neuronavigation systems. Conventionally, image-guided neuronavigation systems have helped localize complex lesions in the brain. This complexity can be attributed to the complicated anatomy of the brain that has fascinated neurosurgeons and anatomists alike. The navigation system in surgery produces the tip of a pointer on an image. The system calibrates preoperative

This is an open-access article distributed under the terms of the Creative Commons Attribution-Non Commercial-Share Alike 4.0 License, which allows others to remix, tweak, and build upon the work non-commercially, as long as the author is credited and the new creations are licensed under the identical terms.

©2020 Published by Scientific Scholar on behalf of Surgical Neurology International

images to the intraoperative coordinate system of the patient using a transformation matrix creating a link between preoperative imaging and anatomical structures giving surgeons a 3-D orientation of the position of the region of interest.^[9] New navigation systems give approximately 2 mm of accuracy.^[9]

The significant limitation of navigation, however, is the presumption that the brain and skull are rigid structures,^[6,5,23] but during surgery due to the phenomenon of brain shift described by Kelly *et al.*^[8] in 1986, this limits the correlation surgeons can achieve between preoperative image and intraoperative anatomy.^[14] This occurs due to a distortion of brain tissue with several studies documenting surgical manipulation of brain tissue, tissue swelling, and loss of cerebrospinal fluid and use of brain retractors^[4,13,17] as a cause of this dynamic spatiotemporal event which is time dependent.^[25] This renders the images in the navigation system incorrect and can make surgery inaccurate. The brain shift phenomenon can occur in the cortex and deep brain structures^[5] which may result in damage to eloquent areas of the brain, for example, in glioma surgery.^[28] The surgical community did not reach a consensus on whether navigation alone improved outcomes in surgery but recognized there was a need for a more accurate solution which was addressed by the real-time images provided by intraoperative imaging modalities.

The main modalities include intraoperative ultrasound (iUS), intraoperative magnetic resonance imaging (iMRI), and intraoperative computed tomography (iCT) scanner. The iUS is more widely available and less costly. Recent advances have yielded promising results with 3-D ultrasound that uses shear waves as opposed to longitudinal waves, linear regression analysis shows that it correlates better with preoperative MRIs.^[26] Studies have shown its usefulness in localizing deep-seated vascular lesions such as cavernomas and metastasis.^[16,18] The iUS's images, however, are of poor quality and user dependent with a cumbersome reconstruction of the navigation view.^[2] Thus, it is not widely used due to its poor resolution and being operator dependent.

MRI is considered to be the gold standard imaging modality for soft-tissue lesions. One prospective randomized controlled trial utilized iMRI to increase the extent of resection,^[20] an established parameter in both low- and high-grade glioma surgery to improve outcomes.^[14] The trial did increase progression-free survival in the iMRI group, however, which could not demonstrate an increase in overall survival. Postoperative rates of neurological deficits did not differ between the control group and those operated on with the help of iMRI.

Intraoperative CT scan has been available as a portable device since the early 2000s and has been used with great success in spinal surgeries. With the development of multidetector CT (MDCT), soft-tissue image resolution is improving and

its use in neurosurgical suites is increasing. It can be easily incorporated into a preexisting setup and requires very little changes; some of these include lead shielding and radiolucent table top with a radiolucent Mayfield/Doro head holder. We recently procured Airo Brainlab 32-slice MDCT and incorporated it into our existing operating theaters. No special surgical or anesthetic instrument/equipment changes were required. We have used this for both spine and cranial surgeries since October 2019 and present our early experience of its uses and benefits.

MATERIALS AND METHODS

This is a descriptive case series. We retrospectively analyzed data of our patients who underwent spinal and cranial surgery where the intraoperative CT scanner was utilized. The Department of Neurosurgery, Allama Iqbal Medical College, Jinnah Hospital, Lahore is the first neurosurgery department in Pakistan to have an intra operative CT scanner and use it in our regular clinical practice. This included a total of 31 patients since October 2019–March 2020; of which 24 (77.4%) were cranial and 7 (22.6%) were spinal cases. There were 13 male (41.9%) and 18 (58.1%) female patients. The ages of our patients ranged from 1 to 83 years with a mean age of 34.29 years \pm 17.54. Patient information was entered and analyzed in SPSS version 25.

For most cranial cases, preoperative MRI was acquired according to our institutional imaging protocol. This included T1, T2 and T1 with contrast for contrast enhancing lesions.

Patients were positioned after general anesthesia with a dedicated radiolucent Doro skull clamp and radiolucent pins. All neurosurgical positions were appropriate except the sitting position. [Figure 1] shows a cranial patient being positioned for an intraoperative CT scan before surgery and [Figure 2] shows our operating theater setup.




Figure 1: Patient being positioned before surgery.

Despite using radiolucent head clamp and pins, artifacts were still encountered due to the high density of head clamp. To minimize this, the pins or clamp were placed caudal to the epicenter of lesion to avoid artifact. According to the manufacturer’s settings, the standard volumetric image acquisition protocol was used giving 1 mm axial slices with a 512 × 512 picture resolution. Our iCT has an aperture of 107 cm and the maximum field of view is 51.2 cm. The standard 25 cm field of view was used to cover the entire skull; however, increased field of view was utilized in areas where required. For cranial cases, we scanned from the vertex to the tip of the nose or 3 cm caudal to the lesion and for the surface registration of the neuronavigation. The scanner automatically calculated the dose of radiation based on the weight and height of the patient. There are three modes to scan in, “standard” and “normal” for bone and “sharp” for soft tissue. The acquisition of the images can be done by the surgeons/theater staff and little technical assistance is required minimizing the need for dedicated staff.

Before start of surgery, a single preoperative CT scan was acquired as a reference to compare with intraoperative CT images. The preoperative CT scan images were transferred through USB as DICOM files to the Medtronic Stealth S7 navigation and registration system and merged with preoperative imaging. Surgery was proceeded as standard with navigation assistance and when the surgeon thought, the procedure had been completed or wanted to assess the extent of resection/shunt placement another intraoperative CT scan was performed and merged with the preoperative CT scan for comparison to decide if further action was required. The average number of scans was two, one preoperative and one intraoperative.

RESULTS

Out of our 21 cranial cases, there were two cases of orbital tumors and both benefited from intervention with the iCT to increase the extent of resection.

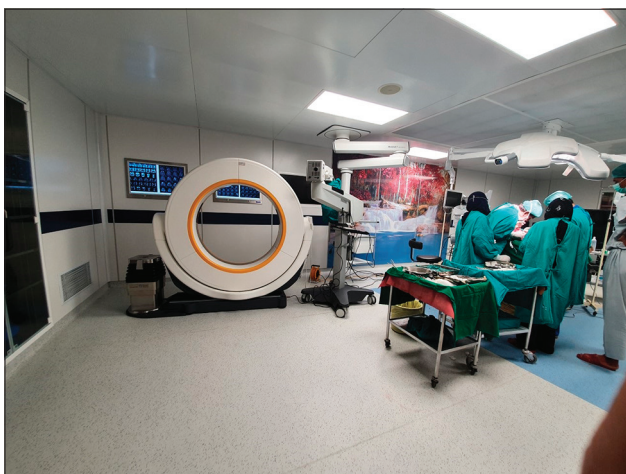

Figure 2: Operating theater setup.

There were four sellar lesions, in one case, we intervened further as iCT notified us of residual tumor. In another case, the iCT revealed an intraoperative complication which influenced our decision to not proceed with further resection of residual disease. Out of our 15 intra-axial brain tumors, 9 had further resection done as shown by the iCT and out of 7 spinal fixations, 4 cases benefitted from screw redirection. In two cases of multiloculated hydrocephalus, the iCT was beneficial in redirecting the ventricular end of ventriculoperitoneal shunt and in one case of third ventricular colloid cyst, the use of iCT resulted in safe surgery.

Table 1 summarizes the type and frequency of pathology. Table 2 shows the number of cases in which the iCT led to further intervention.

DISCUSSION

Clinical localization of lesions within the central nervous system became possible as scientists explored the functional regions of the brain and nervous system. This localization was dramatically improved when imaging studies such as angiography, air ventriculography, and later cross-sectional imaging modalities such as CT and MRI came in to clinical practice. The history of image-guided surgery saw a major technological advance with the Leksell stereotactic frame invented in 1949^[10] which was based on air ventriculography. Invention of CT scan in the early 1970s changed the neuroradiology field in terms of brain imaging

Table 1: Type and frequency of pathology.

Type of pathology	Frequency	Percentage
Orbital tumor	2	6.5
Sellar lesions	4	12.9
Intra-axial brain tumor	15	48.4
Spinal fixation	7	22.6
CSF diversion	3	9.7
Total	31	100

CSF: Cerebrospinal fluid

Table 2: Intervention made following iCT scan.

Type of pathology	Intervention made after acquiring intraoperative image	
	No	Yes
Orbital tumor	0	2
Sellar tumor	3	1
Intra-axial brain tumor	6	9
Spinal fixation	3	4
CSF diversion	0	3
Total	12	19

CSF: Cerebrospinal fluid, iCT: Intraoperative computed tomography

and hence the surgical techniques forever. This saw the emergence of CT compatible stereotactic systems. The first CT compatible frame was the N-localizer and even this had many artifacts.^[3] The next advancement in brain imaging had an even deeper and far reaching effect on the diagnosis and treatment of brain pathologies. MRI has made us look at the brain like never before. However, the imaging was confined to the radiology suite only and accurate localization during surgery would be massively challenging and almost undoable with huge logistic challenges. These were reduced on the advent of frameless navigation systems in which images from MRI and CT could be combined with such systems to not only localize the lesion but also to assess the risk by pointing out neighboring structural and functional regions during surgery. Willems *et al.* showed in a controlled trial of 45 patients with solitary contrast-enhancing intracerebral tumors that standard frameless neuronavigation does not influence the extent of resection.^[27] The phenomenon of brain shift plays a major role and thus there was a need for neuronavigation with real-time updates.

There are currently sparse data regarding the uses of intraoperative CT scan, its use in spinal surgery has been established;^[19] however, its use in other cases involving soft tissues is limited to small case series focusing on a single pathology^[11] due to its subpar imaging quality compared to that of MRIs. Large multicenter controlled trials are also lacking. Our limited experience is for a range of pathologies for both cranial and spinal neurosurgical procedures and in both pediatric and adult patients. We hope to provide data for future recommendations where iCT should be a standard of care imaging intraoperatively for patients requiring it.

Out of our seven spinal patients, two patients required fixation at the craniovertebral (CV) junction. One of them, a 59-year-old male required both anterior and posterior approach as the anterior pathology (fractured and cranially displaced odontoid) was done trans-orally. The iCT was crucial to allow us to orientate our self, correctly direct the screw placement and resect the odontoid peg. [Figure 3] shows iCT scan during craniocervical junction case allowing us to identify the midline which would be near impossible on standard C-arm X-ray (fluoroscopy).

Two patients required fixation of the cervical-thoracic junction. In spinal surgery, junctional area such as cervical-thoracic region and CV junction is poorly visualized on standard C-arm X-ray and is of anatomical complexity. In these cases, the iCT turned out to be extremely helpful. [Figure 4] shows the intraoperative CT scan of a cervical-thoracic fixation where the screw breached the spinal canal, this would not have been picked up on fluoroscopy. The iCT notified us to correct screw placement.

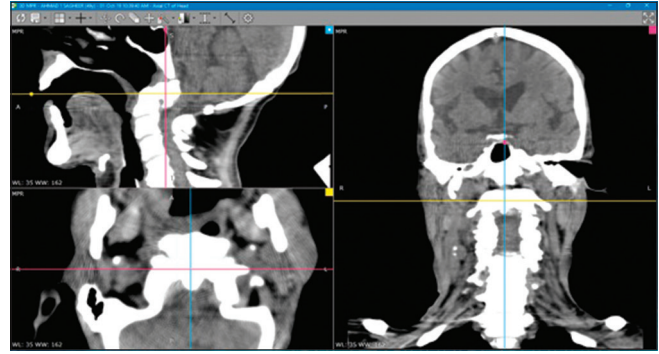


Figure 3: Intraoperative computed tomography during craniocervical junction fixation. Yellow line - axial plane; Red line - coronal plane; Blue line - sagittal plane.

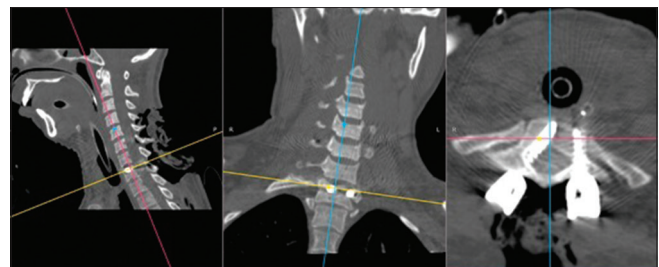


Figure 4: Intraoperative computed tomography scan during cervical-thoracic fixation. Sagittal (left), coronal (middle), and axial (right). Yellow line - axial plane; Red line - coronal plane; Blue line - sagittal plane.

For the first CV junction case, where both anterior and posterior approaches were used, we required three intraoperative scans; however, the subsequent patients of both CV junction and cervical-thoracic junction required two intraoperative scan each. The other 3 (42.8%) cases did not require correction of screw placement and a single intraoperative CT scan confirmed this. The iCT saved 4 (57.1%) patients from further surgery. In one study done by Tormenti *et al.*, it was shown that using iCT scan yielded an overall accuracy of 98.9% ($n = 12$) in simple thoracic and lumbar fixations while the accuracy was 94.8% ($n = 14$) in the fluoroscopy group in assessing if screws are correctly placed.^[24] This study, however, did not involve the complex instabilities such as CV and cervical-thoracic junctions that we encountered in our experience and to our knowledge is the first reported experience of such cases in the literature where the iCT was utilized to great benefit.

iCT was used to quantify residual disease in three sellar tumors and one fungal growth in the sella. One tumor required further resection due to residual disease, this was a case of a 23-year-old male with a growth hormone secreting pituitary adenoma (acromegaly). Out of the three tumors, where no further action was taken the

iCT quantified the extent of resection and showed us in two cases that further resection was not required. These included an 18-year-old female with a sellar fungal growth and a 40-year-old female with a pituitary adenoma. However, in one case, we could not proceed further despite the iCT showing residual disease. This was a transcranial approach for a large macroadenoma in a 44-year-old female. Surgery could not be proceeded as the ipsilateral A1 branch of the anterior cerebral artery was injured and there was poor visualization of the contralateral A1, both of which were engulfed within the tumor. The iCT was performed to find out the details of the operative and perioperative area. Since there was only a localized hematoma in the suprasellar region, it was decided not to proceed as it may further jeopardize the patient.

Of the two orbital tumors operated, both benefitted from the iCT. One was a case of fungal granuloma in a 39-year-old female and an intraoperative scan allowed us to detect residual disease and hematoma at the apex of the orbit. The residual disease in the small cavity of the orbit would have led to great morbidity for this patient. The other case, a 23-year-old female, was of an osteoma of sphenoid in which the iCT helped to monitor the extent of bony resection. The ability to detect hematoma is a testament to the improving iCT technology that can better visualize soft tissue as a previous study reported that such a complication (hematoma) could not be picked up on their iCT.^[21] [Figure 5] shows the hematoma that was detected timely due to the intraoperative scan in the case of fungal granuloma.

Table 3 shows key characteristics of the intra-axial brain tumors. In our series out of 15 intra-axial tumors, in 9 (60%)

cases, iCT guided us to proceed for further resection of residual tumor, these included five low-grade gliomas (100% of all low-grade tumors) and four high-grade tumors (40% of high-grade tumors), including three glioblastomas and one anaplastic oligodendroglioma. A gross total resection was achieved in these cases with the help of the iCT. Achieving a gross total resection is particularly important in low-grade gliomas as it can prolong progression-free survival by years.^[14] The other high-grade gliomas where further action was not taken were adequately resected according to the first iCT scan.

[Figure 6] shows the preoperative (left), first intraoperative (middle), and second intraoperative (right) scan in the case of insular Grade II astrocytoma where the iCT helped us achieve a gross total resection. Further data are required

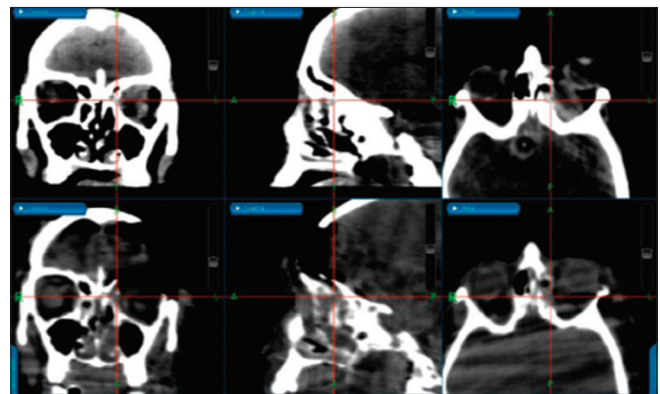


Figure 5: Intraoperative computed tomography scan showing hematoma in the left orbit apex. Yellow line - axial plane; Red line - coronal plane; Blue line - sagittal plane.

Table 3: Intra-axial brain tumors patient characteristics.

Number of patient	Sex	Age (years)	Tumor location	Histopathology	Further resection	Final resection ^a
1.	F	22	Right mesial temporal	Grade II astrocytoma	Yes	GTR
2.	M	13	Right thalamic	Grade II astrocytoma	Yes	GTR
3.	F	29	Right insular	Grade II astrocytoma	Yes	GTR
4.	F	31	Left frontoparietal	Pilocytic astrocytoma	Yes	GTR
5.	M	39	Left frontal	Grade II astrocytoma	Yes	GTR
6.	F	45	Right temporal	GBM	Yes	GTR
7.	M	40	Butterfly glioma	GBM	No	GTR
8.	M	50	Left frontal	Anaplastic oligodendroglioma	Yes	GTR
9.	F	44	Left parietal	GBM	No	GTR
10.	F	50	Left frontoparietal	Breast metastasis	No	GTR
11.	F	50	Left temporoparietal	GBM	Yes	GTR
12.	M	10	Right parietal	GBM	No	GTR
13.	F	50	Right parietal	GBM	No	GTR
14.	F	12	Left parietal	Small round blue cell tumor	No	GTR
15.	M	57	Left temporal	GBM	Yes	GTR

GBM: Glioblastoma multiform, F: Female, M: Male, GTR: Gross total resection, iCT: Intraoperative computed tomography. ^aAccording to intraoperative iCT finding as documented in operative notes

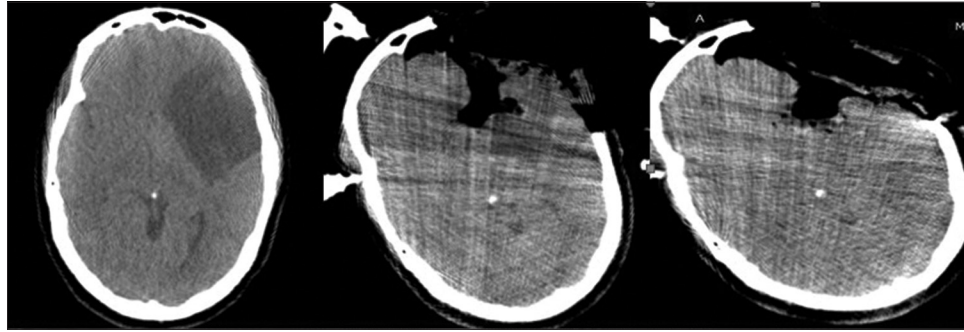


Figure 6: Intraoperative computed tomography scan of insular glioma.

to assess progression-free survival and overall survival to establish long-term benefit.

Multiloculated hydrocephalus is a very difficult entity to manage.^[12] In our series, in such cases, the iCT guided us to redirect the ventricular end of the VP shunt. This included a case of a 10-year-old female with post infectious multiloculated hydrocephalus. Our second case was a 12-month-old female with multiloculated hydrocephalus, here the iCT was of great help; during endoscopic fenestration with neuronavigation, real-time imaging was essential. Our last case was a 25-year-old male with a third ventricular colloid cyst. Here, the iCT was utilized to help excise the colloid cyst (trajectory guidance and completeness of excision), assess intraventricular hemorrhage, and aid in drain placement.

There can be limitations to cranial and cervical spine surgery due to smaller bore of intraoperative CT scanners as reported by Barbagallo *et al.*,^[1] whereas wide bore CT can overcome such problems and also be utilized in both dorsal and lumbar spine. With a wider bore iCT, logistical problems of acquiring intraoperative scan or having to change the standard surgical position to obtain the scan can be avoided. This was a difficulty encountered by Barbagallo *et al.*^[1] In three patients out of 25 (12%) who had intraoperative imaging, the operating position had to be adjusted either to accommodate their anatomical variation (short neck) or as a result of tumor location (parietal lobe tumors) due to the small bore of their iCT.^[1] Similarly, in another study which evaluated intraoperative DBS electrode placement, the iCT had to be tilted in “acquisition” phase to acquire the image.^[21] In both cases, this inadvertently led to an increase in the operating time.

The limited number of RCTs utilizing iMRI highlights an important point, that is, institutions equipped with iMRI accept the surrogate outcome which is the extent of resection, to improve progression free and overall survival. The disadvantage with iMRI is the extremely high cost not only of the machine itself but also of the associated requirements such as a dedicated operation

theater and MRI compatible operating tools and increased operative time. Furthermore, the logistics make it difficult to incorporate it into a preexisting setup. Recent studies suggested that there is no reasonable justification for a low field iMRI in a standard neurosurgical setup, at least not in its current state.^[11] Hirschberg *et al.* showed no increased efficacy of surgery with iMRI for high-grade gliomas, also no statistically significant difference between iMRI and control group in the extent of resection and acceptable complication rates in both groups.^[7] Quantification of risk and benefits has made iMRI an active debate in the community.

Not surprisingly a surgeon’s preferred choice, the iMRI available in a single operation theater, requiring major financial investment to develop a setup of dedicated rooms, staff and equipment would be economically unfeasible. This may also increase the overall operation time such that there would be less cases done per day.^[15] While evidence does show that iMRI reduces the need for immediate surgery 2 weeks postoperatively,^[22] our own experience with the iCT is that it reduces the need for further surgery, confirmed by our 6-week follow-up MRI and does not have the logistic and financial issues associated with iMRI.

Our experience has demonstrated that newer iCT scanners can provide versatile benefits in a wide variety of neurosurgical procedures both in adult and pediatric patients, are cheaper and logistically easier to integrate, and require little input of additional staff [Figure 7]. The iCT provided clinical benefit in our technically difficult cases and has a smooth workflow.

At present, from our experience, the iCT is not only a gold standard imaging modality for spinal surgery but a standard of care for difficult spinal and cranial surgical procedures. Further studies are required to establish its use as a beneficial intraoperative real-time imaging modality that should be utilized in specific patients where it is likely to provide benefit and improve outcome for individual patients. It may be added that more multicenter controlled trials are required to affirm our conclusions.

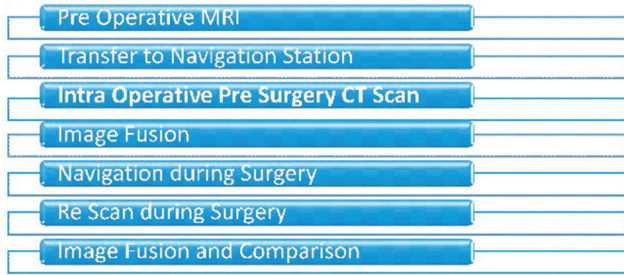


Figure 7: Flowchart of scanning protocol.

CONCLUSION

Our experience has demonstrated that iCT provides versatile benefits in a wide variety of neurosurgical procedures in both adult and pediatric cases, is cheaper and logistically easier to integrate, and requires little input of additional staff. The iCT provided clinical benefit in our technically difficult cases and has a smooth workflow.

Ethical approval

All procedures performed in studies involving human participants were in accordance with the ethical standards of the institutional and/or national research committee and with the 1964 Helsinki Declaration and its later amendments or comparable ethical standards. For this type of study ethical board approval is not required by our institution.

Declaration of patient consent

The authors certify that they have obtained all appropriate patient consent.

Financial support and sponsorship

Publication of this article was made possible by the James I. and Carolyn R. Ausman Educational Foundation.

Conflicts of interest

There are no conflicts of interest.

REFERENCES

1. Barbagallo G, Palmucci S, Visocchi M, Paratore S, Attinà G, Sortino G, *et al.* Portable intraoperative computed tomography scan in image-guided surgery for brain high-grade gliomas: Analysis of technical feasibility and impact on extent of tumor resection. *Oper Neurosur (Hagerstown)* 2016;12:19-30.
2. Bozinov O, Burkhardt JK, Fischer CM, Kockro RA, Bernays RL, Bertalanffy H. Advantages and limitations of intraoperative 3D ultrasound in neurosurgery. Technical note. In: *Intraoperative Imaging*. Berlin: Springer Vienna; 2010. p. 191-6.
3. Brown RA, Nelson JA. The invention and early history of the N-localizer for stereotactic neurosurgery. *Cureus* 2016;8:e642.
4. Golfinos JG, Fitzpatrick BC, Smith LR, Spetzler RF. Clinical use of a frameless stereotactic arm: Results of 325 Cases. *J Neurosurg* 1995;83:197-205.
5. Hartkens T, Hill DL, Castellano-Smith AD, Hawkes DJ, Maurer CR Jr., Martin AJ, *et al.* Measurement and analysis of brain deformation during neurosurgery. *IEEE Trans Med Imaging* 2003;22:82-92.
6. Hill DL, Maurer CR Jr., Maciunas RJ, Barwise JA, Fitzpatrick JM, Wang MY. Measurement of intraoperative brain surface deformation under a craniotomy. *Neurosurgery* 1998;43:514-28.
7. Hirschberg H, Samset E, Hol PK, Tillung T, Lote K. Impact of intraoperative MRI on the surgical results for high-grade gliomas. *Minim Invasive Neurosurg* 2005;48:77-84.
8. Kelly PJ, Kall BA, Goerss S, Earnest F 4th. Computer-assisted stereotaxic laser resection of intra-axial brain neoplasms. *J Neurosurg* 1986;64:427-39.
9. Khoshnevisan A, Allahabadi NS. Neuronavigation: Principles, clinical applications and potential pitfalls. *Iran J Psychiatry* 2012;7:97-103.
10. Lozano A, Philip LG, Ronald RT. *Textbook of Stereotactic and Functional Neurosurgery*. Berlin: Springer; 2009. p. 65.
11. Makary M, Chiocca EA, Erminy N, Antor M, Bergese SD, Abdel-Rasoul M, *et al.* Clinical and economic outcomes of low-field intraoperative MRI-guided tumor resection neurosurgery. *J Magn Reson Imaging* 2011;34:1022-30.
12. Nejat F. Multiloculated hydrocephalus. *Asian J Neurosurg* 2017;12:488.
13. Nimsky C, Ganslandt O, Cerny S, Hastreiter P, Greiner G, Fahlbusch R. Quantification of, visualization of, and compensation for brain shift using intraoperative magnetic resonance imaging. *Neurosurgery* 2000;47:1070-80.
14. Omerhodžić I, Džurlić A, Ahmetpahić A, Rovčanin B, Kalamujić M, Bilalović N, *et al.* Neurosurgical Options for Glioma. In *Glioma-Contemporary Diagnostic and Therapeutic Approaches*. London: Intech Open; 2019.
15. Raabe A, Fichtner J, Gralla J. Advanced intraoperative imaging: Gold standard in brain and spine surgery? *Clin Transl Neurosci* 2017;1:1-4.
16. Rasmussen IA Jr., Lindseth E, Rygh OM, Berntsen EM, Selbekk T, Xu J, *et al.* Functional neuronavigation combined with intra-operative 3D ultrasound: Initial experiences during surgical resections close to eloquent brain areas and future directions in automatic brain shift compensation of preoperative data. *Acta Neurochir (Wien)* 2007;149:365-78.
17. Roberts DW, Hartov A, Kennedy FE, Miga MI, Paulsen KD. Intraoperative brain shift and deformation: A quantitative analysis of cortical displacement in 28 Cases. *Neurosurgery* 1998;43:749-60.
18. Roth J, Biyani N, Beni-Adani L, Constantini S. Real-time neuronavigation with high-quality 3D ultrasound Sono Wand® in pediatric neurosurgery. *Pediatr Neurosurg* 2007;43:185-91.
19. Scarone P, Vincenzo G, Distefano D, Del Grande F, Cianfoni A, Presilla S, *et al.* Use of the Airo mobile intraoperative CT system versus the O-arm for transpedicular screw fixation in the thoracic and lumbar spine: A retrospective cohort study of 263 patients. *J Neurosurg Spine* 2018;29:397-406.

20. Senft C, Bink A, Franz K, Vatter H, Gasser T, Seifert V. Intraoperative MRI guidance and extent of resection in glioma surgery: A randomised, controlled trial. *Lancet Oncol* 2011;12:997-1003.
21. Servello D, Zekaj E, Saleh C, Pacchetti C, Porta M. The pros and cons of intraoperative CT scan in evaluation of deep brain stimulation lead implantation: A retrospective study. *Surgi Neurol Int* 2016;7 Suppl 19:S551-6.
22. Shah MN, Leonard JR, Inder G, Gao F, Geske M, Haydon DH, *et al.* Intraoperative magnetic resonance imaging to reduce the rate of early reoperation for lesion resection in pediatric neurosurgery. *J Neurosurg* 2012;9:259-64. Available from: <https://www.thejns.org/pediatrics/view/journals/j-neurosurg-pediatr/9/3/article-p259.xml>. [Last accessed on 2020 Apr 19].
23. Škrinjar O, Spencer D, Duncan J. Brain shift modeling for use in neurosurgery. In: Wells WM, Colchester A, Delp S, editors. *Medical Image Computing and Computer-Assisted Intervention-MICCAI'98, MICCAI 1998, Lecture Notes in Computer Science*. Vol. 1496. Berlin, Heidelberg: Springer; 1998.
24. Tormenti MJ, Kostov DB, Gardner PA, Kanter AS, Spiro RM, Okonkwo DO. Intraoperative computed tomography image-guided navigation for posterior thoracolumbar spinal instrumentation in spinal deformity surgery. *Neurosurg Focus* 2010;28:E11.
25. Trantakis C, Tittgemeyer M, Schneider JP, Lindner D, Winkler D, Strauss G, *et al.* Investigation of time-dependency of intracranial brain shift and its relation to the extent of tumor removal using intra-operative MRI. *Neurol Res* 2003;25:9-12.
26. White PJ, Whalen S, Tang SC, Clement GT, Jolesz F, Golby AJ. An intraoperative brain shift monitor using shear mode transcranial ultrasound. *J Ultrasound Med* 2009;28:191-203.
27. Willems PW, Taphoorn MJ, Burger H, Sprengel JW, Tulleken CA. Effectiveness of neuronavigation in resecting solitary intracerebral contrast-enhancing tumors: A randomized controlled trial. *J Neurosurg* 2006;104:360-8.
28. Zhang ZZ, Shields LB, Sun DA, Zhang YP, Hunt MA, Shields CB. The art of intraoperative glioma identification. *Front Oncol* 2015;5:175.

How to cite this article: Ashraf M, Choudhary N, Hussain SS, Kamboh UA, Ashraf N. Role of intraoperative computed tomography scanner in modern neurosurgery – An early experience. *Surg Neurol Int* 2020;11:247.