

NCBI Bookshelf. A service of the National Library of Medicine, National Institutes of Health.

PDQ Cancer Information Summaries [Internet]. Bethesda (MD): National Cancer Institute (US); 2002-.

Childhood Ependymoma Treatment (PDQ®)

Health Professional Version

Authors

PDQ Pediatric Treatment Editorial Board.

Published online: March 20, 2020.

This PDQ cancer information summary for health professionals provides comprehensive, peer-reviewed, evidence-based information about the treatment of childhood ependymoma. It is intended as a resource to inform and assist clinicians who care for cancer patients. It does not provide formal guidelines or recommendations for making health care decisions.

This summary is reviewed regularly and updated as necessary by the PDQ Pediatric Treatment Editorial Board, which is editorially independent of the National Cancer Institute (NCI). The summary reflects an independent review of the literature and does not represent a policy statement of NCI or the National Institutes of Health (NIH).

General Information About Childhood Ependymoma

Primary brain tumors, including ependymomas, are a diverse group of diseases that together constitute the most common solid tumor of childhood. Immunohistochemical analysis, cytogenetic and molecular genetic findings, and measures of mitotic activity are increasingly used in tumor diagnosis and classification. Brain tumors are classified according to histology, but tumor location, extent of spread, molecular features, and age are important factors that affect treatment and prognosis.

According to the 2016 revision to the World Health Organization (WHO) classification of tumors of the central nervous system, ependymal tumors are classified into the following five main subtypes:[1]

- Subependymoma (WHO grade I).
- Myxopapillary ependymoma (WHO grade I).
- Ependymoma (WHO grade II).
- Ependymoma, *RELA* fusion–positive (WHO grade II or grade III).
- Anaplastic ependymoma (WHO grade III).

The PDQ childhood brain tumor treatment summaries are organized primarily according to the WHO classification of nervous system tumors.[1] For a full description of the classification of nervous system tumors and a link to the corresponding treatment summary for each type of brain tumor, refer to the PDQ summary on [Childhood Brain and Spinal Cord Tumors Treatment Overview](#).

Incidence

Childhood ependymoma comprises approximately 9% of all childhood brain and spinal cord tumors, representing about 200 cases per year in the United States.[2,3]

Anatomy

Ependymomas arise from ependymal cells that line the ventricles and passageways in the brain and the center of the

spinal cord (refer to Figure 1). Ependymal cells produce cerebrospinal fluid (CSF). These tumors are classified as supratentorial, infratentorial, or spinal. In children, most ependymomas are infratentorial tumors that arise in or around the fourth ventricle and, less commonly, in the supratentorial space. Spinal ependymomas are rare in childhood.

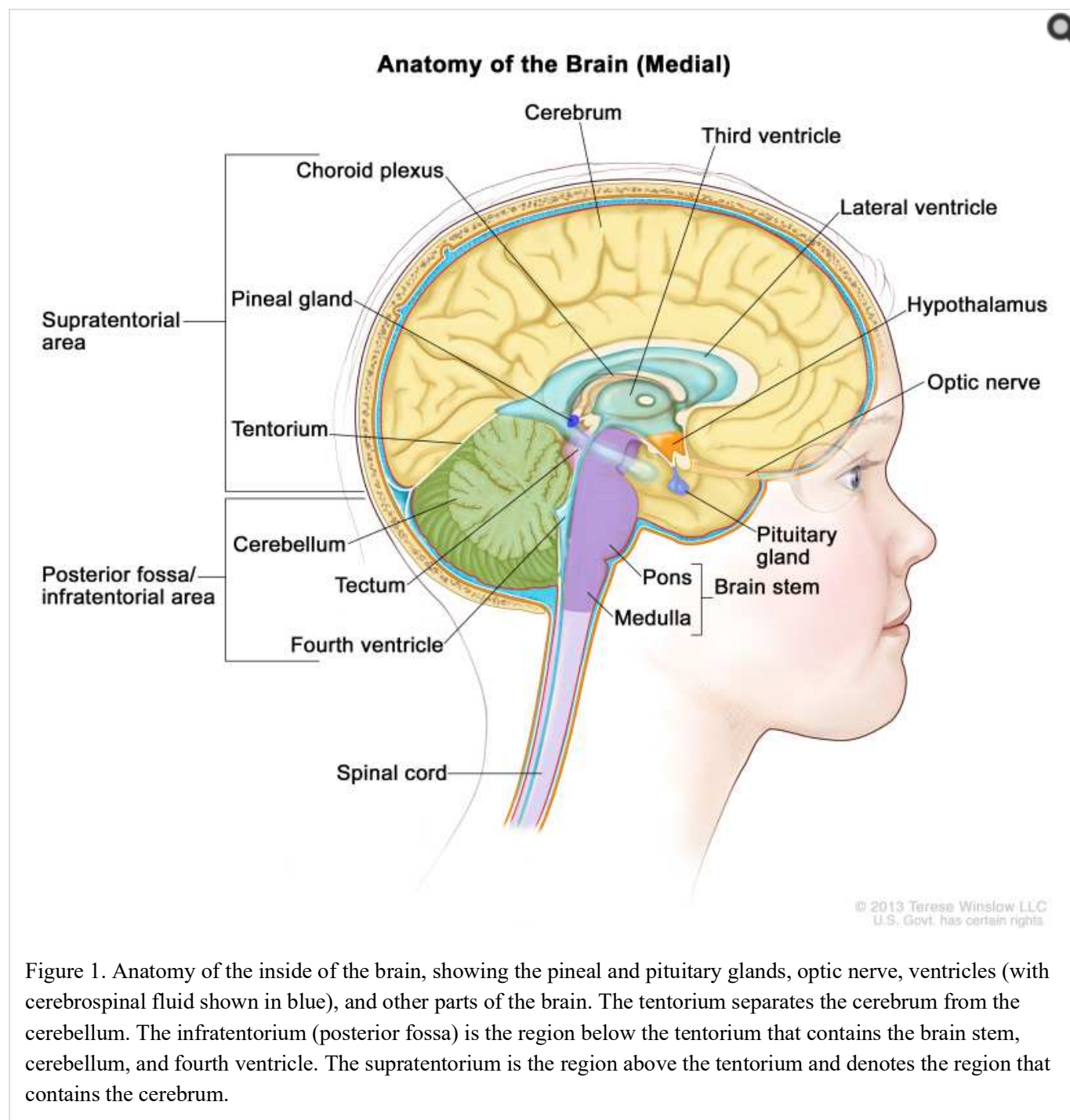


Figure 1. Anatomy of the inside of the brain, showing the pineal and pituitary glands, optic nerve, ventricles (with cerebrospinal fluid shown in blue), and other parts of the brain. The tentorium separates the cerebrum from the cerebellum. The infratentorium (posterior fossa) is the region below the tentorium that contains the brain stem, cerebellum, and fourth ventricle. The supratentorium is the region above the tentorium and denotes the region that contains the cerebrum.

Clinical Features

The clinical presentation of ependymoma is dependent on tumor location.

- **Infratentorial (posterior fossa) ependymomas:** In children, approximately 65% to 75% of ependymomas arise in the posterior fossa.[4] Children with posterior fossa ependymomas may present with signs and symptoms of obstructive hydrocephalus caused by obstruction at the level of the fourth ventricle. They may also present with ataxia, neck pain, or cranial nerve palsies.

- **Supratentorial ependymomas:** Supratentorial ependymomas may result in headaches, seizures, or location-dependent focal neurologic deficits.
- **Spinal cord ependymomas:** Spinal cord ependymomas, which are often the myxopapillary variant, tend to cause back pain, lower extremity weakness, and/or bowel and bladder dysfunction.

Diagnostic Evaluation

Every patient suspected of having an ependymoma is evaluated with diagnostic imaging of the whole brain and spinal cord. The most sensitive method available for evaluating spinal cord subarachnoid metastasis is spinal magnetic resonance imaging (MRI) performed with gadolinium. This is ideally done before surgery to avoid confusion with postoperative blood. If MRI is used, the entire spine is generally imaged in at least two planes with contiguous MRI slices performed after gadolinium enhancement.

If feasible, CSF cytological evaluation is conducted.[5]

Prognostic Factors

Unfavorable factors affecting outcome (except as noted) include the following:

- **Molecular characteristics.**

Posterior fossa ependymomas are divided into the following two groups on the basis of distinctive patterns of gene expression.[6-9]

1. Posterior fossa A ependymoma (PF-EPN-A).

- PF-EPN-A occurs primarily in young children and is characterized by a largely balanced genomic profile, with an increased occurrence of chromosome 1q gain [10-13] and expression of genes and proteins previously shown to be associated with poor prognosis, such as tenascin C and epidermal growth factor receptor.[10,14,15]
- Gain of 1q confers a very poor prognosis despite complete resection and postoperative radiation therapy (5-year event-free survival [EFS], 81.5% for balanced 1q vs. 35.7% for gain 1q).[16][Level of Evidence: 2Di] Chromosome 1q gain was recently identified at the time of relapse in three patients with PF-EPN-A whose tumors did not have 1q gain at diagnosis.[17]

2. Posterior fossa B ependymoma (PF-EPN-B).

- PF-EPN-B occurs primarily in older children and adults and is characterized by a more favorable prognosis and by numerous cytogenetic abnormalities involving whole chromosomes or chromosomal arms.[6,9,18]
- Favorable outcome when compared with PF-EPN-A, with a 5-year progression-free survival (PFS) rate of 73% and an overall survival (OS) rate exceeding 90%.[8,9]
- Gain of 1q is not a prognostic feature in PF-EPN-B, whereas loss of chromosome 13q may confer a poor prognosis.[18]

There is a paucity of data on the optimal risk stratification of spinal ependymoma in children, although inferring from adults, a complete resection confers a favorable prognosis.

Supratentorial tumors can be divided into the following two primary subtypes on the basis of their gene fusion status:

1. Supratentorial ependymomas with *RELA* fusions (ST-EPN-RELA).

- While a retrospective analysis suggested that the *RELA* fusion predicted poorer prognosis,[8] subsequent reports suggest that patients with ST-EPN-RELA who undergo a complete resection and postoperative radiation have relatively favorable survival rates that are in the range of 80% at 5 years.[8,16,17,19] Retrospective studies suggest a poor outcome for patients who undergo complete surgical resections but do not receive postoperative radiation therapy.[8]

2. Supratentorial ependymomas with *YAP1* fusions (ST-EPN-YAP1).

- Patients with ST-EPN-YAP1 have a favorable prognosis (although based on small numbers), with 5-year survival rates approaching 100%.[8,17,20]
- **Younger age at diagnosis.** Younger age at diagnosis has historically been a poor prognostic factor, although this could partially result from the common practice of avoiding or deferring radiation in children younger than 3 years. In a prospective Children's Oncology Group (COG) trial (ACNS0121 [NCT00027846]), immediate postoperative radiation therapy was given to all children older than 1 year after gross-total resection or near-total resection. The study demonstrated that there was no significant difference in 5-year PFS or OS between patients aged 1 to 3 years and patients aged 3 to 21 years.[16]
- **Anaplastic histology.** Anaplastic histology has been associated with a poor prognosis.[21][Level of evidence: 2A]; [22-24]; [25][Level of evidence: 3iA]; [26][Level of evidence: 3iiiDi] However, the distinction between grade II and grade III disease has significant interobserver variability, confounding the use of anaplasia as a prognostic factor. [27]
- **Subtotal resection.** Subtotal resection confers a very poor prognosis.[16,24]; [21][Level of evidence: 2A]
- **Lower doses of radiation.** Lower doses of radiation or chemotherapy-only protocols confer a poor prognosis. [9,17,28,29]

Follow-up After Treatment

Surveillance neuroimaging, coupled with clinical assessments, is generally recommended after treatment for ependymoma. Most practitioners obtain MRI imaging of the brain and/or spinal cord at the following intervals: [30][Level of evidence: 2A]

- First 2 to 3 years after treatment: Every 3 to 4 months.
- Four to 5 years after treatment: Every 6 months.
- More than 5 years after treatment: Annually because of the high incidence of late recurrences and evidence showing better outcomes if relapsed ependymomas are identified on surveillance MRI (5-year OS rate, 37%), compared with cases identified because of the development of symptoms (5-year OS rate, 8%).

References

1. Louis DN, Ohgaki H, Wiestler OD: WHO Classification of Tumours of the Central Nervous System. 4th rev.ed. Lyon, France: IARC Press, 2016.
2. Gurney JG, Smith MA, Bunin GR: CNS and miscellaneous intracranial and intraspinal neoplasms. In: Ries LA, Smith MA, Gurney JG, et al., eds.: Cancer incidence and survival among children and adolescents: United States SEER Program 1975-1995. Bethesda, Md: National Cancer Institute, SEER Program, 1999. NIH Pub.No. 99-4649, Chapter 3, pp 51-63. Also available online. Last accessed March 20, 2020.
3. Central Brain Tumor Registry of the United States: Statistical Report: Primary Brain Tumors in the United States, 1997-2001. Hinsdale, Ill: Central Brain Tumor Registry of the United States, 2004..
4. Andreiuolo F, Puget S, Peyre M, et al.: Neuronal differentiation distinguishes supratentorial and infratentorial childhood ependymomas. *Neuro Oncol* 12 (11): 1126-34, 2010. [PMC free article: PMC3098029] [PubMed:

20615923]

5. Moreno L, Pollack IF, Duffner PK, et al.: Utility of cerebrospinal fluid cytology in newly diagnosed childhood ependymoma. *J Pediatr Hematol Oncol* 32 (6): 515-8, 2010. [PubMed: 20463607]
6. Wani K, Armstrong TS, Vera-Bolanos E, et al.: A prognostic gene expression signature in infratentorial ependymoma. *Acta Neuropathol* 123 (5): 727-38, 2012. [PMC free article: PMC4013829] [PubMed: 22322993]
7. Witt H, Mack SC, Ryzhova M, et al.: Delineation of two clinically and molecularly distinct subgroups of posterior fossa ependymoma. *Cancer Cell* 20 (2): 143-57, 2011. [PMC free article: PMC4154494] [PubMed: 21840481]
8. Pajtler KW, Witt H, Sill M, et al.: Molecular Classification of Ependymal Tumors across All CNS Compartments, Histopathological Grades, and Age Groups. *Cancer Cell* 27 (5): 728-43, 2015. [PMC free article: PMC4712639] [PubMed: 25965575]
9. Ramaswamy V, Hielscher T, Mack SC, et al.: Therapeutic Impact of Cytoreductive Surgery and Irradiation of Posterior Fossa Ependymoma in the Molecular Era: A Retrospective Multicohort Analysis. *J Clin Oncol* 34 (21): 2468-77, 2016. [PMC free article: PMC4962737] [PubMed: 27269943]
10. Mendrzyk F, Korshunov A, Benner A, et al.: Identification of gains on 1q and epidermal growth factor receptor overexpression as independent prognostic markers in intracranial ependymoma. *Clin Cancer Res* 12 (7 Pt 1): 2070-9, 2006. [PubMed: 16609018]
11. Korshunov A, Witt H, Hielscher T, et al.: Molecular staging of intracranial ependymoma in children and adults. *J Clin Oncol* 28 (19): 3182-90, 2010. [PubMed: 20516456]
12. Kilday JP, Mitra B, Domerg C, et al.: Copy number gain of 1q25 predicts poor progression-free survival for pediatric intracranial ependymomas and enables patient risk stratification: a prospective European clinical trial cohort analysis on behalf of the Children's Cancer Leukaemia Group (CCLG), Societe Francaise d'Oncologie Pediatrique (SFOP), and International Society for Pediatric Oncology (SIOP). *Clin Cancer Res* 18 (7): 2001-11, 2012. [PubMed: 22338015]
13. Godfraind C, Kaczmarek JM, Kocak M, et al.: Distinct disease-risk groups in pediatric supratentorial and posterior fossa ependymomas. *Acta Neuropathol* 124 (2): 247-57, 2012. [PMC free article: PMC3554251] [PubMed: 22526017]
14. Korshunov A, Golanov A, Timirgaz V: Immunohistochemical markers for intracranial ependymoma recurrence. An analysis of 88 cases. *J Neurol Sci* 177 (1): 72-82, 2000. [PubMed: 10967185]
15. Andreiuolo F, Le Teuff G, Bayar MA, et al.: Integrating Tenascin-C protein expression and 1q25 copy number status in pediatric intracranial ependymoma prognostication: A new model for risk stratification. *PLoS One* 12 (6): e0178351, 2017. [PMC free article: PMC5472261] [PubMed: 28617804]
16. Merchant TE, Bendel AE, Sabin ND, et al.: Conformal Radiation Therapy for Pediatric Ependymoma, Chemotherapy for Incompletely Resected Ependymoma, and Observation for Completely Resected, Supratentorial Ependymoma. *J Clin Oncol* 37 (12): 974-983, 2019. [PubMed: 30811284]
17. Upadhyaya SA, Robinson GW, Onar-Thomas A, et al.: Molecular grouping and outcomes of young children with newly diagnosed ependymoma treated on the multi-institutional SJYC07 trial. *Neuro Oncol* 21 (10): 1319-1330, 2019. [PMC free article: PMC6784269] [PubMed: 30976811]
18. Cavalli FMG, Hübner JM, Sharma T, et al.: Heterogeneity within the PF-EPN-B ependymoma subgroup. *Acta Neuropathol* 136 (2): 227-237, 2018. [PMC free article: PMC6373486] [PubMed: 30019219]
19. Fukuoka K, Kanemura Y, Shofuda T, et al.: Significance of molecular classification of ependymomas: C11orf95-RELA fusion-negative supratentorial ependymomas are a heterogeneous group of tumors. *Acta Neuropathol Commun* 6 (1): 134, 2018. [PMC free article: PMC6278135] [PubMed: 30514397]
20. Andreiuolo F, Varlet P, Tauziède-Espariat A, et al.: Childhood supratentorial ependymomas with YAP1-MAMLD1 fusion: an entity with characteristic clinical, radiological, cytogenetic and histopathological features. *Brain Pathol* 29 (2): 205-216, 2019. [PubMed: 30246434]
21. Massimino M, Miceli R, Giangaspero F, et al.: Final results of the second prospective AIEOP protocol for pediatric intracranial ependymoma. *Neuro Oncol* 18 (10): 1451-60, 2016. [PMC free article: PMC5035526]

[PubMed: 27194148]

22. Merchant TE, Jenkins JJ, Burger PC, et al.: Influence of tumor grade on time to progression after irradiation for localized ependymoma in children. *Int J Radiat Oncol Biol Phys* 53 (1): 52-7, 2002. [PubMed: 12007941]
23. Korshunov A, Golanov A, Sycheva R, et al.: The histologic grade is a main prognostic factor for patients with intracranial ependymomas treated in the microneurosurgical era: an analysis of 258 patients. *Cancer* 100 (6): 1230-7, 2004. [PubMed: 15022291]
24. Tamburrini G, D'Ercole M, Pettorini BL, et al.: Survival following treatment for intracranial ependymoma: a review. *Childs Nerv Syst* 25 (10): 1303-12, 2009. [PubMed: 19387655]
25. Amirian ES, Armstrong TS, Aldape KD, et al.: Predictors of survival among pediatric and adult ependymoma cases: a study using Surveillance, Epidemiology, and End Results data from 1973 to 2007. *Neuroepidemiology* 39 (2): 116-24, 2012. [PMC free article: PMC3470871] [PubMed: 22846789]
26. Tihan T, Zhou T, Holmes E, et al.: The prognostic value of histological grading of posterior fossa ependymomas in children: a Children's Oncology Group study and a review of prognostic factors. *Mod Pathol* 21 (2): 165-77, 2008. [PubMed: 18084249]
27. Ellison DW, Kocak M, Figarella-Branger D, et al.: Histopathological grading of pediatric ependymoma: reproducibility and clinical relevance in European trial cohorts. *J Negat Results Biomed* 10: 7, 2011. [PMC free article: PMC3117833] [PubMed: 21627842]
28. Vaidya K, Smee R, Williams JR: Prognostic factors and treatment options for paediatric ependymomas. *J Clin Neurosci* 19 (9): 1228-35, 2012. [PubMed: 22840355]
29. Zapotocky M, Beera K, Adamski J, et al.: Survival and functional outcomes of molecularly defined childhood posterior fossa ependymoma: Cure at a cost. *Cancer* 125 (11): 1867-1876, 2019. [PMC free article: PMC6508980] [PubMed: 30768777]
30. Massimino M, Barretta F, Modena P, et al.: Pediatric intracranial ependymoma: correlating signs and symptoms at recurrence with outcome in the second prospective AIEOP protocol follow-up. *J Neurooncol* 140 (2): 457-465, 2018. [PubMed: 30109673]

Molecular Features of Childhood Ependymoma

Molecular Subgroups of Ependymoma

Molecular characterization studies have identified nine molecular subgroups of ependymoma, six of which predominate in childhood. The subgroups are determined by their distinctive DNA methylation and gene expression profiles and by their distinctive spectrum of genomic alterations (refer to Figure 2).[1-4]

- Infratentorial tumors.
 - Posterior fossa A (PF-EPN-A), loss of H3 K27 trimethylation mark.
 - Posterior fossa B (PF-EPN-B), retained H3 K27 trimethylation mark.
- Supratentorial tumors.
 - *C11orf95-RELA*-positive ependymoma (ST-EPN-RELA).
 - *YAP1* fusion-positive ependymoma (ST-EPN-YAP1).
- Spinal tumors.
 - Myxopapillary ependymoma (SP-EPN-MPE).
 - Classic histology (SP-EPN).

Subependymoma—whether supratentorial, infratentorial, or spinal—accounts for the remaining three molecular

variants, and it is rarely, if ever, seen in children.

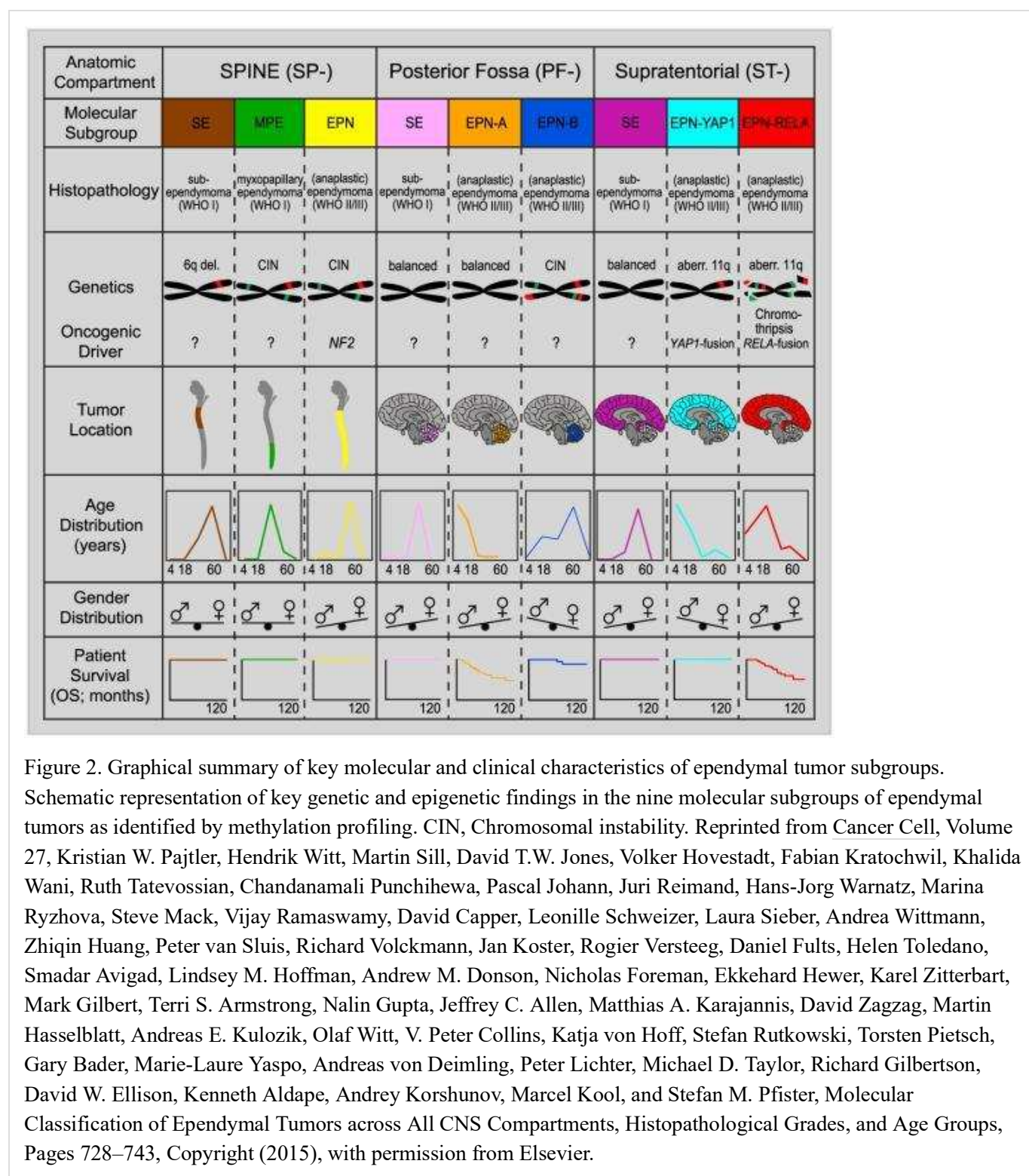


Figure 2. Graphical summary of key molecular and clinical characteristics of ependymal tumor subgroups. Schematic representation of key genetic and epigenetic findings in the nine molecular subgroups of ependymal tumors as identified by methylation profiling. CIN, Chromosomal instability. Reprinted from *Cancer Cell*, Volume 27, Kristian W. Pajtler, Hendrik Witt, Martin Sill, David T.W. Jones, Volker Hovestadt, Fabian Kratochwil, Khalida Wani, Ruth Tatevossian, Chandanamali Punchihewa, Pascal Johann, Juri Reimand, Hans-Jorg Warnatz, Marina Ryzhova, Steve Mack, Vijay Ramaswamy, David Capper, Leonille Schweizer, Laura Sieber, Andrea Wittmann, Zhiqin Huang, Peter van Sluis, Richard Volckmann, Jan Koster, Rogier Versteeg, Daniel Fults, Helen Toledano, Smadar Avigad, Lindsey M. Hoffman, Andrew M. Donson, Nicholas Foreman, Ekkehard Hewer, Karel Zitterbart, Mark Gilbert, Terri S. Armstrong, Nalin Gupta, Jeffrey C. Allen, Matthias A. Karajannis, David Zagzag, Martin Hasselblatt, Andreas E. Kulozik, Olaf Witt, V. Peter Collins, Katja von Hoff, Stefan Rutkowski, Torsten Pietsch, Gary Bader, Marie-Laure Yaspo, Andreas von Deimling, Peter Lichter, Michael D. Taylor, Richard Gilbertson, David W. Ellison, Kenneth Aldape, Andrey Korshunov, Marcel Kool, and Stefan M. Pfister, *Molecular Classification of Ependymal Tumors across All CNS Compartments, Histopathological Grades, and Age Groups*, Pages 728–743, Copyright (2015), with permission from Elsevier.

Infratentorial tumors

Posterior fossa A ependymoma (PF-EPN-A)

The most common posterior fossa ependymoma subgroup is PF-EPN-A and is characterized by the following:

- Presentation in young children (median age, 3 years).[1,5]

- Low rates of mutations that affect protein structure, approximately five per genome.[2]
- Gain of chromosome 1q, a known poor prognostic factor for ependymoma,[6] in approximately 25% of cases. [1,3,7]
- A balanced chromosomal profile with few chromosomal gains or losses.[1,2]
- Loss of the H3 K27 trimethylation mark and globally hypomethylated DNA.[8] Loss of the H3 K27 trimethylation mark occurs by one of the following two mechanisms:
 - Recurrent mutations of CXorf67/EZHIP in 10% of cases, with high CXorf67/EZHIP mRNA expression across almost all PF-EPN-A.[9,10] CXorf67/EZHIP expression (with or without mutation) results in inhibition of the methyltransferase EZH2 leading to loss of the H3 K27 trimethylation mark.[10,11]
 - Recurrent K27M mutations in histone H3 variants in a small proportion of cases.[12,13] Unlike diffuse intrinsic pontine gliomas, mutations in H3.1 (HIST1H3B and HIST1H3C) are more common than mutations in H3.3 (H3F3A).[9] Histone mutations are mutually exclusive with high expression of CXorf67/EZHIP,[9] and they also lead to loss of the H3 K27 trimethylation mark though EZH2 inhibition.

A study that included over 600 cases of PF-EPN-A used methylation array profiling to divide this population into two distinctive subgroups, PFA-1 and PFA-2.[9] Gene expression profiling suggested that these two subtypes may arise in different anatomic locations in the hindbrain. Within both of the PFA-1 and PFA-2 groups, distinctive minor subtypes could be identified, suggesting the presence of heterogeneity. Additional study will be required to define the clinical significance of these subtypes.

Posterior fossa B ependymoma (PF-EPN-B)

The PF-EPN-B subgroup is less common than the PF-EPN-A subgroup, representing 15% to 20% of all posterior fossa ependymomas in children. PF-EPN-B is characterized by the following:

- Presentation primarily in adolescents and young adults (median age, 30 years).[1,5]
- Low rates of mutations that affect protein structure (approximately five per genome), with no recurring mutations.[3]
- Numerous cytogenetic abnormalities, primarily involving the gain/loss of whole chromosomes.[1,3]
- Retained H3 K27 trimethylation.[8]

Supratentorial tumors

Supratentorial ependymomas with RELA fusions (ST-EPN-RELA)

ST-EPN-RELA is the largest subset of pediatric supratentorial ependymomas and is characterized by gene fusions involving *RELA*,[14,15] a transcriptional factor important in NF-κB pathway activity. ST-EPN-RELA is characterized by the following:

- Represents approximately 70% of supratentorial ependymomas in children,[14,15] and presents at a median age of 8 years.[1]
- Presence of *C11orf95-RELA* fusions resulting from chromothripsis involving chromosome 11q13.1.[14]
- Low rates of mutations that affect protein structure and absence of recurring mutations outside of *C11orf95-RELA* fusions.[14]
- Evidence of NF-κB pathway activation at the protein and RNA level.[14]

- Gain of chromosome 1q, in approximately one-quarter of cases, with an indeterminate effect on survival.[1]

Supratentorial ependymomas with *YAP1* fusions (*ST-EPN-YAP1*)

ST-EPN-YAP1 is the second, less common subset of supratentorial ependymomas and has fusions involving *YAP1* on chromosome 11. *ST-EPN-YAP1* is characterized by the following:

- Median age at diagnosis of 1.4 years.[1]
- Presence of a gene fusion involving *YAP1*, with *MAMLD1* being the most common fusion partner.[1,14]
- A relatively stable genome with few chromosomal changes other than the *YAP1* fusion.[1]

Supratentorial ependymomas without *RELA* or *YAP1* fusions (on chromosome 11) are an undefined entity, and it is unclear what these samples represent. By DNA methylation analysis, these samples often cluster with other entities such as high-grade gliomas and embryonal tumors; caution should be taken when diagnosing a supratentorial ependymoma that does not harbor a fusion involving chromosome 11.[16,17]

References

1. Pajtler KW, Witt H, Sill M, et al.: Molecular Classification of Ependymal Tumors across All CNS Compartments, Histopathological Grades, and Age Groups. *Cancer Cell* 27 (5): 728-43, 2015. [PMC free article: PMC4712639] [PubMed: 25965575]
2. Witt H, Mack SC, Ryzhova M, et al.: Delineation of two clinically and molecularly distinct subgroups of posterior fossa ependymoma. *Cancer Cell* 20 (2): 143-57, 2011. [PMC free article: PMC4154494] [PubMed: 21840481]
3. Mack SC, Witt H, Piro RM, et al.: Epigenomic alterations define lethal CIMP-positive ependymomas of infancy. *Nature* 506 (7489): 445-50, 2014. [PMC free article: PMC4174313] [PubMed: 24553142]
4. Pajtler KW, Mack SC, Ramaswamy V, et al.: The current consensus on the clinical management of intracranial ependymoma and its distinct molecular variants. *Acta Neuropathol* 133 (1): 5-12, 2017. [PMC free article: PMC5209402] [PubMed: 27858204]
5. Ramaswamy V, Hielscher T, Mack SC, et al.: Therapeutic Impact of Cytoreductive Surgery and Irradiation of Posterior Fossa Ependymoma in the Molecular Era: A Retrospective Multicohort Analysis. *J Clin Oncol* 34 (21): 2468-77, 2016. [PMC free article: PMC4962737] [PubMed: 27269943]
6. Korshunov A, Witt H, Hielscher T, et al.: Molecular staging of intracranial ependymoma in children and adults. *J Clin Oncol* 28 (19): 3182-90, 2010. [PubMed: 20516456]
7. Merchant TE, Bendel AE, Sabin ND, et al.: Conformal Radiation Therapy for Pediatric Ependymoma, Chemotherapy for Incompletely Resected Ependymoma, and Observation for Completely Resected, Supratentorial Ependymoma. *J Clin Oncol* 37 (12): 974-983, 2019. [PubMed: 30811284]
8. Panwalkar P, Clark J, Ramaswamy V, et al.: Immunohistochemical analysis of H3K27me3 demonstrates global reduction in group-A childhood posterior fossa ependymoma and is a powerful predictor of outcome. *Acta Neuropathol* 134 (5): 705-714, 2017. [PMC free article: PMC5647236] [PubMed: 28733933]
9. Pajtler KW, Wen J, Sill M, et al.: Molecular heterogeneity and CXorf67 alterations in posterior fossa group A (PFA) ependymomas. *Acta Neuropathol* 136 (2): 211-226, 2018. [PMC free article: PMC6105278] [PubMed: 29909548]
10. Hübner JM, Müller T, Papageorgiou DN, et al.: EZHIP/CXorf67 mimics K27M mutated oncohistones and functions as an intrinsic inhibitor of PRC2 function in aggressive posterior fossa ependymoma. *Neuro Oncol* 21 (7): 878-889, 2019. [PMC free article: PMC6620627] [PubMed: 30923826]
11. Jain SU, Do TJ, Lund PJ, et al.: PFA ependymoma-associated protein EZHIP inhibits PRC2 activity through a H3 K27M-like mechanism. *Nat Commun* 10 (1): 2146, 2019. [PMC free article: PMC6513997] [PubMed: 31086175]

12. Gessi M, Capper D, Sahm F, et al.: Evidence of H3 K27M mutations in posterior fossa ependymomas. *Acta Neuropathol* 132 (4): 635-7, 2016. [PubMed: 27539613]
13. Ryall S, Guzman M, Elbabaa SK, et al.: H3 K27M mutations are extremely rare in posterior fossa group A ependymoma. *Childs Nerv Syst* 33 (7): 1047-1051, 2017. [PubMed: 28623522]
14. Parker M, Mohankumar KM, Punchedewa C, et al.: C11orf95-RELA fusions drive oncogenic NF-κB signalling in ependymoma. *Nature* 506 (7489): 451-5, 2014. [PMC free article: PMC4050669] [PubMed: 24553141]
15. Pietsch T, Wohlers I, Goschzik T, et al.: Supratentorial ependymomas of childhood carry C11orf95-RELA fusions leading to pathological activation of the NF-κB signaling pathway. *Acta Neuropathol* 127 (4): 609-11, 2014. [PubMed: 24562983]
16. Sturm D, Orr BA, Toprak UH, et al.: New Brain Tumor Entities Emerge from Molecular Classification of CNS-PNETs. *Cell* 164 (5): 1060-72, 2016. [PMC free article: PMC5139621] [PubMed: 26919435]
17. Fukuoka K, Kanemura Y, Shofuda T, et al.: Significance of molecular classification of ependymomas: C11orf95-RELA fusion-negative supratentorial ependymomas are a heterogeneous group of tumors. *Acta Neuropathol Commun* 6 (1): 134, 2018. [PMC free article: PMC6278135] [PubMed: 30514397]

Histopathologic Classification of Childhood Ependymal Tumors

For the first time, the 2016 World Health Organization (WHO) Classification of Tumors of the Central Nervous System (CNS) incorporated the addition of genotypic findings in the classification of select CNS tumors. This integrated classification is intended to define more homogeneous entities that will improve the accuracy of diagnoses, refine prognoses, and more reliably reach conclusions regarding treatment strategies.

Ependymal tumors are now classified into the following five main subtypes:[1]

1. **Subependymoma (WHO grade I):** A subependymoma is a slow-growing neoplasm, typically attached to the ventricle wall. It is composed of glial tumor cell clusters embedded in a fibrillary matrix.

The true incidence of subependymomas (WHO grade I) is difficult to determine. These tumors are frequently asymptomatic and may be found incidentally at autopsy. Subependymomas probably comprise less than 5% of all ependymal tumors.

A diagnosis of subependymoma in a child is questionable, and further review or molecular analysis should be considered.[2]

2. **Myxopapillary ependymoma (WHO grade I):** A myxopapillary ependymoma arises almost exclusively in the location of the conus medullaris, cauda equina, and filum terminale of the spinal cord and is characterized histologically by tumor cells arranged in a papillary manner around vascularized myxoid stromal cores.
3. **Ependymoma (WHO grade II):** The ependymoma, which is considered a grade II neoplasm originating from the walls of the ventricles or from the spinal canal, is composed of neoplastic ependymal cells. In the 2016 WHO revision, the term *cellular ependymoma* was eliminated as a subtype because it was felt to be synonymous with standard ependymoma. Additional subtypes of ependymoma WHO grade II tumors include the following:
 - Papillary ependymoma—forms linear, epithelial-like surfaces along cerebrospinal fluid exposures.
 - Clear cell ependymoma—displays an oligodendroglial-like appearance with perinuclear halos. This variant is preferentially located in the supratentorial compartment of the brain.
 - Tanycytic ependymoma—the rarest form of grade II ependymoma. This subtype is most commonly found in the spinal cord. Tumor cells are arranged in fascicles of variable width and cell density and are poorly intertwined.
4. **Ependymoma, *RELA* fusion–positive (WHO grade II or grade III):** This integrated diagnosis is seen in most supratentorial ependymal tumors in children. Phenotypically, it is similar to ependymoma (WHO grade II) or

anaplastic ependymoma (WHO grade III). These tumors are characterized by a *C11orf95-RELA* fusion, and LICAM immunohistochemistry may serve as a surrogate for this subtype.[3]

5. **Anaplastic ependymoma (WHO grade III):** This subtype is also known as malignant ependymoma. An anaplastic ependymoma is considered a malignant glioma of ependymal differentiation and, compared with the grade II ependymomas, shows increased cellularity and increased mitotic activity, often associated with microvascular proliferation and necrosis. The distinction between grade II and grade III has significant interobserver variability and lacks uniformity across cooperative group studies.[4]

Subependymomas and myxopapillary ependymomas are usually considered to be clinically and pathologically distinct from the grade II and grade III ependymomas.

Although supratentorial and infratentorial ependymomas are believed to arise from radial glia cells, they have different genomics, genomic landscapes, gene expression, and immunohistochemical signatures.[5-8] Supratentorial tumors are more often characterized by neuronal differentiation.[6] It is clear that supratentorial and infratentorial ependymomas should be considered separate biological entities.[5,8-11]

Ependymoblastoma is no longer recognized in the WHO classification and is now classified as an embryonal tumor with multilayered rosettes (refer to the PDQ summary on [Childhood Medulloblastoma and Other Central Nervous System Embryonal Tumors Treatment](#) for more information).

References

1. Louis DN, Ohgaki H, Wiestler OD: WHO Classification of Tumours of the Central Nervous System. 4th rev.ed. Lyon, France: IARC Press, 2016.
2. Pajtler KW, Mack SC, Ramaswamy V, et al.: The current consensus on the clinical management of intracranial ependymoma and its distinct molecular variants. *Acta Neuropathol* 133 (1): 5-12, 2017. [PMC free article: [PMC5209402](#)] [PubMed: [27858204](#)]
3. Parker M, Mohankumar KM, PUNCHIHEWA C, et al.: C11orf95-RELA fusions drive oncogenic NF-κB signalling in ependymoma. *Nature* 506 (7489): 451-5, 2014. [PMC free article: [PMC4050669](#)] [PubMed: [24553141](#)]
4. Ellison DW, Kocak M, Figarella-Branger D, et al.: Histopathological grading of pediatric ependymoma: reproducibility and clinical relevance in European trial cohorts. *J Negat Results Biomed* 10: 7, 2011. [PMC free article: [PMC3117833](#)] [PubMed: [21627842](#)]
5. Taylor MD, Poppleton H, Fuller C, et al.: Radial glia cells are candidate stem cells of ependymoma. *Cancer Cell* 8 (4): 323-35, 2005. [PubMed: [16226707](#)]
6. Andreiuolo F, Puget S, Peyre M, et al.: Neuronal differentiation distinguishes supratentorial and infratentorial childhood ependymomas. *Neuro Oncol* 12 (11): 1126-34, 2010. [PMC free article: [PMC3098029](#)] [PubMed: [20615923](#)]
7. Grill J, Bergthold G, Ferreira C: Pediatric ependymomas: will molecular biology change patient management? *Curr Opin Oncol* 23 (6): 638-42, 2011. [PubMed: [21892086](#)]
8. Mack SC, Pajtler KW, Chavez L, et al.: Therapeutic targeting of ependymoma as informed by oncogenic enhancer profiling. *Nature* 553 (7686): 101-105, 2018. [PMC free article: [PMC5993422](#)] [PubMed: [29258295](#)]
9. Mack SC, Witt H, Piro RM, et al.: Epigenomic alterations define lethal CIMP-positive ependymomas of infancy. *Nature* 506 (7489): 445-50, 2014. [PMC free article: [PMC4174313](#)] [PubMed: [24553142](#)]
10. Pajtler KW, Witt H, Sill M, et al.: Molecular Classification of Ependymal Tumors across All CNS Compartments, Histopathological Grades, and Age Groups. *Cancer Cell* 27 (5): 728-43, 2015. [PMC free article: [PMC4712639](#)] [PubMed: [25965575](#)]
11. Johnson RA, Wright KD, Poppleton H, et al.: Cross-species genomics matches driver mutations and cell compartments to model ependymoma. *Nature* 466 (7306): 632-6, 2010. [PMC free article: [PMC2912966](#)] [PubMed: [20639864](#)]

Stage Information for Childhood Ependymoma

Although there is no formal staging system, ependymomas are divided into supratentorial, infratentorial, and spinal tumors. Approximately 20% of childhood ependymomas arise in the spine, and 80% arise in the brain (30% in the supratentorial region and 70% in the infratentorial region).[1]

Ependymomas usually originate in the ependymal linings of ventricles or central canal or ventriculus terminalis of the spinal cord and have access to the cerebrospinal fluid. Therefore, these tumors may spread throughout the neuraxis, although dissemination is noted in less than 10% of patients with grade II and grade III ependymomas. Considering the rarity of disseminated disease in posterior fossa and supratentorial ependymoma, it is crucial that imaging of the neuraxis be performed presurgically; spinal imaging should be repeated before initiating radiation therapy to re-evaluate whether metastatic disease is present (as opposed to postoperative blood/vascular congestion).

Myxopapillary ependymomas may disseminate to the nervous system early in the course of illness,[2,3] and imaging of the brain is recommended.

References

1. Villano JL, Parker CK, Dolecek TA: Descriptive epidemiology of ependymal tumours in the United States. *Br J Cancer* 108 (11): 2367-71, 2013. [PMC free article: [PMC3681017](#)] [PubMed: [23660944](#)]
2. Fassett DR, Pingree J, Kestle JR: The high incidence of tumor dissemination in myxopapillary ependymoma in pediatric patients. Report of five cases and review of the literature. *J Neurosurg* 102 (1 Suppl): 59-64, 2005. [PubMed: [16206735](#)]
3. Bandopadhyay P, Silvera VM, Ciarlini PDSC, et al.: Myxopapillary ependymomas in children: imaging, treatment and outcomes. *J Neurooncol* 126 (1): 165-174, 2016. [PubMed: [26468139](#)]

Treatment Option Overview for Childhood Ependymoma

Many of the improvements in survival in patients with childhood cancer have been made as a result of clinical trials that have attempted to improve on the best available, accepted therapy. Clinical trials in pediatrics are designed to compare new therapy with therapy that is currently accepted as standard. This comparison may be done in a randomized study of two treatment arms or by evaluating a single new treatment and comparing the results with those previously obtained with existing therapy.

Because of the relative rarity of cancer in children, all patients with aggressive brain tumors should be considered for entry into a clinical trial. To determine and implement optimum treatment, treatment planning by a multidisciplinary team of cancer specialists who have experience treating childhood brain tumors is required. Radiation therapy for pediatric brain tumors is technically demanding and should be performed in centers that have experience in that area to ensure optimal results.

Treatment of childhood ependymoma begins with surgery. The type of adjuvant therapy given, such as a second surgery, chemotherapy, or radiation therapy, depends on the following:

- Subtype of ependymoma.
- Location of the tumor.
- Whether the tumor was completely removed during the initial surgery.
- Whether the tumor has disseminated throughout the central nervous system.
- Child's age.

[Table 1](#) describes the standard treatment options for newly diagnosed and recurrent childhood ependymoma.

Table 1. Standard Treatment Options for Childhood Ependymoma

Treatment Group	Standard Treatment Options
Newly diagnosed childhood myxopapillary ependymoma (WHO grade I)	Surgery with or without adjuvant radiation therapy
Newly diagnosed childhood ependymoma (WHO grade II), anaplastic ependymoma (WHO grade III), or <i>RELA</i> fusion–positive ependymoma:	Surgery
	Adjuvant therapy:
	—Radiation therapy
No residual disease, no disseminated disease	—Radiation therapy
Residual disease, no disseminated disease	—Second-look surgery
	—Radiation therapy
	—Preirradiation chemotherapy
Central nervous system disseminated disease	—Radiation therapy (not considered standard treatment)
	—Chemotherapy (not considered standard treatment)
Children younger than 1 year	—Chemotherapy
	—Deferred radiation therapy
Recurrent childhood ependymoma	Surgery
	Radiation therapy and/or chemotherapy

Dramatic improvements in survival have been achieved for children and adolescents with cancer. Between 1975 and 2010, childhood cancer mortality decreased by more than 50%.^[1] Childhood and adolescent cancer survivors require close monitoring because cancer therapy side effects may persist or develop months or years after treatment. (Refer to the PDQ summary Late Effects of Treatment for Childhood Cancer for specific information about the incidence, type, and monitoring of late effects in childhood and adolescent cancer survivors.)

References

1. Smith MA, Altekruze SF, Adamson PC, et al.: Declining childhood and adolescent cancer mortality. *Cancer* 120 (16): 2497-506, 2014. [PMC free article: PMC4136455] [PubMed: 24853691]

Treatment of Childhood Myxopapillary Ependymoma

Myxopapillary ependymomas, considered to be a histologic subtype of ependymoma, have a relatively high incidence of central nervous system tumor dissemination at diagnosis and at follow-up. Imaging of the complete craniospinal axis at the time of diagnosis and during follow-up is indicated.^[1,2]

Standard treatment options for newly diagnosed childhood myxopapillary ependymoma (World Health Organization [WHO] grade I) include the following:

1. Surgery with or without adjuvant radiation therapy.

Historically, the management of myxopapillary ependymoma (WHO grade I) consisted of an attempt at en bloc resection of the tumor with no further treatment in the case of a gross-total resection.^{[3]; [4]}[Level of evidence: 3iiiDi] However, based on the finding that dissemination of these tumors to other parts of the neuraxis can occur—

particularly when complete resection is not obtained—and evidence that focal radiation therapy may improve progression-free survival, many practitioners now favor the use of radiation therapy after surgical resection of the primary mass.[1,3]; [5][Level of evidence: 3iiiDi]; [6,7][Level of evidence: 3iiiDiii]

References

1. Fassett DR, Pingree J, Kestle JR: The high incidence of tumor dissemination in myxopapillary ependymoma in pediatric patients. Report of five cases and review of the literature. *J Neurosurg* 102 (1 Suppl): 59-64, 2005. [PubMed: 16206735]
2. Bagley CA, Kothbauer KF, Wilson S, et al.: Resection of myxopapillary ependymomas in children. *J Neurosurg* 106 (4 Suppl): 261-7, 2007. [PubMed: 17465358]
3. Akyurek S, Chang EL, Yu TK, et al.: Spinal myxopapillary ependymoma outcomes in patients treated with surgery and radiotherapy at M.D. Anderson Cancer Center. *J Neurooncol* 80 (2): 177-83, 2006. [PubMed: 16648988]
4. Bagley CA, Wilson S, Kothbauer KF, et al.: Long term outcomes following surgical resection of myxopapillary ependymomas. *Neurosurg Rev* 32 (3): 321-34; discussion 334, 2009. [PubMed: 19221818]
5. Pica A, Miller R, Villà S, et al.: The results of surgery, with or without radiotherapy, for primary spinal myxopapillary ependymoma: a retrospective study from the rare cancer network. *Int J Radiat Oncol Biol Phys* 74 (4): 1114-20, 2009. [PubMed: 19250760]
6. Agbahiwe HC, Wharam M, Batra S, et al.: Management of pediatric myxopapillary ependymoma: the role of adjuvant radiation. *Int J Radiat Oncol Biol Phys* 85 (2): 421-7, 2013. [PMC free article: PMC4613753] [PubMed: 22713833]
7. Jeibmann A, Egensperger R, Kuchelmeister K, et al.: Extent of surgical resection but not myxopapillary versus classical histopathological subtype affects prognosis in lumbo-sacral ependymomas. *Histopathology* 54 (2): 260-2, 2009. [PubMed: 19207953]

Treatment of Childhood Ependymoma, Anaplastic Ependymoma, or *RELA* Fusion–Positive Ependymoma

Standard treatment options for newly diagnosed childhood ependymoma (World Health Organization [WHO] grade II), anaplastic ependymoma (WHO grade III), or *RELA* fusion–positive ependymoma (WHO grade II or grade III) include the following:

1. Surgery.
2. Adjuvant therapy.
 - Treatment of no residual disease, no disseminated disease.
 - Treatment of residual disease, no disseminated disease.
 - Treatment of central nervous system (CNS) disseminated disease.
 - Treatment of children younger than 1 year.

Typically, all patients undergo surgery to remove the tumor. Whether additional treatment is given depends on the extent of tumor resection and whether there is disseminated disease.

Surgery

Surgery is performed in an attempt at maximal tumor reduction. Evidence suggests that more extensive surgical resection is related to an improved rate of survival.[1-5]; [6,7][Level of evidence: 3iDii] Magnetic resonance imaging (MRI) is performed postoperatively to confirm the extent of resection. If not obtained preoperatively, MRI of the

entire neuraxis to evaluate disease dissemination and cerebrospinal fluid cytopathology is performed.

Patients across all molecular subgroups who have residual tumor or disseminated disease should be considered at high risk of relapse and may be treated on clinical trials specifically designed for them. Patients with no evidence of residual tumor still have an approximate 20% to 40% relapse risk despite postoperative radiation therapy.[8][Level of Evidence: 2Di]

Anecdotal experience suggests that surgery alone for completely resected supratentorial nonanaplastic tumors and intradural spinal cord ependymomas may, in select cases, be an appropriate approach to treatment.[9,10][Level of evidence: 3iiiDi]; [11-13][Level of evidence: 3iiiDiii]

Evidence (surgery):

1. In a prospective multi-institutional cooperative group trial (Children's Oncology Group [COG] ACNS0121 [NCT00027846]) for patients with newly diagnosed intracranial ependymomas (N = 356), surgery alone was used for the treatment of supratentorial, nonanaplastic, gross-totally resected ependymomas (n = 11).[8][Level of evidence: 2Di and 2A]
 - The 5-year event-free survival (EFS) rate was 61.4%, and the overall survival (OS) rate was 100%.
 - Local failure occurred in four patients (36%), and local and distant failure occurred in one patient (9%).
 - In this study, the number of patients eligible for a surgery-alone approach was very small; only a subset of these patients successfully avoided additional treatment.

Retrospective analysis of the outcome for patients with posterior fossa ependymoma suggests that these patients might be sufficiently treated with gross-total resection alone,[7] but this approach has not been tested in a prospective randomized clinical trial.

Adjuvant Therapy

Treatment of no residual disease, no disseminated disease

Radiation therapy

The standard postsurgical treatment for these patients has been radiation therapy consisting of 54 Gy to 59.4 Gy to the tumor bed for children aged 3 years and older.[5,14] The ACNS0121 (NCT00027846) study extended the use of radiation therapy (54 Gy) to patients as young as 1 year, resulting in similar EFS and OS rates when compared with children older than 3 years.[8][Level of Evidence: 2Di] It is not necessary to treat the entire CNS (whole brain and spine) because these tumors usually recur initially at the local site, although posterior fossa ependymomas may disseminate at recurrence, particularly in tumors with 1q gain.[15]; [16][Level of evidence: 3iiiA]

When possible, patients should be treated in a center experienced with the delivery of highly conformal radiation therapy (including intensity-modulated radiation therapy or charged-particle radiation therapy [e.g., proton radiation therapy]) to pediatric patients with brain tumors.

Evidence (radiation therapy):

1. In one single-institution study, 74 patients aged 1 to 21 years were treated with conformal radiation therapy immediately after surgery.[17]
 - The 3-year progression-free survival (PFS) rate was 77.6% (\pm 5.8%).
2. In an expansion of the above series, 107 of 153 patients received conformal radiation therapy immediately after up-front resection.[5][Level of evidence: 3iA]

- The 7-year EFS was 76.9% (\pm 13.5%).
3. A COG prospective study (ACNS0121 [NCT00027846]) enrolled 356 patients between the ages of 1 and 21 years with newly diagnosed ependymoma into four strata.[8][Level of Evidence: 2Di]
- a. Stratum 1: Patients with completely resected differentiated histology supratentorial ependymomas who were treated without radiation therapy.
 - The 5-year PFS rate was 61.4% (95% confidence interval [CI], 34.5%–89.6%), with no deaths at 7 years, although only 11 patients were enrolled in this stratum.
 - b. Stratum 2: Patients with subtotally resected ependymomas (both supratentorial and infratentorial) with more than 5 mm residual disease. Treatment consisted of two cycles of chemotherapy followed by second-look surgery and conformal radiation therapy to the tumor bed (adding a 1-cm target clinical volume). Radiation doses were 54 Gy for patients aged 12 to 18 months and 59.4 Gy for patients older than 18 months.
 - The 5-year PFS rate was 25% for patients in whom a second surgery was not feasible, and 50% for patients in whom a second surgery resulted in a gross-total resection.
 - c. Stratum 3 and stratum 4: Patients with near-total resection (stratum 3) and gross-total resection (stratum 4). Patients aged 12 to 18 months received postoperative radiation therapy doses of 54 Gy, and patients older than 18 months received doses of 59.4 Gy (adding a 1-cm target clinical volume).
 - The 5-year PFS rate was 68.5% (range, 62.8%–74.2%).
 - Posterior fossa A ependymoma (PF-EPN-A), 1q balanced (without 1q gain): the 5-year PFS rate was 81.5% (range, 71.5%–91.5%).
 - PF-EPN-A, 1q gain: the 5-year PFS rate was 35.7% (range, 12.8%–58.6%).
 - For patients with PF-EPN-A, distant failure was more common in patients with 1q gain than in patients with 1q balanced (without 1q gain).
 - Supratentorial ependymomas: 30 of 39 patients with supratentorial ependymomas who were tested harbored fusions of *C11orf95-RELA*, 23 of whom were in stratum 3 and 4. There was no significant difference in survival; 5-year OS rates exceeded 80%.
4. Proton-beam radiation therapy (a type of charged-particle radiation therapy) provides a possible advantage for targeting the tumor (supratentorial or infratentorial) while avoiding critical normal brain and neuroendocrine tissues.
- The 3-year PFS rate for children treated with proton-beam radiation therapy was 76% in two series and appears to be similar to the PFS rate for children treated with intensity-modulated photon-beam radiation therapy.[18-20]
 - In the two series that used proton-beam radiation therapy, the 3-year local control rates were 83% to 85%, with OS rates of 90% to 95%.[18,19]

Concerns about brain stem toxicity in very young children (aged <3 years) after proton therapy to the posterior fossa have prompted the use of more conservative doses in these children at some centers.[18,20,21]

Chemotherapy

There is no evidence that adjuvant chemotherapy, including the use of myeloablative chemotherapy,[22] improves the outcome for patients with totally resected, nondisseminated ependymoma. For this reason, current treatment

approaches do not include chemotherapy as a standard component of primary therapy for children with newly diagnosed ependymomas that are completely resected.

Treatment of residual disease, no disseminated disease

Second-look surgery

Second-look surgery should be considered because patients who have complete resections followed by irradiation have better disease control.[23] In some cases, further surgery can be undertaken after the initial attempted resection if the pediatric neurosurgeon believes that a gross-total resection could be obtained by an alternate surgical approach to the tumor. In other cases, further up-front surgery is not anticipated to result in a gross-total resection; therefore, adjuvant therapy is initiated with future consideration of second-look surgery.[8]

Radiation therapy

The rationale for radiation therapy, as described in the Treatment of no residual disease, no disseminated disease subsection above, also pertains to the treatment of children with residual, nondisseminated ependymoma. In patients with a subtotal resection, treatment with radiation therapy results in a 5-year PFS rate of 25%, and outcome is particularly poor in PF-EPN-A patients,[8] although the outcome for patients with residual tumor within the spinal canal may be better.[24]

Preirradiation chemotherapy

The rationale for using chemotherapy in patients with residual tumor is to attempt to achieve a state of no evidence of disease before the patients undergo radiation therapy, either by achieving a complete response (CR) to chemotherapy alone or by facilitating the likelihood of a gross-total resection at the time of second-look surgery after chemotherapy. The benefit of chemotherapy for residual tumor after up-front surgery is still being investigated.

Evidence (preirradiation chemotherapy with or without surgery):

1. One study demonstrated a benefit of preirradiation chemotherapy in children with near-total resection (>90% resection), with outcomes similar to those for children achieving a gross-total resection followed by radiation therapy.[25]
2. The COG ACNS0121 (NCT00027846) trial included two cycles of preirradiation chemotherapy for children with residual disease after up-front surgery (n = 64).[8][Level of evidence: 2Di]
 - Second-look surgery occurred in 39% of patients (n = 25) (gross-total resection, 56%; near-total resection, 20%; subtotal resection, 24%).
 - For patients who underwent second-look surgery, the 5-year EFS was 50.5%, compared with an EFS of 28.5% for patients who did not undergo second surgery.
3. A multi-institutional trial for children younger than 3 years used preirradiation chemotherapy, followed by conformal radiation once the child was older than 12 months, followed by maintenance chemotherapy. [26][Level of evidence: 2Diii]
 - Fifty-four patients were enrolled, and 54% of patients (n = 29) underwent a gross-total resection at diagnosis.
 - Of the remaining 25 patients, 60% (n = 15) underwent a second-look surgery after chemotherapy, with 80% of patients achieving a gross-total resection.
 - At the time of radiation therapy, 76% of patients had a gross-total resection, 13% of patients had a near-total resection, and 11% of patients had a subtotal resection.

- PFS (but not OS) was better for patients who underwent a gross-total resection or near-total resection before radiation therapy than it was for patients who underwent a subtotal resection (4-year PFS, 79% for gross-total resection/near-total resection vs. 41.7% for subtotal resection).

There is no evidence that high-dose chemotherapy with stem cell rescue is of any benefit.[27]; [28][Level of evidence: 2A]

Treatment of CNS disseminated disease

Radiation therapy

Regardless of the degree of surgical resection, these patients generally receive radiation therapy to the whole brain and spine, along with boosts to local disease and bulk areas of disseminated disease. The traditional local postsurgical radiation doses in these patients have been 54 Gy to 55.8 Gy. Doses of approximately 36 Gy to the entire neuraxis (i.e., the whole brain and spine) are also administered but may be modulated depending on the age of the patient.[29] Boosts between 41.4 Gy and 50.4 Gy to bulk areas of spinal disease are administered, with doses depending on the age of the patient and the location of the tumor. However, there are no contemporary studies published to support this approach.

Chemotherapy

While chemotherapy is often utilized because of some degree of chemoresponsiveness, evidence demonstrating improvement in EFS and OS is lacking.[30]

Treatment of children younger than 1 year

Chemotherapy

Some, but not all, chemotherapy regimens induce objective responses in children younger than 3 years with newly diagnosed ependymoma.[31-34] The goal of chemotherapy is to avoid radiation, defer radiation until the child is older, or achieve a state of no evidence of disease before undergoing radiation therapy (either by a CR to chemotherapy or by a gross-total resection at time of second-look surgery after chemotherapy). Up to 25% of infants and young children with totally resected disease may achieve long-term survival. These studies have not been molecularly characterized and it is unclear which patients may benefit from chemotherapy-only regimens. Survivors of chemotherapy-only protocols may eventually receive salvage radiation therapy.[35]; [36][Level of evidence: 2Di]

Deferred radiation therapy

Historically, postoperative radiation therapy was omitted for children younger than 3 years with ependymoma. Two COG studies (POG-9233 and ACNS0121 [NCT00027846]) and many subsequent trials have lowered the age limit for postoperative radiation therapy to age 1 year in an effort to improve outcomes for these younger children. The ACNS0121 trial has shown that conformal radiation in children with completely resected tumors resulted in significantly improved outcomes compared with patients who received chemotherapy alone.[8][Level of evidence: 2Di]

It is unclear which patients can benefit from radiation-sparing approaches; however, comparison of results of the POG-9233 trial with the results of the ACNS0121 (NCT00027846) trial suggests a 50% to 60% improvement in survival for patients who were treated with radiation therapy.[8,35] A prospective evaluation of molecular markers may identify the infants who can be safely treated with radiation-sparing approaches and/or patients who may benefit from chemotherapy.

Evidence (radiation therapy):

1. Retrospective reviews based on Surveillance, Epidemiology, and End Results Program data from children younger than 3 years at diagnosis were accrued over a 50-year period.[37]
 - Results showed that patients who received local radiation therapy had better 10-year survival rates, even after adjusting for the extent of resection and tumor grade (WHO grade II vs. grade III).
2. A large retrospective study, across 820 molecularly characterized posterior fossa ependymomas, demonstrated that adjuvant first-line radiation therapy, along with complete resection and ependymoma posterior fossa B subgroup, was associated with an improved prognosis. Radiation-sparing approaches were associated with dismal outcomes in children with PF-EPN-A tumors.[7]
3. Conformal or charged-particle (e.g., proton) radiation therapy is an alternative approach for minimizing radiation-induced neurologic damage in young children with ependymoma. The need and timing of radiation therapy for children who have successfully completed chemotherapy and have no residual disease is still to be determined.
 - The initial experience with this approach suggested that children younger than 3 years with ependymoma have neurologic deficits at diagnosis that improve with time after conformal radiation treatment.[17]
 - Another study suggested that there was a trend for intellectual deterioration over time, even in older children treated with localized radiation therapy.[38]; [39][Level of evidence: 3iiiC]
4. The COG ACNS0121 (NCT00027846) study showed that children aged 1 year to younger than 3 years who underwent a gross-total resection or near-total resection followed by immediate postoperative radiation therapy had the following results:[8][Level of evidence: 2Di and 2A]
 - The 5-year EFS rate was 62.9%, and the OS rate was 87.4%.
 - These results were not statistically different from the results seen in patients aged 3 to 21 years, who had a 5-year EFS rate of 70.5% and an OS rate of 85.8%.
5. A multi-institutional trial of children younger than 3 years with newly diagnosed ependymomas (n = 54) who received four to six cycles of chemotherapy followed by radiation therapy (once they had reached the age of 12 months) resulted in the following:[26][Level of evidence: 2Diii and 2A]
 - The 4-year PFS rate was 75.1%, and the OS rate was 92.6%.
 - These results were comparable to the results seen in studies that treated children older than 3 years.
 - Of interest, there was no difference in outcomes between infants younger than 1 year and children aged 1 to 3 years at diagnosis.

Conformal radiation approaches, including 3-dimensional conformal radiation therapy that minimizes damage to normal brain tissue and charged-particle radiation therapy, such as proton-beam therapy, are under evaluation for infants and children with ependymoma.[17,40] When analyzing neurologic outcomes after treatment of young children with ependymoma, it is important to consider that not all long-term deficits can be ascribed to radiation therapy because deficits may be present in young children before therapy begins.[17] For example, the presence of hydrocephalus at diagnosis is associated with a lower intelligence quotient, as measured after surgical resection and before administration of radiation therapy.[41]

Treatment Options Under Clinical Evaluation for Childhood Ependymoma or Anaplastic Ependymoma

Early-phase therapeutic trials may be available for selected patients. These trials may be available via the [COG](#), the [Pediatric Brain Tumor Consortium](#), or other entities. Information about National Cancer Institute (NCI)-supported

clinical trials can be found on the [NCI website](#). For information about clinical trials sponsored by other organizations, refer to the [ClinicalTrials.gov website](#).

Current Clinical Trials

Use our advanced clinical trial search to find NCI-supported cancer clinical trials that are now enrolling patients. The search can be narrowed by location of the trial, type of treatment, name of the drug, and other criteria. [General information](#) about clinical trials is also available.

References

1. van Veelen-Vincent ML, Pierre-Kahn A, Kalifa C, et al.: Ependymoma in childhood: prognostic factors, extent of surgery, and adjuvant therapy. *J Neurosurg* 97 (4): 827-35, 2002. [PubMed: 12405370]
2. Abdel-Wahab M, Etuk B, Palermo J, et al.: Spinal cord gliomas: A multi-institutional retrospective analysis. *Int J Radiat Oncol Biol Phys* 64 (4): 1060-71, 2006. [PubMed: 16373081]
3. Kothbauer KF: Neurosurgical management of intramedullary spinal cord tumors in children. *Pediatr Neurosurg* 43 (3): 222-35, 2007. [PubMed: 17409792]
4. Zacharoulis S, Ji L, Pollack IF, et al.: Metastatic ependymoma: a multi-institutional retrospective analysis of prognostic factors. *Pediatr Blood Cancer* 50 (2): 231-5, 2008. [PubMed: 17610266]
5. Merchant TE, Li C, Xiong X, et al.: Conformal radiotherapy after surgery for paediatric ependymoma: a prospective study. *Lancet Oncol* 10 (3): 258-66, 2009. [PMC free article: PMC3615425] [PubMed: 19274783]
6. Cage TA, Clark AJ, Aranda D, et al.: A systematic review of treatment outcomes in pediatric patients with intracranial ependymomas. *J Neurosurg Pediatr* 11 (6): 673-81, 2013. [PubMed: 23540528]
7. Ramaswamy V, Hielscher T, Mack SC, et al.: Therapeutic Impact of Cytoreductive Surgery and Irradiation of Posterior Fossa Ependymoma in the Molecular Era: A Retrospective Multicohort Analysis. *J Clin Oncol* 34 (21): 2468-77, 2016. [PMC free article: PMC4962737] [PubMed: 27269943]
8. Merchant TE, Bendel AE, Sabin ND, et al.: Conformal Radiation Therapy for Pediatric Ependymoma, Chemotherapy for Incompletely Resected Ependymoma, and Observation for Completely Resected, Supratentorial Ependymoma. *J Clin Oncol* 37 (12): 974-983, 2019. [PubMed: 30811284]
9. Volpp PB, Han K, Kagan AR, et al.: Outcomes in treatment for intradural spinal cord ependymomas. *Int J Radiat Oncol Biol Phys* 69 (4): 1199-204, 2007. [PubMed: 17689025]
10. Hukin J, Epstein F, Lefton D, et al.: Treatment of intracranial ependymoma by surgery alone. *Pediatr Neurosurg* 29 (1): 40-5, 1998. [PubMed: 9755311]
11. Little AS, Sheean T, Manoharan R, et al.: The management of completely resected childhood intracranial ependymoma: the argument for observation only. *Childs Nerv Syst* 25 (3): 281-4, 2009. [PubMed: 19153750]
12. Venkatramani R, Dhall G, Patel M, et al.: Supratentorial ependymoma in children: to observe or to treat following gross total resection? *Pediatr Blood Cancer* 58 (3): 380-3, 2012. [PubMed: 21370439]
13. Ghia AJ, Mahajan A, Allen PK, et al.: Supratentorial gross-totally resected non-anaplastic ependymoma: population based patterns of care and outcomes analysis. *J Neurooncol* 115 (3): 513-20, 2013. [PubMed: 24085643]
14. Koshy M, Rich S, Merchant TE, et al.: Post-operative radiation improves survival in children younger than 3 years with intracranial ependymoma. *J Neurooncol* 105 (3): 583-90, 2011. [PubMed: 21637963]
15. Combs SE, Kelter V, Welzel T, et al.: Influence of radiotherapy treatment concept on the outcome of patients with localized ependymomas. *Int J Radiat Oncol Biol Phys* 71 (4): 972-8, 2008. [PubMed: 18337022]
16. Schroeder TM, Chintagumpala M, Okcu MF, et al.: Intensity-modulated radiation therapy in childhood ependymoma. *Int J Radiat Oncol Biol Phys* 71 (4): 987-93, 2008. [PubMed: 18258381]
17. Merchant TE, Mulhern RK, Krasin MJ, et al.: Preliminary results from a phase II trial of conformal radiation therapy and evaluation of radiation-related CNS effects for pediatric patients with localized ependymoma. *J Clin Oncol* 22 (15): 3156-62, 2004. [PubMed: 15284268]

18. Indelicato DJ, Bradley JA, Rotondo RL, et al.: Outcomes following proton therapy for pediatric ependymoma. *Acta Oncol* 57 (5): 644-648, 2018. [PubMed: 29239262]
19. Macdonald SM, Sethi R, Lavally B, et al.: Proton radiotherapy for pediatric central nervous system ependymoma: clinical outcomes for 70 patients. *Neuro Oncol* 15 (11): 1552-9, 2013. [PMC free article: PMC3813421] [PubMed: 24101739]
20. Sato M, Gunther JR, Mahajan A, et al.: Progression-free survival of children with localized ependymoma treated with intensity-modulated radiation therapy or proton-beam radiation therapy. *Cancer* 123 (13): 2570-2578, 2017. [PubMed: 28267208]
21. Indelicato DJ, Flampouri S, Rotondo RL, et al.: Incidence and dosimetric parameters of pediatric brainstem toxicity following proton therapy. *Acta Oncol* 53 (10): 1298-304, 2014. [PubMed: 25279957]
22. Zacharoulis S, Levy A, Chi SN, et al.: Outcome for young children newly diagnosed with ependymoma, treated with intensive induction chemotherapy followed by myeloablative chemotherapy and autologous stem cell rescue. *Pediatr Blood Cancer* 49 (1): 34-40, 2007. [PubMed: 16874765]
23. Massimino M, Solero CL, Garrè ML, et al.: Second-look surgery for ependymoma: the Italian experience. *J Neurosurg Pediatr* 8 (3): 246-50, 2011. [PubMed: 21882914]
24. Wahab SH, Simpson JR, Michalski JM, et al.: Long term outcome with post-operative radiation therapy for spinal canal ependymoma. *J Neurooncol* 83 (1): 85-9, 2007. [PubMed: 17206474]
25. Garvin JH, Selch MT, Holmes E, et al.: Phase II study of pre-irradiation chemotherapy for childhood intracranial ependymoma. Children's Cancer Group protocol 9942: a report from the Children's Oncology Group. *Pediatr Blood Cancer* 59 (7): 1183-9, 2012. [PubMed: 22949057]
26. Upadhyaya SA, Robinson GW, Onar-Thomas A, et al.: Molecular grouping and outcomes of young children with newly diagnosed ependymoma treated on the multi-institutional SJYC07 trial. *Neuro Oncol* 21 (10): 1319-1330, 2019. [PMC free article: PMC6784269] [PubMed: 30976811]
27. Grill J, Kalifa C, Doz F, et al.: A high-dose busulfan-thiotepa combination followed by autologous bone marrow transplantation in childhood recurrent ependymoma. A phase-II study. *Pediatr Neurosurg* 25 (1): 7-12, 1996. [PubMed: 9055328]
28. Venkatramani R, Ji L, Lasky J, et al.: Outcome of infants and young children with newly diagnosed ependymoma treated on the "Head Start" III prospective clinical trial. *J Neurooncol* 113 (2): 285-91, 2013. [PMC free article: PMC4119804] [PubMed: 23508296]
29. Merchant TE, Boop FA, Kun LE, et al.: A retrospective study of surgery and reirradiation for recurrent ependymoma. *Int J Radiat Oncol Biol Phys* 71 (1): 87-97, 2008. [PubMed: 18406885]
30. Bouffet E, Capra M, Bartels U: Salvage chemotherapy for metastatic and recurrent ependymoma of childhood. *Childs Nerv Syst* 25 (10): 1293-301, 2009. [PubMed: 19360417]
31. Duffner PK, Horowitz ME, Krischer JP, et al.: The treatment of malignant brain tumors in infants and very young children: an update of the Pediatric Oncology Group experience. *Neuro-oncol* 1 (2): 152-61, 1999. [PMC free article: PMC1920752] [PubMed: 11554387]
32. Duffner PK, Horowitz ME, Krischer JP, et al.: Postoperative chemotherapy and delayed radiation in children less than three years of age with malignant brain tumors. *N Engl J Med* 328 (24): 1725-31, 1993. [PubMed: 8388548]
33. Geyer JR, Sposto R, Jennings M, et al.: Multiagent chemotherapy and deferred radiotherapy in infants with malignant brain tumors: a report from the Children's Cancer Group. *J Clin Oncol* 23 (30): 7621-31, 2005. [PubMed: 16234523]
34. Grill J, Le Deley MC, Gambarelli D, et al.: Postoperative chemotherapy without irradiation for ependymoma in children under 5 years of age: a multicenter trial of the French Society of Pediatric Oncology. *J Clin Oncol* 19 (5): 1288-96, 2001. [PubMed: 11230470]
35. Strother DR, Lafay-Cousin L, Boyett JM, et al.: Benefit from prolonged dose-intensive chemotherapy for infants with malignant brain tumors is restricted to patients with ependymoma: a report of the Pediatric Oncology Group randomized controlled trial 9233/34. *Neuro Oncol* 16 (3): 457-65, 2014. [PMC free article:

PMC3922508] [PubMed: 24335695]

36. Grundy RG, Wilne SA, Weston CL, et al.: Primary postoperative chemotherapy without radiotherapy for intracranial ependymoma in children: the UKCCSG/SIOP prospective study. *Lancet Oncol* 8 (8): 696-705, 2007. [PubMed: 17644039]
37. Snider CA, Yang K, Mack SC, et al.: Impact of radiation therapy and extent of resection for ependymoma in young children: A population-based study. *Pediatr Blood Cancer* 65 (3): , 2018. [PubMed: 29115718]
38. Zapotocky M, Beera K, Adamski J, et al.: Survival and functional outcomes of molecularly defined childhood posterior fossa ependymoma: Cure at a cost. *Cancer* 125 (11): 1867-1876, 2019. [PMC free article: PMC6508980] [PubMed: 30768777]
39. von Hoff K, Kieffer V, Habrand JL, et al.: Impairment of intellectual functions after surgery and posterior fossa irradiation in children with ependymoma is related to age and neurologic complications. *BMC Cancer* 8: 15, 2008. [PMC free article: PMC2254428] [PubMed: 18208613]
40. MacDonald SM, Safai S, Trofimov A, et al.: Proton radiotherapy for childhood ependymoma: initial clinical outcomes and dose comparisons. *Int J Radiat Oncol Biol Phys* 71 (4): 979-86, 2008. [PubMed: 18325681]
41. Merchant TE, Lee H, Zhu J, et al.: The effects of hydrocephalus on intelligence quotient in children with localized infratentorial ependymoma before and after focal radiation therapy. *J Neurosurg* 101 (2 Suppl): 159-68, 2004. [PubMed: 15835103]

Treatment of Recurrent Childhood Ependymoma

Recurrence is not uncommon for all grades of ependymoma and may develop many years after initial treatment.[1] Late recurrence beyond 10 to 15 years has been reported.[2] Disease generally recurs at the primary tumor site, although concomitant neuraxis dissemination may also be seen. Systemic relapse is extremely rare.

At the time of relapse, a complete evaluation for the extent of recurrence is indicated for all patients.

Treatment options for recurrent childhood ependymoma include the following:

1. Surgery.
2. Radiation therapy and/or chemotherapy.

Surgery

The utility of further surgical intervention is individualized, based on the extent and location of the tumor.

In some cases, surgically accessible lesions may be treated alternatively with radiation therapy.

Radiation Therapy and/or Chemotherapy

Patients with recurrent ependymomas should be considered for treatment with the following modalities:[3][Level of evidence: 3iiiB]

1. Focal retreatment with various radiation modalities, including stereotactic radiosurgery,[4,5][Level of evidence: 3iiiA]; [6,7][Level of evidence: 3iiiDi] intensity-modulated photon therapy, and proton therapy.[8]; [9][Level of evidence: 3iiiB]

Craniospinal irradiation for both local and distant (spinal) recurrence should be considered. A study of 101 reirradiated patients conducted at St. Jude Children's Research Hospital showed that the median durations of overall survival (OS) and freedom from progression were 75.1 months and 27.3 months, respectively. The 1-, 2-, and 5-year estimates of OS were 95.5%, 74.9%, and 57.3%, respectively.[8][Level of evidence:3iiiDiii]

- Among the 46 patients who received focal reirradiation for local failure, there were 13 local failures and 11 distant-only failures.

- Among the ten patients who received craniospinal irradiation for local failure, there were six local failures and no distant-only failures.
- Distant-only failure treated with craniospinal irradiation was independently associated with improved OS compared with individuals with local failure treated with focal radiation therapy (hazard ratio [HR], 0.37; 95% confidence interval [CI], 0.16–0.87).
- The 10-year cumulative incidence of grade greater than 3 radiation necrosis after repeat radiation therapy was 7.9%.
- Gain of chromosome 1q was adversely associated with poorer OS (HR, 3.5; 95% CI, 1.1–10.6) for patients with distant failure (but not local failure) after initial radiation therapy. Other variables associated with reduced OS and freedom from progression included male sex, anaplastic histology at recurrence, and a short interval from initial radiation therapy to recurrence.

Three, and even four, courses of radiation therapy for recurrence can prolong survival with acceptable toxicity. [8][Level of evidence:3iiiDiii]

2. Active anticancer agents, including cyclophosphamide, cisplatin, carboplatin, lomustine, and etoposide, have been utilized in the recurrence setting. While older single-agent studies have demonstrated chemoresponsiveness with these agents, response is rarely durable. [10,11]

Regardless of treatment strategy, the prognosis for patients with recurrence is poor. [1] Entry into studies of novel therapeutic approaches should be considered.

Treatment Options Under Clinical Evaluation for Recurrent Childhood Ependymoma

Early-phase therapeutic trials may be available for selected patients. These trials may be available via the [Children's Oncology Group \(COG\)](#), the [Pediatric Brain Tumor Consortium](#), or other entities. Information about National Cancer Institute (NCI)–supported clinical trials can be found on the [NCI website](#). For information about clinical trials sponsored by other organizations, refer to the [ClinicalTrials.gov website](#).

The following is an example of a national and/or institutional clinical trial that is currently being conducted:

- **APEC1621 (NCT03155620)** (Pediatric MATCH: Targeted Therapy Directed by Genetic Testing in Treating Pediatric Patients with Relapsed or Refractory Advanced Solid Tumors, Non-Hodgkin Lymphomas, or Histiocytic Disorders): NCI-COG Pediatric Molecular Analysis for Therapeutic Choice (MATCH), referred to as Pediatric MATCH, will match targeted agents with specific molecular changes identified using a next-generation sequencing targeted assay of more than 4,000 different mutations across more than 160 genes in refractory and recurrent solid tumors. Children and adolescents aged 1 to 21 years are eligible for the trial.

Tumor tissue from progressive or recurrent disease must be available for molecular characterization. Patients with tumors that have molecular variants addressed by treatment arms included in the trial will be offered treatment on Pediatric MATCH. Additional information can be obtained on the [NCI website](#) and [ClinicalTrials.gov website](#).

- **NCT02125786** (A Trial of Surgery and Fractionated Re-Irradiation for Recurrent Ependymoma): The primary purpose of this study is to investigate whether surgery and reirradiation will help treat ependymoma that has come back after initial treatment. The combined doses of the first and second courses of radiation are higher than what is the usual standard of care. The investigators will study the effects and side effects of surgery and reirradiation. They will also evaluate and study tumor tissue and blood to learn more about the tumor and how it does or does not respond to treatments and will use magnetic resonance imaging and positron emission tomography scans to see if they can predict tumor response and tumor recurrence.

Current Clinical Trials

Use our advanced clinical trial search to find NCI-supported cancer clinical trials that are now enrolling patients. The search can be narrowed by location of the trial, type of treatment, name of the drug, and other criteria. [General information about clinical trials](#) is also available.

References

1. Zacharoulis S, Ashley S, Moreno L, et al.: Treatment and outcome of children with relapsed ependymoma: a multi-institutional retrospective analysis. *Childs Nerv Syst* 26 (7): 905-11, 2010. [PubMed: 20039045]
2. Wu J, Armstrong TS, Gilbert MR: Biology and management of ependymomas. *Neuro Oncol* 18 (7): 902-13, 2016. [PMC free article: PMC4896548] [PubMed: 27022130]
3. Messahel B, Ashley S, Saran F, et al.: Relapsed intracranial ependymoma in children in the UK: patterns of relapse, survival and therapeutic outcome. *Eur J Cancer* 45 (10): 1815-23, 2009. [PubMed: 19427780]
4. Kano H, Yang HC, Kondziolka D, et al.: Stereotactic radiosurgery for pediatric recurrent intracranial ependymomas. *J Neurosurg Pediatr* 6 (5): 417-23, 2010. [PubMed: 21039163]
5. Bouffet E, Hawkins CE, Ballourah W, et al.: Survival benefit for pediatric patients with recurrent ependymoma treated with reirradiation. *Int J Radiat Oncol Biol Phys* 83 (5): 1541-8, 2012. [PubMed: 22245198]
6. Merchant TE, Boop FA, Kun LE, et al.: A retrospective study of surgery and reirradiation for recurrent ependymoma. *Int J Radiat Oncol Biol Phys* 71 (1): 87-97, 2008. [PubMed: 18406885]
7. Kano H, Niranjan A, Kondziolka D, et al.: Outcome predictors for intracranial ependymoma radiosurgery. *Neurosurgery* 64 (2): 279-87; discussion 287-8, 2009. [PubMed: 19190457]
8. Tsang DS, Burghen E, Klimo P, et al.: Outcomes After Reirradiation for Recurrent Pediatric Intracranial Ependymoma. *Int J Radiat Oncol Biol Phys* 100 (2): 507-515, 2018. [PubMed: 29229328]
9. Eaton BR, Chowdhry V, Weaver K, et al.: Use of proton therapy for re-irradiation in pediatric intracranial ependymoma. *Radiother Oncol* 116 (2): 301-8, 2015. [PubMed: 26243681]
10. Bouffet E, Capra M, Bartels U: Salvage chemotherapy for metastatic and recurrent ependymoma of childhood. *Childs Nerv Syst* 25 (10): 1293-301, 2009. [PubMed: 19360417]
11. Jakacki RI, Foley MA, Horan J, et al.: Single-agent erlotinib versus oral etoposide in patients with recurrent or refractory pediatric ependymoma: a randomized open-label study. *J Neurooncol* 129 (1): 131-8, 2016. [PubMed: 27287856]

Changes to This Summary (03/20/2020)

The PDQ cancer information summaries are reviewed regularly and updated as new information becomes available. This section describes the latest changes made to this summary as of the date above.

Treatment of Childhood Ependymoma, Anaplastic Ependymoma, or RELA Fusion–Positive Ependymoma

Added text to state that while chemotherapy is often utilized because of some degree of chemoresponsiveness, evidence demonstrating improvement in event-free survival and overall survival is lacking.

Added text about a large retrospective study, across 820 molecularly characterized posterior fossa ependymomas, that demonstrated that adjuvant first-line radiation therapy, along with complete resection and ependymoma posterior fossa B subgroup, was associated with an improved prognosis.

Treatment of Recurrent Childhood Ependymoma

The [Radiation Therapy and/or Chemotherapy](#) subsection was extensively revised.

Added text about the clinical trial, [A Trial of Surgery and Fractionated Reirradiation for Recurrent Ependymoma](#) that is currently evaluating surgery and reirradiation as a treatment for recurrent childhood ependymoma.

This summary is written and maintained by the [PDQ Pediatric Treatment Editorial Board](#), which is editorially independent of NCI. The summary reflects an independent review of the literature and does not represent a policy statement of NCI or NIH. More information about summary policies and the role of the PDQ Editorial Boards in maintaining the PDQ summaries can be found on the [About This PDQ Summary and PDQ® - NCI's Comprehensive Cancer Database](#) pages.

About This PDQ Summary

Purpose of This Summary

This PDQ cancer information summary for health professionals provides comprehensive, peer-reviewed, evidence-based information about the treatment of childhood ependymoma. It is intended as a resource to inform and assist clinicians who care for cancer patients. It does not provide formal guidelines or recommendations for making health care decisions.

Reviewers and Updates

This summary is reviewed regularly and updated as necessary by the [PDQ Pediatric Treatment Editorial Board](#), which is editorially independent of the National Cancer Institute (NCI). The summary reflects an independent review of the literature and does not represent a policy statement of NCI or the National Institutes of Health (NIH).

Board members review recently published articles each month to determine whether an article should:

- be discussed at a meeting,
- be cited with text, or
- replace or update an existing article that is already cited.

Changes to the summaries are made through a consensus process in which Board members evaluate the strength of the evidence in the published articles and determine how the article should be included in the summary.

The lead reviewers for Childhood Ependymoma Treatment are:

- Kenneth J. Cohen, MD, MBA (Sidney Kimmel Comprehensive Cancer Center at Johns Hopkins Hospital)
- Louis S. Constine, MD (James P. Wilmot Cancer Center at University of Rochester Medical Center)
- Roger J. Packer, MD (Children's National Health System)
- Malcolm A. Smith, MD, PhD (National Cancer Institute)

Any comments or questions about the summary content should be submitted to Cancer.gov through the NCI website's [Email Us](#). Do not contact the individual Board Members with questions or comments about the summaries. Board members will not respond to individual inquiries.

Levels of Evidence

Some of the reference citations in this summary are accompanied by a level-of-evidence designation. These designations are intended to help readers assess the strength of the evidence supporting the use of specific interventions or approaches. The PDQ Pediatric Treatment Editorial Board uses a [formal evidence ranking system](#) in developing its level-of-evidence designations.

Permission to Use This Summary

PDQ is a registered trademark. Although the content of PDQ documents can be used freely as text, it cannot be

identified as an NCI PDQ cancer information summary unless it is presented in its entirety and is regularly updated. However, an author would be permitted to write a sentence such as “NCI’s PDQ cancer information summary about breast cancer prevention states the risks succinctly: [include excerpt from the summary].”

The preferred citation for this PDQ summary is:

PDQ® Pediatric Treatment Editorial Board. PDQ Childhood Ependymoma Treatment. Bethesda, MD: National Cancer Institute. Updated <MM/DD/YYYY>. Available at: <https://www.cancer.gov/types/brain/hp/child-ependymoma-treatment-pdq>. Accessed <MM/DD/YYYY>. [PMID: 26389373]

Images in this summary are used with permission of the author(s), artist, and/or publisher for use within the PDQ summaries only. Permission to use images outside the context of PDQ information must be obtained from the owner(s) and cannot be granted by the National Cancer Institute. Information about using the illustrations in this summary, along with many other cancer-related images, is available in [Visuals Online](#), a collection of over 2,000 scientific images.

Disclaimer

Based on the strength of the available evidence, treatment options may be described as either “standard” or “under clinical evaluation.” These classifications should not be used as a basis for insurance reimbursement determinations. More information on insurance coverage is available on Cancer.gov on the [Managing Cancer Care](#) page.

Contact Us

More information about contacting us or receiving help with the Cancer.gov website can be found on our [Contact Us](#) for [Help](#) page. Questions can also be submitted to Cancer.gov through the website’s [Email Us](#).

Copyright Notice

Bookshelf ID: NBK65935 PMID: [26389373](#)