

NCBI Bookshelf. A service of the National Library of Medicine, National Institutes of Health.

PDQ Cancer Information Summaries [Internet]. Bethesda (MD): National Cancer Institute (US); 2002-.

Childhood Central Nervous System Germ Cell Tumors Treatment (PDQ®)

Health Professional Version

Authors

PDQ Pediatric Treatment Editorial Board.

Published online: August 7, 2020.

Created: December 14, 2011.

This PDQ cancer information summary for health professionals provides comprehensive, peer-reviewed, evidence-based information about the treatment of childhood central nervous system germ cell tumors. It is intended as a resource to inform and assist clinicians who care for cancer patients. It does not provide formal guidelines or recommendations for making health care decisions.

This summary is reviewed regularly and updated as necessary by the PDQ Pediatric Treatment Editorial Board, which is editorially independent of the National Cancer Institute (NCI). The summary reflects an independent review of the literature and does not represent a policy statement of NCI or the National Institutes of Health (NIH).

General Information About Childhood Central Nervous System (CNS) Germ Cell Tumors

Primary brain tumors, including germ cell tumors (GCTs), are a diverse group of diseases that together constitute the most common solid tumor of childhood. The most recent classification of CNS tumors implements molecular parameters for the first time, in addition to histology, to define brain tumor entities. This led to restructuring some CNS tumor types, such as embryonal tumors and gliomas; however, per this updated classification schema, no molecular parameters are used to classify intracranial GCTs. Tumor location and extent of disease (brain invasion and tumor spread) remain important factors that affect treatment and prognosis.

Primary CNS GCTs are a heterogeneous group of neoplasms that are more common in Japan and other Asian countries than in North America and Europe. In North America, they account for approximately 4% of all primary brain tumors, with a peak incidence from age 10 years to age 19 years and a male predominance in a pineal location.[1-3]

CNS GCTs are broadly classified as germinomatous and nongerminomatous germ cell tumors (NGGCTs) on the basis of clinicopathological and laboratory features, including tumor markers.[4,5] An alternative therapeutic classification in Japan distinguishes three groups on the basis of their prognostication: good prognosis (e.g., germinoma), intermediate prognosis (e.g., teratoma with malignant transformation), and poor prognosis (e.g., yolk sac tumor, choriocarcinoma, embryonal carcinoma, and mixed tumors of those entities).[4]

The PDQ childhood brain tumor treatment summaries are organized primarily according to the World Health Organization Classification of Tumors of the Central Nervous System.[4,5] For a full description of the classification of CNS tumors and a link to the corresponding treatment summary for each type of brain tumor, refer to the PDQ summary on [Childhood Brain and Spinal Cord Tumors Treatment Overview](#).

Incidence

In Western countries, GCTs represent 3% to 4% of primary brain tumors in children; however, series from Japan and Asia report the incidence of CNS GCTs as approximately 15% of pediatric CNS tumors.[3,6-8] The genetic or environmental reasons for these differences remain unknown.

Anatomy

CNS GCTs usually arise in the pineal and/or suprasellar regions of the brain, as solitary or multiple lesions (refer to Figure 1). The most common site of origin is the pineal region (45%), and the second most common site is the suprasellar region (30%) within the infundibulum or pituitary stalk. Both of these sites are considered *extra-axial* or *nonparenchymal* CNS locations. Approximately 5% to 10% of patients present with synchronous tumors arising in both the suprasellar and pineal locations, and the histology is most frequently a germinoma.[8] Males have a higher incidence of GCTs than do females, with males having a preponderance of pineal-region primary tumors. Other areas that may be involved, though rare, include the basal ganglia, ventricles, thalamus, cerebral hemispheres, and medulla. [9,10]

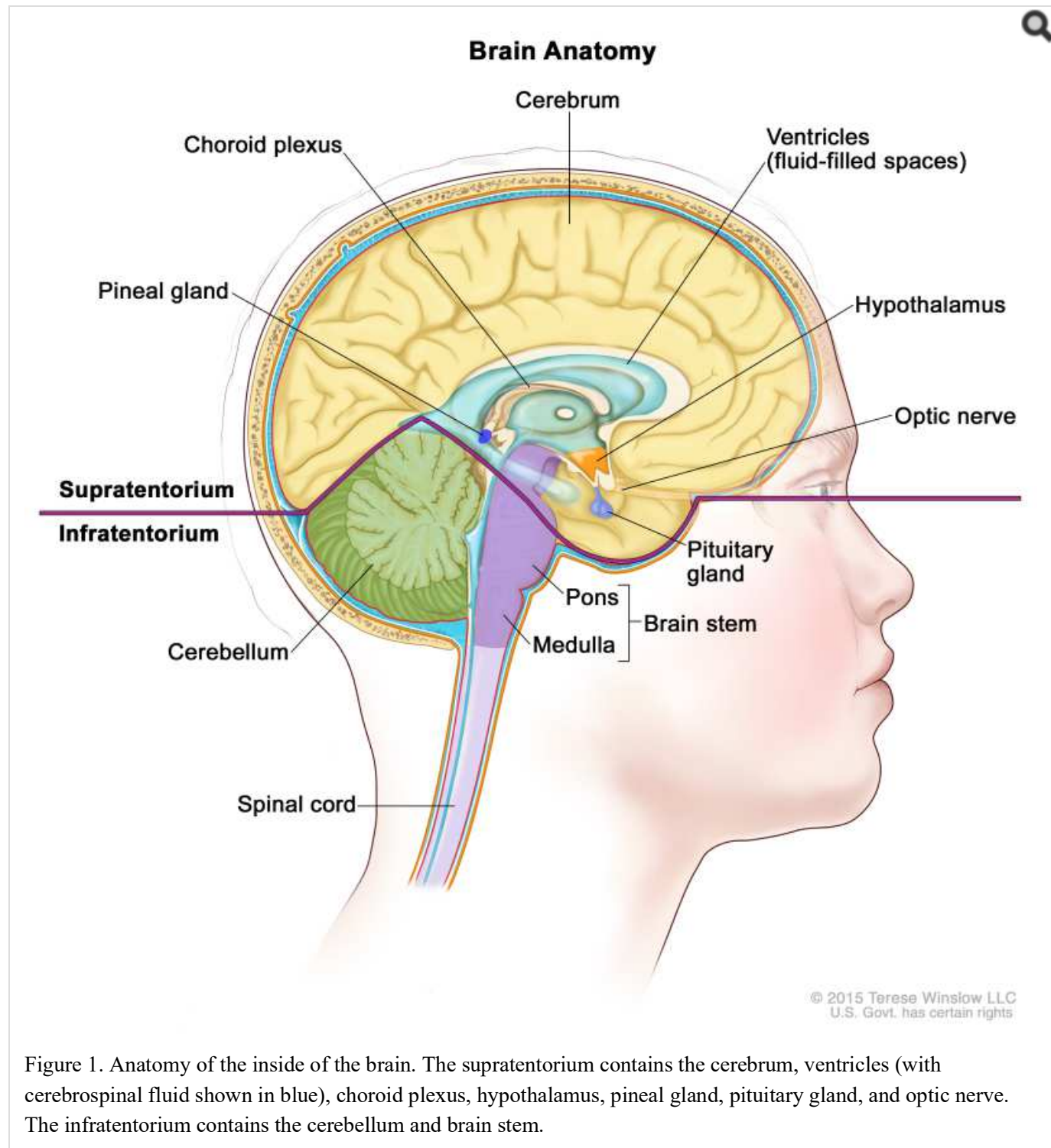


Figure 1. Anatomy of the inside of the brain. The supratentorium contains the cerebrum, ventricles (with cerebrospinal fluid shown in blue), choroid plexus, hypothalamus, pineal gland, pituitary gland, and optic nerve. The infratentorium contains the cerebellum and brain stem.

Molecular Features

In a study of 62 cases of intracranial GCTs, next-generation sequencing, single-nucleotide polymorphism array, and expression array showed frequent mutations in the KIT/RAS signaling pathway (50% of cases) and the AKT/mTOR pathway (19% of cases).[11]

To identify genes and specific pathways that may be involved in CNS tumorigenesis, tumors were profiled for DNA copy-number alterations and loss of heterozygosity using single-nucleotide polymorphism array and quantitative real-time polymerase chain reaction. These investigators found alterations of *CCND2* (12p13) and *RBI* (13q14), suggesting that this may implicate the cyclin/CDK-RB-E2F pathway in tumor formation. Gains in *PRDM14* (8q13) were also noted.[12]

A separate study of 49 cases of intracranial GCTs confirmed high rates of *KIT* and *RAS* mutational activation (56%), global hypomethylation, and chromosomal instability (12p gains in 82% of cases and 13q losses in 45% of cases). Global hypomethylation mirrored primordial germ cells in early development.[13]

Clinical Features

The signs and symptoms of CNS GCTs depend on the location of the tumor in the brain, as follows:

- **Suprasellar region.** Patients with tumors arising in the suprasellar region often present with subtle or overt hormonal deficiencies and may experience a protracted prodrome lasting months to years. Diabetes insipidus caused by antidiuretic hormone deficiency occurs in 70% to 90% of patients and is the most common sentinel symptom; patients can usually compensate for this deficiency by drinking excessive amounts of fluid for months to years. Eventually, other hormonal symptoms and visual deficits may emerge as the tumor expands dorsally and compresses or invades the optic chiasm and/or fills the third ventricle to cause hydrocephalus.[14-16]
- **Pineal region.** Patients with tumors in the pineal region usually have a shorter history of symptoms than do patients with tumors of the suprasellar or basal ganglionic region, with weeks to months of symptoms that include raised intracranial pressure and diplopia related to tectal and aqueductal compression. Symptoms and signs unique to masses in the pineal and posterior third ventricular region include Parinaud syndrome (vertical gaze impairment, convergence nystagmus, and light-near pupillary response dissociation), headache, and nausea and vomiting.
- **Multifocal or bifocal tumors.** Patients with multifocal or bifocal primary tumors may present with both suprasellar-region and pineal-region syndromes.[15]

Nonspecific symptoms such as enuresis, anorexia, and psychiatric complaints [17] can lead to delays in a diagnosis, whereas signs of increased intracranial pressure or visual changes tend to result in an earlier diagnosis.[18]

Diagnostic Evaluation

Radiographic characteristics of CNS GCTs cannot reliably differentiate germinomas from NGGCTs or other CNS tumors. The diagnosis of GCTs is based on the following:

- Characteristic clinical signs and symptoms supported by neuroimaging.
- Histology, if available.
- GCT marker analysis in the serum and lumbar cerebrospinal fluid (CSF).

The diagnosis of a suspected CNS GCT and an assessment of the clinical deficits and extent of metastases can usually be confirmed with the following tests:

- Magnetic resonance imaging (MRI) of brain and spine with gadolinium.
- Alpha-fetoprotein (AFP) and beta subunit human chorionic gonadotropin (beta-HCG) in both serum and CSF. If preoperative lumbar CSF can be obtained safely and tumor markers are found to be elevated, histologic confirmation may not be needed. Before definitive therapy is initiated, a lumbar CSF assessment for cytology and tumor markers should be performed, if safe, to reconfirm the diagnosis and help monitor treatment response and control; the diagnostic utility of lumbar CSF is better validated and more reliable.[18,19]
- Evaluation of pituitary/hypothalamic function.
- Visual-field and acuity examinations for suprasellar or hypothalamic tumors.

If possible, a baseline neuropsychologic examination should be performed after symptoms of endocrine deficiency and raised intracranial pressure are resolved.

A diagnosis of GCTs often requires a tumor biopsy, except when characteristic increased tumor markers are found in the serum and/or CSF. When the tumor markers are negative or mildly elevated but below diagnostic criteria, or if there is any noncharacteristic finding, a tumor biopsy is performed.

It is crucial that appropriate staging is determined and that pure germinomas are distinguished from NGGCTs. Chemotherapy and radiation treatment plans differ significantly depending on GCT category and extent of disease.

References

1. Matsutani M, Sano K, Takakura K, et al.: Primary intracranial germ cell tumors: a clinical analysis of 153 histologically verified cases. *J Neurosurg* 86 (3): 446-55, 1997. [PubMed: 9046301]
2. Matsutani M; Japanese Pediatric Brain Tumor Study Group: Combined chemotherapy and radiation therapy for CNS germ cell tumors--the Japanese experience. *J Neurooncol* 54 (3): 311-6, 2001. [PubMed: 11767296]
3. Ostrom QT, Gittleman H, Liao P, et al.: CBTRUS Statistical Report: Primary brain and other central nervous system tumors diagnosed in the United States in 2010-2014. *Neuro Oncol* 19 (suppl_5): v1-v88, 2017. [PMC free article: PMC5693142] [PubMed: 29117289]
4. Louis DN, Ohgaki H, Wiestler OD: WHO Classification of Tumours of the Central Nervous System. 4th rev.ed. Lyon, France: IARC Press, 2016.
5. Louis DN, Ohgaki H, Wiestler OD, et al.: The 2007 WHO classification of tumours of the central nervous system. *Acta Neuropathol* 114 (2): 97-109, 2007. [PMC free article: PMC1929165] [PubMed: 17618441]
6. Committee of Brain Tumor Registry of Japan: Report of Brain Tumor Registry of Japan (1969-1996). *Neurol Med Chir (Tokyo)* 43 (Suppl): i-vii, 1-111, 2003. [PubMed: 14705327]
7. The Committee of Brain Tumor Registry of Japan: Brain Tumor Registry of Japan (2001-2004). *Neurol Med Chir (Tokyo)* 54 (Suppl): 1-102, 2014. Also available online. Last accessed August 07, 2020.
8. Weksberg DC, Shibamoto Y, Paulino AC: Bifocal intracranial germinoma: a retrospective analysis of treatment outcomes in 20 patients and review of the literature. *Int J Radiat Oncol Biol Phys* 82 (4): 1341-51, 2012. [PubMed: 21669501]
9. Goodwin TL, Sainani K, Fisher PG: Incidence patterns of central nervous system germ cell tumors: a SEER Study. *J Pediatr Hematol Oncol* 31 (8): 541-4, 2009. [PubMed: 19636276]
10. Villano JL, Propp JM, Porter KR, et al.: Malignant pineal germ-cell tumors: an analysis of cases from three tumor registries. *Neuro Oncol* 10 (2): 121-30, 2008. [PMC free article: PMC2613814] [PubMed: 18287340]
11. Wang L, Yamaguchi S, Burstein MD, et al.: Novel somatic and germline mutations in intracranial germ cell tumours. *Nature* 511 (7508): 241-5, 2014. [PMC free article: PMC4532372] [PubMed: 24896186]
12. Terashima K, Yu A, Chow WY, et al.: Genome-wide analysis of DNA copy number alterations and loss of heterozygosity in intracranial germ cell tumors. *Pediatr Blood Cancer* 61 (4): 593-600, 2014. [PubMed: 24249158]

13. Schulte SL, Waha A, Steiger B, et al.: CNS germinomas are characterized by global demethylation, chromosomal instability and mutational activation of the Kit-, Ras/Raf/Erk- and Akt-pathways. *Oncotarget* 7 (34): 55026-55042, 2016. [PMC free article: [PMC5342399](#)] [PubMed: [27391150](#)]
14. Afzal S, Wherrett D, Bartels U, et al.: Challenges in management of patients with intracranial germ cell tumor and diabetes insipidus treated with cisplatin and/or ifosfamide based chemotherapy. *J Neurooncol* 97 (3): 393-9, 2010. [PubMed: [19820898](#)]
15. Hoffman HJ, Otsubo H, Hendrick EB, et al.: Intracranial germ-cell tumors in children. *J Neurosurg* 74 (4): 545-51, 1991. [PubMed: [1848284](#)]
16. Sethi RV, Marino R, Niemierko A, et al.: Delayed diagnosis in children with intracranial germ cell tumors. *J Pediatr* 163 (5): 1448-53, 2013. [PubMed: [23896184](#)]
17. Malbari F, Gershon TR, Garvin JH, et al.: Psychiatric manifestations as initial presentation for pediatric CNS germ cell tumors, a case series. *Childs Nerv Syst* 32 (8): 1359-62, 2016. [PMC free article: [PMC4976767](#)] [PubMed: [27312077](#)]
18. Crawford JR, Santi MR, Vezina G, et al.: CNS germ cell tumor (CNSGCT) of childhood: presentation and delayed diagnosis. *Neurology* 68 (20): 1668-73, 2007. [PubMed: [17502547](#)]
19. Allen J, Chacko J, Donahue B, et al.: Diagnostic sensitivity of serum and lumbar CSF bHCG in newly diagnosed CNS germinoma. *Pediatr Blood Cancer* 59 (7): 1180-2, 2012. [PMC free article: [PMC3356788](#)] [PubMed: [22302772](#)]

Cellular Classification of Childhood CNS Germ Cell Tumors

The pathogenesis of intracranial germ cell tumors (GCTs) is unknown. The *germ cell theory* proposes that central nervous system (CNS) GCTs arise from primordial germ cells that have aberrantly migrated and undergone malignant transformation. A genome-wide methylation profiling study of 61 GCTs supports this hypothesis.[1] An alternative hypothesis, *the embryonic cell theory*, proposes that GCTs arise from a pluripotent embryonic cell that escapes normal developmental signals and progresses to CNS GCTs.[2,3]

Previous molecular studies comparing the genomic alterations in GCTs showed similar copy-number alterations whether the GCT was systemic or CNS based.[4]

The World Health Organization has classified CNS GCTs into the following groups:[5]

- Germinoma.
- Embryonal carcinoma.
- Yolk sac tumor.
- Choriocarcinoma.
- Teratoma.
 - Mature
 - Immature.
- Teratoma with malignant transformation.
- Mixed GCT.

In addition to the microscopic appearance of the various CNS GCTs, tumor markers (proteins, such as alpha-fetoprotein [AFP] and beta subunit human chorionic gonadotropin [beta-HCG], secreted by the tumor cells) found in the serum **and** cerebrospinal fluid (CSF) aid in diagnosis (refer to Tables 1 and 2).

The diagnosis and classification of CNS GCTs can be made on the basis of histology alone, tumor markers alone, or a combination of both.[5-7] There is an effort to use tumor markers for prognostication on the basis of the presence and degree of elevation of AFP and beta-HCG. This is an evolving process, and cooperative groups in North America, Europe, and Japan have adopted slightly different criteria. For example, groups in the United States and Europe consider tumors to be secreting or mixed GCTs if serum and/or CSF AFP levels are 10 ng/mL or higher and/or serum and/or CSF beta-HCG levels are 50 IU/L or higher; however, several European and Asian groups designate tumors with serum and/or CSF AFP levels of 50 ng/mL or higher and/or beta-HCG levels of 100 IU/L or higher as secreting GCTs. Patients with pure germinomas and teratomas usually present with negative markers, but low levels of beta-HCG can be detected in patients with germinomas.[8]

Favorable-risk germinomas can secrete low levels of beta-HCG resulting from a syncytiotrophoblastic component. Nongerminomatous germ cell tumors (NGGCTs) can consist of one malignant NGGCT type (e.g., embryonal carcinoma, yolk sac tumor, endodermal sinus tumor, or choriocarcinoma) or contain multiple elements of GCT components, including teratomatous or germinomatous constituents.

Table 1. Immunohistochemical Markers and Germ Cell Tumor Variants

Tumor Type	Beta-HCG	AFP	PLAP	c-kit
Germinoma	±	-	±	+
Germinoma (syncytiotrophoblastic)	+	-	±	+
Embryonal carcinoma	+	+	+	-
Yolk sac tumor	-	+	±	-
Choriocarcinoma	+	-	±	-
Teratoma				
Immature teratoma	±	±	-	±
Mature teratoma	-	-	-	-
Mixed germ cell tumor	±	±	±	±

AFP = alpha-fetoprotein; HCG = human chorionic gonadotropin; PLAP = placental alkaline phosphatase; + = positive; - = negative; ± = equivocal.

Table 2. Serum and Cerebrospinal Fluid Markers and Germ Cell Tumor Variants

Tumor Type	Beta-HCG	AFP
Germinoma	Normal or slightly elevated, not diagnostic	Negative
Embryonal carcinoma	Elevated	Elevated
Yolk sac tumor	Negative	Highly elevated
Choriocarcinoma	Highly elevated	Negative
Teratoma	Negative	Elevated, not diagnostic

AFP = alpha-fetoprotein; HCG = human chorionic gonadotropin.

Elevations of tumor markers along with imaging findings are used as surrogate diagnostic markers for CNS GCT and may obviate the need for a histologic diagnosis. The tumor markers AFP and beta-HCG are the most useful, although other markers, such as placental alkaline phosphatase and c-kit, are being investigated. Distinguishing between different GCT types by CSF protein marker levels alone is somewhat arbitrary, and standards vary across continents. Patients with pure germinomas and teratomas usually present with negative markers, but very low levels of beta-HCG

can be detected in patients with germinomas.[9] Current efforts are directed at determining a marker threshold for beta-HCG–secreting germinomas, because data suggest that the beta-HCG levels of 50 mIU/mL in Europe and 100 mIU/mL in North America that are used to distinguish germinomas from NGGCTs are questionable.

The use of tumor markers and histology in GCT clinical trials is evolving. For example, in the COG-ACNS1123 (NCT01602666) trial, patients are eligible for assignment to the germinoma regimen without biopsy confirmation if they have one of the following:

1. Either pineal region tumors or suprasellar primary tumors, normal AFP levels, and beta-HCG levels between 5 and 50 mIU/mL in serum and/or CSF.
2. Bifocal presentation (pineal and suprasellar), suprasellar location, diabetes insipidus, normal AFP levels, and beta-HCG levels lower than 100 mIU/mL in serum and/or CSF.

Alternative classification schemes for CNS GCTs have been proposed by groups such as the Japanese Pediatric Brain Tumor Study Group for CNS GCTs, who based their stratification on the prognostic grouping of the differing histologic variants, as shown in Table 3. Pure germinomas and mature teratomas fall into the good prognostic group; choriocarcinomas, yolk sac tumors, embryonal carcinomas, or mixtures of these three histologic subtypes fall into the poor prognostic group.[10]

Table 3. Japanese Pediatric Brain Tumor Study Group Classification

Prognostic Group	Tumor Type
Good	Germinoma, pure
	Mature teratoma
Intermediate	Germinoma with syncytiotrophoblastic giant cells
	Immature teratoma
	Mixed tumors mainly composed of germinoma or teratoma
	Teratoma with malignant transformation
Poor	Choriocarcinoma
	Embryonal carcinoma
	Mixed tumors composed of choriocarcinoma, yolk sac tumor, or embryonal carcinoma
	Yolk sac tumor

References

1. Fukushima S, Yamashita S, Kobayashi H, et al.: Genome-wide methylation profiles in primary intracranial germ cell tumors indicate a primordial germ cell origin for germinomas. *Acta Neuropathol* 133 (3): 445-462, 2017. [PubMed: 28078450]
2. Sano K, Matsutani M, Seto T: So-called intracranial germ cell tumours: personal experiences and a theory of their pathogenesis. *Neurol Res* 11 (2): 118-26, 1989. [PubMed: 2569683]
3. Teilum G: Embryology of ovary, testis, and genital ducts. In: Teilum G: *Special Tumors of Ovary and Testis and Related Extragonadal Lesions: Comparative Pathology and Histological Identification*. Philadelphia, Pa: J. B. Lippincott, 1976, pp 15-30.
4. Schneider DT, Zahn S, Sievers S, et al.: Molecular genetic analysis of central nervous system germ cell tumors with comparative genomic hybridization. *Mod Pathol* 19 (6): 864-73, 2006. [PubMed: 16607373]
5. Rosenblum MK, Nakazato Y, Matsutani M: Germ cell tumours. In: Louis DN, Ohgaki H, Wiestler OD: WHO

Classification of Tumours of the Central Nervous System. 4th rev.ed. Lyon, France: IARC Press, 2016, pp 286-91.

6. Murray MJ, Bartels U, Nishikawa R, et al.: Consensus on the management of intracranial germ-cell tumours. *Lancet Oncol* 16 (9): e470-e477, 2015. [PubMed: 26370356]
7. Allen J, Chacko J, Donahue B, et al.: Diagnostic sensitivity of serum and lumbar CSF bHCG in newly diagnosed CNS germinoma. *Pediatr Blood Cancer* 59 (7): 1180-2, 2012. [PMC free article: PMC3356788] [PubMed: 22302772]
8. Calaminus G, Bamberg M, Harms D, et al.: AFP/beta-HCG secreting CNS germ cell tumors: long-term outcome with respect to initial symptoms and primary tumor resection. Results of the cooperative trial MAKEI 89. *Neuropediatrics* 36 (2): 71-7, 2005. [PubMed: 15822019]
9. Frazier AL, Olson TA, Schneider DT, et al.: Germ cell tumors. In: Pizzo PA, Poplack DG, eds.: *Principles and Practice of Pediatric Oncology*. 7th ed. Philadelphia, Pa: Lippincott Williams and Wilkins, 2015, pp 899-918.
10. Matsutani M; Japanese Pediatric Brain Tumor Study Group: Combined chemotherapy and radiation therapy for CNS germ cell tumors--the Japanese experience. *J Neurooncol* 54 (3): 311-6, 2001. [PubMed: 11767296]

Stage Information for Childhood CNS Germ Cell Tumors

There is no universally accepted clinical staging system for germ cell tumors (GCTs), but a modified Chang staging system has been traditionally used.[1] Staging evaluation of central nervous system GCTs includes the following:

- Magnetic resonance imaging (MRI). In addition to whole-brain MRI, MRI of the spine is required.
- Lumbar cerebrospinal fluid (CSF). When medically permissible, lumbar CSF should be obtained for the measurement of tumor markers (alpha-fetoprotein [AFP] and beta subunit human chorionic gonadotropin [beta-HCG]) and for cytopathologic review.

Serum tumor markers are often obtained for AFP and beta-HCG; however, they do not serve as a substitute for CSF tumor markers, if lumbar CSF can be safely obtained.[2]

Patients with localized disease and negative CSF cytology are considered to be M0 (metastatic negative); patients with positive CSF cytology or patients with drop metastasis (spinal or cranial subarachnoid metastases that arise from intracranial lesions) are considered to be M+ (metastatic positive). Appropriate staging is crucial because patients with metastatic disease may receive higher total doses of radiation and more extended radiation fields.

GCTs may be disseminated throughout the neuraxis at the time of diagnosis or at any disease stage. Several patterns of spread may occur in germinomas, such as subependymal dissemination in the lateral or third ventricles and parenchymal infiltration. Rarely, extracranial spread to lung and bone has also been reported.[3,4]

Patients with bifocal intracranial germinomas limited to the suprasellar and pineal region are being treated in the same manner as are patients with synchronous, localized, nonmetastatic tumors in ongoing studies in North America (COG ACNS1123 [NCT01602666]) and Europe (SIOP CNS GCT II [NCT01424839]).

References

1. Calaminus G, Kortmann R, Worch J, et al.: SIOP CNS GCT 96: final report of outcome of a prospective, multinational nonrandomized trial for children and adults with intracranial germinoma, comparing craniospinal irradiation alone with chemotherapy followed by focal primary site irradiation for patients with localized disease. *Neuro Oncol* 15 (6): 788-96, 2013. [PMC free article: PMC3661100] [PubMed: 23460321]
2. Fujimaki T, Mishima K, Asai A, et al.: Levels of beta-human chorionic gonadotropin in cerebrospinal fluid of patients with malignant germ cell tumor can be used to detect early recurrence and monitor the response to treatment. *Jpn J Clin Oncol* 30 (7): 291-4, 2000. [PubMed: 11007160]
3. Jennings MT, Gelman R, Hochberg F: Intracranial germ-cell tumors: natural history and pathogenesis. *J*

Neurosurg 63 (2): 155-67, 1985. [PubMed: 2991485]

4. Gay JC, Janco RL, Lukens JN: Systemic metastases in primary intracranial germinoma. Case report and literature review. *Cancer* 55 (11): 2688-90, 1985. [PubMed: 3995478]

Treatment Option Overview for Childhood CNS Germ Cell Tumors

Teratomas, germinomas, and other nongerminomatous germ cell tumors (NGGCTs) have differing prognoses and require different treatment regimens. Studies have observed the following:[1-5]

- For children older than 3 years and adults, radiation therapy has been an important component of therapy for germinomas and NGGCTs, although the optimal total dose and field size are debated.
- Germ cell tumors (GCTs) arising in the central nervous system, similar to gonadal and extragonadal GCTs, have demonstrated sensitivity to chemotherapy.
- Germinomas are highly chemosensitive and radiosensitive tumors. They are curable with craniospinal irradiation and local site–boost radiation therapy alone. However, the use of neoadjuvant or preirradiation chemotherapy allows reduced radiation therapy doses and volumes and, subsequently, reduced long-term radiation therapy–related effects. In North America, patients with localized germinomas are effectively treated with whole-ventricular irradiation supplemented with tumor site–boost radiation therapy. Focal irradiation to the tumor bed, regardless of response to chemotherapy, is considered inadequate treatment.[6]
- For NGGCTs, the combined use of more intensive neoadjuvant chemotherapy followed by either localized or craniospinal irradiation has resulted in excellent survival rates in the last decade.[7,8]

Table 4 outlines the treatment options for newly diagnosed and recurrent childhood CNS GCTs.

Table 4. Treatment Options for Childhood Central Nervous System (CNS) Germ Cell Tumors (GCTs)

Treatment Group	Treatment Options
Newly diagnosed childhood germinomas	Radiation therapy
	Neoadjuvant chemotherapy followed by response-based radiation therapy
Newly diagnosed childhood teratomas	Surgery
	Adjuvant therapy, for patients who had a subtotal resection (controversial):
	—Focal radiation therapy
	—Chemotherapy
	—Stereotactic radiosurgery
Newly diagnosed childhood nongerminomatous GCTs	Chemotherapy followed by radiation therapy
	Surgery, if needed
Recurrent childhood CNS GCTs	Chemotherapy followed by additional radiation therapy
	High-dose chemotherapy with stem cell rescue with or without additional radiation therapy

Dramatic improvements in survival have been achieved for children and adolescents with cancer. Between 1975 and 2010, childhood cancer mortality decreased by more than 50%.[9] Childhood and adolescent cancer survivors require close monitoring because cancer therapy side effects may persist or develop months or years after treatment. (Refer to

the PDQ summary on [Late Effects of Treatment for Childhood Cancer](#) for specific information about the incidence, type, and monitoring of late effects in childhood and adolescent cancer survivors.)

References

1. Osuka S, Tsuboi K, Takano S, et al.: Long-term outcome of patients with intracranial germinoma. *J Neurooncol* 83 (1): 71-9, 2007. [PubMed: 17245622]
2. Allen JC, Kim JH, Packer RJ: Neoadjuvant chemotherapy for newly diagnosed germ-cell tumors of the central nervous system. *J Neurosurg* 67 (1): 65-70, 1987. [PubMed: 2439668]
3. Kellie SJ, Boyce H, Dunkel IJ, et al.: Primary chemotherapy for intracranial nongerminomatous germ cell tumors: results of the second international CNS germ cell study group protocol. *J Clin Oncol* 22 (5): 846-53, 2004. [PubMed: 14990640]
4. Calaminus G, Kortmann R, Worch J, et al.: SIOP CNS GCT 96: final report of outcome of a prospective, multinational nonrandomized trial for children and adults with intracranial germinoma, comparing craniospinal irradiation alone with chemotherapy followed by focal primary site irradiation for patients with localized disease. *Neuro Oncol* 15 (6): 788-96, 2013. [PMC free article: [PMC3661100](#)] [PubMed: 23460321]
5. Calaminus G, Bamberg M, Harms D, et al.: AFP/beta-HCG secreting CNS germ cell tumors: long-term outcome with respect to initial symptoms and primary tumor resection. Results of the cooperative trial MAKEI 89. *Neuropediatrics* 36 (2): 71-7, 2005. [PubMed: 15822019]
6. Joo JH, Park JH, Ra YS, et al.: Treatment outcome of radiation therapy for intracranial germinoma: adaptive radiation field in relation to response to chemotherapy. *Anticancer Res* 34 (10): 5715-21, 2014. [PubMed: 25275079]
7. Goldman S, Bouffet E, Fisher PG, et al.: Phase II Trial Assessing the Ability of Neoadjuvant Chemotherapy With or Without Second-Look Surgery to Eliminate Measurable Disease for Nongerminomatous Germ Cell Tumors: A Children's Oncology Group Study. *J Clin Oncol* 33 (22): 2464-71, 2015. [PMC free article: [PMC4507465](#)] [PubMed: 26101244]
8. Calaminus G, Frappaz D, Kortmann RD, et al.: Outcome of patients with intracranial non-germinomatous germ cell tumors-lessons from the SIOP-CNS-GCT-96 trial. *Neuro Oncol* 19 (12): 1661-1672, 2017. [PMC free article: [PMC5716085](#)] [PubMed: 29048505]
9. Smith MA, Altekruse SF, Adamson PC, et al.: Declining childhood and adolescent cancer mortality. *Cancer* 120 (16): 2497-506, 2014. [PMC free article: [PMC4136455](#)] [PubMed: 24853691]

Treatment of Newly Diagnosed Childhood CNS Germinomas

Treatment Options for Newly Diagnosed Childhood CNS Germinomas

Treatment options for newly diagnosed childhood central nervous system (CNS) germinomas include the following:

1. [Radiation therapy](#).
2. [Neoadjuvant chemotherapy followed by response-based radiation therapy](#).

Radiation therapy

Germinomas are highly radiosensitive and have been traditionally treated successfully with radiation therapy alone. Historically, patients with nondisseminated disease have been treated with craniospinal irradiation plus a boost to the region of the primary tumor. The dose of craniospinal irradiation has ranged from 24 Gy to 36 Gy, although studies have used lower doses. The local tumor dose of radiation therapy has ranged between 40 Gy and 50 Gy. Studies of lower-dose craniospinal irradiation have shown excellent outcomes.[1] This modification has resulted in 5-year overall survival rates of higher than 90%.[2]; [3][Level of evidence: 2A]; [4,5][Level of evidence: 3iA] These excellent survival rates have allowed investigators to focus on reducing radiation treatment volume and dose in an attempt to

decrease late effects.[3,6,7]

Patterns of relapse after craniospinal irradiation versus reduced-volume radiation therapy (whole-brain or whole-ventricular radiation therapy) have supported the omission of craniospinal irradiation for localized germinomas.[8-10] On the basis of these results, the treatment for patients with localized germinomas has been modified to cover the whole ventricular system (24 Gy) followed by a boost to the primary site (40–45 Gy), rather than to deliver radiation therapy to the entire craniospinal axis or even to the whole brain. This change has not resulted in worse outcomes and is expected to minimize the acute and long-term toxicity of radiation therapy. Focal radiation therapy directed only to the tumor volume, even after neoadjuvant chemotherapy, results in inferior outcomes compared with whole-brain or whole-ventricle radiation therapy; therefore, focal radiation therapy is not recommended.[7]

Neoadjuvant chemotherapy followed by response-based radiation therapy

Chemotherapy has been explored in an effort to reduce radiation therapy doses and associated neurodevelopmental morbidity. Several studies have confirmed the feasibility of this approach for maintaining excellent survival rates, but the number of treated patients is small.[11-13][Level of evidence: 2A]; [14,15][Level of evidence: 3iA]; [16][Level of evidence: 3iiiC]

Chemotherapy agents such as cyclophosphamide, ifosfamide, etoposide, cisplatin, and carboplatin are highly active in CNS germinomas. Patients receiving chemotherapy agents that require hyperhydration (e.g., cyclophosphamide, ifosfamide, and cisplatin) are often quite challenging to manage because of the possibility of diabetes insipidus in patients with primary tumors of the suprasellar region.[17]

An international group of investigators has explored a chemotherapy-only approach primarily for younger children. The investigators were able to achieve a complete response in 84% of patients with germinomas treated with chemotherapy alone. Fifty percent of these patients suffered tumor relapse or progression; many recurrences were local, local plus ventricular, and ventricular alone and/or with leptomeningeal dissemination throughout the CNS, which required additional therapy, including radiation.[18] Subsequent studies have continued to support the need for radiation therapy after chemotherapy and the likely requirement for whole-ventricular irradiation (24 Gy) with local tumor site–boost (total dose, 40 Gy).[19][Level of evidence: 2A]; [20][Level of evidence: 3iiiA] Excellent results have also been reported for patients with metastatic germinomas who received craniospinal irradiation of 24 Gy with local tumor site–boost (total dose, 40 Gy).[21][Level of evidence: 2A]

Optimal management of bifocal lesions is less clear, but most investigators consider this presentation a form of multifocal primary disease to be staged as M0. A meta-analysis of 60 patients demonstrated excellent progression-free survival after craniospinal irradiation alone. Chemotherapy plus localized radiation therapy, including whole-ventricular irradiation, also resulted in excellent disease control.[22][Level of evidence: 3iiDiii]

Treatment Options Under Clinical Evaluation for Newly Diagnosed Childhood CNS Germinomas

Early-phase therapeutic trials may be available for selected patients. These trials may be available via the Children's Oncology Group (COG), the Pediatric Brain Tumor Consortium, or other entities. Information about National Cancer Institute (NCI)–supported clinical trials can be found on the [NCI website](#). For information about clinical trials sponsored by other organizations, refer to the [ClinicalTrials.gov website](#).

References

1. Bamberg M, Kortmann RD, Calaminus G, et al.: Radiation therapy for intracranial germinoma: results of the German cooperative prospective trials MAKEI 83/86/89. *J Clin Oncol* 17 (8): 2585-92, 1999. [PubMed: 10561326]
2. Shibamoto Y, Abe M, Yamashita J, et al.: Treatment results of intracranial germinoma as a function of the irradiated volume. *Int J Radiat Oncol Biol Phys* 15 (2): 285-90, 1988. [PubMed: 3403311]

3. Cho J, Choi JU, Kim DS, et al.: Low-dose craniospinal irradiation as a definitive treatment for intracranial germinoma. *Radiother Oncol* 91 (1): 75-9, 2009. [PubMed: 19019472]
4. Huang PI, Chen YW, Wong TT, et al.: Extended focal radiotherapy of 30 Gy alone for intracranial synchronous bifocal germinoma: a single institute experience. *Childs Nerv Syst* 24 (11): 1315-21, 2008. [PubMed: 18581122]
5. Eom KY, Kim IH, Park CI, et al.: Upfront chemotherapy and involved-field radiotherapy results in more relapses than extended radiotherapy for intracranial germinomas: modification in radiotherapy volume might be needed. *Int J Radiat Oncol Biol Phys* 71 (3): 667-71, 2008. [PubMed: 18514777]
6. Chen MJ, Santos Ada S, Sakuraba RK, et al.: Intensity-modulated and 3D-conformal radiotherapy for whole-ventricular irradiation as compared with conventional whole-brain irradiation in the management of localized central nervous system germ cell tumors. *Int J Radiat Oncol Biol Phys* 76 (2): 608-14, 2010. [PubMed: 19879065]
7. Joo JH, Park JH, Ra YS, et al.: Treatment outcome of radiation therapy for intracranial germinoma: adaptive radiation field in relation to response to chemotherapy. *Anticancer Res* 34 (10): 5715-21, 2014. [PubMed: 25275079]
8. Rogers SJ, Mosleh-Shirazi MA, Saran FH: Radiotherapy of localised intracranial germinoma: time to sever historical ties? *Lancet Oncol* 6 (7): 509-19, 2005. [PubMed: 15992700]
9. Shikama N, Ogawa K, Tanaka S, et al.: Lack of benefit of spinal irradiation in the primary treatment of intracranial germinoma: a multiinstitutional, retrospective review of 180 patients. *Cancer* 104 (1): 126-34, 2005. [PubMed: 15895370]
10. Hardenbergh PH, Golden J, Billet A, et al.: Intracranial germinoma: the case for lower dose radiation therapy. *Int J Radiat Oncol Biol Phys* 39 (2): 419-26, 1997. [PubMed: 9308946]
11. Kretschmar C, Kleinberg L, Greenberg M, et al.: Pre-radiation chemotherapy with response-based radiation therapy in children with central nervous system germ cell tumors: a report from the Children's Oncology Group. *Pediatr Blood Cancer* 48 (3): 285-91, 2007. [PMC free article: PMC4086720] [PubMed: 16598761]
12. Allen JC, DaRosso RC, Donahue B, et al.: A phase II trial of preirradiation carboplatin in newly diagnosed germinoma of the central nervous system. *Cancer* 74 (3): 940-4, 1994. [PubMed: 8039122]
13. Buckner JC, Peethambaram PP, Smithson WA, et al.: Phase II trial of primary chemotherapy followed by reduced-dose radiation for CNS germ cell tumors. *J Clin Oncol* 17 (3): 933-40, 1999. [PubMed: 10071287]
14. Khatua S, Dhall G, O'Neil S, et al.: Treatment of primary CNS germinomatous germ cell tumors with chemotherapy prior to reduced dose whole ventricular and local boost irradiation. *Pediatr Blood Cancer* 55 (1): 42-6, 2010. [PubMed: 20222020]
15. Cheng S, Kilday JP, Laperriere N, et al.: Outcomes of children with central nervous system germinoma treated with multi-agent chemotherapy followed by reduced radiation. *J Neurooncol* 127 (1): 173-80, 2016. [PubMed: 26744133]
16. O'Neil S, Ji L, Buranahirun C, et al.: Neurocognitive outcomes in pediatric and adolescent patients with central nervous system germinoma treated with a strategy of chemotherapy followed by reduced-dose and volume irradiation. *Pediatr Blood Cancer* 57 (4): 669-73, 2011. [PubMed: 21495164]
17. Afzal S, Wherrett D, Bartels U, et al.: Challenges in management of patients with intracranial germ cell tumor and diabetes insipidus treated with cisplatin and/or ifosfamide based chemotherapy. *J Neurooncol* 97 (3): 393-9, 2010. [PubMed: 19820898]
18. Balmaceda C, Heller G, Rosenblum M, et al.: Chemotherapy without irradiation--a novel approach for newly diagnosed CNS germ cell tumors: results of an international cooperative trial. The First International Central Nervous System Germ Cell Tumor Study. *J Clin Oncol* 14 (11): 2908-15, 1996. [PubMed: 8918487]
19. da Silva NS, Cappellano AM, Diez B, et al.: Primary chemotherapy for intracranial germ cell tumors: results of the third international CNS germ cell tumor study. *Pediatr Blood Cancer* 54 (3): 377-83, 2010. [PubMed: 20063410]
20. Alapetite C, Brisse H, Patte C, et al.: Pattern of relapse and outcome of non-metastatic germinoma patients treated with chemotherapy and limited field radiation: the SFOP experience. *Neuro Oncol* 12 (12): 1318-25,

2010. [PMC free article: PMC3018943] [PubMed: 20716594]

21. Calaminus G, Kortmann R, Worch J, et al.: SIOP CNS GCT 96: final report of outcome of a prospective, multinational nonrandomized trial for children and adults with intracranial germinoma, comparing craniospinal irradiation alone with chemotherapy followed by focal primary site irradiation for patients with localized disease. *Neuro Oncol* 15 (6): 788-96, 2013. [PMC free article: PMC3661100] [PubMed: 23460321]
22. Weksberg DC, Shibamoto Y, Paulino AC: Bifocal intracranial germinoma: a retrospective analysis of treatment outcomes in 20 patients and review of the literature. *Int J Radiat Oncol Biol Phys* 82 (4): 1341-51, 2012. [PubMed: 21669501]

Treatment of Newly Diagnosed Childhood CNS Teratomas

Treatment Options for Newly Diagnosed Childhood CNS Teratomas

Teratomas are designated as mature or immature on the basis of the absence or presence of differentiated tissues. The Japanese Pediatric Brain Tumor Study Group stratifies teratomas for classification and intensity of treatment (chemotherapy and radiation) into the good-risk group (mature teratomas) and intermediate-risk group (immature teratomas) (refer to Table 3), while the Children's Oncology Group includes immature teratomas with other nongerminomatous germ cell tumors.

Treatment options for newly diagnosed childhood central nervous system teratomas include the following:

1. Surgery.
2. Adjuvant therapy, for patients who had a subtotal resection (controversial).
 - Focal radiation therapy.
 - Chemotherapy.
 - Stereotactic radiosurgery.

The primary treatment for teratomas is maximal surgical resection. Adjuvant treatment in the form of focal radiation therapy and/or adjuvant chemotherapy for subtotally resected tumors is controversial, with small institutional series suggesting potential utility for the use of stereotactic radiosurgery.[1,2][Level of evidence: 3iA]

References

1. Huang X, Zhang R, Zhou LF: Diagnosis and treatment of intracranial immature teratoma. *Pediatr Neurosurg* 45 (5): 354-60, 2009. [PubMed: 19907199]
2. Lee YH, Park EK, Park YS, et al.: Treatment and outcomes of primary intracranial teratoma. *Childs Nerv Syst* 25 (12): 1581-7, 2009. [PubMed: 19693515]

Treatment of Newly Diagnosed Childhood CNS Nongerminomatous Germ Cell Tumors

The prognosis for children with central nervous system (CNS) nongerminomatous germ cell tumors (NGGCTs) remains inferior to that for children with germinomas, but the difference is diminishing with the addition of multimodality therapy. With the current treatment regimens, the 10-year overall survival (OS) for NGGCTs ranges between 70% and 80%.[1,2] NGGCTs are radiosensitive, but survival after standard craniospinal irradiation alone has been poor, ranging from 20% to 45% at 5 years. In patients with NGGCTs who suffer tumor relapse, most relapses occur within 18 months.

Treatment Options for Newly Diagnosed Childhood CNS NGGCTs

Treatment options for newly diagnosed childhood CNS NGGCTs include the following:

1. Chemotherapy followed by radiation therapy.
2. Surgery, for tumors that partially respond to chemotherapy or for tumors that increase in size during or after therapy (possible growing teratoma syndrome).

The optimal treatment regimen for CNS NGGCTs remains unclear.

Chemotherapy followed by radiation therapy

Anticancer agents that have been used include carboplatin, etoposide, bleomycin, ifosfamide, and vinblastine in different combinations. The use of chemotherapy before radiation therapy has increased survival rates, but the specific chemotherapy regimen and length of therapy and the optimal radiation field, timing, and dose remain under investigation.[1,3,4] Some investigators have proposed radiation therapy fields that are smaller than those used for craniospinal irradiation (e.g., whole-ventricular irradiation with a boost to the local tumor site) for patients with nondisseminated NGGCT. Controversy exists over the pattern of tumor relapse in patients treated with chemotherapy and focal radiation.[1,2,5,6]

Evidence (chemotherapy followed by radiation therapy):

1. A Children's Oncology Group (COG) study (ACNS0122 [NCT00047320]) evaluated neoadjuvant chemotherapy followed by radiation therapy for children with localized NGGCTs.[7] Neoadjuvant chemotherapy consisted of six courses with carboplatin/etoposide alternating with ifosfamide/etoposide. After chemotherapy was completed, responding patients received 36 Gy of craniospinal radiation therapy, with 54 Gy to the tumor bed.
 - On the basis of a central review, 87% of patients showed either partial response (PR) or complete response (CR).
 - For the 102 eligible patients in the study, 5-year event-free survival (EFS) was 84% (\pm 4%), and OS was 93% (\pm 3%).
 - At 3 years, the EFS was 92% and the OS was 98% for all patients who achieved CR or PR either after induction chemotherapy or with the absence of malignant elements documented during second-look surgery.
2. The European SIOP-CNS-GCT-96 (NCT00293358) trial evaluated neoadjuvant chemotherapy consisting of four courses with cisplatin/etoposide/ifosfamide followed by focal radiation therapy (54 Gy) for patients with nonmetastatic disease.[8]
 - Patients with localized tumors (n = 116) demonstrated 5-year progression-free survival (PFS) rates of 72% (\pm 4%) and OS rates of 82% (\pm 4%).
3. The COG ACNS1123 (NCT01602666) phase II trial evaluated the omission of craniospinal irradiation and the efficacy of dose- and volume-reduced radiation therapy, defined as a dose of 30.6 Gy to the whole ventricular field plus a 23.4-Gy boost to the primary site, for patients with CNS NGGCTs who obtained CRs or PRs and marker normalization after six cycles of chemotherapy.[9]
 - Of the 107 eligible patients, 66 achieved CRs or PRs and received reduced-dose radiation therapy.
 - There were ten recurrences in patients who received reduced-dose radiation therapy, which prompted early study closure; however, after a retrospective central review, two subjects were found to have been ineligible for the reduction in radiation therapy.
 - Six of the eight eligible patients had recurrences in the spine only, and two patients had combined local plus spinal recurrences.

- The 3-year PFS rate was 87.8%, and the OS rate was 92.4%.

Surgery

A small percentage of patients treated with chemotherapy may have normalization of tumor markers with a less-than-complete radiographic response. Occasionally, a mass continues to expand in size even though tumor markers may have normalized. This condition is frequently designated as *growing teratoma syndrome* and may represent a lack of response by the more mature germ cell components (such as immature teratoma) to chemotherapy with or without radiation therapy.[7,10,11] In such circumstances, surgery is usually required for debulking, histologic confirmation, and exclusion of mixed germ cell tumor components.

A second-look surgery can help determine whether the residual mass contains teratoma, fibrosis, or residual NGGCT.[2,12] If second-look surgery finds mature teratoma or fibrosis after chemotherapy, the general approach is to proceed with radiation therapy as if the patient had achieved a CR to chemotherapy. However, if an active tumor is observed, then alternative treatment approaches are generally considered.[7]

Treatment Options Under Clinical Evaluation for Newly Diagnosed Childhood CNS NGGCTs

Early-phase therapeutic trials may be available for selected patients. These trials may be available via the COG, the Pediatric Brain Tumor Consortium, or other entities. Information about National Cancer Institute (NCI)-supported clinical trials can be found on the NCI website. For information about clinical trials sponsored by other organizations, refer to the ClinicalTrials.gov website.

References

1. Robertson PL, DaRosso RC, Allen JC: Improved prognosis of intracranial non-germinoma germ cell tumors with multimodality therapy. *J Neurooncol* 32 (1): 71-80, 1997. [PubMed: 9049865]
2. Baranzelli M, Patte C, Bouffet E, et al.: Carboplatin-based chemotherapy (CT) and focal irradiation (RT) in primary germ cell tumors (GCT): A French Society of Pediatric Oncology (SFOP) experience (meeting abstract). [Abstract] *Proceedings of the American Society of Clinical Oncology* 18: A-538, 140A, 1999.
3. Matsutani M; Japanese Pediatric Brain Tumor Study Group: Combined chemotherapy and radiation therapy for CNS germ cell tumors--the Japanese experience. *J Neurooncol* 54 (3): 311-6, 2001. [PubMed: 11767296]
4. Calaminus G, Bamberg M, Jürgens H, et al.: Impact of surgery, chemotherapy and irradiation on long term outcome of intracranial malignant non-germinomatous germ cell tumors: results of the German Cooperative Trial MAKEI 89. *Klin Padiatr* 216 (3): 141-9, 2004 May-Jun. [PubMed: 15175958]
5. Aoyama H, Shirato H, Ikeda J, et al.: Induction chemotherapy followed by low-dose involved-field radiotherapy for intracranial germ cell tumors. *J Clin Oncol* 20 (3): 857-65, 2002. [PubMed: 11821471]
6. Kim JW, Kim WC, Cho JH, et al.: A multimodal approach including craniospinal irradiation improves the treatment outcome of high-risk intracranial nongerminomatous germ cell tumors. *Int J Radiat Oncol Biol Phys* 84 (3): 625-31, 2012. [PubMed: 22420971]
7. Goldman S, Bouffet E, Fisher PG, et al.: Phase II Trial Assessing the Ability of Neoadjuvant Chemotherapy With or Without Second-Look Surgery to Eliminate Measurable Disease for Nongerminomatous Germ Cell Tumors: A Children's Oncology Group Study. *J Clin Oncol* 33 (22): 2464-71, 2015. [PMC free article: PMC4507465] [PubMed: 26101244]
8. Calaminus G, Frappaz D, Kortmann RD, et al.: Outcome of patients with intracranial non-germinomatous germ cell tumors-lessons from the SIOP-CNS-GCT-96 trial. *Neuro Oncol* 19 (12): 1661-1672, 2017. [PMC free article: PMC5716085] [PubMed: 29048505]
9. Fangusaro J, Wu S, MacDonald S, et al.: Phase II Trial of Response-Based Radiation Therapy for Patients With Localized CNS Nongerminomatous Germ Cell Tumors: A Children's Oncology Group Study. *J Clin Oncol* 37 (34): 3283-3290, 2019. [PMC free article: PMC6900864] [PubMed: 31545689]
10. Yagi K, Kageji T, Nagahiro S, et al.: Growing teratoma syndrome in a patient with a non-germinomatous germ

cell tumor in the neurohypophysis--case report. *Neurol Med Chir (Tokyo)* 44 (1): 33-7, 2004. [PubMed: 14959935]

11. Kim CY, Choi JW, Lee JY, et al.: Intracranial growing teratoma syndrome: clinical characteristics and treatment strategy. *J Neurooncol* 101 (1): 109-15, 2011. [PubMed: 20532955]
12. Oya S, Saito A, Okano A, et al.: The pathogenesis of intracranial growing teratoma syndrome: proliferation of tumor cells or formation of multiple expanding cysts? Two case reports and review of the literature. *Childs Nerv Syst* 30 (8): 1455-61, 2014. [PubMed: 24633581]

Treatment of Recurrent Childhood CNS Germ Cell Tumors

The most common type of relapse for childhood central nervous system (CNS) germ cell tumors (GCTs) is local recurrence at the primary tumor site; however, 30% of relapses are outside the primary site and/or combined with leptomeningeal spread. The outcome for patients with relapse, especially those with nongerminomatous germ cell tumors (NGGCTs), remains poor.

Treatment Options for Recurrent Childhood CNS GCTs

Treatment options for recurrent childhood CNS GCTs include the following:

1. Chemotherapy followed by additional radiation therapy.
2. High-dose chemotherapy with stem cell rescue with or without additional radiation therapy.

Patients with germinomas that were treated initially with chemotherapy only can benefit from chemotherapy followed by radiation therapy.[1,2] Reirradiation after chemotherapy at recurrence has been utilized.[2-4]

For pure germinoma patients who previously received radiation therapy, myeloablative chemotherapy with stem cell rescue has been used.[5,6] High-dose chemotherapy and autologous stem cell rescue may also have curative potential for a minority of patients with relapsed systemic NGGCTs.[4-8]

Enrollment on clinical trials should be considered for all patients with recurrent disease. Information about ongoing National Cancer Institute (NCI)-supported clinical trials is available from the [NCI website](#).

Treatment Options Under Clinical Evaluation for Recurrent Childhood CNS GCTs

Early-phase therapeutic trials may be available for selected patients. These trials may be available via the Children's Oncology Group (COG), the Pediatric Brain Tumor Consortium, or other entities. Information about NCI-supported clinical trials can be found on the [NCI website](#). For information about clinical trials sponsored by other organizations, refer to the [ClinicalTrials.gov website](#).

The following is an example of a national and/or institutional clinical trial that is currently being conducted:

- **APEC1621 (NCT03155620)** (Pediatric MATCH: Targeted Therapy Directed by Genetic Testing in Treating Pediatric Patients with Relapsed or Refractory Advanced Solid Tumors, Non-Hodgkin Lymphomas, or Histiocytic Disorders): NCI-COG Pediatric Molecular Analysis for Therapeutic Choice (MATCH), referred to as Pediatric MATCH, will match targeted agents with specific molecular changes identified using a next-generation sequencing targeted assay of more than 4,000 different mutations across more than 160 genes in refractory and recurrent solid tumors. Children and adolescents aged 1 to 21 years are eligible for the trial.

Tumor tissue from progressive or recurrent disease must be available for molecular characterization. Patients with tumors that have molecular variants addressed by treatment arms included in the trial will be offered treatment on Pediatric MATCH. Additional information can be obtained on the [NCI website](#) and [ClinicalTrials.gov website](#).

References

1. Merchant TE, Sherwood SH, Mulhern RK, et al.: CNS germinoma: disease control and long-term functional outcome for 12 children treated with craniospinal irradiation. *Int J Radiat Oncol Biol Phys* 46 (5): 1171-6, 2000. [PubMed: 10725628]
2. Sawamura Y, Ikeda JL, Tada M, et al.: Salvage therapy for recurrent germinomas in the central nervous system. *Br J Neurosurg* 13 (4): 376-81, 1999. [PubMed: 10616563]
3. Hu YW, Huang PI, Wong TT, et al.: Salvage treatment for recurrent intracranial germinoma after reduced-volume radiotherapy: a single-institution experience and review of the literature. *Int J Radiat Oncol Biol Phys* 84 (3): 639-47, 2012. [PubMed: 22361082]
4. Murray MJ, Bailey S, Heinemann K, et al.: Treatment and outcomes of UK and German patients with relapsed intracranial germ cell tumors following uniform first-line therapy. *Int J Cancer* 141 (3): 621-635, 2017. [PubMed: 28463397]
5. Siegert W, Beyer J, Strohscheer I, et al.: High-dose treatment with carboplatin, etoposide, and ifosfamide followed by autologous stem-cell transplantation in relapsed or refractory germ cell cancer: a phase I/II study. The German Testicular Cancer Cooperative Study Group. *J Clin Oncol* 12 (6): 1223-31, 1994. [PubMed: 7911158]
6. Modak S, Gardner S, Dunkel IJ, et al.: Thiotepa-based high-dose chemotherapy with autologous stem-cell rescue in patients with recurrent or progressive CNS germ cell tumors. *J Clin Oncol* 22 (10): 1934-43, 2004. [PubMed: 15143087]
7. Beyer J, Kramar A, Mandanas R, et al.: High-dose chemotherapy as salvage treatment in germ cell tumors: a multivariate analysis of prognostic variables. *J Clin Oncol* 14 (10): 2638-45, 1996. [PubMed: 8874322]
8. Motzer RJ, Mazumdar M, Bosl GJ, et al.: High-dose carboplatin, etoposide, and cyclophosphamide for patients with refractory germ cell tumors: treatment results and prognostic factors for survival and toxicity. *J Clin Oncol* 14 (4): 1098-105, 1996. [PubMed: 8648363]

Long-Term Effects of Childhood CNS Germ Cell Tumors

A significant proportion of children with central nervous system (CNS) germ cell tumors (GCTs) present with endocrinopathies, including diabetes insipidus and panhypopituitarism. In most cases, these endocrinopathies are permanent despite tumor control, and patients will need continuous hormone replacement therapy.[1,2]

Although significant improvements in the overall survival of patients with CNS GCTs have occurred, patients face significant late effects based on the location of the primary tumor and its treatment. Treatment-related late effects include the following:

- Each chemotherapeutic agent has its own characteristic long-term side effects.
- Radiation therapy to the areas commonly affected by GCTs is known to contribute to a decline in patient performance status, visual-field impairments, extraocular movement disturbances, endocrine disorders, learning disabilities, and stroke.[3-6]
- Second tumors have been identified in this population, some of which are thought to be related to previous irradiation.[7,8]

Current clinical trials and therapeutic approaches are directed at minimizing the long-term sequelae that result from the treatment of CNS GCTs.

Refer to the PDQ summary on [Late Effects of Treatment for Childhood Cancer](#) for specific information about the incidence, type, and monitoring of late effects in survivors of childhood and adolescent cancer.

References

1. Rosenblum MK, Matsutani M, Van Meir EG: CNS germ cell tumours. In: Kleihues P, Cavenee WK, eds.: Pathology and Genetics of Tumours of the Nervous System. Lyon, France: International Agency for Research on Cancer, 2000, pp 208-14.
2. Hoffman HJ, Otsubo H, Hendrick EB, et al.: Intracranial germ-cell tumors in children. *J Neurosurg* 74 (4): 545-51, 1991. [PubMed: 1848284]
3. Osuka S, Tsuboi K, Takano S, et al.: Long-term outcome of patients with intracranial germinoma. *J Neurooncol* 83 (1): 71-9, 2007. [PubMed: 17245622]
4. Balmaceda C, Finlay J: Current advances in the diagnosis and management of intracranial germ cell tumors. *Curr Neurol Neurosci Rep* 4 (3): 253-62, 2004. [PubMed: 15102352]
5. Odagiri K, Omura M, Hata M, et al.: Treatment outcomes, growth height, and neuroendocrine functions in patients with intracranial germ cell tumors treated with chemoradiation therapy. *Int J Radiat Oncol Biol Phys* 84 (3): 632-8, 2012. [PubMed: 22420962]
6. Liang SY, Yang TF, Chen YW, et al.: Neuropsychological functions and quality of life in survived patients with intracranial germ cell tumors after treatment. *Neuro Oncol* 15 (11): 1543-51, 2013. [PMC free article: PMC3813422] [PubMed: 24101738]
7. Acharya S, DeWees T, Shinohara ET, et al.: Long-term outcomes and late effects for childhood and young adulthood intracranial germinomas. *Neuro Oncol* 17 (5): 741-6, 2015. [PMC free article: PMC4482856] [PubMed: 25422317]
8. Jabbour SK, Zhang Z, Arnold D, et al.: Risk of second tumor in intracranial germinoma patients treated with radiation therapy: the Johns Hopkins experience. *J Neurooncol* 91 (2): 227-32, 2009. [PubMed: 18813873]

Current Clinical Trials

Use our [advanced clinical trial search](#) to find NCI-supported cancer clinical trials that are now enrolling patients. The search can be narrowed by location of the trial, type of treatment, name of the drug, and other criteria. [General information](#) about clinical trials is also available.

Changes to This Summary (08/07/2020)

The PDQ cancer information summaries are reviewed regularly and updated as new information becomes available. This section describes the latest changes made to this summary as of the date above.

Treatment of Newly Diagnosed Childhood Central Nervous System (CNS) Nongerminomatous Germ Cell Tumors (NGGCTs)

Added text about the results of the Children's Oncology Group ACNS1123 phase II trial that evaluated the omission of craniospinal irradiation and the efficacy of dose- and volume-reduced radiation therapy for patients with CNS NGGCTs who obtained complete responses or partial responses and marker normalization after six cycles of chemotherapy (cited Fangusaro et al. as reference 9).

This summary is written and maintained by the PDQ Pediatric Treatment Editorial Board, which is editorially independent of NCI. The summary reflects an independent review of the literature and does not represent a policy statement of NCI or NIH. More information about summary policies and the role of the PDQ Editorial Boards in maintaining the PDQ summaries can be found on the [About This PDQ Summary](#) and [PDQ® - NCI's Comprehensive Cancer Database](#) pages.

About This PDQ Summary

Purpose of This Summary

This PDQ cancer information summary for health professionals provides comprehensive, peer-reviewed, evidence-based information about the treatment of childhood central nervous system germ cell tumors. It is intended as a

resource to inform and assist clinicians who care for cancer patients. It does not provide formal guidelines or recommendations for making health care decisions.

Reviewers and Updates

This summary is reviewed regularly and updated as necessary by the PDQ Pediatric Treatment Editorial Board, which is editorially independent of the National Cancer Institute (NCI). The summary reflects an independent review of the literature and does not represent a policy statement of NCI or the National Institutes of Health (NIH).

Board members review recently published articles each month to determine whether an article should:

- be discussed at a meeting,
- be cited with text, or
- replace or update an existing article that is already cited.

Changes to the summaries are made through a consensus process in which Board members evaluate the strength of the evidence in the published articles and determine how the article should be included in the summary.

The lead reviewers for Childhood Central Nervous System Germ Cell Tumors Treatment are:

- Kenneth J. Cohen, MD, MBA (Sidney Kimmel Comprehensive Cancer Center at Johns Hopkins Hospital)
- Karen J. Marcus, MD, FACR (Dana-Farber Cancer Institute/Boston Children's Hospital)
- Roger J. Packer, MD (Children's National Health System)
- D. Williams Parsons, MD, PhD
- Malcolm A. Smith, MD, PhD (National Cancer Institute)

Any comments or questions about the summary content should be submitted to Cancer.gov through the NCI website's [Email Us](#). Do not contact the individual Board Members with questions or comments about the summaries. Board members will not respond to individual inquiries.

Levels of Evidence

Some of the reference citations in this summary are accompanied by a level-of-evidence designation. These designations are intended to help readers assess the strength of the evidence supporting the use of specific interventions or approaches. The PDQ Pediatric Treatment Editorial Board uses a [formal evidence ranking system](#) in developing its level-of-evidence designations.

Permission to Use This Summary

PDQ is a registered trademark. Although the content of PDQ documents can be used freely as text, it cannot be identified as an NCI PDQ cancer information summary unless it is presented in its entirety and is regularly updated. However, an author would be permitted to write a sentence such as “NCI’s PDQ cancer information summary about breast cancer prevention states the risks succinctly: [include excerpt from the summary].”

The preferred citation for this PDQ summary is:

PDQ® Pediatric Treatment Editorial Board. PDQ Childhood Central Nervous System Germ Cell Tumors Treatment. Bethesda, MD: National Cancer Institute. Updated <MM/DD/YYYY>. Available at: <https://www.cancer.gov/types/brain/hp/child-cns-germ-cell-treatment-pdq>. Accessed <MM/DD/YYYY>. [PMID: 26389498]

Images in this summary are used with permission of the author(s), artist, and/or publisher for use within the PDQ

summaries only. Permission to use images outside the context of PDQ information must be obtained from the owner(s) and cannot be granted by the National Cancer Institute. Information about using the illustrations in this summary, along with many other cancer-related images, is available in [Visuals Online](#), a collection of over 2,000 scientific images.

Disclaimer

Based on the strength of the available evidence, treatment options may be described as either “standard” or “under clinical evaluation.” These classifications should not be used as a basis for insurance reimbursement determinations. More information on insurance coverage is available on Cancer.gov on the [Managing Cancer Care](#) page.

Contact Us

More information about contacting us or receiving help with the Cancer.gov website can be found on our [Contact Us](#) for Help page. Questions can also be submitted to Cancer.gov through the website’s [Email Us](#).

Copyright Notice

Bookshelf ID: NBK82800 PMID: 26389498