

NCBI Bookshelf. A service of the National Library of Medicine, National Institutes of Health.

PDQ Cancer Information Summaries [Internet]. Bethesda (MD): National Cancer Institute (US); 2002-.

Childhood Medulloblastoma and Other Central Nervous System Embryonal Tumors Treatment (PDQ®)

Health Professional Version

Authors

PDQ Pediatric Treatment Editorial Board.

Published online: October 5, 2020.

Created: February 13, 2008.

This PDQ cancer information summary for health professionals provides comprehensive, peer-reviewed, evidence-based information about the treatment of childhood medulloblastoma and other central nervous system embryonal tumors. It is intended as a resource to inform and assist clinicians who care for cancer patients. It does not provide formal guidelines or recommendations for making health care decisions.

This summary is reviewed regularly and updated as necessary by the PDQ Pediatric Treatment Editorial Board, which is editorially independent of the National Cancer Institute (NCI). The summary reflects an independent review of the literature and does not represent a policy statement of NCI or the National Institutes of Health (NIH).

General Information About Medulloblastoma and Other Central Nervous System (CNS) Embryonal Tumors

World Health Organization (WHO) Classification for CNS Embryonal Tumors and Pineoblastoma

Embryonal tumors are a collection of biologically heterogeneous lesions that share the tendency to disseminate throughout the nervous system via cerebrospinal fluid (CSF) pathways. Although there is significant variability, histologically these tumors are grouped together because they are at least partially composed of hyperchromatic cells (blue cell tumors on standard staining) with little cytoplasm, which are densely packed and demonstrate a high degree of mitotic activity. Other histologic and immunohistochemical features, such as the degree of apparent cellular transformation along identifiable cell lineages (ependymal, glial, etc.), can be used to separate these tumors to some degree. However, a convention, which has been accepted by the WHO, also separates these tumors on the basis of presumed location of origin within the central nervous system (CNS). Molecular studies have substantiated the differences between tumors arising in different areas of the brain and give partial credence to this classification approach.[1]

As of 2016, the WHO has proposed an integrated phenotypic and genotypic classification system for CNS tumors in which diagnoses are *layered* with

WHO grade, histologic classification, and molecular classification.[2] The term *primitive neuroectodermal tumor (PNET)* has been removed from the newest WHO diagnostic lexicon, although some rare entities (e.g., medulloepithelioma) have remained. A molecularly distinct entity, embryonal tumor with multilayered rosettes (ETMR), *C19MC*-altered, has been added, encompassing embryonal tumor with abundant neuropil and true rosettes (ETANTR), ependymoblastoma, and medulloepithelioma. The WHO classification will be updated as other molecularly distinct entities are defined.

The pathologic diagnosis of embryonal tumors is based primarily on histological and immunohistological microscopic features. However, molecular genetic studies are employed increasingly to subclassify embryonal tumors. These molecular genetic findings are also being utilized for risk stratification and treatment planning.[3-6]

The 2016 WHO categorization of embryonal tumors is as follows:[2]

- Medulloblastoma, genetically defined.
 - Medulloblastoma, WNT-activated.
 - Medulloblastoma, sonic hedgehog (SHH)-activated and *TP53*-mutant.
 - Medulloblastoma, SHH-activated and *TP53*-wild-type.
 - Medulloblastoma, non-WNT/non-SHH.
 - Medulloblastoma, group 3.
 - Medulloblastoma, group 4.
- Medulloblastoma, histologically defined.
 - Medulloblastoma, classic.
 - Medulloblastoma, desmoplastic/nodular.
 - Medulloblastoma with extensive nodularity (MBEN).
 - Medulloblastoma, large cell/anaplastic.
- Medulloblastoma, not otherwise specified (NOS).
- ETMR, *C19MC*-altered.

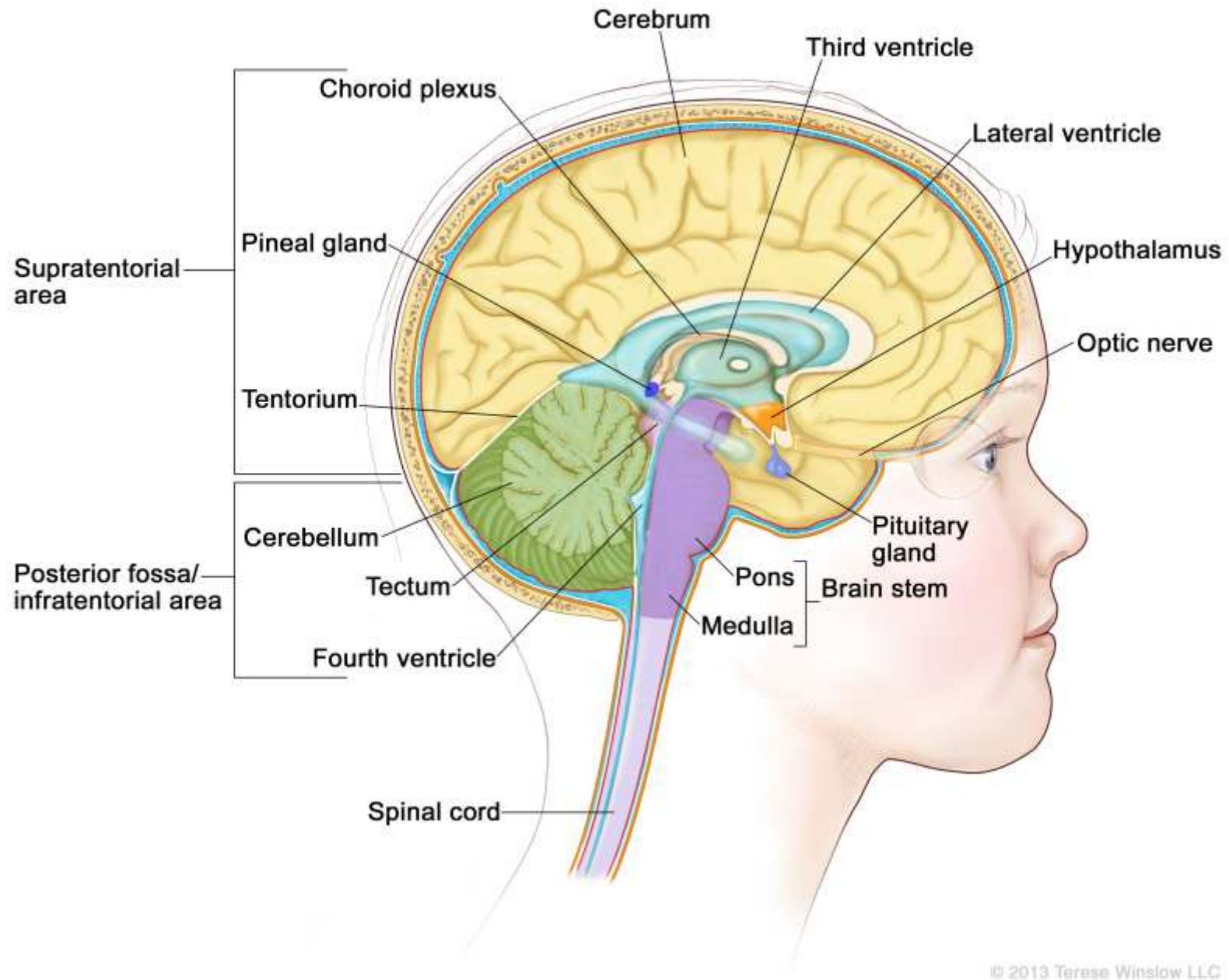
- ETMR, NOS.
- Medulloepithelioma.
- CNS neuroblastoma.
- CNS ganglioneuroblastoma.
- CNS embryonal tumor, NOS.
- CNS atypical teratoid/rhabdoid tumor. (Refer to the PDQ summary on [Childhood Central Nervous System Atypical Teratoid/Rhabdoid Tumor Treatment](#) for more information about CNS atypical teratoid/rhabdoid tumors.)
- CNS embryonal tumor with rhabdoid features.

Pineoblastoma, which in the past was conventionally grouped with embryonal tumors, is categorized by the WHO as a pineal parenchymal tumor. Given that therapies for pineoblastomas are quite similar to those utilized for embryonal tumors, pineoblastomas are discussed in this summary. A somewhat closely aligned tumor, pineal parenchymal tumor of intermediate differentiation, has been identified but is not considered an embryonal tumor and primarily arises in adults.[2]

Anatomy



Anatomy of the Brain (Medial)



© 2013 Terese Winslow LLC

Figure 1. Anatomy of the inside of the brain, showing the pineal and pituitary glands, optic nerve, ventricles (with cerebrospinal fluid shown in blue), and other parts of the brain. The posterior fossa is the region below the tentorium, which separates the cortex from the cerebellum and essentially denotes the region containing the brain stem, cerebellum, and fourth ventricle.

Incidence

Embryonal tumors comprise 20% to 25% of primary CNS tumors (malignant brain tumors and pilocytic astrocytomas) arising in children. These tumors occur along the pediatric age spectrum but tend to cluster early in life. The incidence of embryonal tumors in children aged 1 to 9 years is fivefold to tenfold higher than is the incidence of embryonal tumors in adults (refer to [Table 1](#)).^[7,8]

Table 1. Annual Incidence Rates for Childhood Central Nervous System Embryonal Tumors According to Age^a

Age Group (y)	Annual Incidence Rate (Cases per 1 Million)
<5	11
5–9	7
10–19	3–4

^aSource: Childhood cancer by the International Classification of Childhood Cancer ^[7] and Smoll et al.^[8]

Medulloblastomas comprise the vast majority of pediatric embryonal tumors and by definition arise in the posterior fossa (refer to [Figure 1](#)), where they constitute approximately 40% of all posterior fossa tumors. Other forms of embryonal tumors each make up 2% or less of all childhood brain tumors.

Diagnostic and Staging Evaluation

Imaging studies and CSF analysis are included in the diagnostic and staging evaluation.

Imaging studies

Diagnosis is usually readily made by either magnetic resonance imaging (MRI) or computed tomography (CT) scan. MRI is preferable because the anatomic relationship between the tumor and surrounding brain and tumor dissemination is better visualized with this method.^[9]

After diagnosis, evaluation of embryonal tumors is quite similar, essentially independent of the histologic subtype and the location of the tumor. Given the tendency of these tumors to disseminate throughout the CNS early in the course of illness, imaging evaluation of the neuraxis by means of MRI of

the entire brain and spine is indicated. Preferably, this is done before surgery to avoid postoperative artifacts, especially blood. Such imaging can be difficult to interpret and must be performed in at least two planes, with and without the use of contrast enhancement (gadolinium).[10] A study of the significance of equivocal findings on spinal MRIs in children with medulloblastoma identified equivocal findings in 48 of 100 patients (48%). The study reported the following results:

- Of the 48 patients with equivocal findings, 45 had preoperative MRI scans.
- Analysis by subgroup identified a higher proportion of equivocal findings in the SHH subgroup ($P = .007$).
- Five-year overall survival (OS) in children with equivocal findings (80%) was not different from 5-year OS in patients who had normal MRI findings (84.8%), while OS in patients with M3 metastases was worse (54.7%) ($P = .02$).[11]

However, in a paper describing the experience in patients without metastatic disease at diagnosis treated with 23.4 Gy of craniospinal radiation therapy, equivocal findings were associated with poorer event-free survival (EFS) and OS.[10] Consensus guidelines for timing and neuroimaging techniques have been suggested, including preoperative assessment of the entire neuroaxis and postoperative assessment of amount of residual disease.[12]

After surgery, imaging of the primary tumor site is indicated to determine the extent of residual disease.

CSF analysis

After surgery, lumbar CSF analysis is performed, if deemed safe. Neuroimaging and CSF evaluation are considered complementary because as many as 10% of patients will have evidence of free-floating tumor cells in the CSF without clear evidence of leptomeningeal disease on MRI scan.[13]

CSF analysis is conventionally done 14 to 21 days after surgery. If CSF is obtained within 14 days of the operation, detection of tumor cells within the spinal fluid is possibly related to the surgical procedure. In most staging systems, if fluid is obtained in the first few days after surgery and found to be positive for tumor cells, the positivity must be confirmed by a subsequent spinal tap to be considered diagnostically significant. When obtainment of fluid by lumbar spinal tap is deemed unsafe, ventricular fluid can be obtained; however, this method may not be as sensitive as lumbar fluid assessment.[13]

Because embryonal tumors are very rarely metastatic to the bone, bone marrow, or other body sites at the time of diagnosis, studies such as bone marrow aspirates, chest x-rays, or bone scans are not indicated, unless there are symptoms or signs suggesting organ involvement.

Prognostic Factors

Various clinical and biologic parameters have been shown to be associated with the likelihood of disease control of embryonal tumors after treatment.[4]

The significance of many of these factors have been shown to be predictive for medulloblastomas, although some are used to assign risk, to some degree, for other embryonal tumors. Parameters that are most frequently utilized to predict outcome include the following:[14,15]

- Extent of CNS disease at diagnosis.
- Age at diagnosis.
- Amount of residual disease after definitive surgery.
- Tumor histopathology.
- Biological/molecular tumor cell characteristics.

It has become increasingly clear, especially for medulloblastomas, that outcome is also related to the molecular characteristics of the tumor, but this has not been definitively shown for other embryonal tumors.[1,5,6,16-18] OS rates range from 40% to 90%, depending on the molecular subtype of the medulloblastoma and possibly other factors, such as extent of dissemination at time of diagnosis and degree of resection. Children with medulloblastoma who survive for 5 years are considered cured of their tumor. Survival rates for other embryonal tumors are generally poorer, ranging from less than 5% to 50%; specific survival rates are discussed within each subgroup in the summary.[19-22]

In older studies, the presence of brain stem involvement in children with medulloblastoma was found to be a prognostic factor; it has not been found to be of predictive value in subsequent studies utilizing both radiation and chemotherapy.[10,14]

An accurate diagnosis is a critical issue for patients with embryonal tumors. For example, in the ACNS0332 (NCT00392327) trial that enrolled 80 patients with high-risk medulloblastoma, supratentorial CNS-PNET tumors, and pineoblastoma, 60 patients had sufficient tissue for evaluation. Thirty-one tumors were nonpineal in location, 22 (71%) of which represented tumors that were not intended for trial inclusion, including 18 high-grade gliomas, 2 atypical teratoid/rhabdoid tumors, and 2 ependymomas. Outcomes across tumor types were strikingly different. Patients with supratentorial embryonal tumors/pineoblastomas exhibited a 5-year EFS of 62.8% (95% confidence interval [CI], 43.4%–82.2%) and OS of 78.5% (95% CI, 62.2%–94.8%), whereas patients with molecularly classified high-grade gliomas had an EFS of 5.6% (95% CI, 0%–13%) and OS of 12% (95% CI, 0%–24.7%). Survival rates for patients with high-grade gliomas were similar to those of patients who were enrolled in historic studies that avoided craniospinal irradiation and intensive chemotherapy. Thus, for patients with CNS-PNET/pineoblastoma, prognosis is considerably better than previously assumed when molecularly confirmed high-grade gliomas are removed.[23]

Prognosis is poor for patients with medulloepithelioma and ETMR, with 5-year survival rates ranging between 0% and 30%.[24-26] In a retrospective multivariate analysis of 38 patients, total or near-total resection, the use of radiation therapy, and the use of high-dose chemotherapy were associated with an improved prognosis.[27][Level of evidence: 3iA]

Extent of CNS disease at diagnosis

Patients with disseminated CNS disease at diagnosis are at highest risk of disease relapse.[13-15] Ten percent to 40% of patients with medulloblastoma have CNS dissemination at diagnosis, with infants having the highest incidence and adolescents and adults having the lowest incidence.

Nonmedulloblastoma embryonal tumors and pineoblastomas may also be disseminated at the time of diagnosis, although the incidence of dissemination may be somewhat less than that of medulloblastomas, with dissemination at diagnosis being documented in approximately 10% to 20% of patients. [19,20] Patients with nonmedulloblastoma embryonal tumors and pineoblastomas who have disseminated disease at the time of diagnosis have a poor OS, with reported survival rates at 5 years ranging from 10% to 30%.[19-22]

Age at diagnosis

Age younger than 3 years at diagnosis (except for desmoplastic medulloblastoma/MBEN) portends an unfavorable outcome for those with medulloblastoma and, possibly, other embryonal tumors.[28-32]

Amount of residual disease after definitive surgery

As a predictor of outcome, postoperative MRI measurement of the amount of residual disease after definitive surgery has been supplanted by extent of resection after surgery.[10]

In older studies, the extent of resection for medulloblastomas was found to be related to survival.[14,15,33,34] A Hirntumor and International Society of Paediatric Oncology (HIT-SIOP) study of 340 children reported that residual disease ($>1.5 \text{ cm}^2$) connoted a poorer 5-year EFS.[35] Extent of resection after surgery is still used to separate patients into risk groups, with patients having more than 1.5 cm^2 of residual disease stratified into high-risk groups, with intensification of craniospinal irradiation to 36 Gy.

An international, retrospective, collaborative study included 787 patients of all ages with medulloblastoma who were treated in a variety of ways and incorporated molecular subgrouping and clinical factors in the analysis. The multivariate analysis found that subtotal resection ($>1.5 \text{ cm}^2$ residual), but not near-total resection ($<1.5 \text{ cm}^2$ residual), was associated with inferior progression-free survival compared with gross-total resection. This study suggested that attempts to completely remove the tumor, especially when the likelihood of neurological morbidity is high, are not warranted because there appears to be little or no benefit to gross-total resection when compared with near-total resection. It gives some credence to the present approach in which patients with more than 1.5 cm^2 of disease are considered higher-risk patients.[36] Prospective studies are needed to better define the impact of extent of resection on outcome within molecularly defined subgroups.

In patients with other forms of embryonal tumors, the extent of resection has not been definitively shown to impact survival.[21] However, in a Children's Oncology Group study of 66 children with supratentorial embryonal tumors, extent of resection was found to be prognostic for those with

localized disease at the time of diagnosis.[37]

Tumor histopathology

For medulloblastomas, histopathologic features such as large cell variant, anaplasia, and desmoplasia have been shown in retrospective analyses to correlate with outcome.[29,38,39] In prospective studies, immunohistochemical and histopathologic findings have not predicted outcome in children older than 3 years at diagnosis, with the exception of the large cell/anaplastic variant, which has been associated with poorer prognosis.[10,18,40] Several studies have observed that the histologic finding of desmoplasia, seen in patients aged 3 years and younger with desmoplastic medulloblastoma, especially MBEN, connotes a significantly better prognosis compared with outcomes for infants and young children with classic or large cell/anaplastic medulloblastoma.[18,28-30,41]; [31][Level of evidence: 2A]

For other embryonal tumors, histologic variations have not been associated with differing outcome.

Biological/molecular tumor cell characteristics

Genomic analyses (including RNA gene expression and DNA methylation profiles, as well as DNA sequencing to identify mutations) on both fresh-frozen and formalin-fixed, paraffin-embedded sections have identified molecular subtypes of medulloblastoma.[3-6,16,17,42-49] These subtypes include those characterized by WNT pathway activation and SHH pathway activation, as well as additional subgroups characterized by MYC or MYCN alterations and other genomic alterations.[3-6,16,17,42-48] Children with medulloblastoma whose tumors show WNT pathway activation usually have an excellent prognosis, while patients with SHH pathway-activated tumors have a prognosis that is influenced by the presence or absence of *TP53* mutations (favorable vs. unfavorable prognosis, respectively).[50] The outcome for the remaining patients is less favorable than that for patients with WNT pathway activation. Mutations in medulloblastoma are observed in a subtype-specific manner, with *CTNNB1* mutations observed in the WNT subtype and with *PTCH1*, *SMO*, and *SUFU* mutations observed in the SHH subtype. The prognostic significance of recurring mutations is closely aligned with that of the molecular subtype with which they are associated.[4,51] At recurrence, the subtype remains unchanged from the original molecular subtype at diagnosis.[52]

Refer to the [Molecular subtypes of medulloblastoma](#) section of this summary for more information about the subtypes of medulloblastoma and the prognostic significance of specific molecular alterations.

For nonmedulloblastoma embryonal tumors, integrative genomic analysis has also identified molecular subtypes with different outcomes. (Refer to the [Subtypes of nonmedulloblastoma embryonal tumors](#) section of this summary for more detailed information.)

Follow-up After Treatment

Relapse in children with embryonal tumors is most likely to occur within the first 18 months of diagnosis.[35,53] Surveillance imaging of the brain and

spine is usually undertaken at routine intervals during and after treatment (refer to [Table 2](#)). The frequency of such imaging, designed to detect recurrent disease at an early, asymptomatic state, has been arbitrarily determined and has not been shown to clearly influence survival.[\[54-57\]](#) Growth hormone replacement therapy has not been shown to increase the likelihood of disease relapse.[\[30\]](#)

Table 2. Surveillance Testing During and After Treatment for Medulloblastoma and Other Central Nervous System Embryonal Tumors

Surveillance Period	Frequency of Visits During Surveillance Period	Testing
First 3 years after diagnosis	Every 3 months	Physical exam
		Imaging of the brain every 3 months for the first 3 years, then every 6 months for the ensuing 2 years, and then as per preference of the treating physician or per protocol; MRI of the spine every 3 months for the first 2 years, then every 6 months for 1 year, and then as per preference of the treating physician or per protocol ^a
		Endocrinology evaluation once a year
		Neuropsychologic testing every 1–2 years
3–5 years after diagnosis	Every 6 months	Physical exam
		Imaging of the brain and spine once a year
		Endocrinology evaluation once a year
		Neuropsychologic testing every 1–2 years
More than 5 years after diagnosis	Once a year	Physical exam
		Imaging of the brain once a year
		Endocrinology evaluation once a year
		Neuropsychologic testing every 1–2 years (optional)

MRI = magnetic resonance imaging.

^aFor pineoblastoma, continue spinal evaluations every 6 months until 5 years from diagnosis. Although these suggestions are based on a small sample size, there is evidence for

continuing surveillance testing of the spine until 5 years after diagnosis.[58]

Childhood and adolescent cancer survivors require close monitoring because cancer therapy side effects may persist or develop months or years after treatment. (Refer to the PDQ summary on [Late Effects of Treatment for Childhood Cancer](#) for specific information about the incidence, type, and monitoring of late effects in childhood and adolescent cancer survivors.)

References

1. Pomeroy SL, Tamayo P, Gaasenbeek M, et al.: Prediction of central nervous system embryonal tumour outcome based on gene expression. *Nature* 415 (6870): 436-42, 2002. [PubMed: 11807556]
2. Louis DN, Perry A, Reifenberger G, et al.: The 2016 World Health Organization Classification of Tumors of the Central Nervous System: a summary. *Acta Neuropathol* 131 (6): 803-20, 2016. [PubMed: 27157931]
3. Pfister S, Remke M, Benner A, et al.: Outcome prediction in pediatric medulloblastoma based on DNA copy-number aberrations of chromosomes 6q and 17q and the MYC and MYCN loci. *J Clin Oncol* 27 (10): 1627-36, 2009. [PubMed: 19255330]
4. Taylor MD, Northcott PA, Korshunov A, et al.: Molecular subgroups of medulloblastoma: the current consensus. *Acta Neuropathol* 123 (4): 465-72, 2012. [PMC free article: PMC3306779] [PubMed: 22134537]
5. Kool M, Koster J, Bunt J, et al.: Integrated genomics identifies five medulloblastoma subtypes with distinct genetic profiles, pathway signatures and clinicopathological features. *PLoS One* 3 (8): e3088, 2008. [PMC free article: PMC2518524] [PubMed: 18769486]
6. Ellison DW, Onilude OE, Lindsey JC, et al.: beta-Catenin status predicts a favorable outcome in childhood medulloblastoma: the United Kingdom Children's Cancer Study Group Brain Tumour Committee. *J Clin Oncol* 23 (31): 7951-7, 2005. [PubMed: 16258095]
7. Childhood cancer by the ICCC. In: Howlader N, Noone AM, Krapcho M, et al., eds.: *SEER Cancer Statistics Review, 1975-2009 (Vintage 2009 Populations)*. Bethesda, Md: National Cancer Institute, 2012, Section 29. Also available online. Last accessed August 05, 2020.
8. Smoll NR, Drummond KJ: The incidence of medulloblastomas and primitive neuroectodermal tumours in adults and children. *J Clin Neurosci* 19 (11): 1541-4, 2012. [PubMed: 22981874]
9. Chintagumpala MM, Paulino A, Panigrahy A, et al.: Embryonal and pineal region tumors. In: Pizzo PA, Poplack DG, eds.: *Principles and Practice of Pediatric Oncology*. 7th ed. Philadelphia, Pa: Lippincott Williams and Wilkins, 2015, pp 671-99.
10. Packer RJ, Gajjar A, Vezina G, et al.: Phase III study of craniospinal radiation therapy followed by adjuvant chemotherapy for newly diagnosed average-risk medulloblastoma. *J Clin Oncol* 24 (25): 4202-8, 2006. [PubMed: 16943538]
11. Bennett J, Ashmawy R, Ramaswamy V, et al.: The clinical significance of equivocal findings on spinal MRI in children with medulloblastoma. *Pediatr Blood Cancer* 64 (8): , 2017. [PubMed: 28205381]
12. Warren KE, Vezina G, Poussaint TY, et al.: Response assessment in medulloblastoma and leptomeningeal seeding tumors: recommendations from the Response Assessment in Pediatric Neuro-Oncology committee. *Neuro Oncol* 20 (1): 13-23, 2018. [PMC free article: PMC5761545] [PubMed:]

28449033]

13. Fouladi M, Gajjar A, Boyett JM, et al.: Comparison of CSF cytology and spinal magnetic resonance imaging in the detection of leptomeningeal disease in pediatric medulloblastoma or primitive neuroectodermal tumor. *J Clin Oncol* 17 (10): 3234-7, 1999. [PubMed: 10506624]
14. Zeltzer PM, Boyett JM, Finlay JL, et al.: Metastasis stage, adjuvant treatment, and residual tumor are prognostic factors for medulloblastoma in children: conclusions from the Children's Cancer Group 921 randomized phase III study. *J Clin Oncol* 17 (3): 832-45, 1999. [PubMed: 10071274]
15. Yao MS, Mehta MP, Boyett JM, et al.: The effect of M-stage on patterns of failure in posterior fossa primitive neuroectodermal tumors treated on CCG-921: a phase III study in a high-risk patient population. *Int J Radiat Oncol Biol Phys* 38 (3): 469-76, 1997. [PubMed: 9231668]
16. Thompson MC, Fuller C, Hogg TL, et al.: Genomics identifies medulloblastoma subgroups that are enriched for specific genetic alterations. *J Clin Oncol* 24 (12): 1924-31, 2006. [PubMed: 16567768]
17. Northcott PA, Korshunov A, Witt H, et al.: Medulloblastoma comprises four distinct molecular variants. *J Clin Oncol* 29 (11): 1408-14, 2011. [PMC free article: PMC4874239] [PubMed: 20823417]
18. Rutkowski S, von Hoff K, Emser A, et al.: Survival and prognostic factors of early childhood medulloblastoma: an international meta-analysis. *J Clin Oncol* 28 (33): 4961-8, 2010. [PubMed: 20940197]
19. Cohen BH, Zeltzer PM, Boyett JM, et al.: Prognostic factors and treatment results for supratentorial primitive neuroectodermal tumors in children using radiation and chemotherapy: a Children's Cancer Group randomized trial. *J Clin Oncol* 13 (7): 1687-96, 1995. [PubMed: 7602359]
20. Reddy AT, Janss AJ, Phillips PC, et al.: Outcome for children with supratentorial primitive neuroectodermal tumors treated with surgery, radiation, and chemotherapy. *Cancer* 88 (9): 2189-93, 2000. [PubMed: 10813733]
21. Timmermann B, Kortmann RD, Köhl J, et al.: Role of radiotherapy in the treatment of supratentorial primitive neuroectodermal tumors in childhood: results of the prospective German brain tumor trials HIT 88/89 and 91. *J Clin Oncol* 20 (3): 842-9, 2002. [PubMed: 11821469]
22. Jakacki RI, Zeltzer PM, Boyett JM, et al.: Survival and prognostic factors following radiation and/or chemotherapy for primitive neuroectodermal tumors of the pineal region in infants and children: a report of the Children's Cancer Group. *J Clin Oncol* 13 (6): 1377-83, 1995. [PubMed: 7751882]
23. Hwang EI, Kool M, Burger PC, et al.: Extensive Molecular and Clinical Heterogeneity in Patients With Histologically Diagnosed CNS-PNET Treated as a Single Entity: A Report From the Children's Oncology Group Randomized ACNS0332 Trial. *J Clin Oncol* : JCO2017764720, 2018. [PubMed: 30332335]
24. Louis DN, Ohgaki H, Wiestler OD, et al.: The 2007 WHO classification of tumours of the central nervous system. *Acta Neuropathol* 114 (2): 97-109, 2007. [PMC free article: PMC1929165] [PubMed: 17618441]
25. Sharma MC, Mahapatra AK, Gaikwad S, et al.: Pigmented medulloepithelioma: report of a case and review of the literature. *Childs Nerv Syst* 14 (1-2): 74-8, 1998 Jan-Feb. [PubMed: 9548346]
26. Müller K, Zwiener I, Welker H, et al.: Curative treatment for central nervous system medulloepithelioma despite residual disease after resection. Report of two cases treated according to the GPHO Protocol HIT 2000 and review of the literature. *Strahlenther Onkol* 187 (11): 757-62, 2011.

- [PubMed: 22037651]
27. Horwitz M, Dufour C, Leblond P, et al.: Embryonal tumors with multilayered rosettes in children: the SFCE experience. *Childs Nerv Syst* 32 (2): 299-305, 2016. [PubMed: 26438544]
 28. Leary SE, Zhou T, Holmes E, et al.: Histology predicts a favorable outcome in young children with desmoplastic medulloblastoma: a report from the children's oncology group. *Cancer* 117 (14): 3262-7, 2011. [PMC free article: PMC3119763] [PubMed: 21246528]
 29. Giangaspero F, Perilongo G, Fondelli MP, et al.: Medulloblastoma with extensive nodularity: a variant with favorable prognosis. *J Neurosurg* 91 (6): 971-7, 1999. [PubMed: 10584843]
 30. von Bueren AO, von Hoff K, Pietsch T, et al.: Treatment of young children with localized medulloblastoma by chemotherapy alone: results of the prospective, multicenter trial HIT 2000 confirming the prognostic impact of histology. *Neuro Oncol* 13 (6): 669-79, 2011. [PMC free article: PMC3107096] [PubMed: 21636711]
 31. Rutkowski S, Gerber NU, von Hoff K, et al.: Treatment of early childhood medulloblastoma by postoperative chemotherapy and deferred radiotherapy. *Neuro Oncol* 11 (2): 201-10, 2009. [PMC free article: PMC2718992] [PubMed: 18818397]
 32. Rutkowski S, Bode U, Deinlein F, et al.: Treatment of early childhood medulloblastoma by postoperative chemotherapy alone. *N Engl J Med* 352 (10): 978-86, 2005. [PubMed: 15758008]
 33. Albright AL, Wisoff JH, Zeltzer PM, et al.: Effects of medulloblastoma resections on outcome in children: a report from the Children's Cancer Group. *Neurosurgery* 38 (2): 265-71, 1996. [PubMed: 8869053]
 34. Taylor RE, Bailey CC, Robinson K, et al.: Results of a randomized study of preradiation chemotherapy versus radiotherapy alone for nonmetastatic medulloblastoma: The International Society of Paediatric Oncology/United Kingdom Children's Cancer Study Group PNET-3 Study. *J Clin Oncol* 21 (8): 1581-91, 2003. [PubMed: 12697884]
 35. Lannering B, Rutkowski S, Doz F, et al.: Hyperfractionated versus conventional radiotherapy followed by chemotherapy in standard-risk medulloblastoma: results from the randomized multicenter HIT-SIOP PNET 4 trial. *J Clin Oncol* 30 (26): 3187-93, 2012. [PubMed: 22851561]
 36. Thompson EM, Hielscher T, Bouffet E, et al.: Prognostic value of medulloblastoma extent of resection after accounting for molecular subgroup: a retrospective integrated clinical and molecular analysis. *Lancet Oncol* 17 (4): 484-95, 2016. [PMC free article: PMC4907853] [PubMed: 26976201]
 37. Jakacki RI, Burger PC, Kocak M, et al.: Outcome and prognostic factors for children with supratentorial primitive neuroectodermal tumors treated with carboplatin during radiotherapy: a report from the Children's Oncology Group. *Pediatr Blood Cancer* 62 (5): 776-83, 2015. [PMC free article: PMC4376578] [PubMed: 25704363]
 38. McManamy CS, Lamont JM, Taylor RE, et al.: Morphophenotypic variation predicts clinical behavior in childhood non-desmoplastic medulloblastomas. *J Neuropathol Exp Neurol* 62 (6): 627-32, 2003. [PubMed: 12834107]
 39. Massimino M, Antonelli M, Gandola L, et al.: Histological variants of medulloblastoma are the most powerful clinical prognostic indicators. *Pediatr Blood Cancer* 60 (2): 210-6, 2013. [PubMed: 22693015]

40. Eberhart CG, Kratz J, Wang Y, et al.: Histopathological and molecular prognostic markers in medulloblastoma: c-myc, N-myc, TrkC, and anaplasia. *J Neuropathol Exp Neurol* 63 (5): 441-9, 2004. [PubMed: 15198123]
41. Garrè ML, Cama A, Bagnasco F, et al.: Medulloblastoma variants: age-dependent occurrence and relation to Gorlin syndrome--a new clinical perspective. *Clin Cancer Res* 15 (7): 2463-71, 2009. [PubMed: 19276247]
42. Tabori U, Baskin B, Shago M, et al.: Universal poor survival in children with medulloblastoma harboring somatic TP53 mutations. *J Clin Oncol* 28 (8): 1345-50, 2010. [PubMed: 20142599]
43. Onvani S, Etame AB, Smith CA, et al.: Genetics of medulloblastoma: clues for novel therapies. *Expert Rev Neurother* 10 (5): 811-23, 2010. [PubMed: 20420498]
44. Dubuc AM, Northcott PA, Mack S, et al.: The genetics of pediatric brain tumors. *Curr Neurol Neurosci Rep* 10 (3): 215-23, 2010. [PubMed: 20425037]
45. Giangaspero F, Wellek S, Masuoka J, et al.: Stratification of medulloblastoma on the basis of histopathological grading. *Acta Neuropathol* 112 (1): 5-12, 2006. [PubMed: 16685513]
46. Jones DT, Jäger N, Kool M, et al.: Dissecting the genomic complexity underlying medulloblastoma. *Nature* 488 (7409): 100-5, 2012. [PMC free article: PMC3662966] [PubMed: 22832583]
47. Peyrl A, Chocholous M, Kieran MW, et al.: Antiangiogenic metronomic therapy for children with recurrent embryonal brain tumors. *Pediatr Blood Cancer* 59 (3): 511-7, 2012. [PubMed: 22147459]
48. Kool M, Korshunov A, Remke M, et al.: Molecular subgroups of medulloblastoma: an international meta-analysis of transcriptome, genetic aberrations, and clinical data of WNT, SHH, Group 3, and Group 4 medulloblastomas. *Acta Neuropathol* 123 (4): 473-84, 2012. [PMC free article: PMC3306778] [PubMed: 22358457]
49. Schwalbe EC, Williamson D, Lindsey JC, et al.: DNA methylation profiling of medulloblastoma allows robust subclassification and improved outcome prediction using formalin-fixed biopsies. *Acta Neuropathol* 125 (3): 359-71, 2013. [PMC free article: PMC4313078] [PubMed: 23291781]
50. Goschzik T, Schwalbe EC, Hicks D, et al.: Prognostic effect of whole chromosomal aberration signatures in standard-risk, non-WNT/non-SHH medulloblastoma: a retrospective, molecular analysis of the HIT-SIOP PNET 4 trial. *Lancet Oncol* 19 (12): 1602-1616, 2018. [PMC free article: PMC6262170] [PubMed: 30392813]
51. Polkinghorn WR, Tarbell NJ: Medulloblastoma: tumorigenesis, current clinical paradigm, and efforts to improve risk stratification. *Nat Clin Pract Oncol* 4 (5): 295-304, 2007. [PubMed: 17464337]
52. Ramaswamy V, Remke M, Bouffet E, et al.: Recurrence patterns across medulloblastoma subgroups: an integrated clinical and molecular analysis. *Lancet Oncol* 14 (12): 1200-7, 2013. [PMC free article: PMC3953419] [PubMed: 24140199]
53. Packer RJ, Zhou T, Holmes E, et al.: Survival and secondary tumors in children with medulloblastoma receiving radiotherapy and adjuvant chemotherapy: results of Children's Oncology Group trial A9961. *Neuro Oncol* 15 (1): 97-103, 2013. [PMC free article: PMC3534419] [PubMed: 23444199]

23099653]

54. Shaw DW, Geyer JR, Berger MS, et al.: Asymptomatic recurrence detection with surveillance scanning in children with medulloblastoma. *J Clin Oncol* 15 (5): 1811-3, 1997. [PubMed: 9164189]
55. Torres CF, Rebsamen S, Silber JH, et al.: Surveillance scanning of children with medulloblastoma. *N Engl J Med* 330 (13): 892-5, 1994. [PubMed: 8114859]
56. Kramer ED, Vezina LG, Packer RJ, et al.: Staging and surveillance of children with central nervous system neoplasms: recommendations of the Neurology and Tumor Imaging Committees of the Children's Cancer Group. *Pediatr Neurosurg* 20 (4): 254-62; discussion 262-3, 1994. [PubMed: 8043464]
57. Sabel M, Fleischhack G, Tippelt S, et al.: Relapse patterns and outcome after relapse in standard risk medulloblastoma: a report from the HIT-SIOP-PNET4 study. *J Neurooncol* 129 (3): 515-524, 2016. [PMC free article: PMC5020107] [PubMed: 27423645]
58. Perreault S, Lober RM, Carret AS, et al.: Surveillance imaging in children with malignant CNS tumors: low yield of spine MRI. *J Neurooncol* 116 (3): 617-23, 2014. [PubMed: 24401959]

Childhood Medulloblastoma

Hereditary Cancer Predisposition Syndromes Associated With Medulloblastoma

Increasingly, subsets of children with brain tumors, including medulloblastoma, have been found to have germline mutations, predisposing them to the development of not only medulloblastoma but also other cancers.[1,2] These mutations have obvious connotations for the affected child, siblings, parents and, potentially, other family members in regard to cancer surveillance, prevention, diagnosis, and management. The mutations may also affect specific tumor treatment.

Medulloblastoma can arise in the setting of hereditary cancer predisposition syndromes in approximately 5% of patients.[1,2] A large study of over 1,000 patients demonstrated germline mutations in approximately 5% of all patients diagnosed with medulloblastoma. Germline mutations were identified in *APC*, *BRCA2*, *PALB2*, *PTCH1*, *SUFU*, and *TP53*. [2]

Syndromes known to be associated with medulloblastoma include the following:

- Turcot syndrome (related to germline mutations in *APC*),[3] exclusive to the WNT-activated subtype.[2]
- Rubinstein-Taybi syndrome (related to germline mutations in *CREBBP*).[4-6]
- Gorlin syndrome (also known as basal cell nevus syndrome or nevoid basal cell carcinoma syndrome, associated with germline *PTCH1* and *SUFU* mutations).[7-11] The risk of developing medulloblastoma in patients with Gorlin syndrome appears to be higher in those with *SUFU* mutations

than in those with *PTCH1* germline mutations. In one study, 2 of 115 individuals (1.7%) with Gorlin syndrome and a *PTCH1* mutation developed a pathology-proven medulloblastoma, compared with 3 of 9 individuals (33%) from three families with *SUFU*-related Gorlin syndrome. Each of the *SUFU*-related patients developed medulloblastoma before age 3 years.[11]

- Li-Fraumeni syndrome (related to germline mutations in *TP53*).[12,13] In one analysis, all germline *TP53* mutations were restricted to the sonic hedgehog (SHH)-activated subtype.[2]
- Fanconi anemia (related to *BRCA2* mutations).[14-17]

Heterozygous deleterious germline mutations in the G protein-coupled receptor 161 (*GPR161*) were identified in approximately 3% of cases of SHH medulloblastoma.[18] *GPR161* is an inhibitor of SHH signaling. Median age at diagnosis for *GPR161*-mutated cases was 1.5 years. Loss of heterozygosity (LOH) at the *GPR161* locus was noted in all tumors, with tumors from five of six patients showing copy-neutral LOH of chromosome 1q (on which *GPR161* resides). The risk of nonmedulloblastoma cancers in patients with deleterious *GPR161* mutations is not defined.

Sometimes medulloblastoma may be the initial manifestation of the presence of germline mutations in these predisposition genes. Germline testing should be considered in the following circumstances:

- *APC* mutation testing in patients with WNT-activated medulloblastoma in the absence of a somatic beta-catenin mutation.
- *SUFU*, *PTCH1*, *TP53*, *PALB2*, and *BRCA2* mutation testing in patients with SHH-activated medulloblastoma. Patients with desmoplastic tumors with extensive nodularity should be carefully evaluated for stigmata of Gorlin syndrome.[7] One report observed that medulloblastoma with extensive nodularity (MBEN) was associated with Gorlin syndrome in 5 of 12 cases.[7] Gorlin syndrome is an autosomal dominant disorder in which those affected are predisposed to develop basal cell carcinomas later in life, especially in skin in the radiation portal. The syndrome can be diagnosed early in life by detection of characteristic dermatological and skeletal features such as keratocysts of the jaw, bifid or fused ribs, macrocephaly, and calcifications of the falx.[7]
- *PALB2* and *BRCA2* mutation testing in patients with a family history of *BRCA*-associated cancers or homologous recombination repair deficiency.

Clinical Presentation

By definition, medulloblastomas must arise in the posterior fossa.[19,20] In approximately 80% of children, medulloblastomas arise in the region of the fourth ventricle. Most of the early symptomatology is related to blockage of cerebrospinal fluid (CSF) and resultant accumulation of CSF in the brain, termed *hydrocephalus*. Children with medulloblastoma are usually diagnosed within 2 to 3 months of the onset of symptoms. Medulloblastoma commonly presents with the following signs and symptoms:[21]

- Relatively abrupt onset of headaches, especially in the morning on waking.
- Nausea and/or vomiting.
- Lethargy.
- Ataxia, including truncal unsteadiness.
- Some degree of nystagmus.
- Papilledema.

Twenty percent of patients with medulloblastoma will not have hydrocephalus at the time of diagnosis and are more likely to present initially with cerebellar deficits. For example, more laterally positioned medulloblastomas of the cerebellum may not result in hydrocephalus and, because of their location, are more likely to result in lateralizing cerebellar dysfunction (appendicular ataxia) manifested by unilateral dysmetria, unsteadiness, and weakness of the sixth and seventh nerves on the same side as the tumor. Later, as the tumor grows toward the midline and blocks CSF, the more classical symptoms associated with hydrocephalus become evident.

Cranial nerve findings are less common, except for unilateral or bilateral sixth nerve palsies, which are usually related to hydrocephalus.[21] At times, medulloblastomas will present explosively, with the acute onset of lethargy and unconsciousness resulting from hemorrhage within the tumor.

In infants, the presentation of medulloblastoma is more variable and may include the following:

- Nonspecific lethargy.
- Psychomotor delays.
- Loss of developmental milestones.
- Feeding difficulties.

On examination, there may be bulging of the anterior fontanel due to increased intracranial pressure and abnormal eye movements, including eyes that are deviated downward (the so-called *sun setting* sign) because of loss of upgaze secondary to compression of the tectum of the midbrain.

Cellular and Molecular Classification

The following four histologic types of medulloblastoma are recognized by the World Health Organization (WHO) classification:[20]

- Medulloblastoma, classic.
- Medulloblastoma, desmoplastic/nodular.
- MBEN.
- Medulloblastoma, large cell/anaplastic.

Significant attention has been focused on medulloblastomas that display anaplastic features, including increased nuclear size, marked cytological pleomorphism, numerous mitoses, and apoptotic bodies.[22,23] Using the criteria of *anaplasia* is subjective because most medulloblastomas have some degree of anaplasia. Foci of anaplasia may appear in tumors with histologic features of both classic and large cell medulloblastomas, and there is significant overlap between the anaplastic and large cell variants, which are frequently termed *large cell/anaplastic medulloblastoma*. [22,23] One convention is to consider medulloblastomas as anaplastic when anaplasia is diffuse (variably defined as anaplasia occurring in 50% to 80% of the tumor).

The incidence of medulloblastoma with the desmoplastic/nodular histologic variant, which most commonly arises in a cerebellar hemisphere, is higher in infants, is less common in children, and increases again in adolescents and adults. The desmoplastic/nodular histologic variant is different from MBEN; the nodular variant has an expanded lobular architecture. The MBEN subtype occurs almost exclusively in infants and carries an excellent prognosis.[7,24]

Molecular subtypes of medulloblastoma

Multiple medulloblastoma subtypes have been identified by integrative molecular analysis.[25-42] Since 2012, the general consensus is that medulloblastoma can be molecularly separated into at least four core subtypes, including WNT-activated, sonic hedgehog (SHH)-activated, group 3, and group 4 medulloblastoma. However, different regions of the same tumor are likely to have other disparate genetic mutations, adding to the complexity of devising effective molecularly targeted therapy.[43] These subtypes remain stable across primary and metastatic components.[44,45]

The 2016 World Health Organization (WHO) classification has endorsed this consensus by adding the following categories for molecularly defined medulloblastoma:[20]

- Medulloblastoma, WNT-activated.
- Medulloblastoma, SHH-activated and *TP53*-mutant.
- Medulloblastoma, SHH-activated and *TP53*-wild-type.

- Medulloblastoma, non-WNT/non-SHH.

Further subclassification within these subgroups is possible, which will provide even more prognostic information.[45-47]

Medulloblastoma, WNT-activated

WNT tumors are medulloblastomas with aberrations in the WNT signaling pathway and represent approximately 10% of all medulloblastomas.[46] WNT medulloblastomas show a WNT signaling gene expression signature and beta-catenin nuclear staining by immunohistochemistry.[48] They are usually histologically classified as *classic medulloblastoma* tumors and rarely have a large cell/anaplastic appearance. WNT medulloblastomas generally occur in older patients (median age, 10 years) and are infrequently metastasized at diagnosis.

CTNNB1 mutations are observed in 85% to 90% of WNT medulloblastoma cases, with *APC* mutations detected in many of the cases that lack *CTNNB1* mutations. Patients with WNT medulloblastoma whose tumors have *APC* mutations often have Turcot syndrome (i.e., germline *APC* mutations).[47] In addition to *CTNNB1* mutations, WNT medulloblastoma tumors show 6q loss (monosomy 6) in 80% to 90% of cases. While monosomy 6 is observed in most medulloblastoma patients younger than 18 years at diagnosis, it appears to be much less common (approximately 25% of cases) in patients older than 18 years.[46,48]

The WNT subset is primarily observed in older children, adolescents, and adults and does not show a male predominance. The subset is believed to have brain stem origin, from the embryonal rhombic lip region.[49] WNT medulloblastomas are associated with a very good outcome in children, especially in individuals whose tumors have beta-catenin nuclear staining and proven 6q loss and/or *CTNNB1* mutations.[40,50,51]

Medulloblastoma, SHH-activated and TP53-mutant and medulloblastoma, SHH-activated and TP53-wildtype

SHH tumors are medulloblastomas with aberrations in the SHH pathway and represent approximately 25% of medulloblastoma cases.[46] SHH medulloblastomas are characterized by chromosome 9q deletions; desmoplastic/nodular histology; and mutations in SHH pathway genes, including *PTCH1*, *PTCH2*, *SMO*, *SUFU*, and *GLI2*. [48]

Heterozygous deleterious germline mutations in the *GPR161* gene were identified in approximately 3% of cases of SHH medulloblastoma.[18] *GPR161* is an inhibitor of SHH signaling. Median age at diagnosis for *GPR161*-mutated cases was 1.5 years. Loss of heterozygosity (LOH) at the *GPR161* locus was noted in all tumors, with tumors from five of six patients showing copy-neutral LOH of chromosome 1q (on which *GPR161* resides).

Mutations in the third nucleotide (r.3A>G) of the U1 spliceosomal small nuclear RNAs (snRNAs) are highly specific for SHH medulloblastoma.[52,53] U1 snRNA r.3A>G mutations are observed in virtually all cases of SHH medulloblastoma in adults, in approximately one-third of cases in children and adolescents, and are absent in infant cases.[53] U1 snRNA mutations disrupt RNA splicing, leading to inactivation of tumor-suppressor genes (e.g., *PTCH1*) and activation of oncogenes (e.g., *GLI2*). The significance of U1 snRNA r.3A>G mutations in specific SHH medulloblastoma subtypes is

described below.

SHH medulloblastomas show a bimodal age distribution and are observed primarily in children younger than 3 years and in older adolescence/adulthood. The tumors are believed to emanate from the external granular layer of the cerebellum. The heterogeneity in age at presentation maps to distinctive subsets identified by further molecular characterization, as follows:

- The subset of medulloblastoma most common in **children aged 3 to 16 years**, termed SHH-alpha, is enriched for *MYCN* and *GLI2* amplifications, with *TP53* mutations commonly co-occurring with one of these amplifications.[45,46] *PTCH1* mutations occur in this subtype and are mutually exclusive with *TP53* mutations (often germline), while *SMO* and *SUFU* mutations are rare.[45,54] U1 snRNA mutations occur in approximately 25% of SHH-alpha medulloblastoma cases and are associated with a very poor prognosis.[53]
- Two SHH subtypes that occur primarily in **children younger than 3 years** have been described.[46] One of these subtypes, termed SHH-beta, is more frequently metastatic, with more frequent focal amplifications.[55] The second of these subtypes, termed SHH-gamma, is enriched for the medulloblastoma with extensive nodularity (MBEN) histology. SHH pathway mutations in children younger than 3 years with medulloblastoma include *PTCH1* and *SUFU* mutations.[45] *SUFU* mutations are rarely observed in older children and adults, and they are commonly germline events.[54]

A second report that used DNA methylation arrays also identified two subtypes of SHH medulloblastoma in young children.[55] One of the subtypes contained all of the cases with *SMO* mutations, and it was associated with a favorable prognosis. The other subtype had most of the *SUFU* mutations, and it was associated with a much lower progression-free survival (PFS) rate. *PTCH1* mutations were present in both subtypes.

- A fourth SHH subtype, termed SHH-delta, includes most of the **adult** cases of SHH medulloblastoma.[46] Virtually all cases of SHH-delta medulloblastoma have the U1 snRNA r.A>3 mutation,[53] and approximately 90% of cases have *TERT* promoter mutations.[46] *PTCH1* and *SMO* mutations are also observed in adults with SHH medulloblastoma.

The outcome for patients with nonmetastatic SHH medulloblastoma is relatively favorable for children younger than 3 years and for adults.[46] Young children with the MBEN histology have a particularly favorable prognosis.[7,24,56-58] Patients with SHH medulloblastoma at greatest risk of treatment failure are children older than 3 years whose tumors have *TP53* mutations, often with co-occurring *GLI2* or *MYCN* amplification and large cell/anaplastic histology.[46,54,59]

Patients with unfavorable molecular findings have an unfavorable prognosis, with fewer than 50% of patients surviving after conventional treatment.[41,54,59-61]

The 2016 WHO classification identifies SHH medulloblastoma with a *TP53* mutation as a distinctive entity (medulloblastoma, SHH-activated and *TP53*-mutant).[20] Approximately 25% of SHH-activated medulloblastoma cases have *TP53* mutations, with a high percentage of these cases also

showing a *TP53* germline mutation (9 of 20 in one study). These patients are commonly between the ages of 5 years and 18 years and have a worse outcome (overall survival at 5 years, <50%).^[61] The tumors often show large cell anaplastic histology.^[61]

Medulloblastoma, non-WNT/non-SHH-activated

The WHO classification combines group 3 and group 4 medulloblastoma cases into a single entity, partly on the basis of the absence of immediate clinical impact for this distinction. Group 3 medulloblastoma represents approximately 25% of medulloblastoma cases, while group 4 medulloblastoma represents approximately 40% of medulloblastoma cases.^[46,48] Both group 3 and group 4 medulloblastoma patients are predominantly male.^[34,45] Group 3 and group 4 medulloblastomas can be further subdivided on the basis of characteristics such as gene expression and DNA methylation profiles, but the optimal approach to their subdivision is not established.^[46,47]

Various genomic alterations are observed in group 3 and group 4 medulloblastomas; however, no single alteration occurs in more than 10% to 20% of cases. Genomic alterations include the following:

- *MYC* amplification was the most common distinctive alteration reported for group 3 medulloblastoma, occurring in approximately 15% of cases.^[39,47]
- The most common distinctive genomic alteration described for group 4 medulloblastoma (observed in approximately 15% of cases) was activation of *PRDM6* by enhancer hijacking, resulting from the tandem duplication of the adjacent *SNCAIP* gene.^[47]
- Other genomic alterations were observed in both group 3 and group 4 cases, including *MYCN* amplification and structural variants leading to *GFI1* or *GFI1B* overexpression through enhancer hijacking.
- Isochromosome 17q (i17q) is the most common cytogenetic abnormality and is observed in a high percentage of group 4 cases as well as in group 3 cases, but it is rarely observed in WNT and SHH medulloblastoma.^[39,47] Prognosis for group 3 and group 4 patients does not appear to be affected by the presence of i17q.^[62]

Group 3 patients with *MYC* amplification or *MYC* overexpression have a poor prognosis,^[45] with fewer than 50% of these patients surviving 5 years after diagnosis.^[46] This poor prognosis is especially true in children younger than 4 years at diagnosis.^[41] However, patients with group 3 medulloblastoma without *MYC* amplification who are older than 3 years have a prognosis similar to that of most patients with non-WNT medulloblastoma, with a 5-year PFS rate higher than 70%.^[60,62]

Group 4 medulloblastomas occur throughout infancy and childhood and into adulthood. The prognosis for group 4 medulloblastoma patients is similar to that for patients with other non-WNT medulloblastomas and may be affected by additional factors such as the presence of metastatic disease, chromosome 11q loss, and chromosome 17p loss.^[38,39,46,59] One study found that group 4 patients with either chromosome 11 loss or gain of

chromosome 17 were low risk, regardless of metastases. In cases lacking both of these cytogenetic features, metastasis at presentation differentiated between high and intermediate risk.[59]

For group 3 and group 4 standard-risk patients (i.e., without *MYC* amplification or metastatic disease), the gain or loss of whole chromosomes appears to connote a favorable prognosis. This finding was derived from the data of 91 patients with non-WNT/non-SHH medulloblastoma enrolled in the SIOP-PNET-4 (NCT01351870) clinical trial and was confirmed in an independent group of 70 children with non-WNT/non-SHH medulloblastoma treated between 1990 and 2014.[62] Chromosomal abnormalities include the following:

- The gain/loss of one or more whole chromosomes was associated with a 5-year event-free survival (EFS) of 93%, compared with an EFS of 64% for no whole chromosome gains/losses.
- The most common whole chromosomal gains/losses are gain of chromosome 7 and loss of chromosomes 8 and 11.
- The optimally performing prognosis discriminator was determined to be the occurrence of two or more of the following aberrations: chromosome 7 gain, chromosome 8 loss, and chromosome 11 loss. Approximately 40% of group 3 and group 4 standard-risk patients had two or more of these chromosomal aberrations and had a 5-year EFS of 100%, compared with an EFS of 68% for patients with fewer than two aberrations.
- In an independent cohort, the prognostic significance of two or more gains/losses versus zero or one gain/loss of chromosomes 7, 8, and 11 was confirmed (5-year EFS, 95% for patients with two or more vs. 59% for patients with one or fewer).

The classification of medulloblastoma into the four major subtypes will likely be altered in the future.[46,47,63,64] Further subdivision within subgroups based on molecular characteristics is likely because each of the subgroups is further molecularly dissected, although the studies are nearing consensus as data from multiple independent studies are merged. As an example, using complementary bioinformatics approaches, concordance was analyzed between multiple large published cohorts, and a more unified subgrouping was described. For children with group 3 and group 4 medulloblastomas, eight distinct subgroups were determined by DNA methylation clustering. Specific subgroups had different prognoses.[38,48,54,65]

Whether the classification for adults with medulloblastoma has a predictive ability similar to that for children is unknown.[39,41] In one study of adult medulloblastoma, *MYC* oncogene amplifications were rarely observed, and tumors with 6q deletion and WNT activation (as identified by nuclear beta-catenin staining) did not share the excellent prognosis seen in pediatric medulloblastomas, although another study did confirm an excellent prognosis for WNT-activated tumors in adults.

[39,41]

Staging Evaluation

Historically, staging was based on an intraoperative evaluation of both the size and extent of the tumor, coupled with postoperative neuroimaging of the brain and spine and cytological evaluation of CSF (the Chang system). Intraoperative evaluation of the extent of the tumor has been supplanted by neuraxis imaging before diagnosis and postoperative imaging to determine the amount of primary site residual disease. The following tests and procedures are now used for staging:

- Magnetic resonance imaging (MRI) of the brain and spine (often done preoperatively).
- Postoperative MRI of the brain to determine the amount of residual disease.
- Lumbar CSF analysis.[66-68]

The tumor extent is defined as:

- M₀: No dissemination.
- M₁: CSF-positive cytology only.
- M₂: Gross nodular seeding in cerebellar-cerebral subarachnoid space and/or lateral or third ventricle.
- M₃: Gross nodular seeding in spinal subarachnoid space.
- M₄: Extranodal metastasis.

Postoperative degree of residual disease is designated as:

- Gross-total resection/near-total resection: No or minimal ($\leq 1.5 \text{ cm}^2$) evidence of residual disease after resection.
- Subtotal resection: Residual disease after diagnosis ($> 1.5 \text{ cm}^2$ of measurable residual disease).
- Biopsy: No tumor resection; only a sample of tumor tissue is removed.

Since the 1990s, prospective studies have been performed using this staging system to separate patients into average-risk and high-risk medulloblastoma subgroups.[67-69]

The presence of diffuse ($> 50\%$ of the pathologic specimen) histologic anaplasia has been incorporated as an addition to staging systems. If diffuse anaplasia is found, patients with otherwise average-risk disease are upstaged to high-risk disease.

Risk Stratification

Risk stratification is based on neuroradiographic evaluation for disseminated disease, CSF cytological examination, postoperative neuroimaging evaluation for the amount of residual disease, and patient age. (Refer to the [Staging Evaluation](#) section of this summary for more information.) Patients older than 3 years with medulloblastoma have been stratified into the following two risk groups:

- **Average risk:** Children older than 3 years with tumors that are totally resected or near-totally resected ($\leq 1.5 \text{ cm}^2$ of residual disease) and who have no metastatic disease.[67]
- **High risk:** Children older than 3 years with metastatic disease and/or subtotal resection ($> 1.5 \text{ cm}^2$ of residual disease).[67] Metastatic disease includes neuroradiographic evidence of disseminated disease, positive cytology in lumbar or ventricular CSF obtained more than 14 days after surgery, or extraneural disease.[67] Children with tumors showing diffuse anaplasia and who otherwise would have been considered average risk are assigned to the high-risk group.[23,33]

For younger children, in some studies for those younger than 3 years and for others younger than 4 or 5 years, similar separation into average-risk (no dissemination and $\leq 1.5 \text{ cm}^2$ of residual disease) or high-risk (disseminated disease and/or $> 1.5 \text{ cm}^2$ of residual disease) groups has been employed. Histologic findings of desmoplasia have also been used to connote a more favorable risk subgrouping, especially for the MBEN subgroup.[70,71]

Assigning a risk group on the basis of the extent of resection and disease at diagnosis may not predict treatment outcome. Molecular genetics and histologic factors may be more informative, although they must be evaluated in the context of patient age, the extent of disease at the time of diagnosis, and treatment received.[38,72] The risk characterizations of molecular subdivisions are changing and are becoming integrated into risk stratification schema to assign treatment in North American prospective studies (e.g., [NCT01878617](#) and [NCT02724579](#)).[63]

Treatment Option Overview for Childhood Medulloblastoma

[Table 3](#) describes the standard treatment options for newly diagnosed and recurrent childhood medulloblastoma.

Table 3. Standard Treatment Options for Childhood Medulloblastoma

Treatment Group		Standard Treatment Options
Newly diagnosed childhood medulloblastoma	Younger children with medulloblastoma	Surgery
		Adjuvant chemotherapy
	Children older than 3 years with	Surgery

Treatment Group	Standard Treatment Options
average-risk medulloblastoma	Adjuvant radiation therapy
	Adjuvant chemotherapy
Children older than 3 years with high-risk medulloblastoma	Surgery
	Adjuvant radiation therapy
	Adjuvant chemotherapy
Recurrent childhood medulloblastoma	There are no standard treatment options. (Refer to the Treatment of Recurrent Childhood Medulloblastoma and Other CNS Embryonal Tumors section of this summary for more information.)

Surgery

Surgery is considered a standard part of treatment for histologic confirmation of tumor type and as a means to improve outcome. Total or near-total resections are considered optimal, if they can be performed safely.[73,74]

Postoperatively, children may have significant neurologic deficits caused by preoperative tumor-related brain injury, hydrocephalus, or surgery-related brain injury.[75][Level of evidence: 3iC] A significant number of patients with medulloblastoma will develop cerebellar mutism syndrome (also known as posterior fossa syndrome). Symptoms of cerebellar mutism syndrome include the following:

- Delayed onset of speech.
- Suprabulbar palsies.
- Ataxia.
- Hypotonia.
- Emotional lability.

The etiology of cerebellar mutism syndrome remains unclear, although cerebellar vermal damage and/or disruption of cerebellar-cortical tracts has been postulated as the possible cause of the mutism.[76,77]; [78][Level of evidence: 3iC] In two Children's Cancer Group studies that evaluated children with both average-risk and high-risk medulloblastoma, the syndrome was identified in nearly 25% of patients.[77-79]; [80][Level of evidence: 3iiiC]

Approximately 50% of patients with this syndrome manifest long-term, permanent neurologic and neurocognitive sequelae.[78,80]

Radiation therapy

Radiation therapy to the primary tumor site is usually in the range of 54 Gy to 55.8 Gy.[81] In most instances, this is given with a margin of 1 cm to 2 cm around the primary tumor site, preferably by conformal techniques.[81] Reducing boost volumes for the whole posterior fossa and to the tumor bed plus margins did not compromise outcomes in average-risk patients in the Children's Oncology Group (COG) ACNS0331 (NCT00085735) study. [82][Level of evidence: 1iiA] For all medulloblastomas in children older than 3 or 4 years at diagnosis, craniospinal radiation therapy is given at doses ranging between 23.4 Gy and 36 Gy, depending on risk factors such as extent of disease at diagnosis. A prospective phase II toxicity study of proton radiation therapy [83] and a retrospective efficacy report of protons versus photons for medulloblastoma [84] demonstrated equivalent outcomes for progression-free survival (PFS), overall survival (OS), patterns of relapse, and delayed toxic effects. A retrospective study of 84 children who received either proton (n = 38) or photon (n = 46) radiation therapy demonstrated similar rates of grade 3 and grade 4 ototoxicity despite low mean cochlear doses in children who received proton radiation therapy, suggesting that other factors (e.g. cisplatin, initial tumor location in relationship to the vestibulocochlear nerve [eighth cranial nerve]) contribute to ototoxicity.[85] The comparative outcomes of these treatment technologies are under investigation.

Chemotherapy is usually administered during and after radiation therapy.

For children younger than 3 years, efforts are made to omit or delay radiation therapy, given the profound impact of radiation at this age. Children of all ages are susceptible to the adverse effects of radiation on brain development. Debilitating effects on neurocognitive development, growth, and endocrine function have been frequently observed, especially in younger children.[86-90]

Chemotherapy

Chemotherapy, usually given during and after radiation therapy, is a standard component of treatment for older children with medulloblastoma and other embryonal tumors. Chemotherapy can be used to delay and sometimes obviate the need for radiation therapy in 20% to 40% of children younger than 3 to 4 years with nondisseminated medulloblastoma.[91,92]; [90][Level of evidence: 3iiiC]

Treatment of Childhood Medulloblastoma

Treatment of younger children with medulloblastoma

Five-year event-free survival (EFS) rates for young children with medulloblastoma, arbitrarily described in the past as aged 3 years and younger at diagnosis, have ranged between 30% and 70%. There is no consensus as to what age constitutes a *younger* population of children with medulloblastoma

who are best treated with immediate postsurgery chemotherapy and delayed or no radiation therapy. Most studies are in agreement that in patients aged 3 years and younger, initial chemotherapy should be strongly considered. In patients between the ages of 3 and 4 years, and possibly as old as age 5 years, some investigators have recommended that radiation therapy be delayed or omitted entirely. Such decisions are based on multiple factors, including histologic subtype, molecular subtype, extent of disease at diagnosis, preexisting neurologic and neurodevelopmental status, and family preferences. Most long-term survivors who have been successfully treated with chemotherapy alone have had nondisseminated completely resected tumors. [70,91,93]; [94][Level of evidence: 2A] Several studies that have utilized chemotherapy alone for younger patients have observed that the finding of desmoplasia (seen in patients with desmoplastic medulloblastoma or MBEN) and/or molecular evidence of SHH signaling, connotes a significantly better prognosis than does the finding of classic or large cell/anaplastic medulloblastoma. [7,24,56-58]; [71][Level of evidence: 2A]

The treatment of younger children with newly diagnosed medulloblastoma continues to evolve. Results have been variable, and comparison across studies has been difficult because of differences in the drug regimens used and the utilization of craniospinal and local boost radiation therapy at the end of chemotherapy or when children reached age 3 years in some studies.

Standard treatment options for younger children with newly diagnosed medulloblastoma include the following:

1. Surgery.
2. Adjuvant chemotherapy.

Surgery

If deemed feasible, complete surgical resection of the tumor is the optimal treatment. Surgical resectability is associated with histology, as patients with desmoplastic/nodular medulloblastoma or MBEN have a higher rate of complete resection than do patients with classic medulloblastoma. [57,58]

Adjuvant chemotherapy

Therapies for younger children with medulloblastoma have included the use of multiagent chemotherapeutic approaches, including drugs such as cyclophosphamide, etoposide, cisplatin, and vincristine, with or without concomitant high-dose intravenous and/or intraventricular methotrexate. [58,70,91,93,95,96]; [97][Level of evidence: 2A]; [98][Level of evidence: 2B] The efficacy of chemotherapy has varied depending on the histology and/or molecular subtype of the tumor.

Desmoplastic/MBEN medulloblastoma and/or tumors with SHH signaling

A series of studies have demonstrated that intensive chemotherapy, including either high-dose systemic and intraventricular methotrexate or high-dose chemotherapy supported by stem cell rescue, without radiation therapy, is an effective treatment for most infants and very young children with

medulloblastoma.

Evidence (chemotherapy):

1. In the German Hirntumor (HIT) 2000 multicenter trial, a multiagent chemotherapy regimen that included high-dose intravenous and intraventricular methotrexate was used. This drug regimen did not include high-dose chemotherapy supported by bone marrow or peripheral stem cell rescue.[70]
 - Nineteen patients with desmoplastic medulloblastoma or MBEN had a 5-year EFS rate of 90% ($\pm 7\%$) and an OS rate of 100% ($\pm 0\%$).
 - All patients were treated with postoperative chemotherapy alone and no radiation was given before progression.
2. An expanded cohort of the German HIT 2000 trial included an additional 23 children with nodular desmoplasia or MBEN who were treated with the same regimen. The following results were reported:[55,99]
 - Combined results confirmed the excellent survival, with a 5-year EFS rate of greater than 90%.
 - In this expanded cohort, molecular characterization was performed and a subset of tumors with SHH signaling were identified; these patients with tumors demonstrating SHH signaling had a similar excellent prognosis.
 - Further characterization of the SHH signaling molecular subtype by chromosomal aberrations did not identify any differences in EFS or OS.
 - Other studies have suggested that further subdivision by chromosomal aberrations in young children with SHH-driven medulloblastoma was predictive of outcome.
3. A COG clinical trial (CCG-9921) also observed a favorable outcome for children with desmoplastic medulloblastoma (including MBEN). In this study, patients with desmoplastic tumors did not receive radiation therapy before progression.[91]
 - Patients in the desmoplastic group achieved an EFS rate of 77% ($\pm 9\%$) and an OS rate of 85% ($\pm 8\%$), compared with an EFS rate of 17% ($\pm 5\%$) and an OS rate of 29% ($\pm 6\%$) for patients in the nondesmoplastic group ($P < .0001$ for both EFS and OS comparisons).
4. The COG-ACNS1221 (NCT02017964) study tested systemic chemotherapy that was identical to the chemotherapy used in the German HIT 2000 trial, except for the omission of intraventricular methotrexate.[100]
 - The study was closed early because of a higher-than-expected rate of relapse, with a 2-year PFS rate of 52% in the 25 patients who were studied.
5. Another treatment option for children younger than 3 years at diagnosis is high-dose chemotherapy. Results of trials utilizing higher-dose,

marrow-ablative chemotherapeutic regimens supported by stem cell rescue have also demonstrated that a subgroup of patients with medulloblastoma who are younger than 3 years and, in some studies, younger than 5 years at the time of diagnosis can be successfully treated with chemotherapy alone.[92,94,101][Level of evidence: 2A]; [102]

- a. The best survival rates using this higher-dose chemotherapy approach have been seen in patients with desmoplastic medulloblastoma and MBEN.[102]
 - After treatment with chemotherapy without concomitant radiation therapy, patients with nondisseminated disease have achieved survival rates of nearly 90%, and patients with disseminated disease have achieved survival rates of 80%.

Nondesmoplastic, non-MBEN, and non-SHH signaling–driven medulloblastoma

Compared with children with desmoplastic medulloblastoma or MBEN treated with current intensive chemotherapy regimens, children with other histological and/or molecular subtypes fare less well. One recent study suggested that patients with molecularly identified group 4 tumors did well with chemotherapy alone.[99]

Evidence (chemotherapy):

1. In children with nondesmoplastic, non-MBEN, and/or non-SHH–signaling tumors, the EFS rates are less than 40% despite the use of intensive chemotherapy supplemented with methotrexate (intravenous and intraventricular) or the use of high-dose chemotherapy regimens supported with stem cell rescue.[58,91,99,102,103]
 - Outcome is particularly poor when these patients have disseminated disease.
2. In some studies, radiation therapy to the primary tumor site and/or craniospinal axis has been added after chemotherapy, which makes the assessment of the efficacy of chemotherapy more difficult.[99,102,103]
3. There is no consensus on how much radiation therapy (dose and extent) should be given and at what age radiation therapy should be instituted in young patients with localized or disseminated disease.
 - In the expanded HIT 2000 study, the addition of focal radiation therapy to the primary tumor site in patient with localized disease after chemotherapy did not improve EFS or OS.[99]

Treatment of children older than 3 years with average-risk medulloblastoma

Standard treatment options for children older than 3 years with newly diagnosed average-risk medulloblastoma include the following:

1. Surgery.
2. Adjuvant radiation therapy.
3. Adjuvant chemotherapy.

Surgery

If deemed feasible, total or near-total removal of the tumor is considered optimal.[73]

Adjuvant radiation therapy

Radiation therapy is usually initiated after surgery with or without concurrent chemotherapy.[104-106] The best survival results for children with medulloblastoma have been obtained when radiation therapy is initiated within 4 to 6 weeks postsurgery.[105-107]; [81,108][Level of evidence: 1iA]

The radiation dose for patients with average-risk medulloblastoma is 54 Gy to the posterior fossa or local tumor bed and 23.4 Gy to the entire neuraxis (i.e., the whole brain and spine), termed *craniospinal irradiation*.[104-106,109]

Evidence (adjuvant radiation therapy):

1. With radiation therapy alone, using a craniospinal radiation dose of 35 Gy with a boost to the posterior fossa of 55 Gy, 5-year EFS rates range between 50% and 65% in those with nondisseminated disease.[69,105]
2. The minimal dose of craniospinal radiation needed for disease control is unknown. Attempts to lower the dose of craniospinal radiation therapy to 23.4 Gy without chemotherapy have resulted in an increased incidence of isolated leptomeningeal relapse.[109]

Lower doses of craniospinal radiation were evaluated in a COG study (NCT00085735). Children aged 3 to 7 years were randomly assigned to receive a craniospinal radiation dose of either 18 Gy or 23.4 Gy, as well as a limited target volume boost to the tumor bed.[82][Level of evidence: 1iiA]

- Preliminary results revealed that 18 Gy of craniospinal irradiation was inferior to 23.4 Gy of craniospinal irradiation (5-year EFS of 82.6% ± 4.2% and OS of 85.8% for patients who received 23.4 Gy vs. EFS of 71.9% ± 4.9% and OS of 77.9% ± 4.9% for patients who received 18 Gy).

Analysis according to molecular subgroups is pending. Craniospinal radiation dose reduction to 18 Gy is currently being investigated in WNT medulloblastoma patients (NCT02724579), the molecular subgroup with the best prognosis.

3. The SIOP-PNET-4 (NCT01351870) study compared daily radiation therapy (1.8 Gy fractions with 23.4 Gy to the neuraxis and a 30 Gy boost to the posterior fossa) with twice-per-day radiation (1 Gy fractions with 36 Gy and a 24-Gy boost to the posterior fossa). [110]
 - With a median follow-up of 7.8 years, the 10-year OS was not significantly different between the two radiation groups.
 - Long-term side effects were not reported in this study.
4. If chemotherapy is added after radiation therapy, 23.4 Gy of craniospinal radiation therapy has been shown to be an effective dose.[81,110-112] Lower doses are being evaluated.
5. Although the standard boost in medulloblastoma is to the entire posterior fossa, failure data patterns reveal that radiation therapy to the tumor bed instead of the entire posterior fossa is equally effective and may be associated with reduced toxicity.[113,114]; [82][Level of evidence: 1iiA]

Adjuvant chemotherapy

Chemotherapy is now a standard component of the treatment of children with average-risk medulloblastoma.

Evidence (adjuvant chemotherapy):

1. Prospective randomized trials and single-arm trials suggest that adjuvant chemotherapy given during and after radiation therapy improves OS for children with average-risk medulloblastoma.[80,104-108]
 - Radiation therapy and chemotherapy given during and after surgery has demonstrated 5-year EFS rates of 70% to 85%.[104-106]; [115][Level of evidence: 2A]
2. A lower radiation dose of 23.4 Gy to the neuraxis when coupled with chemotherapy has been shown to result in disease control in up to 85% of patients and may decrease the severity of long-term neurocognitive sequelae.[81,111,112,116]
3. A variety of chemotherapeutic regimens have been successfully used, including the combination of cisplatin, lomustine, and vincristine or the combination of cisplatin, cyclophosphamide, and vincristine.[104,105,116,117] These therapies have increased 5-year and 10-year EFS and OS rates and have likely decreased the incidence of late relapse. However, long-term survivors treated with multimodality therapy are at a high risk of late effects such as hearing loss, cardiac complications, and secondary neoplasms.[118]

In addition, postradiation high-dose cyclophosphamide supported by peripheral stem cell rescue, but with reduced cumulative doses of vincristine and cisplatin, has resulted in similar survival rates.[51]
4. Although medulloblastoma is often sensitive to chemotherapy, preradiation chemotherapy has not been shown to improve survival in average-risk medulloblastoma patients compared with treatment with radiation therapy and subsequent chemotherapy. In some prospective studies, preradiation

chemotherapy has been related to a poorer rate of survival.[105-108]

Treatment of children older than 3 years with high-risk medulloblastoma

Standard treatment options for children older than 3 years who are newly diagnosed with medulloblastoma and have metastatic disease or have had a subtotal resection include the following:

1. Surgery.
2. Adjuvant radiation therapy.
3. Adjuvant chemotherapy.

In high-risk patients, numerous studies have demonstrated that multimodality therapy improves the duration of disease control and overall disease-free survival.[51,119] Studies show that approximately 50% to 70% of patients with high-risk disease, including those with metastatic disease, will experience long-term disease control.[51,104,119-121]; [122][Level of evidence: 1iiA]; [123][Level of evidence: 2A]; [124][Level of evidence: 1iiA]

Surgery

As for those with average-risk disease, attempt at gross-total resection is considered optimal, if deemed feasible.[69,73]

Adjuvant radiation therapy

In contrast to standard-risk treatment, the craniospinal radiation dose is generally 36 Gy.

Adjuvant chemotherapy

Evidence (adjuvant chemotherapy):

1. The drugs that have been found to be useful in children with average-risk disease are the same drugs that have been used extensively in children with high-risk disease, including cisplatin, lomustine, cyclophosphamide, etoposide, and vincristine.[122] These therapies have increased 5-year and 10-year EFS and OS rates and have likely decreased the incidence of late relapse. However, long-term survivors treated with multimodality therapy are at a high risk of late effects such as hearing loss, cardiac complications, and secondary neoplasms.[118]
2. Postradiation high-dose nonmyeloablative chemotherapy supported by peripheral stem cell rescue, but with reduced cumulative doses of vincristine and cisplatin, has also been utilized and has resulted in 5-year PFS rates of approximately 60%.[51]

Treatment options under clinical evaluation for childhood medulloblastoma

Early-phase therapeutic trials may be available for selected patients. These trials may be available via the [COG](#), the [Pediatric Brain Tumor Consortium](#), or other entities. Information about National Cancer Institute (NCI)–supported clinical trials can be found on the [NCI website](#). For information about clinical trials sponsored by other organizations, refer to the [ClinicalTrials.gov website](#).

The following is an example of a national and/or institutional clinical trial that is currently being conducted:

- **COG-ACNS1422 (NCT02724579)** (Reduced Craniospinal Radiation Therapy and Chemotherapy in Treating Younger Patients With Newly Diagnosed WNT-Driven Medulloblastoma): This phase II trial studies the effectiveness of reduced doses of radiation therapy to the brain and spine (craniospinal) and chemotherapy for patients with the newly diagnosed type of brain tumor called WNT/Wingless (WNT)–driven medulloblastoma. Studies using chemotherapy and radiation therapy are shown to be effective in treating patients with WNT-driven medulloblastoma.

References

1. Zhang J, Walsh MF, Wu G, et al.: Germline Mutations in Predisposition Genes in Pediatric Cancer. *N Engl J Med* 373 (24): 2336-46, 2015. [PMC free article: [PMC4734119](#)] [PubMed: [26580448](#)]
2. Waszak SM, Northcott PA, Buchhalter I, et al.: Spectrum and prevalence of genetic predisposition in medulloblastoma: a retrospective genetic study and prospective validation in a clinical trial cohort. *Lancet Oncol* 19 (6): 785-798, 2018. [PMC free article: [PMC5984248](#)] [PubMed: [29753700](#)]
3. Hamilton SR, Liu B, Parsons RE, et al.: The molecular basis of Turcot's syndrome. *N Engl J Med* 332 (13): 839-47, 1995. [PubMed: [7661930](#)]
4. Taylor MD, Mainprize TG, Rutka JT, et al.: Medulloblastoma in a child with Rubenstein-Taybi Syndrome: case report and review of the literature. *Pediatr Neurosurg* 35 (5): 235-8, 2001. [PubMed: [11741116](#)]
5. Miller RW, Rubinstein JH: Tumors in Rubinstein-Taybi syndrome. *Am J Med Genet* 56 (1): 112-5, 1995. [PubMed: [7747773](#)]
6. Bourdeaut F, Miquel C, Richer W, et al.: Rubinstein-Taybi syndrome predisposing to non-WNT, non-SHH, group 3 medulloblastoma. *Pediatr Blood Cancer* 61 (2): 383-6, 2014. [PubMed: [24115570](#)]
7. Garrè ML, Cama A, Bagnasco F, et al.: Medulloblastoma variants: age-dependent occurrence and relation to Gorlin syndrome--a new clinical perspective. *Clin Cancer Res* 15 (7): 2463-71, 2009. [PubMed: [19276247](#)]
8. Pastorino L, Ghiorzo P, Nasti S, et al.: Identification of a SUFU germline mutation in a family with Gorlin syndrome. *Am J Med Genet A* 149A (7): 1539-43, 2009. [PubMed: [19533801](#)]
9. Brugières L, Remenieras A, Pierron G, et al.: High frequency of germline SUFU mutations in children with desmoplastic/nodular medulloblastoma younger than 3 years of age. *J Clin Oncol* 30 (17): 2087-93, 2012. [PubMed: [22508808](#)]

10. Evans DG, Farndon PA, Burnell LD, et al.: The incidence of Gorlin syndrome in 173 consecutive cases of medulloblastoma. *Br J Cancer* 64 (5): 959-61, 1991. [PMC free article: [PMC1977448](#)] [PubMed: [1931625](#)]
11. Smith MJ, Beetz C, Williams SG, et al.: Germline mutations in SUFU cause Gorlin syndrome-associated childhood medulloblastoma and redefine the risk associated with PTCH1 mutations. *J Clin Oncol* 32 (36): 4155-61, 2014. [PubMed: [25403219](#)]
12. Li FP, Fraumeni JF: Rhabdomyosarcoma in children: epidemiologic study and identification of a familial cancer syndrome. *J Natl Cancer Inst* 43 (6): 1365-73, 1969. [PubMed: [5396222](#)]
13. Pearson AD, Craft AW, Ratcliffe JM, et al.: Two families with the Li-Fraumeni cancer family syndrome. *J Med Genet* 19 (5): 362-5, 1982. [PMC free article: [PMC1048922](#)] [PubMed: [6958872](#)]
14. de Chadarévian JP, Vekemans M, Bernstein M: Fanconi's anemia, medulloblastoma, Wilms' tumor, horseshoe kidney, and gonadal dysgenesis. *Arch Pathol Lab Med* 109 (4): 367-9, 1985. [PubMed: [2985019](#)]
15. Offit K, Levran O, Mullaney B, et al.: Shared genetic susceptibility to breast cancer, brain tumors, and Fanconi anemia. *J Natl Cancer Inst* 95 (20): 1548-51, 2003. [PubMed: [14559878](#)]
16. Dewire MD, Ellison DW, Patay Z, et al.: Fanconi anemia and biallelic BRCA2 mutation diagnosed in a young child with an embryonal CNS tumor. *Pediatr Blood Cancer* 53 (6): 1140-2, 2009. [PMC free article: [PMC3782106](#)] [PubMed: [19530235](#)]
17. Reid S, Renwick A, Seal S, et al.: Biallelic BRCA2 mutations are associated with multiple malignancies in childhood including familial Wilms tumour. *J Med Genet* 42 (2): 147-51, 2005. [PMC free article: [PMC1735989](#)] [PubMed: [15689453](#)]
18. Begemann M, Waszak SM, Robinson GW, et al.: Germline GPR161 Mutations Predispose to Pediatric Medulloblastoma. *J Clin Oncol* 38 (1): 43-50, 2020. [PMC free article: [PMC6943973](#)] [PubMed: [31609649](#)]
19. Rorke LB: The cerebellar medulloblastoma and its relationship to primitive neuroectodermal tumors. *J Neuropathol Exp Neurol* 42 (1): 1-15, 1983. [PubMed: [6296325](#)]
20. Louis DN, Perry A, Reifenberger G, et al.: The 2016 World Health Organization Classification of Tumors of the Central Nervous System: a summary. *Acta Neuropathol* 131 (6): 803-20, 2016. [PubMed: [27157931](#)]
21. Ramaswamy V, Remke M, Shih D, et al.: Duration of the pre-diagnostic interval in medulloblastoma is subgroup dependent. *Pediatr Blood Cancer* 61 (7): 1190-4, 2014. [PubMed: [24616042](#)]
22. McManamy CS, Lamont JM, Taylor RE, et al.: Morphophenotypic variation predicts clinical behavior in childhood non-desmoplastic medulloblastomas. *J Neuropathol Exp Neurol* 62 (6): 627-32, 2003. [PubMed: [12834107](#)]
23. Eberhart CG, Kratz J, Wang Y, et al.: Histopathological and molecular prognostic markers in medulloblastoma: c-myc, N-myc, TrkC, and anaplasia. *J Neuropathol Exp Neurol* 63 (5): 441-9, 2004. [PubMed: [15198123](#)]
24. Giangaspero F, Perilongo G, Fondelli MP, et al.: Medulloblastoma with extensive nodularity: a variant with favorable prognosis. *J Neurosurg* 91 (6): 971-7, 1999. [PubMed: [10584843](#)]
25. Onvani S, Etame AB, Smith CA, et al.: Genetics of medulloblastoma: clues for novel therapies. *Expert Rev Neurother* 10 (5): 811-23, 2010.

- [PubMed: 20420498]
26. Dubuc AM, Northcott PA, Mack S, et al.: The genetics of pediatric brain tumors. *Curr Neurol Neurosci Rep* 10 (3): 215-23, 2010. [PubMed: 20425037]
 27. Thompson MC, Fuller C, Hogg TL, et al.: Genomics identifies medulloblastoma subgroups that are enriched for specific genetic alterations. *J Clin Oncol* 24 (12): 1924-31, 2006. [PubMed: 16567768]
 28. Kool M, Koster J, Bunt J, et al.: Integrated genomics identifies five medulloblastoma subtypes with distinct genetic profiles, pathway signatures and clinicopathological features. *PLoS One* 3 (8): e3088, 2008. [PMC free article: PMC2518524] [PubMed: 18769486]
 29. Tabori U, Baskin B, Shago M, et al.: Universal poor survival in children with medulloblastoma harboring somatic TP53 mutations. *J Clin Oncol* 28 (8): 1345-50, 2010. [PubMed: 20142599]
 30. Pfister S, Remke M, Benner A, et al.: Outcome prediction in pediatric medulloblastoma based on DNA copy-number aberrations of chromosomes 6q and 17q and the MYC and MYCN loci. *J Clin Oncol* 27 (10): 1627-36, 2009. [PubMed: 19255330]
 31. Ellison DW, Onilude OE, Lindsey JC, et al.: beta-Catenin status predicts a favorable outcome in childhood medulloblastoma: the United Kingdom Children's Cancer Study Group Brain Tumour Committee. *J Clin Oncol* 23 (31): 7951-7, 2005. [PubMed: 16258095]
 32. Polkinghorn WR, Tarbell NJ: Medulloblastoma: tumorigenesis, current clinical paradigm, and efforts to improve risk stratification. *Nat Clin Pract Oncol* 4 (5): 295-304, 2007. [PubMed: 17464337]
 33. Giangaspero F, Wellek S, Masuoka J, et al.: Stratification of medulloblastoma on the basis of histopathological grading. *Acta Neuropathol* 112 (1): 5-12, 2006. [PubMed: 16685513]
 34. Northcott PA, Korshunov A, Witt H, et al.: Medulloblastoma comprises four distinct molecular variants. *J Clin Oncol* 29 (11): 1408-14, 2011. [PMC free article: PMC4874239] [PubMed: 20823417]
 35. Pomeroy SL, Tamayo P, Gaasenbeek M, et al.: Prediction of central nervous system embryonal tumour outcome based on gene expression. *Nature* 415 (6870): 436-42, 2002. [PubMed: 11807556]
 36. Jones DT, Jäger N, Kool M, et al.: Dissecting the genomic complexity underlying medulloblastoma. *Nature* 488 (7409): 100-5, 2012. [PMC free article: PMC3662966] [PubMed: 22832583]
 37. Peyrl A, Chocholous M, Kieran MW, et al.: Antiangiogenic metronomic therapy for children with recurrent embryonal brain tumors. *Pediatr Blood Cancer* 59 (3): 511-7, 2012. [PubMed: 22147459]
 38. Taylor MD, Northcott PA, Korshunov A, et al.: Molecular subgroups of medulloblastoma: the current consensus. *Acta Neuropathol* 123 (4): 465-72, 2012. [PMC free article: PMC3306779] [PubMed: 22134537]
 39. Kool M, Korshunov A, Remke M, et al.: Molecular subgroups of medulloblastoma: an international meta-analysis of transcriptome, genetic aberrations, and clinical data of WNT, SHH, Group 3, and Group 4 medulloblastomas. *Acta Neuropathol* 123 (4): 473-84, 2012. [PMC free article: PMC3306778] [PubMed: 22358457]
 40. Pietsch T, Schmidt R, Remke M, et al.: Prognostic significance of clinical, histopathological, and molecular characteristics of medulloblastomas in

- the prospective HIT2000 multicenter clinical trial cohort. *Acta Neuropathol* 128 (1): 137-49, 2014. [PMC free article: [PMC4059991](#)] [PubMed: [24791927](#)]
41. Cho YJ, Tsherniak A, Tamayo P, et al.: Integrative genomic analysis of medulloblastoma identifies a molecular subgroup that drives poor clinical outcome. *J Clin Oncol* 29 (11): 1424-30, 2011. [PMC free article: [PMC3082983](#)] [PubMed: [21098324](#)]
 42. Gajjar A, Bowers DC, Karajannis MA, et al.: Pediatric Brain Tumors: Innovative Genomic Information Is Transforming the Diagnostic and Clinical Landscape. *J Clin Oncol* 33 (27): 2986-98, 2015. [PMC free article: [PMC4567701](#)] [PubMed: [26304884](#)]
 43. Morrissy AS, Cavalli FMG, Remke M, et al.: Spatial heterogeneity in medulloblastoma. *Nat Genet* 49 (5): 780-788, 2017. [PMC free article: [PMC5553617](#)] [PubMed: [28394352](#)]
 44. Wang X, Dubuc AM, Ramaswamy V, et al.: Medulloblastoma subgroups remain stable across primary and metastatic compartments. *Acta Neuropathol* 129 (3): 449-57, 2015. [PMC free article: [PMC4333718](#)] [PubMed: [25689980](#)]
 45. Schwalbe EC, Lindsey JC, Nakjang S, et al.: Novel molecular subgroups for clinical classification and outcome prediction in childhood medulloblastoma: a cohort study. *Lancet Oncol* 18 (7): 958-971, 2017. [PMC free article: [PMC5489698](#)] [PubMed: [28545823](#)]
 46. Cavalli FMG, Remke M, Rampasek L, et al.: Intertumoral Heterogeneity within Medulloblastoma Subgroups. *Cancer Cell* 31 (6): 737-754.e6, 2017. [PMC free article: [PMC6163053](#)] [PubMed: [28609654](#)]
 47. Northcott PA, Buchhalter I, Morrissy AS, et al.: The whole-genome landscape of medulloblastoma subtypes. *Nature* 547 (7663): 311-317, 2017. [PMC free article: [PMC5905700](#)] [PubMed: [28726821](#)]
 48. Northcott PA, Jones DT, Kool M, et al.: Medulloblastomics: the end of the beginning. *Nat Rev Cancer* 12 (12): 818-34, 2012. [PMC free article: [PMC3889646](#)] [PubMed: [23175120](#)]
 49. Gibson P, Tong Y, Robinson G, et al.: Subtypes of medulloblastoma have distinct developmental origins. *Nature* 468 (7327): 1095-9, 2010. [PMC free article: [PMC3059767](#)] [PubMed: [21150899](#)]
 50. Ellison DW, Dalton J, Kocak M, et al.: Medulloblastoma: clinicopathological correlates of SHH, WNT, and non-SHH/WNT molecular subgroups. *Acta Neuropathol* 121 (3): 381-96, 2011. [PMC free article: [PMC3519926](#)] [PubMed: [21267586](#)]
 51. Gajjar A, Chintagumpala M, Ashley D, et al.: Risk-adapted craniospinal radiotherapy followed by high-dose chemotherapy and stem-cell rescue in children with newly diagnosed medulloblastoma (St Jude Medulloblastoma-96): long-term results from a prospective, multicentre trial. *Lancet Oncol* 7 (10): 813-20, 2006. [PubMed: [17012043](#)]
 52. Shuai S, Suzuki H, Diaz-Navarro A, et al.: The U1 spliceosomal RNA is recurrently mutated in multiple cancers. *Nature* 574 (7780): 712-716, 2019. [PubMed: [31597163](#)]
 53. Suzuki H, Kumar SA, Shuai S, et al.: Recurrent noncoding U1 snRNA mutations drive cryptic splicing in SHH medulloblastoma. *Nature* 574 (7780): 707-711, 2019. [PMC free article: [PMC7141958](#)] [PubMed: [31664194](#)]
 54. Kool M, Jones DT, Jäger N, et al.: Genome sequencing of SHH medulloblastoma predicts genotype-related response to smoothed inhibition. *Cancer Cell* 25 (3): 393-405, 2014. [PMC free article: [PMC4493053](#)] [PubMed: [24651015](#)]

55. Robinson GW, Rudneva VA, Buchhalter I, et al.: Risk-adapted therapy for young children with medulloblastoma (SJYC07): therapeutic and molecular outcomes from a multicentre, phase 2 trial. *Lancet Oncol* 19 (6): 768-784, 2018. [PMC free article: [PMC6078206](#)] [PubMed: [29778738](#)]
56. Leary SE, Zhou T, Holmes E, et al.: Histology predicts a favorable outcome in young children with desmoplastic medulloblastoma: a report from the children's oncology group. *Cancer* 117 (14): 3262-7, 2011. [PMC free article: [PMC3119763](#)] [PubMed: [21246528](#)]
57. Rutkowski S, von Hoff K, Emser A, et al.: Survival and prognostic factors of early childhood medulloblastoma: an international meta-analysis. *J Clin Oncol* 28 (33): 4961-8, 2010. [PubMed: [20940197](#)]
58. von Bueren AO, von Hoff K, Pietsch T, et al.: Treatment of young children with localized medulloblastoma by chemotherapy alone: results of the prospective, multicenter trial HIT 2000 confirming the prognostic impact of histology. *Neuro Oncol* 13 (6): 669-79, 2011. [PMC free article: [PMC3107096](#)] [PubMed: [21636711](#)]
59. Shih DJ, Northcott PA, Remke M, et al.: Cytogenetic prognostication within medulloblastoma subgroups. *J Clin Oncol* 32 (9): 886-96, 2014. [PMC free article: [PMC3948094](#)] [PubMed: [24493713](#)]
60. Schwalbe EC, Williamson D, Lindsey JC, et al.: DNA methylation profiling of medulloblastoma allows robust subclassification and improved outcome prediction using formalin-fixed biopsies. *Acta Neuropathol* 125 (3): 359-71, 2013. [PMC free article: [PMC4313078](#)] [PubMed: [23291781](#)]
61. Zhukova N, Ramaswamy V, Remke M, et al.: Subgroup-specific prognostic implications of TP53 mutation in medulloblastoma. *J Clin Oncol* 31 (23): 2927-35, 2013. [PMC free article: [PMC4878050](#)] [PubMed: [23835706](#)]
62. Goschzik T, Schwalbe EC, Hicks D, et al.: Prognostic effect of whole chromosomal aberration signatures in standard-risk, non-WNT/non-SHH medulloblastoma: a retrospective, molecular analysis of the HIT-SIOP PNET 4 trial. *Lancet Oncol* 19 (12): 1602-1616, 2018. [PMC free article: [PMC6262170](#)] [PubMed: [30392813](#)]
63. Gottardo NG, Hansford JR, McGlade JP, et al.: Medulloblastoma Down Under 2013: a report from the third annual meeting of the International Medulloblastoma Working Group. *Acta Neuropathol* 127 (2): 189-201, 2014. [PMC free article: [PMC3895219](#)] [PubMed: [24264598](#)]
64. Louis DN, Perry A, Burger P, et al.: International Society Of Neuropathology--Haarlem consensus guidelines for nervous system tumor classification and grading. *Brain Pathol* 24 (5): 429-35, 2014. [PubMed: [24990071](#)]
65. Sharma T, Schwalbe EC, Williamson D, et al.: Second-generation molecular subgrouping of medulloblastoma: an international meta-analysis of Group 3 and Group 4 subtypes. *Acta Neuropathol* 138 (2): 309-326, 2019. [PMC free article: [PMC6660496](#)] [PubMed: [31076851](#)]
66. Fouladi M, Gajjar A, Boyett JM, et al.: Comparison of CSF cytology and spinal magnetic resonance imaging in the detection of leptomeningeal disease in pediatric medulloblastoma or primitive neuroectodermal tumor. *J Clin Oncol* 17 (10): 3234-7, 1999. [PubMed: [10506624](#)]
67. Zeltzer PM, Boyett JM, Finlay JL, et al.: Metastasis stage, adjuvant treatment, and residual tumor are prognostic factors for medulloblastoma in children: conclusions from the Children's Cancer Group 921 randomized phase III study. *J Clin Oncol* 17 (3): 832-45, 1999. [PubMed: [10071274](#)]
68. Yao MS, Mehta MP, Boyett JM, et al.: The effect of M-stage on patterns of failure in posterior fossa primitive neuroectodermal tumors treated on

- CCG-921: a phase III study in a high-risk patient population. *Int J Radiat Oncol Biol Phys* 38 (3): 469-76, 1997. [PubMed: 9231668]
69. Taylor RE, Bailey CC, Robinson K, et al.: Results of a randomized study of preradiation chemotherapy versus radiotherapy alone for nonmetastatic medulloblastoma: The International Society of Paediatric Oncology/United Kingdom Children's Cancer Study Group PNET-3 Study. *J Clin Oncol* 21 (8): 1581-91, 2003. [PubMed: 12697884]
70. Rutkowski S, Bode U, Deinlein F, et al.: Treatment of early childhood medulloblastoma by postoperative chemotherapy alone. *N Engl J Med* 352 (10): 978-86, 2005. [PubMed: 15758008]
71. Rutkowski S, Gerber NU, von Hoff K, et al.: Treatment of early childhood medulloblastoma by postoperative chemotherapy and deferred radiotherapy. *Neuro Oncol* 11 (2): 201-10, 2009. [PMC free article: PMC2718992] [PubMed: 18818397]
72. Ramaswamy V, Remke M, Adamski J, et al.: Medulloblastoma subgroup-specific outcomes in irradiated children: who are the true high-risk patients? *Neuro Oncol* 18 (2): 291-7, 2016. [PMC free article: PMC4724171] [PubMed: 25605817]
73. Albright AL, Wisoff JH, Zeltzer PM, et al.: Effects of medulloblastoma resections on outcome in children: a report from the Children's Cancer Group. *Neurosurgery* 38 (2): 265-71, 1996. [PubMed: 8869053]
74. Thompson EM, Hielscher T, Bouffet E, et al.: Prognostic value of medulloblastoma extent of resection after accounting for molecular subgroup: a retrospective integrated clinical and molecular analysis. *Lancet Oncol* 17 (4): 484-95, 2016. [PMC free article: PMC4907853] [PubMed: 26976201]
75. Stargatt R, Rosenfeld JV, Maixner W, et al.: Multiple factors contribute to neuropsychological outcome in children with posterior fossa tumors. *Dev Neuropsychol* 32 (2): 729-48, 2007. [PubMed: 17931127]
76. Pollack IF, Polinko P, Albright AL, et al.: Mutism and pseudobulbar symptoms after resection of posterior fossa tumors in children: incidence and pathophysiology. *Neurosurgery* 37 (5): 885-93, 1995. [PubMed: 8559336]
77. Robertson PL, Muraszko KM, Holmes EJ, et al.: Incidence and severity of postoperative cerebellar mutism syndrome in children with medulloblastoma: a prospective study by the Children's Oncology Group. *J Neurosurg* 105 (6): 444-51, 2006. [PubMed: 17184075]
78. Wells EM, Khademian ZP, Walsh KS, et al.: Postoperative cerebellar mutism syndrome following treatment of medulloblastoma: neuroradiographic features and origin. *J Neurosurg Pediatr* 5 (4): 329-34, 2010. [PubMed: 20367335]
79. Gudrunardottir T, Sehested A, Juhler M, et al.: Cerebellar mutism: review of the literature. *Childs Nerv Syst* 27 (3): 355-63, 2011. [PubMed: 21061011]
80. Wolfe-Christensen C, Mullins LL, Scott JG, et al.: Persistent psychosocial problems in children who develop posterior fossa syndrome after medulloblastoma resection. *Pediatr Blood Cancer* 49 (5): 723-6, 2007. [PubMed: 17066468]
81. Packer RJ, Gajjar A, Vezina G, et al.: Phase III study of craniospinal radiation therapy followed by adjuvant chemotherapy for newly diagnosed average-risk medulloblastoma. *J Clin Oncol* 24 (25): 4202-8, 2006. [PubMed: 16943538]
82. Michalski JM, Janss A, Vezina G, et al.: Results of COG ACNS0331: a phase III trial of involved-field radiotherapy (IFRT) and low dose craniospinal irradiation (LD-CSI) with chemotherapy in average-risk medulloblastoma: a report from the Children's Oncology Group. [Abstract]

- Int J Radiat Oncol Biol Phys 96 (5): A-LBA-2, 937-8, 2016. Also available online. Last accessed October 05, 2020.
83. Yock TI, Yeap BY, Ebb DH, et al.: Long-term toxic effects of proton radiotherapy for paediatric medulloblastoma: a phase 2 single-arm study. *Lancet Oncol* 17 (3): 287-98, 2016. [PubMed: 26830377]
 84. Eaton BR, Esiashvili N, Kim S, et al.: Clinical Outcomes Among Children With Standard-Risk Medulloblastoma Treated With Proton and Photon Radiation Therapy: A Comparison of Disease Control and Overall Survival. *Int J Radiat Oncol Biol Phys* 94 (1): 133-8, 2016. [PMC free article: PMC4692186] [PubMed: 26700707]
 85. Paulino AC, Mahajan A, Ye R, et al.: Ototoxicity and cochlear sparing in children with medulloblastoma: Proton vs. photon radiotherapy. *Radiother Oncol* 128 (1): 128-132, 2018. [PubMed: 29373195]
 86. Ris MD, Packer R, Goldwein J, et al.: Intellectual outcome after reduced-dose radiation therapy plus adjuvant chemotherapy for medulloblastoma: a Children's Cancer Group study. *J Clin Oncol* 19 (15): 3470-6, 2001. [PubMed: 11481352]
 87. Packer RJ, Sutton LN, Atkins TE, et al.: A prospective study of cognitive function in children receiving whole-brain radiotherapy and chemotherapy: 2-year results. *J Neurosurg* 70 (5): 707-13, 1989. [PubMed: 2709111]
 88. Johnson DL, McCabe MA, Nicholson HS, et al.: Quality of long-term survival in young children with medulloblastoma. *J Neurosurg* 80 (6): 1004-10, 1994. [PubMed: 8189255]
 89. Walter AW, Mulhern RK, Gajjar A, et al.: Survival and neurodevelopmental outcome of young children with medulloblastoma at St Jude Children's Research Hospital. *J Clin Oncol* 17 (12): 3720-8, 1999. [PubMed: 10577843]
 90. Laughton SJ, Merchant TE, Sklar CA, et al.: Endocrine outcomes for children with embryonal brain tumors after risk-adapted craniospinal and conformal primary-site irradiation and high-dose chemotherapy with stem-cell rescue on the SJMB-96 trial. *J Clin Oncol* 26 (7): 1112-8, 2008. [PubMed: 18309946]
 91. Geyer JR, Sposto R, Jennings M, et al.: Multiagent chemotherapy and deferred radiotherapy in infants with malignant brain tumors: a report from the Children's Cancer Group. *J Clin Oncol* 23 (30): 7621-31, 2005. [PubMed: 16234523]
 92. Chi SN, Gardner SL, Levy AS, et al.: Feasibility and response to induction chemotherapy intensified with high-dose methotrexate for young children with newly diagnosed high-risk disseminated medulloblastoma. *J Clin Oncol* 22 (24): 4881-7, 2004. [PubMed: 15611503]
 93. Grill J, Sainte-Rose C, Jouvet A, et al.: Treatment of medulloblastoma with postoperative chemotherapy alone: an SFOP prospective trial in young children. *Lancet Oncol* 6 (8): 573-80, 2005. [PubMed: 16054568]
 94. Cohen BH, Geyer JR, Miller DC, et al.: Pilot Study of Intensive Chemotherapy With Peripheral Hematopoietic Cell Support for Children Less Than 3 Years of Age With Malignant Brain Tumors, the CCG-99703 Phase I/II Study. A Report From the Children's Oncology Group. *Pediatr Neurol* 53 (1): 31-46, 2015. [PMC free article: PMC5166616] [PubMed: 26092413]
 95. Duffner PK, Horowitz ME, Krischer JP, et al.: Postoperative chemotherapy and delayed radiation in children less than three years of age with malignant brain tumors. *N Engl J Med* 328 (24): 1725-31, 1993. [PubMed: 8388548]
 96. Ater JL, van Eys J, Woo SY, et al.: MOPP chemotherapy without irradiation as primary postsurgical therapy for brain tumors in infants and young

- children. *J Neurooncol* 32 (3): 243-52, 1997. [PubMed: 9049886]
97. Grundy RG, Wilne SH, Robinson KJ, et al.: Primary postoperative chemotherapy without radiotherapy for treatment of brain tumours other than ependymoma in children under 3 years: results of the first UKCCSG/SIOP CNS 9204 trial. *Eur J Cancer* 46 (1): 120-33, 2010. [PubMed: 19818598]
98. Blaney SM, Kocak M, Gajjar A, et al.: Pilot study of systemic and intrathecal mafosfamide followed by conformal radiation for infants with intracranial central nervous system tumors: a pediatric brain tumor consortium study (PBTC-001). *J Neurooncol* 109 (3): 565-71, 2012. [PMC free article: PMC3529096] [PubMed: 22790443]
99. Mynarek M, von Hoff K, Pietsch T, et al.: Nonmetastatic Medulloblastoma of Early Childhood: Results From the Prospective Clinical Trial HIT-2000 and An Extended Validation Cohort. *J Clin Oncol* 38 (18): 2028-2040, 2020. [PubMed: 32330099]
100. Lafay-Cousin L, Bouffet E, Strother D, et al.: Phase II Study of Nonmetastatic Desmoplastic Medulloblastoma in Children Younger Than 4 Years of Age: A Report of the Children's Oncology Group (ACNS1221). *J Clin Oncol* 38 (3): 223-231, 2020. [PMC free article: PMC6968798] [PubMed: 31774708]
101. Dhall G, Grodman H, Ji L, et al.: Outcome of children less than three years old at diagnosis with non-metastatic medulloblastoma treated with chemotherapy on the "Head Start" I and II protocols. *Pediatr Blood Cancer* 50 (6): 1169-75, 2008. [PubMed: 18293379]
102. Dhall G, O'Neil SH, Ji L, et al.: Excellent Outcome of Young Children with Nodular Desmoplastic Medulloblastoma Treated on "Head Start" III: A Multi-Institutional, Prospective Clinical Trial. *Neuro Oncol* : , 2020. [PubMed: 32304218]
103. Lafay-Cousin L, Smith A, Chi SN, et al.: Clinical, Pathological, and Molecular Characterization of Infant Medulloblastomas Treated with Sequential High-Dose Chemotherapy. *Pediatr Blood Cancer* 63 (9): 1527-34, 2016. [PMC free article: PMC5031363] [PubMed: 27145464]
104. Packer RJ, Sutton LN, Elterman R, et al.: Outcome for children with medulloblastoma treated with radiation and cisplatin, CCNU, and vincristine chemotherapy. *J Neurosurg* 81 (5): 690-8, 1994. [PubMed: 7931615]
105. Bailey CC, Gnekow A, Wellek S, et al.: Prospective randomised trial of chemotherapy given before radiotherapy in childhood medulloblastoma. International Society of Paediatric Oncology (SIOP) and the (German) Society of Paediatric Oncology (GPO): SIOP II. *Med Pediatr Oncol* 25 (3): 166-78, 1995. [PubMed: 7623725]
106. Kortmann RD, Köhl J, Timmermann B, et al.: Postoperative neoadjuvant chemotherapy before radiotherapy as compared to immediate radiotherapy followed by maintenance chemotherapy in the treatment of medulloblastoma in childhood: results of the German prospective randomized trial HIT '91. *Int J Radiat Oncol Biol Phys* 46 (2): 269-79, 2000. [PubMed: 10661332]
107. Taylor RE, Bailey CC, Robinson KJ, et al.: Impact of radiotherapy parameters on outcome in the International Society of Paediatric Oncology/United Kingdom Children's Cancer Study Group PNET-3 study of preradiotherapy chemotherapy for M0-M1 medulloblastoma. *Int J Radiat Oncol Biol Phys* 58 (4): 1184-93, 2004. [PubMed: 15001263]
108. von Hoff K, Hinkes B, Gerber NU, et al.: Long-term outcome and clinical prognostic factors in children with medulloblastoma treated in the prospective randomised multicentre trial HIT'91. *Eur J Cancer* 45 (7): 1209-17, 2009. [PubMed: 19250820]

109. Thomas PR, Deutsch M, Kepner JL, et al.: Low-stage medulloblastoma: final analysis of trial comparing standard-dose with reduced-dose neuraxis irradiation. *J Clin Oncol* 18 (16): 3004-11, 2000. [PubMed: 10944134]
110. Sabel M, Fleischhack G, Tippelt S, et al.: Relapse patterns and outcome after relapse in standard risk medulloblastoma: a report from the HIT-SIOP-PNET4 study. *J Neurooncol* 129 (3): 515-524, 2016. [PMC free article: PMC5020107] [PubMed: 27423645]
111. Oyharcabal-Bourden V, Kalifa C, Gentet JC, et al.: Standard-risk medulloblastoma treated by adjuvant chemotherapy followed by reduced-dose craniospinal radiation therapy: a French Society of Pediatric Oncology Study. *J Clin Oncol* 23 (21): 4726-34, 2005. [PubMed: 16034048]
112. Merchant TE, Kun LE, Krasin MJ, et al.: Multi-institution prospective trial of reduced-dose craniospinal irradiation (23.4 Gy) followed by conformal posterior fossa (36 Gy) and primary site irradiation (55.8 Gy) and dose-intensive chemotherapy for average-risk medulloblastoma. *Int J Radiat Oncol Biol Phys* 70 (3): 782-7, 2008. [PMC free article: PMC2716663] [PubMed: 17892918]
113. Fukunaga-Johnson N, Sandler HM, Marsh R, et al.: The use of 3D conformal radiotherapy (3D CRT) to spare the cochlea in patients with medulloblastoma. *Int J Radiat Oncol Biol Phys* 41 (1): 77-82, 1998. [PubMed: 9588920]
114. Huang E, Teh BS, Strother DR, et al.: Intensity-modulated radiation therapy for pediatric medulloblastoma: early report on the reduction of ototoxicity. *Int J Radiat Oncol Biol Phys* 52 (3): 599-605, 2002. [PubMed: 11849779]
115. Carrie C, Grill J, Figarella-Branger D, et al.: Online quality control, hyperfractionated radiotherapy alone and reduced boost volume for standard risk medulloblastoma: long-term results of MSFOP 98. *J Clin Oncol* 27 (11): 1879-83, 2009. [PubMed: 19273707]
116. Packer RJ, Goldwein J, Nicholson HS, et al.: Treatment of children with medulloblastomas with reduced-dose craniospinal radiation therapy and adjuvant chemotherapy: A Children's Cancer Group Study. *J Clin Oncol* 17 (7): 2127-36, 1999. [PubMed: 10561268]
117. Nageswara Rao AA, Wallace DJ, Billups C, et al.: Cumulative cisplatin dose is not associated with event-free or overall survival in children with newly diagnosed average-risk medulloblastoma treated with cisplatin based adjuvant chemotherapy: report from the Children's Oncology Group. *Pediatr Blood Cancer* 61 (1): 102-6, 2014. [PMC free article: PMC4591537] [PubMed: 23956184]
118. Salloum R, Chen Y, Yasui Y, et al.: Late Morbidity and Mortality Among Medulloblastoma Survivors Diagnosed Across Three Decades: A Report From the Childhood Cancer Survivor Study. *J Clin Oncol* 37 (9): 731-740, 2019. [PMC free article: PMC6424138] [PubMed: 30730781]
119. Verlooy J, Mosseri V, Bracard S, et al.: Treatment of high risk medulloblastomas in children above the age of 3 years: a SFOP study. *Eur J Cancer* 42 (17): 3004-14, 2006. [PubMed: 16956759]
120. Gandola L, Massimino M, Cefalo G, et al.: Hyperfractionated accelerated radiotherapy in the Milan strategy for metastatic medulloblastoma. *J Clin Oncol* 27 (4): 566-71, 2009. [PubMed: 19075266]
121. Evans AE, Jenkin RD, Sposto R, et al.: The treatment of medulloblastoma. Results of a prospective randomized trial of radiation therapy with and without CCNU, vincristine, and prednisone. *J Neurosurg* 72 (4): 572-82, 1990. [PubMed: 2319316]
122. Jakacki RI, Burger PC, Zhou T, et al.: Outcome of children with metastatic medulloblastoma treated with carboplatin during craniospinal radiotherapy: a Children's Oncology Group Phase I/II study. *J Clin Oncol* 30 (21): 2648-53, 2012. [PMC free article: PMC4559602] [PubMed: 22665539]

123. von Bueren AO, Kortmann RD, von Hoff K, et al.: Treatment of Children and Adolescents With Metastatic Medulloblastoma and Prognostic Relevance of Clinical and Biologic Parameters. *J Clin Oncol* 34 (34): 4151-4160, 2016. [PubMed: 27863192]
124. Tarbell NJ, Friedman H, Polkinghorn WR, et al.: High-risk medulloblastoma: a pediatric oncology group randomized trial of chemotherapy before or after radiation therapy (POG 9031). *J Clin Oncol* 31 (23): 2936-41, 2013. [PMC free article: PMC3732312] [PubMed: 23857975]

Childhood Nonmedulloblastoma Embryonal Tumors

In the most recent World Health Organization (WHO) classification of primary central nervous system (CNS) tumors, all nonmedulloblastoma tumors of neuroectodermal origin that lack the specific histopathological features or molecular alterations that define other CNS tumors are classified as CNS embryonal tumors. CNS embryonal tumors include: embryonal tumor with multilayered rosettes (ETMR), *CI9MC*-altered; medulloepithelioma; CNS embryonal tumor, not otherwise specified (NOS); atypical teratoid/rhabdoid tumors (AT/RTs); and CNS embryonal tumor with rhabdoid features.[1] These tumors will be discussed in this section, with the exception of AT/RTs (refer to the PDQ summary on [Childhood CNS AT/RT Treatment](#) for more information). Pineoblastoma will be discussed in this summary because it shares histologic features with the embryonal tumors and is conventionally treated in the same fashion (refer to the [Childhood Pineoblastoma](#) section of this summary for more information).

Clinical Presentation

For nonmedulloblastoma embryonal tumors, presentation is also relatively rapid and depends on the location of the tumor in the nervous system. Embryonal tumors tend to be fast-growing tumors and are usually diagnosed within 3 months of initial onset of symptoms.

Nonmedulloblastoma embryonal tumors may occur anywhere in the CNS, and presentation is variable. Usually there is significant neurologic dysfunction associated with lethargy and vomiting. Supratentorial embryonal tumors (refer to [Figure 1](#)) will result in focal neurologic deficits such as hemiparesis and visual field loss, depending on which portion of the cerebral cortex is involved. They may also result in seizures and obtundation.

Cellular and Molecular Classification

The WHO Classification of Tumors of the CNS classifies nonmedulloblastoma embryonal tumors primarily by histologic and immunohistologic features, with the exception of ETMR and atypical teratoid tumor with rhabdoid features.[1] By definition, these tumors arise in the cerebral hemisphere, brain stem, or spinal cord and are composed of undifferentiated or poorly differentiated neuroepithelial cells that may display divergent differentiation. This classification, based on the histopathological characteristics and location of the tumor, is as follows:

- ETMR, *CI9MC*-altered.
- ETMR, NOS.

- Medulloepithelioma.
- CNS neuroblastoma.
- CNS ganglioneuroblastoma.
- CNS embryonal tumor, NOS.
- AT/RT.
- CNS embryonal tumor with rhabdoid features.

CNS embryonal tumors that demonstrate distinct areas of neuronal differentiation are termed *cerebral neuroblastomas* and, if ganglion cells are present, *ganglioneuroblastomas*. Likewise, medulloepitheliomas have a specific histologic pattern and remain a separate entity.[1,2]

Genomic molecular characterizations of embryonal tumors and pineoblastomas have demonstrated substantial heterogeneity among these tumors. These tumors are also molecularly different from medulloblastomas.[3,4]

Although the WHO classification system does not yet use molecular findings to classify nonmedulloblastoma embryonal tumors (except for ETMR, *C19MC*-altered and AT/RT with *SMARCB1* loss), future classification will most likely be based on both histological and molecular findings and, possibly, site of origin in the nervous system.

Subtypes of nonmedulloblastoma embryonal tumors

Molecular subtypes of nonmedulloblastoma embryonal tumors

A study applying unsupervised clustering of DNA methylation patterns for 323 nonmedulloblastoma embryonal tumors found that approximately one-half of these tumors diagnosed as nonmedulloblastoma embryonal tumors showed molecular profiles characteristic of other known pediatric brain tumors (e.g., high-grade glioma and atypical teratoid/rhabdoid tumor [AT/RT]).[4] This observation highlights the utility of molecular characterization to assign this class of tumors to their appropriate biology-based diagnosis.

Among the same collection of 323 tumors diagnosed as nonmedulloblastoma embryonal tumors, molecular characterization identified genomically and biologically distinctive subtypes, including the following:

- **Embryonal tumor with multilayered rosettes (ETMR):** Representing 11% of the 323 cases, this subtype combines embryonal rosette-forming neuroepithelial brain tumors that were previously categorized as either embryonal tumor with abundant neuropil and true rosettes (ETANTR), ependymoblastoma, or medulloepithelioma.[4,5] ETMRs arise in young children (median age at diagnosis, 2–3 years) and show a highly

aggressive clinical course, with a median progression-free survival (PFS) of less than 1 year and few long-term survivors.[5-7]

ETMRs are defined at the molecular level by high-level amplification of the microRNA cluster C19MC and by a gene fusion between *TTYH1* and *C19MC*. [5,8,9] This gene fusion puts expression of C19MC under control of the *TTYH1* promoter, leading to high-level aberrant expression of the microRNAs within the cluster. The World Health Organization (WHO) allows histologically similar tumors without *C19MC* alteration to be classified as ETMR, not otherwise specified (NOS).

- **Central nervous system (CNS) neuroblastoma with FOXR2 activation (CNS NB-FOXR2):** Representing 14% of the 323 cases, this subtype is characterized by genomic alterations that lead to increased expression of the transcription factor FOXR2.[4] CNS NB-FOXR2 is primarily observed in children younger than 10 years, and the histology of these tumors is typically that of CNS neuroblastoma or CNS ganglioneuroblastoma.[4] There is no single genomic alteration among CNS NB-FOXR2 tumors leading to FOXR2 overexpression, with gene fusions involving multiple *FOXR2* partners identified.[4] This subtype has not been added to the WHO diagnostic lexicon.
- **CNS Ewing sarcoma family tumor with CIC alteration (CNS EFT-CIC):** Representing 4% of the 323 cases, this subtype is characterized by genomic alterations affecting *CIC* (located on chromosome 19q13.2), with fusion to *NUTM1* being identified in several cases tested.[4] *CIC* gene fusions are also identified in extra-CNS Ewing-like sarcomas, and the gene expression signature of CNS EFT-CIC tumors is similar to that of these sarcomas.[4] CNS EFT-CIC tumors generally occur in children younger than 10 years and are characterized by a small cell phenotype but with variable histology.[4] This subtype has not been added to the WHO diagnostic lexicon.
- **CNS high-grade neuroepithelial tumor with MNI alteration (CNS HGNET-MN1):** Representing 3% of the 323 cases, this subtype is characterized by gene fusions involving *MNI* (located on chromosome 22q12.3), with fusion partners including *BEND2* and *CXXC5*. [4] The CNS HGNET-MN1 subtype shows a striking female predominance and tends to occur in the second decade of life.[4] This subtype contained most cases carrying a diagnosis of astroblastoma as per the 2007 WHO classification scheme.[4] This subtype has not been added to the WHO diagnostic lexicon. Two other reports that together examined 35 cases of histologically defined astroblastoma found that 14 showed methylation profiles consistent with CNS HGNET-MN1 and/or *MNI* alterations by fluorescence *in situ* hybridization.[10,11]
- **CNS high-grade neuroepithelial tumor with BCOR alteration (CNS HGNET-BCOR):** Representing 3% of the 323 cases, this subtype is characterized by internal tandem duplications of *BCOR*, [4] a genomic alteration that is also found in clear cell sarcoma of the kidney.[12,13] While the median age at diagnosis is younger than 10 years, cases arising in the second decade of life and beyond do occur.[4] This subtype has not been added to the WHO diagnostic lexicon.

The contribution of DNA methylation profiling to correctly diagnose supratentorial embryonal tumors was demonstrated in a clinical trial of patients with supratentorial primitive neuroectodermal tumors of the CNS (CNS-PNET) and pineoblastoma.[14] For the pineoblastoma cases, there was high concordance between the diagnosis made by methylation profiling and the diagnosis made by central pathology review diagnosis (26 of 29). However,

for the remaining 31 patients, the diagnosis made by methylation profiling was high-grade glioma in 18 patients, AT/RT in 2 patients, and *RELA*-fusion–positive ependymoma in 2 patients. Adjudication of discrepancies between the diagnosis made by central review pathology and the diagnosis made by methylation profiling was in favor of methylation profiling in the ten cases that were re-examined.

Medulloepithelioma

Medulloepithelioma with the classic *C19MC* amplification is considered an ETMR, *C19MC*-altered (refer to the ETMR information above). However, when a tumor has the histological features of medulloepithelioma, but without a *C19MC* amplification, it is identified as a histologically discrete tumor within the WHO classification system and called *medulloepithelioma*.^[15,16] Medulloepithelioma tumors are rare and tend to arise most commonly in infants and young children. Medulloepitheliomas, which histologically recapitulate the embryonal neural tube, tend to arise supratentorially, primarily intraventricularly, but may arise infratentorially, in the cauda, and even extraneurally, along nerve roots.^[15,16]

Intraocular medulloepithelioma is biologically distinct from intra-axial medulloepithelioma.^[17,18]

Staging Evaluation

Patients with nonmedulloblastoma, nonmedulloepithelioma embryonal tumors are staged in a fashion similar to that used for children with medulloblastoma; however, the patients are not assigned to average-risk and high-risk subgroups for treatment purposes (refer to the medulloblastoma [Staging Evaluation](#) section of this summary for more information).

Medulloepitheliomas frequently disseminate to the neuraxis.^[19] Medulloepithelioma is staged in the same way as medulloblastoma; however, the patients are not assigned to average-risk and high-risk subgroups for treatment purposes (refer to the medulloblastoma [Staging Evaluation](#) section of this summary for more information).

Treatment Option Overview for Childhood Nonmedulloblastoma Embryonal Tumors

[Table 4](#) describes the standard treatment options for newly diagnosed and recurrent childhood nonmedulloblastoma, nonmedulloepithelioma embryonal tumors and medulloepithelioma.

Table 4. Standard Treatment Options for Childhood Nonmedulloblastoma, Nonmedulloepithelioma Embryonal Tumors and Medulloepithelioma

Treatment Group		Standard Treatment Options
Newly diagnosed childhood	Children aged 3	Surgery

Treatment Group		Standard Treatment Options
nonmedulloblastoma, nonmedulloepithelioma embryonal tumors	years and younger	Adjuvant chemotherapy
	Children older than 3 years	Surgery
		Adjuvant radiation therapy
	Adjuvant chemotherapy	
Newly diagnosed childhood embryonal tumors with multilayered rosettes or medulloepithelioma		Surgery and adjuvant therapy
Recurrent childhood nonmedulloblastoma embryonal tumors		There are no standard treatment options. (Refer to the Treatment of Recurrent Childhood Medulloblastoma and Other CNS Embryonal Tumors section of this summary for more information.)

Treatment of Childhood Nonmedulloblastoma Embryonal Tumors

(Refer to the PDQ summary on [Childhood Central Nervous System Atypical Teratoid/Rhabdoid Tumor Treatment](#) for more information about the treatment of CNS atypical teratoid/rhabdoid tumors.)

(Refer to the [Treatment of Childhood Embryonal Tumor With Multilayered Rosettes or Medulloepithelioma](#) section of this summary for information about the treatment of medulloepithelioma.)

Treatment of children aged 3 years and younger

Standard treatment options for children aged 3 years and younger with newly diagnosed nonmedulloblastoma, nonmedulloepithelioma embryonal tumors include the following:

1. Surgery.
2. Adjuvant chemotherapy.

Treatment of children aged 3 years and younger with nonmedulloblastoma, nonmedulloepithelioma embryonal tumors is similar to that outlined for children aged 3 years and younger with medulloblastoma. (Refer to the medulloblastoma [Treatment of children aged 3 years and younger](#) section of this summary for more information).

With the use of chemotherapy alone, outcome has been variable, with survival rates at 5 years ranging between 0% and 50%.[20-22]; [23][Level of evidence: 2Di] The addition of craniospinal irradiation to chemotherapy-based regimens may successfully treat some children but with anticipated neurodevelopmental decline.[24][Level of evidence: 2A]

Treatment of children older than 3 years

Standard treatment options for children older than 3 years with newly diagnosed nonmedulloblastoma, nonmedulloepithelioma embryonal tumors include the following:

1. Surgery.
2. Adjuvant radiation therapy.
3. Adjuvant chemotherapy.

Surgery

Evidence (surgery):

1. Attempting aggressive surgical resection is the first step in the management of newly diagnosed nonmedulloblastoma embryonal tumors. Although previous studies did not demonstrate that the extent of resection is predictive of outcome,[25-27] one study demonstrated an improved survival when the tumor was completely resected.[28][Level of evidence: 2A] A published study (COG-ACNS0332 [NCT00392327]) of molecularly classified nonmedulloblastoma embryonal tumors revealed improved overall survival (OS) for patients who had less than 1.5 cm² of residual disease compared with patients who had more than 1.5 cm² of residual disease.[14][Level of evidence: 1iiA]
2. Nonmedulloblastoma embryonal tumors are often amenable to resection; in reported case series, 50% to 75% of patients were totally or near-totally resected.[25,26]; [14][Level of evidence: 1iiA]

Adjuvant radiation therapy

After surgery, children with nonmedulloblastoma embryonal tumors usually receive treatment similar to that received by children with high-risk medulloblastoma.

Conventionally, patients are treated with radiation to the entire neuraxis with local boost radiation therapy, as given for medulloblastoma.[27] However, the local boost radiation therapy may be problematic because of the size of the tumor and its location in the cerebral cortex. Also, there is no definitive evidence that craniospinal radiation therapy is superior to radiation to the primary tumor site alone in children with nondisseminated lesions.[25-27]

Adjuvant chemotherapy

The chemotherapeutic approaches during and after radiation therapy are similar to those used for children with high-risk medulloblastoma. Three-year to 5-year OS rates of 25% to 50% have been noted.[\[25-27\]](#); [\[28,29\]](#)[\[Level of evidence: 2A\]](#); [\[30\]](#)[\[Level of evidence: 3iiiB\]](#)

In a published study of nonpineal tumors that were diagnosed as CNS primitive neuroectodermal tumors (PNETs) by traditional pathology, 71% of these cases were revealed to be glioblastoma or another diagnosis by DNA methylation studies. Patients with nonmedulloblastoma embryonal tumors (n = 36) (including pineoblastomas, n = 26) had a 5-year OS of 78.5% (95% confidence interval [CI], 62.2%–94.8%). In contrast, the patients with glioblastoma had a 5-year OS of 12% (95% CI, 0%–24.7%). The study showed no benefit for children who received carboplatin or isotretinoin.[\[14\]](#)[\[Level of evidence: 1iiA\]](#) This study highlights the importance of molecular classification of tumors traditionally termed CNS-PNET.[\[4\]](#)

Treatment of Childhood Embryonal Tumors with Multilayered Rosettes or Medulloepithelioma

There are few data on which to base treatment of newly diagnosed medulloepithelioma and embryonal tumor with multilayered rosettes (ETMR). Treatment considerations are usually the same as those for children with high-risk medulloblastoma and for children aged 3 years and younger at diagnosis with other embryonal tumors. (Refer to the [Treatment of children older than 3 years with high-risk medulloblastoma](#) and the [Treatment of children aged 3 years and younger](#) sections of this summary for more information.)

References

1. Louis DN, Perry A, Reifenberger G, et al.: The 2016 World Health Organization Classification of Tumors of the Central Nervous System: a summary. *Acta Neuropathol* 131 (6): 803-20, 2016. [\[PubMed: 27157931\]](#)
2. Benesch M, Sperl D, von Bueren AO, et al.: Primary central nervous system primitive neuroectodermal tumors (CNS-PNETs) of the spinal cord in children: four cases from the German HIT database with a critical review of the literature. *J Neurooncol* 104 (1): 279-86, 2011. [\[PubMed: 21181235\]](#)
3. Pomeroy SL, Tamayo P, Gaasenbeek M, et al.: Prediction of central nervous system embryonal tumour outcome based on gene expression. *Nature* 415 (6870): 436-42, 2002. [\[PubMed: 11807556\]](#)
4. Sturm D, Orr BA, Toprak UH, et al.: New Brain Tumor Entities Emerge from Molecular Classification of CNS-PNETs. *Cell* 164 (5): 1060-72, 2016. [\[PMC free article: PMC5139621\]](#) [\[PubMed: 26919435\]](#)
5. Korshunov A, Sturm D, Ryzhova M, et al.: Embryonal tumor with abundant neuropil and true rosettes (ETANTR), ependymoblastoma, and medulloepithelioma share molecular similarity and comprise a single clinicopathological entity. *Acta Neuropathol* 128 (2): 279-89, 2014. [\[PMC free article: PMC4102829\]](#) [\[PubMed: 24337497\]](#)
6. Picard D, Miller S, Hawkins CE, et al.: Markers of survival and metastatic potential in childhood CNS primitive neuro-ectodermal brain tumours:

- an integrative genomic analysis. *Lancet Oncol* 13 (8): 838-48, 2012. [PMC free article: [PMC3615440](#)] [PubMed: [22691720](#)]
7. Spence T, Sin-Chan P, Picard D, et al.: CNS-PNETs with C19MC amplification and/or LIN28 expression comprise a distinct histogenetic diagnostic and therapeutic entity. *Acta Neuropathol* 128 (2): 291-303, 2014. [PMC free article: [PMC4159569](#)] [PubMed: [24839957](#)]
 8. Kleinman CL, Gerges N, Papillon-Cavanagh S, et al.: Fusion of TTYH1 with the C19MC microRNA cluster drives expression of a brain-specific DNMT3B isoform in the embryonal brain tumor ETMR. *Nat Genet* 46 (1): 39-44, 2014. [PubMed: [24316981](#)]
 9. Li M, Lee KF, Lu Y, et al.: Frequent amplification of a chr19q13.41 microRNA polycistron in aggressive primitive neuroectodermal brain tumors. *Cancer Cell* 16 (6): 533-46, 2009. [PMC free article: [PMC3431561](#)] [PubMed: [19962671](#)]
 10. Wood MD, Tihan T, Perry A, et al.: Multimodal molecular analysis of astroblastoma enables reclassification of most cases into more specific molecular entities. *Brain Pathol* 28 (2): 192-202, 2018. [PMC free article: [PMC5843525](#)] [PubMed: [28960623](#)]
 11. Lehman NL, Usualieva A, Lin T, et al.: Genomic analysis demonstrates that histologically-defined astroblastomas are molecularly heterogeneous and that tumors with MN1 rearrangement exhibit the most favorable prognosis. *Acta Neuropathol Commun* 7 (1): 42, 2019. [PMC free article: [PMC6419470](#)] [PubMed: [30876455](#)]
 12. Ueno-Yokohata H, Okita H, Nakasato K, et al.: Consistent in-frame internal tandem duplications of BCOR characterize clear cell sarcoma of the kidney. *Nat Genet* 47 (8): 861-3, 2015. [PubMed: [26098867](#)]
 13. Roy A, Kumar V, Zorman B, et al.: Recurrent internal tandem duplications of BCOR in clear cell sarcoma of the kidney. *Nat Commun* 6: 8891, 2015. [PMC free article: [PMC4660214](#)] [PubMed: [26573325](#)]
 14. Hwang EI, Kool M, Burger PC, et al.: Extensive Molecular and Clinical Heterogeneity in Patients With Histologically Diagnosed CNS-PNET Treated as a Single Entity: A Report From the Children's Oncology Group Randomized ACNS0332 Trial. *J Clin Oncol : JCO*2017764720, 2018. [PubMed: [30332335](#)]
 15. Louis DN, Ohgaki H, Wiestler OD, et al.: The 2007 WHO classification of tumours of the central nervous system. *Acta Neuropathol* 114 (2): 97-109, 2007. [PMC free article: [PMC1929165](#)] [PubMed: [17618441](#)]
 16. Sharma MC, Mahapatra AK, Gaikwad S, et al.: Pigmented medulloepithelioma: report of a case and review of the literature. *Childs Nerv Syst* 14 (1-2): 74-8, 1998 Jan-Feb. [PubMed: [9548346](#)]
 17. Jakobiec FA, Kool M, Stagner AM, et al.: Intraocular Medulloepitheliomas and Embryonal Tumors With Multilayered Rosettes of the Brain: Comparative Roles of LIN28A and C19MC. *Am J Ophthalmol* 159 (6): 1065-1074.e1, 2015. [PubMed: [25748578](#)]
 18. Korshunov A, Jakobiec FA, Eberhart CG, et al.: Comparative integrated molecular analysis of intraocular medulloepitheliomas and central nervous system embryonal tumors with multilayered rosettes confirms that they are distinct nosologic entities. *Neuropathology* 35 (6): 538-44, 2015. [PubMed: [26183384](#)]
 19. Müller K, Zwiener I, Welker H, et al.: Curative treatment for central nervous system medulloepithelioma despite residual disease after resection. Report of two cases treated according to the GPHO Protocol HIT 2000 and review of the literature. *Strahlenther Onkol* 187 (11): 757-62, 2011. [PubMed: [22037651](#)]

20. Geyer JR, Sposto R, Jennings M, et al.: Multiagent chemotherapy and deferred radiotherapy in infants with malignant brain tumors: a report from the Children's Cancer Group. *J Clin Oncol* 23 (30): 7621-31, 2005. [PubMed: 16234523]
21. Marec-Berard P, Jouvét A, Thiesse P, et al.: Supratentorial embryonal tumors in children under 5 years of age: an SFOP study of treatment with postoperative chemotherapy alone. *Med Pediatr Oncol* 38 (2): 83-90, 2002. [PubMed: 11813171]
22. Grill J, Sainte-Rose C, Jouvét A, et al.: Treatment of medulloblastoma with postoperative chemotherapy alone: an SFOP prospective trial in young children. *Lancet Oncol* 6 (8): 573-80, 2005. [PubMed: 16054568]
23. Fangusaro J, Finlay J, Sposto R, et al.: Intensive chemotherapy followed by consolidative myeloablative chemotherapy with autologous hematopoietic cell rescue (AuHCR) in young children with newly diagnosed supratentorial primitive neuroectodermal tumors (sPNETs): report of the Head Start I and II experience. *Pediatr Blood Cancer* 50 (2): 312-8, 2008. [PubMed: 17668858]
24. Friedrich C, von Bueren AO, von Hoff K, et al.: Treatment of young children with CNS-primitive neuroectodermal tumors/pineoblastomas in the prospective multicenter trial HIT 2000 using different chemotherapy regimens and radiotherapy. *Neuro Oncol* 15 (2): 224-34, 2013. [PMC free article: PMC3548584] [PubMed: 23223339]
25. Cohen BH, Zeltzer PM, Boyett JM, et al.: Prognostic factors and treatment results for supratentorial primitive neuroectodermal tumors in children using radiation and chemotherapy: a Children's Cancer Group randomized trial. *J Clin Oncol* 13 (7): 1687-96, 1995. [PubMed: 7602359]
26. Reddy AT, Janss AJ, Phillips PC, et al.: Outcome for children with supratentorial primitive neuroectodermal tumors treated with surgery, radiation, and chemotherapy. *Cancer* 88 (9): 2189-93, 2000. [PubMed: 10813733]
27. Timmermann B, Kortmann RD, Köhl J, et al.: Role of radiotherapy in the treatment of supratentorial primitive neuroectodermal tumors in childhood: results of the prospective German brain tumor trials HIT 88/89 and 91. *J Clin Oncol* 20 (3): 842-9, 2002. [PubMed: 11821469]
28. Jakacki RI, Burger PC, Kocak M, et al.: Outcome and prognostic factors for children with supratentorial primitive neuroectodermal tumors treated with carboplatin during radiotherapy: a report from the Children's Oncology Group. *Pediatr Blood Cancer* 62 (5): 776-83, 2015. [PMC free article: PMC4376578] [PubMed: 25704363]
29. Chintagumpala M, Hassall T, Palmer S, et al.: A pilot study of risk-adapted radiotherapy and chemotherapy in patients with supratentorial PNET. *Neuro Oncol* 11 (1): 33-40, 2009. [PMC free article: PMC2718957] [PubMed: 18796696]
30. Johnston DL, Keene DL, Lafay-Cousin L, et al.: Supratentorial primitive neuroectodermal tumors: a Canadian pediatric brain tumor consortium report. *J Neurooncol* 86 (1): 101-8, 2008. [PubMed: 17619825]

Childhood Pineoblastoma

The World Health Organization (WHO) classifies pineoblastomas in the tumors of the pineal region group. However, they are discussed in this summary because they share histologic features with other embryonal tumors and are conventionally treated as other embryonal tumors.[1]

Clinical Presentation

Pineoblastoma often results in hydrocephalus due to blockage of cerebrospinal fluid at the third ventricular level and other symptoms related to pressure on the back of the brain stem in the tectal region. Symptoms may include a constellation of abnormalities in eye movements (Parinaud syndrome) manifested by pupils that react poorly to light but better to accommodation, loss of upgaze, retraction or convergence nystagmus, and lid retraction. As they grow, these tumors may also cause hemiparesis and ataxia.[2]

Cellular and Molecular Classification

Pineoblastoma is histologically similar to medulloblastoma and shares histologic features with embryonal tumors; however, because of the WHO classification, its histogenesis is linked to the pineocyte (a type of pineal cell) and is classified separately.[1] This classification does not take into account the molecular genetic makeup of these tumors.[1]

Genomic molecular characterizations of embryonal tumors and pineoblastomas have demonstrated substantial heterogeneity among these tumors. These tumors are also molecularly different from medulloblastomas.[3,4]

Although the WHO classification system does not yet use molecular findings to classify nonmedulloblastoma embryonal tumors, future classification will most likely be based on both histological and molecular findings and, possibly, the site of origin in the nervous system.

Pineoblastoma, which was previously conventionally grouped with embryonal tumors, is now categorized by the World Health Organization (WHO) as a pineal parenchymal tumor. Given that therapies for pineoblastoma are quite similar to those utilized for embryonal tumors, the previous convention of including pineoblastoma with the central nervous system (CNS) embryonal tumors is followed here. Pineoblastoma is associated with germline mutations in both the *RBI* gene and in *DICER1*, as described below:

- Pineoblastoma is associated with germline mutations in *RBI*, with the term *trilateral retinoblastoma* used to refer to ocular retinoblastoma in combination with a histologically similar brain tumor generally arising in the pineal gland or other midline structures. Historically, intracranial tumors have been reported in 5% to 15% of children with heritable retinoblastoma.[5] Rates of pineoblastoma among children with heritable retinoblastoma who undergo current treatment programs may be lower than these historical estimates.[6-8]
- Germline *DICER1* mutations have also been reported in patients with pineoblastoma.[9] Among 18 patients with pineoblastoma, 3 patients with *DICER1* germline mutations were identified, and an additional 3 patients known to be carriers of germline *DICER1* mutations developed pineoblastoma.[9] The *DICER1* mutations in patients with pineoblastoma are loss-of-function mutations that appear to be distinct from the mutations observed in *DICER1* syndrome-related tumors such as pleuropulmonary blastoma.
[9]

Staging Evaluation

Dissemination at the time of diagnosis occurs in 10% to 30% of patients with pineoblastoma.[10] Because of the location of the tumor, total resections are uncommon, and most patients have only a biopsy or a subtotal resection before postsurgical treatment.[10,11] Staging for children with pineoblastomas is the same as that performed for children with medulloblastoma; however, the patients are not assigned to average-risk and high-risk subgroups for treatment purposes (refer to the medulloblastoma [Staging Evaluation](#) section of this summary for more information).[10]

Treatment Option Overview for Childhood Pineoblastoma

Table 5 describes the standard treatment options for newly diagnosed and recurrent childhood pineoblastoma.

Table 5. Standard Treatment Options for Childhood Pineoblastoma

Treatment Group		Standard Treatment Options
Newly diagnosed childhood pineoblastoma	Children aged 3 years and younger	Biopsy (for diagnosis) or subtotal resection
		Adjuvant chemotherapy
		High-dose, marrow-ablative chemotherapy with autologous bone marrow rescue or peripheral stem cell rescue
	Children older than 3 years	Surgery
		Adjuvant radiation therapy
		Adjuvant chemotherapy
Recurrent childhood pineoblastoma		There are no standard treatment options. (Refer to the Treatment of Recurrent Childhood Medulloblastoma and Other CNS Embryonal Tumors section of this summary for more information.)

Treatment of Childhood Pineoblastoma

Treatment of children aged 3 years and younger

Standard treatment options for children aged 3 years and younger with pineoblastoma include the following:

1. [Biopsy \(for diagnosis\) or subtotal resection.](#)

2. Adjuvant chemotherapy.
3. High-dose, marrow-ablative chemotherapy with autologous bone marrow rescue or peripheral stem cell rescue.

Biopsy

Biopsy is usually performed to diagnose pineoblastoma.

Adjuvant chemotherapy

Children aged 3 years and younger with pineoblastoma are usually treated initially with chemotherapy in the hope of delaying, if not obviating, the need for radiation therapy.[12] Overall prognosis for this group of children remains very poor. In two sequential multicenter prospective clinical trials, all five children younger than 3 years who were treated with chemotherapy died.[13][Level of evidence: 2A] In children responding to chemotherapy, the timing and amount of radiation therapy required after chemotherapy is unclear. The addition of craniospinal irradiation to chemotherapy-based regimens may successfully treat some children but with anticipated neurodevelopmental decline.[14][Level of evidence: 2A]

High-dose, marrow-ablative chemotherapy with autologous bone marrow rescue or peripheral stem cell rescue

High-dose, marrow-ablative chemotherapy with autologous bone marrow rescue or peripheral stem cell rescue has been used with some success in young children.[15][Level of evidence: 2Di]

Treatment of children older than 3 years

Standard treatment options for children older than 3 years with newly diagnosed pineoblastoma include the following:

1. Surgery.
2. Adjuvant radiation therapy.
3. Adjuvant chemotherapy.

Surgery

Surgery is usually the initial treatment for patients with pineoblastoma to diagnose the tumor.[16] Total and near-total resection is infrequently obtained in patients with pineoblastoma, and the impact of the degree of resection on outcome is unknown.[10,11]

Adjuvant radiation therapy

The usual postsurgical treatment for patients with pineoblastoma begins with radiation therapy, although some trials have utilized preradiation chemotherapy. The total dose of radiation therapy to the tumor site is 54 Gy to 55.8 Gy using conventional fractionation.[10,11]

Craniospinal irradiation with doses ranging between 23.4 Gy and 36 Gy are also recommended because of the propensity of this tumor to disseminate throughout the subarachnoid space.[10,11]

Adjuvant chemotherapy

Chemotherapy is usually utilized in the same way as outlined for high-risk medulloblastomas in children with nondisseminated disease at the time of diagnosis. (Refer to the [Treatment of children older than 3 years with high-risk medulloblastoma](#) section in this summary for more information.)

The 5-year disease-free survival rate exceeds 50% in children with localized disease at diagnosis undergoing aggressive resection.[10,11,17,18][[Level of evidence: 1iiA](#)] The Children's Oncology Group (COG) [COG-ACNS0332 \(NCT00392327\)](#) study of 36 patients with nonmedulloblastoma embryonal tumors (which included 26 pineoblastomas) reported a 5-year overall survival (OS) of 78.5% (95% confidence interval, 62.2%–94.8%).[18][[Level of evidence: 1iiA](#)]

For patients with disseminated disease at the time of diagnosis, survival is considerably poorer.[10,11] In the [COG-ACNS0332 \(NCT00392327\)](#) study, there was no significant difference in event-free survival or OS according to metastatic status.

Treatment options under clinical evaluation for childhood pineoblastoma

For patients with pineoblastoma, a variety of different treatment approaches are under evaluation, including the use of higher doses of chemotherapy after radiation therapy supported by peripheral stem cell rescue and the use of chemotherapy during radiation therapy.

Early-phase therapeutic trials may be available for selected patients. These trials may be available via the [COG](#), the [Pediatric Brain Tumor Consortium](#), or other entities. Information about National Cancer Institute (NCI)–supported clinical trials can be found on the [NCI website](#). For information about clinical trials sponsored by other organizations, refer to the [ClinicalTrials.gov website](#).

References

1. Louis DN, Perry A, Reifenberger G, et al.: The 2016 World Health Organization Classification of Tumors of the Central Nervous System: a summary. *Acta Neuropathol* 131 (6): 803-20, 2016. [[PubMed: 27157931](#)]
2. Chintagumpala MM, Paulino A, Panigrahy A, et al.: Embryonal and pineal region tumors. In: Pizzo PA, Poplack DG, eds.: *Principles and Practice*

- of Pediatric Oncology. 7th ed. Philadelphia, Pa: Lippincott Williams and Wilkins, 2015, pp 671-99.
3. Pomeroy SL, Tamayo P, Gaasenbeek M, et al.: Prediction of central nervous system embryonal tumour outcome based on gene expression. *Nature* 415 (6870): 436-42, 2002. [PubMed: 11807556]
 4. Sturm D, Orr BA, Toprak UH, et al.: New Brain Tumor Entities Emerge from Molecular Classification of CNS-PNETs. *Cell* 164 (5): 1060-72, 2016. [PMC free article: PMC5139621] [PubMed: 26919435]
 5. de Jong MC, Kors WA, de Graaf P, et al.: Trilateral retinoblastoma: a systematic review and meta-analysis. *Lancet Oncol* 15 (10): 1157-67, 2014. [PubMed: 25126964]
 6. Ramasubramanian A, Kytasty C, Meadows AT, et al.: Incidence of pineal gland cyst and pineoblastoma in children with retinoblastoma during the chemoreduction era. *Am J Ophthalmol* 156 (4): 825-9, 2013. [PubMed: 23876864]
 7. Abramson DH, Dunkel IJ, Marr BP, et al.: Incidence of pineal gland cyst and pineoblastoma in children with retinoblastoma during the chemoreduction era. *Am J Ophthalmol* 156 (6): 1319-20, 2013. [PubMed: 24238207]
 8. Turaka K, Shields CL, Meadows AT, et al.: Second malignant neoplasms following chemoreduction with carboplatin, etoposide, and vincristine in 245 patients with intraocular retinoblastoma. *Pediatr Blood Cancer* 59 (1): 121-5, 2012. [PubMed: 21826785]
 9. de Kock L, Sabbaghian N, Druker H, et al.: Germ-line and somatic DICER1 mutations in pineoblastoma. *Acta Neuropathol* 128 (4): 583-95, 2014. [PMC free article: PMC4381868] [PubMed: 25022261]
 10. Jakacki RI, Zeltzer PM, Boyett JM, et al.: Survival and prognostic factors following radiation and/or chemotherapy for primitive neuroectodermal tumors of the pineal region in infants and children: a report of the Childrens Cancer Group. *J Clin Oncol* 13 (6): 1377-83, 1995. [PubMed: 7751882]
 11. Timmermann B, Kortmann RD, Köhl J, et al.: Role of radiotherapy in the treatment of supratentorial primitive neuroectodermal tumors in childhood: results of the prospective German brain tumor trials HIT 88/89 and 91. *J Clin Oncol* 20 (3): 842-9, 2002. [PubMed: 11821469]
 12. Mason WP, Grovas A, Halpern S, et al.: Intensive chemotherapy and bone marrow rescue for young children with newly diagnosed malignant brain tumors. *J Clin Oncol* 16 (1): 210-21, 1998. [PubMed: 9440745]
 13. Hinkes BG, von Hoff K, Deinlein F, et al.: Childhood pineoblastoma: experiences from the prospective multicenter trials HIT-SKK87, HIT-SKK92 and HIT91. *J Neurooncol* 81 (2): 217-23, 2007. [PubMed: 16941074]
 14. Friedrich C, von Bueren AO, von Hoff K, et al.: Treatment of young children with CNS-primitive neuroectodermal tumors/pineoblastomas in the prospective multicenter trial HIT 2000 using different chemotherapy regimens and radiotherapy. *Neuro Oncol* 15 (2): 224-34, 2013. [PMC free article: PMC3548584] [PubMed: 23223339]
 15. Fangusaro J, Finlay J, Sposto R, et al.: Intensive chemotherapy followed by consolidative myeloablative chemotherapy with autologous hematopoietic cell rescue (AuHCR) in young children with newly diagnosed supratentorial primitive neuroectodermal tumors (sPNETs): report of the Head Start I and II experience. *Pediatr Blood Cancer* 50 (2): 312-8, 2008. [PubMed: 17668858]
 16. Jakacki RI, Burger PC, Kocak M, et al.: Outcome and prognostic factors for children with supratentorial primitive neuroectodermal tumors treated

- with carboplatin during radiotherapy: a report from the Children's Oncology Group. *Pediatr Blood Cancer* 62 (5): 776-83, 2015. [PMC free article: PMC4376578] [PubMed: 25704363]
17. Gururangan S, McLaughlin C, Quinn J, et al.: High-dose chemotherapy with autologous stem-cell rescue in children and adults with newly diagnosed pineoblastomas. *J Clin Oncol* 21 (11): 2187-91, 2003. [PubMed: 12775745]
18. Hwang EI, Kool M, Burger PC, et al.: Extensive Molecular and Clinical Heterogeneity in Patients With Histologically Diagnosed CNS-PNET Treated as a Single Entity: A Report From the Children's Oncology Group Randomized ACNS0332 Trial. *J Clin Oncol* : JCO2017764720, 2018. [PubMed: 30332335]

Treatment of Recurrent Childhood Medulloblastoma and Other CNS Embryonal Tumors

Recurrence of all forms of central nervous system (CNS) embryonal tumors is not uncommon and usually occurs within 36 months of treatment. However, recurrent tumors may develop many years after initial treatment.[1-3] In such *late* relapses, especially those occurring 5 or more years after diagnosis, differentiation from secondary tumors such as high-grade gliomas can be difficult, and histological confirmation is recommended and usually required. Disease may recur at the primary site or may be disseminated at the time of relapse. Sites of noncontiguous relapse may include the spinal leptomeninges, intracranial sites, and cerebrospinal fluid, in isolation or in any combination, and may be associated with primary tumor relapse.[1,2,4] Extraneural disease relapse may occur but is rare and is seen primarily in patients who were treated with radiation therapy alone.[5][Level of evidence: 3iiiA]

Studies have found that even in patients with nondisseminated disease at diagnosis, and independent of the dose of radiation therapy or the type of chemotherapy, approximately one-third of patients will relapse at the primary tumor site alone; one-third will relapse at the primary tumor site plus distant sites; and one-third will relapse at distant sites without relapse at the primary site.[1,2,4]

Treatment Options

There are no standard treatment options for recurrent childhood CNS embryonal tumors. (Refer to the [Treatment for Recurrent Childhood CNS Atypical Teratoid/Rhabdoid Tumor](#) section in the PDQ summary on [Childhood Central Nervous System Atypical Teratoid/Rhabdoid Tumor Treatment](#) for more information.)

For most children, treatment is palliative, and disease control is transient in patients previously treated with radiation therapy and chemotherapy, with more than 80% of patients progressing within 2 years.[3]; [6][Level of evidence: 3iB] For young children, predominantly those younger than 3 years at diagnosis who were never treated with radiation therapy, longer-term control with reoperation, radiation therapy, and chemotherapy is possible.[4,7-9]

Treatment approaches may include the following:

1. Surgery.
2. Radiation therapy.
3. Chemotherapy.
4. High-dose chemotherapy with stem cell rescue.
5. Molecularly targeted therapy.

Surgery

At the time of relapse, a complete evaluation for extent of recurrence is indicated for all embryonal tumors. Biopsy or surgical resection may be necessary for confirmation of relapse because other entities such as secondary tumors and treatment-related brain necrosis may be clinically indistinguishable from tumor recurrence. The need for surgical intervention must be individualized on the basis of the initial tumor type, the length of time between initial treatment and the reappearance of the lesion, and clinical symptomatology.

Radiation therapy

Patients with recurrent embryonal tumors who have already received radiation therapy and chemotherapy may be candidates for further radiation therapy depending on the site and dose of previous radiation, including reirradiation at the primary tumor site, focal areas of radiation therapy to sites of disseminated disease and, rarely, craniospinal radiation therapy.[10] In most cases, such therapy is palliative. Stereotactic radiation therapy and/or salvage chemotherapy can also be used (refer to the Chemotherapy subsection of this summary for more information).[11]

Chemotherapy

Recurrent CNS embryonal tumors can respond to chemotherapeutic agents used singularly or in combination, including cyclophosphamide, cisplatin, carboplatin, lomustine, etoposide, topotecan, temozolomide, and antiangiogenic metronomic therapy.[7,12-21]; [22,23][Level of evidence: 2A]

Approximately 30% to 50% of these patients will have objective responses to conventional chemotherapy, but long-term disease control is rare.

For select patients with recurrent medulloblastoma—primarily infants and young children who were treated at the time of diagnosis with chemotherapy alone and who developed local recurrence—long-term disease control may be obtained after further treatment with chemotherapy plus local radiation therapy; this potential may be greatest in patients who are able to undergo complete resection of the recurrent disease.[24][Level of evidence: 2A]; [25][Level of evidence: 3iiiA]

In a St. Jude Children's Research Hospital study (SJYC07 [NCT00602667]), 29 patients with progressive disease received craniospinal irradiation

(median dose, 36 Gy; interquartile range, 36–36). Of the 29 patients who received craniospinal irradiation, 18 patients (62%) were alive at the time of publication, compared with 6 of 25 patients (24%) who did not receive craniospinal irradiation.[26][Level of evidence: 2Di]

High-dose chemotherapy with stem cell rescue

For patients who have previously received radiation therapy, higher-dose chemotherapeutic regimens, supported with autologous bone marrow rescue or peripheral stem cell support, have been used with variable results.[8,9,27-30][Level of evidence: 2A]; [31][Level of evidence: 3iiB]; [32,33][Level of evidence: 3iiiA]

1. With such regimens, objective response is frequent, occurring in 50% to 75% of patients; however, long-term disease control is obtained in fewer than 30% of patients and is seen primarily in patients in first relapse and in those with only localized disease at the time of relapse.[9]; [30][Level of evidence: 2A]; [31][Level of evidence: 3iiB]
2. Additionally, results from national trials for relapsed medulloblastoma that specified *intent to transplant* as part of their treatment plan showed that only approximately 5% of patients initiating retrieval therapy achieve long-term disease-free survival with this strategy.[30,34] Thus, studies that report from the time of transplant overestimate the benefit of transplant-based approaches for the total population of relapsing patients.
3. Long-term disease control for patients with disseminated disease is infrequent.[35][Level of evidence: 3iA]

Molecularly targeted therapy

With the increased knowledge of the molecular and genetic changes associated with different subtypes of medulloblastoma, *molecularly targeted therapy*, also called precision therapy, is being actively explored in children with recurrent disease.

In patients with recurrent sonic hedgehog (SHH) medulloblastomas, the SHH *PTCH1* inhibitor vismodegib demonstrated radiographic responses in 3 of 12 pediatric-aged patients, with two responses being sustained for less than 2 months and one response for more than 6 months. Only patients with upstream mutations of the SHH pathway, at the level of *PTCH1* or *SMO*, responded.[36] However, because of the development of irreversible growth plate fusions, the use of vismodegib is limited to skeletally mature children.[37]

Treatment Options Under Clinical Evaluation for Recurrent Childhood Medulloblastoma and Other CNS Embryonal Tumors

Early-phase therapeutic trials may be available for selected patients. These trials may be available via the [Children's Oncology Group \(COG\)](#), the [Pediatric Brain Tumor Consortium](#), or other entities. Information about National Cancer Institute (NCI)–supported clinical trials can be found on the [NCI website](#). For information about clinical trials sponsored by other organizations, refer to the [ClinicalTrials.gov website](#).

The following is an example of a national and/or institutional clinical trial that is currently being conducted:

- **APEC1621 (NCT03155620)** (Pediatric MATCH: Targeted Therapy Directed by Genetic Testing in Treating Pediatric Patients with Relapsed or Refractory Advanced Solid Tumors, Non-Hodgkin Lymphomas, or Histiocytic Disorders): NCI-COG Pediatric Molecular Analysis for Therapeutic Choice (MATCH), referred to as Pediatric MATCH, will match targeted agents with specific molecular changes identified using a next-generation sequencing targeted assay of more than 4,000 different mutations across more than 160 genes in refractory and recurrent solid tumors. Children and adolescents aged 1 to 21 years are eligible for the trial.

Tumor tissue from progressive or recurrent disease must be available for molecular characterization. Patients with tumors that have molecular variants addressed by treatment arms included in the trial will be offered treatment on Pediatric MATCH. Additional information can be obtained on the [NCI website](#) and [ClinicalTrials.gov website](#).

Current Clinical Trials

Use our [advanced clinical trial search](#) to find NCI-supported cancer clinical trials that are now enrolling patients. The search can be narrowed by location of the trial, type of treatment, name of the drug, and other criteria. [General information](#) about clinical trials is also available.

References

1. Taylor RE, Bailey CC, Robinson K, et al.: Results of a randomized study of preradiation chemotherapy versus radiotherapy alone for nonmetastatic medulloblastoma: The International Society of Paediatric Oncology/United Kingdom Children's Cancer Study Group PNET-3 Study. *J Clin Oncol* 21 (8): 1581-91, 2003. [PubMed: 12697884]
2. Packer RJ, Goldwein J, Nicholson HS, et al.: Treatment of children with medulloblastomas with reduced-dose craniospinal radiation therapy and adjuvant chemotherapy: A Children's Cancer Group Study. *J Clin Oncol* 17 (7): 2127-36, 1999. [PubMed: 10561268]
3. Sabel M, Fleischhack G, Tippelt S, et al.: Relapse patterns and outcome after relapse in standard risk medulloblastoma: a report from the HIT-SIOP-PNET4 study. *J Neurooncol* 129 (3): 515-524, 2016. [PMC free article: PMC5020107] [PubMed: 27423645]
4. Oyharcabal-Bourden V, Kalifa C, Gentet JC, et al.: Standard-risk medulloblastoma treated by adjuvant chemotherapy followed by reduced-dose craniospinal radiation therapy: a French Society of Pediatric Oncology Study. *J Clin Oncol* 23 (21): 4726-34, 2005. [PubMed: 16034048]
5. Mazloom A, Zangeneh AH, Paulino AC: Prognostic factors after extraneural metastasis of medulloblastoma. *Int J Radiat Oncol Biol Phys* 78 (1): 72-8, 2010. [PubMed: 20133080]
6. Johnston DL, Keene D, Strother D, et al.: Survival Following Tumor Recurrence in Children With Medulloblastoma. *J Pediatr Hematol Oncol* 40 (3): e159-e163, 2018. [PubMed: 29432312]
7. Gentet JC, Doz F, Bouffet E, et al.: Carboplatin and VP 16 in medulloblastoma: a phase II Study of the French Society of Pediatric Oncology

- (SFOP). *Med Pediatr Oncol* 23 (5): 422-7, 1994. [PubMed: 8084309]
8. Kadota RP, Mahoney DH, Doyle J, et al.: Dose intensive melphalan and cyclophosphamide with autologous hematopoietic stem cells for recurrent medulloblastoma or germinoma. *Pediatr Blood Cancer* 51 (5): 675-8, 2008. [PMC free article: PMC2900925] [PubMed: 18623206]
 9. Butturini AM, Jacob M, Aguajo J, et al.: High-dose chemotherapy and autologous hematopoietic progenitor cell rescue in children with recurrent medulloblastoma and supratentorial primitive neuroectodermal tumors: the impact of prior radiotherapy on outcome. *Cancer* 115 (13): 2956-63, 2009. [PubMed: 19402050]
 10. Wetmore C, Herington D, Lin T, et al.: Reirradiation of recurrent medulloblastoma: does clinical benefit outweigh risk for toxicity? *Cancer* 120 (23): 3731-7, 2014. [PMC free article: PMC4364918] [PubMed: 25080363]
 11. Abe M, Tokumaru S, Tabuchi K, et al.: Stereotactic radiation therapy with chemotherapy in the management of recurrent medulloblastomas. *Pediatr Neurosurg* 42 (2): 81-8, 2006. [PubMed: 16465076]
 12. Friedman HS, Oakes WJ: The chemotherapy of posterior fossa tumors in childhood. *J Neurooncol* 5 (3): 217-29, 1987. [PubMed: 3316521]
 13. Needle MN, Molloy PT, Geyer JR, et al.: Phase II study of daily oral etoposide in children with recurrent brain tumors and other solid tumors. *Med Pediatr Oncol* 29 (1): 28-32, 1997. [PubMed: 9142202]
 14. Gaynon PS, Ettinger LJ, Baum ES, et al.: Carboplatin in childhood brain tumors. A Children's Cancer Study Group Phase II trial. *Cancer* 66 (12): 2465-9, 1990. [PubMed: 2249186]
 15. Allen JC, Walker R, Luks E, et al.: Carboplatin and recurrent childhood brain tumors. *J Clin Oncol* 5 (3): 459-63, 1987. [PubMed: 3546620]
 16. Ashley DM, Longee D, Tien R, et al.: Treatment of patients with pineoblastoma with high dose cyclophosphamide. *Med Pediatr Oncol* 26 (6): 387-92, 1996. [PubMed: 8614374]
 17. Lefkowitz IB, Packer RJ, Siegel KR, et al.: Results of treatment of children with recurrent medulloblastoma/primitive neuroectodermal tumors with lomustine, cisplatin, and vincristine. *Cancer* 65 (3): 412-7, 1990. [PubMed: 2153428]
 18. Friedman HS, Mahaley MS, Schold SC, et al.: Efficacy of vincristine and cyclophosphamide in the therapy of recurrent medulloblastoma. *Neurosurgery* 18 (3): 335-40, 1986. [PubMed: 3703192]
 19. Castello MA, Clerico A, Deb G, et al.: High-dose carboplatin in combination with etoposide (JET regimen) for childhood brain tumors. *Am J Pediatr Hematol Oncol* 12 (3): 297-300, 1990. [PubMed: 2173440]
 20. Cefalo G, Massimino M, Ruggiero A, et al.: Temozolomide is an active agent in children with recurrent medulloblastoma/primitive neuroectodermal tumor: an Italian multi-institutional phase II trial. *Neuro Oncol* 16 (5): 748-53, 2014. [PMC free article: PMC3984557] [PubMed: 24482446]
 21. Le Teuff G, Castaneda-Heredia A, Dufour C, et al.: Phase II study of temozolomide and topotecan (TOTEM) in children with relapsed or refractory extracranial and central nervous system tumors including medulloblastoma with post hoc Bayesian analysis: A European ITCC study. *Pediatr Blood Cancer* 67 (1): e28032, 2020. [PubMed: 31595663]
 22. Minturn JE, Janss AJ, Fisher PG, et al.: A phase II study of metronomic oral topotecan for recurrent childhood brain tumors. *Pediatr Blood Cancer*

- 56 (1): 39-44, 2011. [PubMed: 21108437]
23. Peyrl A, Chocholous M, Kieran MW, et al.: Antiangiogenic metronomic therapy for children with recurrent embryonal brain tumors. *Pediatr Blood Cancer* 59 (3): 511-7, 2012. [PubMed: 22147459]
 24. Ridola V, Grill J, Doz F, et al.: High-dose chemotherapy with autologous stem cell rescue followed by posterior fossa irradiation for local medulloblastoma recurrence or progression after conventional chemotherapy. *Cancer* 110 (1): 156-63, 2007. [PubMed: 17541945]
 25. Bakst RL, Dunkel IJ, Gilheeneey S, et al.: Reirradiation for recurrent medulloblastoma. *Cancer* 117 (21): 4977-82, 2011. [PubMed: 21495027]
 26. Robinson GW, Rudneva VA, Buchhalter I, et al.: Risk-adapted therapy for young children with medulloblastoma (SJYC07): therapeutic and molecular outcomes from a multicentre, phase 2 trial. *Lancet Oncol* 19 (6): 768-784, 2018. [PMC free article: PMC6078206] [PubMed: 29778738]
 27. Dunkel IJ, Boyett JM, Yates A, et al.: High-dose carboplatin, thiotepa, and etoposide with autologous stem-cell rescue for patients with recurrent medulloblastoma. Children's Cancer Group. *J Clin Oncol* 16 (1): 222-8, 1998. [PubMed: 9440746]
 28. Park JE, Kang J, Yoo KH, et al.: Efficacy of high-dose chemotherapy and autologous stem cell transplantation in patients with relapsed medulloblastoma: a report on the Korean Society for Pediatric Neuro-Oncology (KSPNO)-S-053 study. *J Korean Med Sci* 25 (8): 1160-6, 2010. [PMC free article: PMC2908784] [PubMed: 20676326]
 29. Gilman AL, Jacobsen C, Bunin N, et al.: Phase I study of tandem high-dose chemotherapy with autologous peripheral blood stem cell rescue for children with recurrent brain tumors: a Pediatric Blood and Marrow Transplant Consortium study. *Pediatr Blood Cancer* 57 (3): 506-13, 2011. [PubMed: 21744474]
 30. Pizer B, Donachie PH, Robinson K, et al.: Treatment of recurrent central nervous system primitive neuroectodermal tumours in children and adolescents: results of a Children's Cancer and Leukaemia Group study. *Eur J Cancer* 47 (9): 1389-97, 2011. [PubMed: 21474302]
 31. Massimino M, Gandola L, Spreafico F, et al.: No salvage using high-dose chemotherapy plus/minus reirradiation for relapsing previously irradiated medulloblastoma. *Int J Radiat Oncol Biol Phys* 73 (5): 1358-63, 2009. [PubMed: 19019566]
 32. Gururangan S, Krauser J, Watral MA, et al.: Efficacy of high-dose chemotherapy or standard salvage therapy in patients with recurrent medulloblastoma. *Neuro Oncol* 10 (5): 745-51, 2008. [PMC free article: PMC2666251] [PubMed: 18755919]
 33. Dunkel IJ, Gardner SL, Garvin JH, et al.: High-dose carboplatin, thiotepa, and etoposide with autologous stem cell rescue for patients with previously irradiated recurrent medulloblastoma. *Neuro Oncol* 12 (3): 297-303, 2010. [PMC free article: PMC2940591] [PubMed: 20167818]
 34. Gajjar A, Pizer B: Role of high-dose chemotherapy for recurrent medulloblastoma and other CNS primitive neuroectodermal tumors. *Pediatr Blood Cancer* 54 (4): 649-51, 2010. [PubMed: 20146223]
 35. Bowers DC, Gargan L, Weprin BE, et al.: Impact of site of tumor recurrence upon survival for children with recurrent or progressive medulloblastoma. *J Neurosurg* 107 (1 Suppl): 5-10, 2007. [PubMed: 17644914]
 36. Robinson GW, Orr BA, Wu G, et al.: Vismodegib Exerts Targeted Efficacy Against Recurrent Sonic Hedgehog-Subgroup Medulloblastoma: Results From Phase II Pediatric Brain Tumor Consortium Studies PBTC-025B and PBTC-032. *J Clin Oncol* 33 (24): 2646-54, 2015. [PMC free

article: PMC4534527] [PubMed: 26169613]

37. Robinson GW, Kaste SC, Chemaitilly W, et al.: Irreversible growth plate fusions in children with medulloblastoma treated with a targeted hedgehog pathway inhibitor. *Oncotarget* 8 (41): 69295-69302, 2017. [PMC free article: PMC5642479] [PubMed: 29050204]

Changes to This Summary (10/05/2020)

The PDQ cancer information summaries are reviewed regularly and updated as new information becomes available. This section describes the latest changes made to this summary as of the date above.

Childhood Medulloblastoma

The Treatment of younger children with medulloblastoma subsection was renamed from Treatment of children aged 3 years and younger, and it was extensively revised.

This summary is written and maintained by the PDQ Pediatric Treatment Editorial Board, which is editorially independent of NCI. The summary reflects an independent review of the literature and does not represent a policy statement of NCI or NIH. More information about summary policies and the role of the PDQ Editorial Boards in maintaining the PDQ summaries can be found on the About This PDQ Summary and PDQ® - NCI's Comprehensive Cancer Database pages.

About This PDQ Summary

Purpose of This Summary

This PDQ cancer information summary for health professionals provides comprehensive, peer-reviewed, evidence-based information about the treatment of childhood medulloblastoma and other central nervous system embryonal tumors. It is intended as a resource to inform and assist clinicians who care for cancer patients. It does not provide formal guidelines or recommendations for making health care decisions.

Reviewers and Updates

This summary is reviewed regularly and updated as necessary by the PDQ Pediatric Treatment Editorial Board, which is editorially independent of the National Cancer Institute (NCI). The summary reflects an independent review of the literature and does not represent a policy statement of NCI or the National Institutes of Health (NIH).

Board members review recently published articles each month to determine whether an article should:

- be discussed at a meeting,

- be cited with text, or
- replace or update an existing article that is already cited.

Changes to the summaries are made through a consensus process in which Board members evaluate the strength of the evidence in the published articles and determine how the article should be included in the summary.

The lead reviewers for Childhood Medulloblastoma and Other Central Nervous System Embryonal Tumors Treatment are:

- Kenneth J. Cohen, MD, MBA (Sidney Kimmel Comprehensive Cancer Center at Johns Hopkins Hospital)
- Louis S. Constine, MD (James P. Wilmot Cancer Center at University of Rochester Medical Center)
- Roger J. Packer, MD (Children's National Health System)
- Malcolm A. Smith, MD, PhD (National Cancer Institute)

Any comments or questions about the summary content should be submitted to Cancer.gov through the NCI website's [Email Us](#). Do not contact the individual Board Members with questions or comments about the summaries. Board members will not respond to individual inquiries.

Levels of Evidence

Some of the reference citations in this summary are accompanied by a level-of-evidence designation. These designations are intended to help readers assess the strength of the evidence supporting the use of specific interventions or approaches. The PDQ Pediatric Treatment Editorial Board uses a [formal evidence ranking system](#) in developing its level-of-evidence designations.

Permission to Use This Summary

PDQ is a registered trademark. Although the content of PDQ documents can be used freely as text, it cannot be identified as an NCI PDQ cancer information summary unless it is presented in its entirety and is regularly updated. However, an author would be permitted to write a sentence such as “NCI’s PDQ cancer information summary about breast cancer prevention states the risks succinctly: [include excerpt from the summary].”

The preferred citation for this PDQ summary is:

PDQ® Pediatric Treatment Editorial Board. PDQ Childhood Medulloblastoma and Other Central Nervous System Embryonal Tumors Treatment. Bethesda, MD: National Cancer Institute. Updated <MM/DD/YYYY>. Available at: <https://www.cancer.gov/types/brain/hp/child-cns-embryonal-treatment-pdq>. Accessed <MM/DD/YYYY>. [PMID: 26389418]

Images in this summary are used with permission of the author(s), artist, and/or publisher for use within the PDQ summaries only. Permission to use images outside the context of PDQ information must be obtained from the owner(s) and cannot be granted by the National Cancer Institute. Information about using the illustrations in this summary, along with many other cancer-related images, is available in [Visuals Online](#), a collection of over 2,000 scientific images.

Disclaimer

Based on the strength of the available evidence, treatment options may be described as either “standard” or “under clinical evaluation.” These classifications should not be used as a basis for insurance reimbursement determinations. More information on insurance coverage is available on Cancer.gov on the [Managing Cancer Care](#) page.

Contact Us

More information about contacting us or receiving help with the Cancer.gov website can be found on our [Contact Us for Help](#) page. Questions can also be submitted to Cancer.gov through the website’s [Email Us](#).

Copyright Notice

Bookshelf ID: NBK65981 PMID: [26389418](#)