



Pediatric hemispheric high-grade glioma: targeting the future

Christina Coleman¹ · Schuyler Stoller² · Michael Grotzer³ · Ana Guerreiro Stucklin³ · Javad Nazarian³ · Sabine Mueller^{2,3,4,5}

© Springer Science+Business Media, LLC, part of Springer Nature 2020

Abstract

Pediatric high-grade gliomas (pHGGs) are a group of tumors affecting approximately 0.85 children per 100,000 annually. The general outcome for these tumors is poor with 5-year survival rates of less than 20%. It is now recognized that these tumors represent a heterogeneous group of tumors rather than one entity. Large-scale genomic analyses have led to a greater understanding of the molecular drivers of different subtypes of these tumors and have also aided in the development of subtype-specific therapies. For example, for pHGG with *NTRK* fusions, promising new targeted therapies are actively being explored. Herein, we review the clinico-pathologic and molecular classification of these tumors, historical treatments, current management strategies, and therapies currently under investigation.

Keywords Pediatric hemispheric high-grade glioma · Glioblastoma · Targeted therapy · Molecular classification

1 Introduction

Pediatric high-grade gliomas (pHGG) are a heterogeneous group of tumors classified by the World Health Organization (WHO) as Grade III and Grade IV [1]. The revised WHO classification from 2016 is now incorporating molecular features into the classification scheme differentiating between IDH mutant and non-mutant HGG, diffuse midline glioma H3K27M mutant and anaplastic oligodendroglioma, and IDH mutant and 1p/19q-codeleted [1]. Overall, the survival for patients with pHGG remains poor with 5-year survival rates being fairly stagnant over the last decades at about 20% [2]. However, an increased understanding of the

molecular landscape of pHGG has led to the development of new targeted agents that are being investigated with early promising results for some subtypes. Improved understanding of the underlying biology and better molecular stratification for trial enrollment will be critical to improve outcomes for pHGG.

2 Prevalence and survival trends

Gliomas are the most common central nervous system (CNS) tumors in children. The majority of these are low-grade tumors with generally excellent survival rates with a reported 20-year overall survival (OS) of 87% ± 0.8% in a study of 4040 patients [3]. However, around 30% of these tumors are classified as high-grade tumors and associated with inferior outcomes and few long-term survivors [4]. The most recently published Central Brain Tumor Registry of the United States (CBTRUS) statistical report details the incidence of malignant CNS tumors in children 0–14 years old to be 3.83 per 100,000 people. In this same age group, at least 16.7% of these tumors are malignant gliomas (glioma malignant, NOS, and glioblastoma) [5]. These tumors' age-adjusted mortality rate was reported to be 0.72 per 100,000 [5]. The OS for pHGG (age 0–14) by subtype is 65.4%, 25.2%, and 20.4% at 1, 5, and 10 years for anaplastic astrocytoma (AA) and 58.1%, 21.8%, and 18.1% for glioblastoma (GBM); however, these assessments do not take into account any molecular characterization [5].

✉ Sabine Mueller
Sabine.Mueller@ucsf.edu

- ¹ Division of Pediatric Hematology/Oncology, Department of Pediatrics, UCSF Benioff Children's Hospital, Oakland, 747 52nd Street, Oakland, CA 94609, USA
- ² Department of Neurology, University of California, San Francisco, 625 Nelson Rising Lane, Box 0663, San Francisco, CA 94158, USA
- ³ Department of Oncology and Children's Research Center, University Children's Hospital Zurich, Zurich, Switzerland
- ⁴ Division of Hematology/Oncology, Department of Pediatrics, University of California, San Francisco, 550 16th Street, 4th Floor, San Francisco, CA 94158, USA
- ⁵ Department of Neurological Surgery, University of California, San Francisco, 505 Parnassus Avenue, M779, San Francisco, CA, USA

The consistent set of clinical characteristics and outcomes as well as frequency with which CBTRUS generates statistical reports allows for opportunities to compare these data across time and different populations. Generally, there seems to be an increased incidence of pHGGs between the two-time intervals across age groups (2007–2011 and 2012–2016) (Fig. 1). In a report of NCI's Surveillance, Epidemiology, and End Results (SEER) Program data spanning from 1998 to 2013, pHGG (age 0–19) displayed a rise in the incidence of 1.55 annual percent change, though this increase did not reach statistical significance. Glioblastoma, however, did significantly increase with a 3.01 annual percent change (95% confidence interval: 0.97, 5.01) [7]. While this may represent a true increased incidence in these diagnoses, changes in diagnostic ability, tumor classification criteria, and reporting frequency may also account for these observations. However, epidemiologic studies in adult HGG suggest that there might be a true increase in the incidence of these high-grade tumors. For example, one study examining 81,135 brain tumor subjects in England (1995–2015) showed a specific increase in GBM in the frontal and temporal lobes suggesting that the incidence cannot fully be accounted for by improved diagnostic tools [8]. Thus far, no studies were able to demonstrate a clear environmental risk factor associated with gliomas other than ionizing radiation. Multiple studies have examined the relationship between cellular phone use and glioma, but no causal relationship has been established [9, 10]. Further studies are needed to better define and ascertain if there is true increase in the incidence of pHGGs.

Generally, there is no evidence that the incidence of pHGG differs by ethnicity or race. For example, both the Korean Central Cancer Registry (KCCR) and Brain Tumor Registry of Canada (BTRC) published inaugural incidence reports that mirrored CBTRUS-employed methodologies to allow for

these comparisons. Table 1 outlines the rates of pHGG diagnoses, which did not widely differ among the countries and reports included.

In very young children, the diagnosis of pHGG is rare, making for small cohorts reporting different incidence rates, ranging from 5.5% (CBTRUS, USA, population 0–14 years of age, percentage < 1-year old) to 17.8% (Germany, population 0–19 years of age, percentage < 2 years old) of all brain tumors in the corresponding age subgroups [15]. These patients present most often with tumors located in the cerebral hemispheres. In the pediatric-focused review of 2007–2011 CBTRUS data, a pHGG diagnosis in infants (< 1-year-old) was the only age group for which supratentorial tumors were more common than brainstem tumors (39.1% and 33.3%, respectively) [16]. In older children, midline HGGs are more prevalent than hemispheric gliomas and also confer poor survival prognoses. Midline HGGs will not be discussed in this review.

3 Clinical presentation

Patients who receive a diagnosis of pHGG present with a variety of symptoms that are mainly determined by tumor location and age of presentation [17]. While patients with hemispheric tumors experience higher rates of focal neurological signs and seizures, patients with posterior fossa tumors experience higher rates of cranial nerve palsies and symptoms related to increased intracranial pressure (ICP). While tumor location in cerebral hemispheres confers a higher risk of seizures, seizures are generally more prevalent in pediatric low-grade gliomas [18]. Infants often exhibit non-specific and delayed increased ICP-related symptoms due to increased skull elasticity and correspondingly can demonstrate increased head

Fig. 1 CBTRUS incidence rates of pediatric anaplastic astrocytoma and glioblastoma multiforme from 2007 to 2011 and 2012 to 2016 reports. Data adapted from [5, 6]

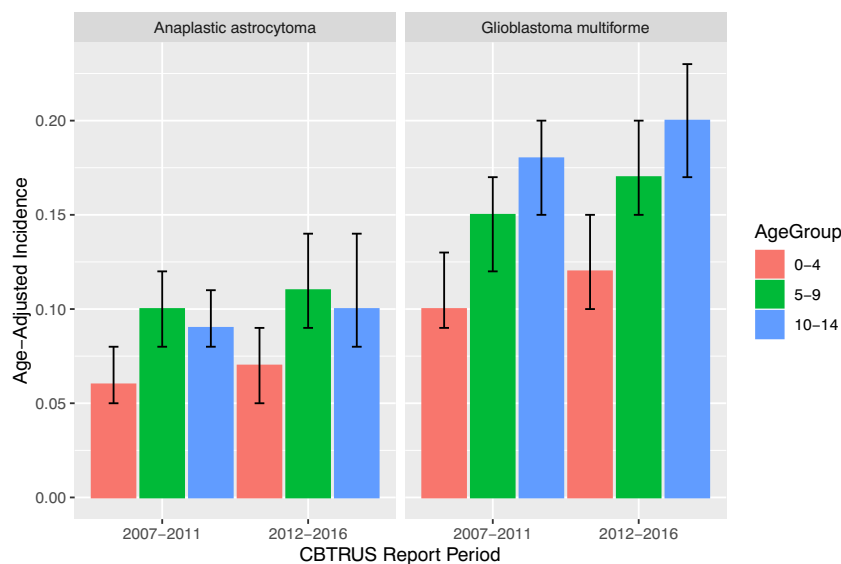


Table 1 Incidence rates for pediatric HGG

Country	Year range	Age-standardized rate		
		Anaplastic astrocytoma	Glioblastoma	Glioma (malignant), ROS
Canada [11]	2010–2015	0.06 (0.00–0.13)	0.19 (0.05–0.33)	0.68 (0.42–0.94)
United States of America [5]	2012–2016	0.10 (0.09–0.11)	0.17 (0.15–0.18)	0.80 (0.77–0.84)
Korea [12]	2005–2014	0.07 (0.05–0.08) ^a	0.13 (0.11–0.15) ^a	0.27 (0.24–0.30) ^a
Great Britain [13]	2001–2010	0.09 ^b	0.14 ^b	–
England [14]	1995–2003	0.05 ^b	0.12 ^b	–

Data was summarized from five studies (see references in table). Incidence rates are reported per 100,000 people, age-standardized, and with reference to country standard population unless otherwise indicated. ^a Rates per 100,000 persons in the USA year 2000 population. ^b Rates per 100,000 persons in world standard population. Anaplastic pleomorphic xanthoastrocytoma data not reported

circumference and unspecific clinical signs of poor feeding, irritability as well as failure to thrive [19]. The duration of symptoms prior to diagnosis tends to be shorter for high-grade lesions than for lower-grade lesions [20, 21]. The average reported length of latency between symptom onset and diagnosis varies between case series, though this is influenced by the pathologic diagnoses included in the series. One series of 245 pediatric patients with brain tumors, including patients with both low-grade and high-grade tumors (33 patients with pHGG), found a median interval of 24 days from symptom onset to diagnosis (mean 59.3 days and range 0–795 days), and this length was significantly shorter with increasing tumor grade [20]. Another series of 104 pediatric brain tumors reported a median duration of symptoms of 7.3 months (95% CI, 4.99–9.67 months) though most patients had either astrocytoma with no defined grade or medulloblastoma [21].

4 Imaging findings

On diagnostic MRI, pHGG characteristically have ill-defined margins due to their invasive nature. These tumors are often contrast-enhancing on T1-weighted sequences, and accompanying edema shows as hyperintense signal on T2 FLAIR sequences [22]. While multiple MRI sequences and features can aid in differentiating pHGG from other intracranial tumors, there is presently no single characteristic imaging feature that can be used for differentiation. Additionally, at the current stage it is impossible to differentiate between different pHGG histopathologies based on imaging alone, and heterogeneity exists within these groups.

While MRI sequences at diagnosis may not be able to provide insight regarding the tumor's prognosis, advanced MRI sequences and PET imaging may hold promise for these purposes. Perfusion MRI sequences are of particular interest for pHGG due to their ability to quantify vascular features in these tumors such as microvascular proliferative changes. There is promise for perfusion sequences to aid in differentiating between HGG and

LGG by using perfusion measure thresholds and ratios [23]. In cases when pHGGs are not amenable to safe surgical sampling for pathologic analysis, advances in the field of radiogenomics may be of particular value to assess specific genomic markers. The field of radiogenomics aims to relate features on imaging, such as tumor-related signal intensity and location, with genomic markers in order to more quickly and less invasively determine specific subtypes. There are, however, relatively few of these analyses in pHGG, while promising analyses have been performed in adult GBM [24]. One of the few pHGG radiogenomic analyses classified H3K27M mutation status in pediatric brain stem glioma patients based on a number of clinical and imaging characteristics to achieve an accuracy of 84% [25]. Additionally, with the availability of blood-brain barrier permeable positron emission tomography (PET) ligands, PET is a separate modality that may have the potential to prognosticate these tumors. Leveraging the differential metabolic and protein synthetic profiles of these tumors, 18F-fluorodeoxyglucose (FDG), and amino acid PET tracers have demonstrated promising ability to differentiate different glioma grades but are early in the development for pHGGs [26, 27].

A key challenge in the caring for children with pHGG is assessment of these tumors with time and especially in response to therapy. Using standard MRI sequences, it can be challenging to differentiate between true tumor progression and treatment related changes. In a small cohort of 10 adult patients with GBM, it was noted that in observing contrast changes for 75 min post injection, patients who had delayed rapid contrast clearance were those with active tumors while those with delayed clearance did not have active tumors [28]. This led to larger studies and subsequently more widespread use of delayed-contrast MRI for calculating high resolution treatment response assessment maps (TRAMS). TRAMS are used in adult GBMs to better differentiate active disease from treatment changes [29]. Pediatric investigations using TRAMS have not yet been reported but are being actively pursued.

5 Overview and general approach to treatment

The current therapeutic approach to pHGGs consists of maximal safe surgical resection followed by focal radiation therapy in children greater than 3 years of age. A standard chemotherapy regimen has not yet been established, and most neuro-oncologists aim to enroll children with pHGG into clinical trials. The standard of care for infant pHGGs is rapidly changing and no widely followed regimen has been developed. Current approaches range from maximal safe surgical resection followed by high-dose chemotherapy protocols, standard chemotherapy regimens, or observation alone given case reports that highlight good outcomes without additional therapies [30]. The approach to infant HGG is discussed in greater detail below.

5.1 Surgery

The first method of treatment is surgical resection of the tumor whenever feasible. Maximal safe resection is often desired but sometimes not feasible given the extent of the tumor and location. A number of studies report correlations between improved extent of resection (EOR) and clinical outcomes such as progression free survival (PFS) and OS [31–34]. There exists contradictory evidence, however, for the association between EOR and improved survival outlook for infant pHGG [15]. In a study of 198 infants with brain tumors treated on a chemotherapeutic protocol, a multivariate analysis of PFS revealed that complete resection was the only significant favorable factor ($p < 0.001$; relative risk, 0.33; 95% confidence interval (95% CI), 0.20 to 0.54). This analysis did not however separate out different histologies, and only 17 of the included patients had HGGs [35]. In another study of 21 children under age 5 years with pHGG, 5 out of the 7 children who had complete surgical resection were alive at the time of the publication, while only 7 out of the 14 with incomplete resection survived; however, this difference was not statically significant and may be attributable to the small sample size [36].

5.2 Radiation

For children older than 3, focal radiation to 54 Gy after tumor resection is considered the standard of care by many. While pHGG are thought to be generally radiosensitive, this therapy is often avoided or delayed in children under 3 years of age, following studies reporting deleterious late effects on cognitive function, neuroendocrine function, secondary neoplasm, and vascular changes leading to increased stroke risk [35, 37–41]. Radiation induced tumors often arise within the prior radiation field and are genomically distinct from the primary tumor and will be discussed in greater detail below. Because

radiation-induced side effects are dose-dependent, re-irradiation is not always considered a viable treatment option but is an emerging strategy in the recurrent pHGG setting [42]. A recent retrospective study demonstrated that re-irradiation for pHGG recurrence was well tolerated and correlated with a longer median survival time. Compared to 26 patients not undergoing re-irradiation, 14 patients with re-irradiation had improved median survival from the time of first disease progression (9.4 vs 3.8 months, $p = 0.005$) [43]. Ongoing investigations are assessing if the use of combined immune directed therapies with re-irradiation is a more effective treatment strategy. For example, an ongoing study tests the combination of PD-1 inhibition in combination with re-irradiation in children with recurrent or refractory pHGG (Pacific Pediatric Neuro-Oncology Consortium (PNOC) study 013, NCT03690869).

Little information exists regarding the use of proton radiation therapy in pHGG, but it has been shown in other pediatric brain tumor entities such as medulloblastoma and ependymoma to lead to similar survival benefits with less toxicities [44–47]. Proton therapy has a smaller exit dose than photon therapy, which may translate into fewer toxicities [48]. For infiltrative tumors like pHGG, however, a diminished exit dose may not be desired. In adult HGG patients, proton beam therapy displayed similar survival outcomes and toxicity to photon radiation therapy [49].

5.3 Conventional chemotherapy

Until now, no standard chemotherapy approach has been developed that is widely accepted by the pediatric neuro-oncology community, and therefore most care providers aim to enroll pHGG patients into investigational clinical trials. Following the success of the Stupp trial's use of temozolomide in adult glioblastoma patients [50], the Children's Oncology Group (COG) studies ACNS0126 and ACNS0423 similarly employed the use of temozolomide concurrent with radiotherapy and as single agent or in combination as adjuvant chemotherapy. ACNS0126 trial did not demonstrate survival benefit compared to the treatment regimens of the previous Children's Cancer Group (CCG)-945 study conducted in the 1980s: 3-year EFS rate for anaplastic astrocytoma (AA) was $13 \pm 6\%$ compared with $22 \pm 5.5\%$ in CCG-945 ($p = 0.95$) and for GBM it was $7 \pm 4\%$ compared with $15 \pm 5\%$ in CCG-945 ($p = 0.77$) [51]. While not demonstrating a difference, temozolomide offers a more attractive toxicity profile when compared with preceding treatment regimens, spurring its inclusion in many treatment regimens. ACNS0423 built on ACNS0126 by including lomustine as adjuvant chemotherapy, similarly driven by an adult GBM study with encouraging survival outcomes. With the addition of lomustine, ACNS0423 reported a significant improvement in EFS and OS compared to ACNS0126 (3-year EFS was 0.22 (95% CI, 0.14–0.30) in ACNS0423 compared with 0.11 (95% CI, 0.05–

0.18) in ACNS0126) [52]. The German cooperative group is conducting the HIT-HGG-2013 trial comparing the combinations of temozolomide and chloroquine and temozolomide and valproate with historical data from previous studies using single agent temozolomide (NCT03243461). Of note, there has been a reported increased risk of secondary hematologic malignancies (SHM) associated with temozolomide in these patients. In an analysis of 487 patients in the HIT-HGG database, no secondary malignancies occurred in 194 patients after first-line temozolomide therapy, but 4 out of 131 patients treated with temozolomide for relapse following first-line multi-agent chemotherapy experienced SHM (20% at 10 years; $p = 0.041$) [53].

Unfortunately, despite a variety of therapeutic approaches, the survival for patients with pHGG remains poor. Key challenges to assess new therapies lie in the inclusion of a very heterogeneous group of pHGG subtypes, lack of tissue correlates, and limited preclinical assessments in relevant and subtype-specific model systems. With the increasing understanding of the molecular heterogeneity of pHGG, more targeted agents are being investigated in the treatment of certain pHGG subtypes that hold great promise to improve outcomes.

6 Subtypes of pediatric high-grade glioma and associated molecular characteristics

Clinico-pathological features of the more common molecular subtypes of non-brainstem pHGG are summarized in Fig. 2. Key subtypes will be discussed below, along with potential targeted therapies in greater detail.

6.1 BRAF V600E mutant pHGG

Point mutations in the *BRAF* gene that substitute valine to glutamic acid at position 600 (BRAFV600E) and activate the mitogen-activated protein kinase (MAPK) pathway are most commonly identified in melanoma [62]. However, this mutation has also been identified in other tumors including 10–15% of pHGG cases [63] and 17% of pLGG [64]. In a group of 32 BRAFV600E mutant pHGGs, the 2-year OS was 67% and the average age at diagnosis 10 years [54]. It remains unclear what drives malignant transformation of glioma, but a retrospective study of 886 pLGG samples showed that the 26 low-grade lesions (2.9%) that did transform into secondary higher-grade gliomas (sHGG) most often had BRAFV600E mutations (39%) and CDKN2A deletions (57%) [65]. Multiple reports have shown success in managing BRAFV600E pHGG with *BRAF* inhibiting drugs such as MEK inhibitor trametinib and BRAFV600E-specific inhibitors dabrafenib and vemurafenib [63, 66]. A phase 2 study of dabrafenib with trametinib after local irradiation in newly

diagnosed BRAFV600E-mutant pHGG is underway (NCT03919071). Trials examining the use of *BRAF* inhibition in recurrent *BRAF*-mutated tumors including HGGs are also ongoing (NCT01677741, NCT01748149). For example, in pediatric patients with recurrent BRAFV600E mutant brain tumors, vemurafenib has been shown to be well tolerated, and to be effective ranging from complete responses, partial responses to stable disease although most responses were seen in LGG [67].

6.1.1 Anaplastic pleomorphic xanthoastrocytoma

Anaplastic pleomorphic xanthoastrocytoma (anaplastic PXA), a specific subtype of pHGG, harbors a particularly high incidence of BRAFV600E mutation and was added as a distinct entity in the 2016 WHO classification [1]. Anaplastic PXA is a WHO Grade III HGG, whereas the WHO grade II PXA is considered a low-grade lesion. The frequency of BRAFV600E mutation is known to be lower in anaplastic PXA than in PXA (49% vs 75%) [2]. CDKN2A homozygous deletion in combination with RAF alterations have been shown to be defining features of both PXA and anaplastic PXA. PXA and anaplastic PXA however have differentiating methylation profiles and anaplastic PXA clusters closer to a rare IDH-wildtype subtype of GBM, epithelioid GBM [68, 69]. Alterations in the telomerase reverse transcriptase (*TERT*) gene are also commonly found in anaplastic PXA (7/15 (47%) of patients in a recent series) [68].

As expected, the 5-year OS for patients with anaplastic PXA is shorter than for patients with PXA (57% vs 90% in a group of 74 patients including 31 pediatric patients, $p = 0.0003$ [70]). As with other pHGGs, improved survival has been associated with extent of resection and treatment with *BRAF*-inhibiting agents [70, 71]. Some trials discussed evaluating the use of *BRAF* inhibitors in pHGG include patients with anaplastic PXA, but responses and failures must be evaluated in the subtype-specific context.

6.2 G34 R/V

Mutations in histone genes, such as the H3K27 mutation, have had huge impact in our understanding and ongoing research efforts for diffuse midline HGG. However, a subset of supratentorial HGGs carry a distinct histone mutation that substitutes glycine to arginine or valine at position 34 (G34R- or G34 V-H3.3). This mutation most commonly occurs in adolescent and young adult patients (median age 20 years) and is almost exclusively found in HGGs of the cerebral hemispheres [55]. Patients harboring tumors with this mutation tend to have longer OS than diffuse midline gliomas, H3K27 mutant (median survival 18 months and 2 year OS 27.3% in an analysis of 67 patients) [54, 72]. Mutations at G34R have been found to co-occur with two other oncogenic

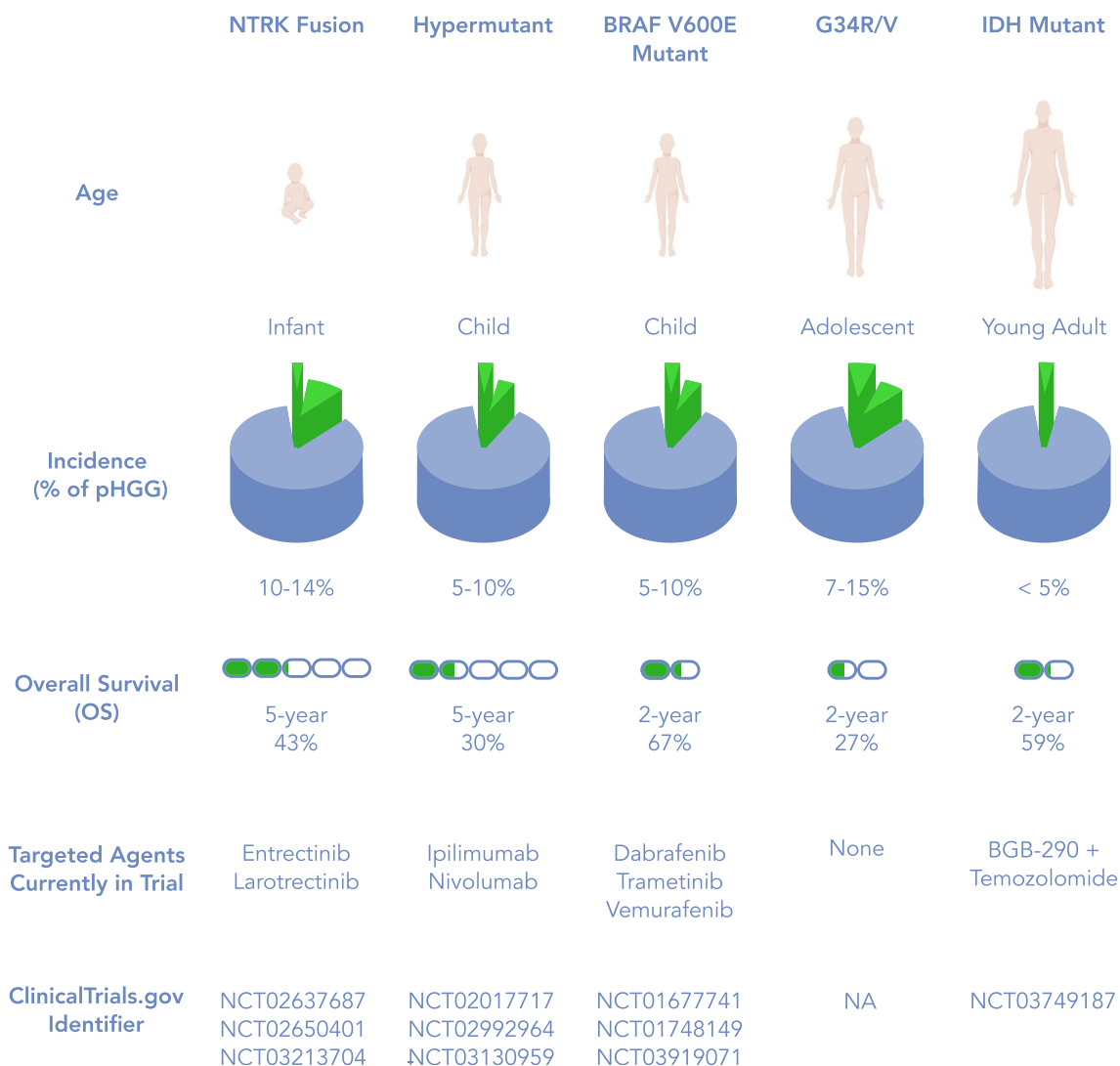


Fig. 2 Molecular subtypes of non-brainstem pGG with associated incidence, survival, and ongoing trials. Data adapted from [54–61]

mutations: the α -thalassaemia/mental retardation syndrome X-linked (ATRX) and death-domain associated protein (DAXX) [55]. Tumors with G34R/V mutation also carry a high frequency of O⁶-methylguanine-DNA methyltransferase (MGMT) promoter methylation and therefore might have a better response to temozolomide [54, 73].

While there is a paucity of animal models to study this mutation, some patient derived cell lines have been generated [74] that are being utilized to further study this specific entity. Overall, these observations highlight the need to assess therapies in a subtype-specific manner in order to achieve significant progress.

6.3 IDH-1

Isocitrate dehydrogenase (IDH) is an enzyme involved in cellular energy and metabolism. Arginine-to-histidine missense mutations in either the *IDH1* or *IDH2* genes are more

commonly found in adult patients with GBM but are also present in a subset of pediatric patients but representing less than 5% of pGG, typically adolescent patients [56, 57]. *IDH*-mutant gliomas are generally associated with a more favorable prognosis compared to wildtype tumors. However, this correlation has been more clearly established in the adult LGG setting. The prognostic implication of the *IDH* mutation is still under investigation in pGG, and current research is limited by the rarity of this mutation in children. *IDH* mutations induce DNA repair deficiency and induce a BRCA mutant-like state which can be exploited with poly (ADP)-ribose polymerase (PARP) inhibitors [75, 76]. PARP proteins are involved in base excision repair (BER), which repairs DNA damage induced by alkylators such as temozolomide. PARP inhibitors either catalytically inhibit the ribosylation function of PARPs or by “trapping” PARP proteins at sites of DNA damage [77]. Preclinical investigations have shown that these “PARP-trapping” PARP inhibitors synergize with

TMZ more strongly compared to no-trapping PARP inhibitors. This has led to the clinical investigation of the use of temozolomide in combination with PARP inhibitors in *IDH*-mutant cancers. A phase 1 study examining the use of specific PARP inhibitor BGB-290 and temozolomide in adolescent and young adult (AYA) patients with *IDH1/IDH2*-mutant glioma is actively ongoing (PNOC017, NCT03749187).

6.4 Receptor tyrosine kinase-fused gliomas

The prognosis for infants with HGG is superior to that of older children [54, 78]. Comparing survival in an international cohort of 150 infant HGGs to a cohort of older children with HGG from Sick Kids hospital, the 5-year OS for infants was 54.5% (40.0–74.2%) vs 6.6% for older children (2.4–18.5%) ($p < 0.001$) [58]. There are even reports of spontaneous regression of congenital glioblastoma, suggesting that this disease is indeed distinct from the disease in older children and adults [30]. Several studies have examined different chemotherapy regimens in young children and demonstrated some survival benefit. [36, 79–82]. However, the natural history of this disease makes these results difficult to interpret. While infant HGGs are most often treated with conventional chemotherapy, increased knowledge of the molecular characteristics of these tumors opened the possibility of targeted therapies, while large-scale genomic efforts have shown that infant HGGs carry a lower rate of genomic alterations compared to older children, and large percentage carry specific fusion genes that can be exploited therapeutically [59]. An analysis of 118 pHGGs demonstrated that 40% of non-brainstem infant HGGs carry neurotrophic receptor kinase gene (*NTRK*) fusions [59]. Fusions involving one of the three *NTRK* genes lead to constitutive activation of the MAPK, phosphoinositide 2-kinase (PI3K) and protein kinase C (PKC) pathways responsible for cellular proliferation, survival, and invasion [83]. A recent study of an international cohort of pediatric glioma samples from 150 patients between 1986 and 2017 defined three subgroups of infant glioma based on clinical and molecular characteristics. Group 1 were hemispheric tumors characterized by receptor tyrosine kinase (*RTK*) fusions involving the *ALK/ROS1/NTRK/MET* genes. Most of these Group 1 tumors were HGG (82.8%, 24/29, $p < 0.0001$). Group 2 (hemispheric RAS/MAPK-driven tumors) and Group 3 (midline RAS/MAPK-driven tumors) were exclusively comprised of low-grade gliomas [58]. *MET* fusions, which similarly leads to increased MAPK signaling, have been found in a small subset of pediatric GBM samples (5/53) in one study [84]. Though mostly recognized in hemispheric HGGs infants, alterations in these *RTKs* appear to be, as least in part, neither restricted to infancy [84] nor to a histological entity/grade [58, 85].

Several drugs are now being investigated in tumors with these *RTK* alterations. A phase 1 study showed promising

responses to entrectinib, a new-generation CNS-penetrant oral inhibitor of *ALK/ROS1/NTRK* kinases, in refractory CNS tumors harboring alterations in these kinases [86, 87]. A study of the safety and efficacy of entrectinib, a pan-TRK *ROS1* and *ALK* inhibitor, is also ongoing (NCT02650401). Ensartinib, another CNS-penetrant *ALK* inhibitor, is currently being investigated through the COG pediatric MATCH trial for patients with relapsed or refractory *ALK* or *ROS* mutant tumors, including those located in the CNS (NCT03213652). Larotrectinib is a pan-TRK inhibitor that was granted accelerated FDA approval (2019) for adult and pediatric solid tumors with *NTRK* fusions. Larotrectinib is well tolerated in pediatric patients and has shown significant antitumor activity in patients with *TRK* fusion-positive cancers [88, 89]. One published case has reported efficacy of larotrectinib in a patient with pHGG that had failed conventional chemotherapy [90]. Further studies assessing the efficacy of larotrectinib in up-front and recurrent pediatric malignancies, including HGG are ongoing (NCT03213704 and NCT02637687).

6.5 Hypermutant glioblastoma in patients with constitutional mismatch repair deficiency

Homozygous germline alterations in mismatch repair (MMR) genes *PMS2*, *MLH1*, *MSH2*, and *MSH6* result in biallelic MMR deficiency syndrome (bMMRD) [91]. Patients with bMMRD develop cancers within the first two decades of life, most commonly gliomas, hematologic malignancies, and gastrointestinal cancers [92]. GBMs that arise in the setting of bMMRD have been shown to have the highest mutational load in cancer [60]. Patients with germline *POLE* mutations are also prone to the development of hypermutant tumors [60]. While these mutations are overall very rare, a series examining pHGG in Jordan, where consanguinity is more commonly present, found that 51% of pediatric GBMs had a germline mutation in one of the four MMR genes [61]. In contrast, in a German study, the incidence of hypermutated samples accounted for only 5% of pHGG and in North America 9% of pHGG patients were found to have a germline mutation in a cancer predisposition syndrome, but only a small number of these were in MMR genes [93, 94]. There are little data about survival for patients with hypermutated HGG. One report suggests that the outcome is similar to non-hypermutated pHGGs [61], whereas another suggested slightly improved OS for HGG occurring in the setting of bMMRD when tumors were fully resected [95]. In a series of 13 patients with bMMRD and HGG, the average age at diagnosis was 12 years and the 5-year OS survival was 30%; however, little information is given on treatment received [61]. Hypermutant cancers in adults with high neoantigen load have responded to immune checkpoint inhibition [96, 97]. Nivolumab and pembrolizumab are monoclonal antibodies that target programmed death 1 (PD-1). The use of checkpoint inhibitors

enhances effector T-cell activation and aids in the initiation of an antitumor response [98]. This strategy has been shown to be effective in some cases of hypermutated pediatric GBM in the bMMRD context [99–101]. These findings have led to the initiation of a pilot study of nivolumab for pediatric patients with hypermutant tumors, including gliomas which are currently being conducted (NCT02992964). Ipilimumab is an anti-cytotoxic T lymphocyte-associated protein 4 (CTLA-4) antibody which has also been used in adult cancers with high mutational load. It is also currently being investigated for its role in pHGG, including hypermutated tumors.

6.6 Secondary radiation-induced pediatric high-grade glioma

The most common etiology for the development of secondary HGG is a history of ionizing radiation [102]. In a recent large series of secondary pHGG, all patients had been previously treated for a malignancy and all lesions arose in previous radiation fields [103]. The median OS for patients in this study was 9.75 months [103]. In another cohort of 12 patients with radiation-induced HGG, the median age at diagnosis is 14 [104]. The interval between radiation therapy and secondary glioma diagnosis ranged from 4 to 41 years (mean 16 years). In this study, a genetic analysis of the radiation induced tumors was conducted and revealed a genetic landscape different from that of primary pHGG with high incidence of biallelic *TP53* inactivation, *CDK4* amplification or *CDKN2A* homozygous deletion, and amplifications or rearrangements involving RTK and Ras-Raf-MAP kinase pathway genes [104]. Unfortunately, the survival for patients with radiation-induced HGG remains poor with no effective therapeutic options.

7 New therapeutic approaches for pHGG

The most recent large-scale clinical trial for children with HGG – the HERBY trial – evaluated the addition of bevacizumab to radiation and temozolomide in patients with non-brainstem pHGG [105]. For the overall cohort, there was no clinical benefit to adding bevacizumab. However, post-hoc analysis of the molecular characteristics of the patients revealed that the addition of bevacizumab provided some benefit to certain subgroups of pHGG including hypermutated pHGG and pHGG with BRAF V600E mutations [106]. This highlights that therapies need to be evaluated within a subtype-specific context and tissue correlates are absolutely necessary to understand responses and failures. Further, in the HERBY trial, MGMT promoter methylation assessed by methylation-specific PCR (MSP) did not confer similar survival benefits seen adult trials [106]. These discrepancies can be attributed to a number of factors, including the method of determining MGMT promoter methylation [107]. This emphasizes that international standards need to be developed to assess potential prospective biomarkers and harmonization needs to occur across study sites on a national and international level in order to achieve better outcomes for pHGGs.

As outlined above, standard chemotherapy has not been effective in treating pHGG. Studies directed toward specific mutations as well as studies harnessing the immune system are being investigated and are summarized in Tables 2 and 3. Precision medicine-based approaches with multi-agent therapy plans for newly diagnosed pHGG are actively being pursued and are often used in clinical practice off studies as more and more centers perform molecular profiling on these tumors (NCT03739372).

Table 2 Small molecule drugs and immune targeted treatments in trial for newly diagnosed pediatric HGG

Drug/treatment	Molecular target	Clinical trial
Dabrafenib, trametinib	BRAFV600E serine/threonine kinase	NCT03919071
Dasatinib	BCR-ABL tyrosine kinase	NCT03352427
Everolimus	mTOR	
BGB-290	PARP inhibitor	NCT03749187
HLA-A2 restricted glioma antigen peptides vaccine, poly-ICLC	HLA-A2	NCT01130077
Anti-tumor dendritic cell vaccine following dose-intensified temozolomide	Patient-specific dendritic cells	NCT03334305
CMV RNA-pulsed dendritic cells with tetanus toxoid pre-conditioning and GM-CSF	Patient-specific tumor cells	NCT03615404
HSPPC-96 Vaccine	Patient-specific tumor cells	NCT02722512

Abbreviations: mTOR, mammalian target of rapamycin; PARP, poly-ADP-ribose polymerase; Poly-ICLC, polyinosinic-polycytidylic acid stabilized with polylysine and carboxymethylcellulose; GM-CSF, granulocyte macrophage-colony stimulating factor; HSPPC-96, heat shock protein peptide complex-96

Table 3 Small molecule drugs and immune targeted treatments in trial for recurrent/refractory pediatric HGG

Drug/treatment	Molecular target	Clinical trial
Dabrafenib, trametinib	BRAFV600E tyrosine kinase	NCT02684058
Cemiplimab (REGN2810) with radiation	PD-1	NCT03690869
Selinexor	XPO1	NCT02323880
Mebendazole	Anti-helminth, unknown anti-neoplastic mechanism	NCT02644291
Olaparib	PARP	NCT03233204
Larotrectinib	NTRK fusions	NCT03213704
Palbociclib	CDK4/6	NCT03526250
Abemaciclib (LY2835219)	CDK4/6	NCT02644460
Tazemetostat	EZH2	NCT03213665
LY3023414	PI3K, mTOR	NCT03213678
Erdafitinib	FGFR	NCT03210714
Vemurafenib	BRAFV600E	NCT03220035
ONC201	DRD2	NCT03416530
		NCT02525692
		NCT03134131
Pembrolizumab	PD-1	NCT02359565
Nivolumab	PD-1	NCT02992964
Nivolumab and ipilimumab	PD-1/CTLA-4	NCT03130959
Fimepinostat	PI3K, HDAC	NCT03893487
Volitinib	c-Met tyrosine kinase	NCT03598244
DSP-7888	WT-1 peptide	NCT02750891
Dendritic cell vaccine	Tumor cells	NCT01808820
AdV-tk vector (expresses <i>herpes thymidine kinase gene</i>) and valacyclovir	Tumor cells remaining in tumor bed post-operatively	NCT00634231
APX005M	CD40	APX005M
EGFR806-specific CAR-T cell locoregional immunotherapy	EGFR	NCT03638167
HER-2 specific	HER-2	NCT03500991
CAR-T cell locoregional immunotherapy		

Abbreviations: PD-1, programmed death receptor 1; XPO1, exportin 1 (nuclear export protein); PI3K, phosphoinositide 3-kinase; mTOR, mammalian target of rapamycin; PARP, poly-ADP-ribose polymerase; NTRK, neurotrophic tyrosine receptor kinase; CDK4/6, cyclin-dependent kinase 4/6; EZH2, enhancer of zeste 2 polycomb repressive complex 2 subunit (histone methyltransferase); FGFR, fibroblast growth factor receptor; DRD2, dopamine receptor 2; HDAC, histone deacetylase; WT-1, Wilms' tumor 1; EGFR, epidermal growth factor receptor; HER-2, epidermal growth factor receptor 2

7.1 Immunotherapy

Another strategy being explored in the treatment of pHGG is that of harnessing the immune system to target tumor antigens. The role of immunotherapy in the treatment of pHGG is still under active investigation. The varied immunotherapeutic approaches to pediatric brain tumors were recently reviewed [108]. While a full discussion of immunotherapy for pHGG is outside the scope of this review, we will discuss some approaches currently being investigated. In an adult study of 35 patients with recurrent GBM, those treated with neoadjuvant pembrolizumab had a significant survival advantage compared to those only treated with adjuvant therapy (hazard ratio 0.39 compared to adjuvant-only group; 95% CI 0.17 to 0.94, $p =$

0.04). In this study, the investigators found that neoadjuvant PD-1 blockage induced functional activation of tumor infiltrating lymphocytes leading to an intratumoral interferon response and suggesting that the survival benefit is driven by this immune response. This study underscores that the timing of administration of this class of drugs may be key for efficacy [109]. This approach will be investigated in pediatric patients in an upcoming trial conducted through PNOG. Another immune therapy under active investigation is the use of the cytokine interleukin-12 (IL-12) which has anti-cancer properties but is toxic when administered systemically. A phase one trial of 31 adult patients with HGG investigating the injection of IL-12 into tumor resection cavity followed by the administration of vedolimex which is an oral activator

of IL-12 showed tolerability of this approach [110]. This approach is also currently being tested in the pediatric setting (NCT03330197). Another immune directed therapy being investigated is the use of oncolytic viruses. For example, a phase 1 study examining the safety of oncolytic poliovirus (PV) immunotherapy with polio-/rhinovirus recombinant PVSRIIP in pediatric patients with HGG is ongoing (NCT03043391).

7.2 CNS directed delivery

While multiple different therapies are being investigated in the treatment of pHGG, the delivery of these drugs to the tumor can be challenging. The treatment of pHGG is particularly difficult because of the challenges posed by the blood-brain barrier (BBB) and the blood-tumor barrier (BTB). This anatomical and efflux-pump equipped boundary limits the selection of available systemic agents or mandates the use of dosing regimens that may have significant toxicities. Some strategies are being investigated to overcome these challenges including tumor-directed delivery strategies. Convection-enhanced delivery (CED) is a technique for administering drug to tumor that was first described by Bobo et al. in 1994 [111]. Clinical trials have examined CED of different chemotherapies or immune-directed therapies to adult HGG patients with varying rates of success and continue to be studied [112–114]. The first phase 1 trial using CED in pediatric patients with DIPG demonstrated that this approach appeared to be safe and overall well tolerated [115]. Two ongoing trials examining different agents being administered using CED in pediatric patients with DIPG are currently being conducted by PNO (NCT03086616, NCT03566199). Another method for CNS-directed delivery is the use of focused ultrasound to disrupt the BBB [116]. This approach is being tested clinically in adults with recurrent glioma (NCT03551249).

7.3 Tumor-treating fields (TTF)

A different approach that is also being investigated in recurrent or refractory pHGG is the use of the external device Optune NovoTTF-200A, which when worn delivers alternating electrical fields toward the tumor acting as a locally delivered antimetabolic treatment interfering with cell division and organelle assembly and is FDA approved in adults for newly diagnosed GBM [117]. In a randomized clinical trial of adults with GBM, the addition of tumor-treating fields to temozolomide resulted in an increase in OS (20.5 months; 95% CI 16.7–25 months; $n = 196$ vs 15.6 months 95% CI 13.3–19.1 months $n = 84$, $p = 0.004$) [118]. This device is also being examined in pediatric patients with recurrent or refractory HGG (NCT03033992).

8 Novel diagnostic approaches

Another challenge that arises when treating patients with HGG is the invasive nature of diagnosing and assessing molecular tumor response. The location of many pHGGs as well as the invasive nature of the procedure can make repeat sampling difficult. This makes it challenging to understand how these tumors might change in response to therapy or how they might evade treatments. In adult patients with brain tumors, cerebral spinal fluid (CSF)-derived circulating tumor DNA (ctDNA) is used for aiding diagnosis and assessing response to therapy [119]. In pediatrics, this method is starting to be investigated. CSF has previously been shown to better detect genomic alterations in brain tumors than serum [120]. However, in children, collection of CSF often requires sedation and can therefore be more challenging. With technological advances, the sensitivity of plasma derived ctDNA may improve. In PNO003, serum-derived ctDNA was able to detect H3K27 mutation in 11/13 patients at diagnosis [121].

9 Conclusions

Pediatric HGGs are a heterogeneous group of tumors with poor clinical outcomes. With our increasing knowledge of the molecular landscape of pHGG, new directed therapies are being evaluated. Future investigations should consider the heterogeneity of these tumors and design subtype-specific trials when appropriate. Tissue correlates will remain necessary until noninvasive assessments such as ctDNA is further developed. International collaborations are needed to harmonize investigations of new drugs given the overall rarity of these tumors.

References

1. Louis, D. N., Perry, A., Reifenberger, G., von Deimling, A., Figarella-Branger, D., Cavenee, W. K., Ohgaki, H., Wiestler, O. D., Kleihues, P., & Ellison, D. W. (2016). The 2016 World Health Organization classification of tumors of the central nervous system: A summary. *Acta Neuropathologica*, 131(6), 803–820. <https://doi.org/10.1007/s00401-016-1545-1>.
2. Fangusaro, J. (2012). Pediatric high grade glioma: A review and update on tumor clinical characteristics and biology. *Frontiers in Oncology*, 2, 105. <https://doi.org/10.3389/fonc.2012.00105>.
3. Bandopadhyay, P., Berghold, G., London, W. B., Goumnerova, L. C., Morales La Madrid, A., Marcus, K. J., et al. (2014). Long-term outcome of 4,040 children diagnosed with pediatric low-grade gliomas: An analysis of the surveillance epidemiology and end results (SEER) database. *Pediatric Blood & Cancer*, 61(7), 1173–1179. <https://doi.org/10.1002/pbc.24958>.
4. Qaddoumi, I., Sultan, I., & Gajjar, A. (2009). Outcome and prognostic features in pediatric gliomas: A review of 6212 cases from

- the surveillance, epidemiology, and end results database. *Cancer*, 115(24), 5761–5770. <https://doi.org/10.1002/cncr.24663>.
5. Ostrom, Q. T., Cioffi, G., Gittleman, H., Patil, N., Waite, K., Kruchko, C., & Barnholtz-Sloan, J. S. (2019). CBTRUS statistical report: Primary brain and other central nervous system tumors diagnosed in the United States in 2012–2016. *Neuro-Oncology*, 21(Supplement_5), v1–v100. <https://doi.org/10.1093/neuonc/noz150>.
 6. Q. T. Ostrom, H. Gittleman, P. Liao, C. Rouse, Y. Chen, J. Dowling, Y. Wolinsky, C. Kruchko, J. Barnholtz-Sloan, (2014) CBTRUS Statistical Report: Primary Brain and Central Nervous System Tumors Diagnosed in the United States in 2007–2011. *Neuro-Oncology*, 16(Supplement_4), iv1–iv63.
 7. Withrow, D. R., de Gonzalez, A. B., Lam, C. J. K., Warren, K. E., & Shiels, M. S. (2019). Trends in pediatric central nervous system tumor incidence in the United States, 1998–2013. *Cancer epidemiology, Biomarkers & Prevention*, 28(3), 522–530. <https://doi.org/10.1158/1055-9965.EPI-18-0784>.
 8. Philips, A., Henshaw, D. L., Lambum, G., & O'Carroll, M. J. (2018). Brain tumours: Rise in glioblastoma multiforme incidence in England 1995–2015 suggests an adverse environmental or lifestyle factor. *Journal of Environmental and Public Health*, 2018, 7910754. <https://doi.org/10.1155/2018/7910754>.
 9. Lahkola, A., Auvinen, A., Raitanen, J., Schoemaker, M. J., Christensen, H. C., Feychting, M., Johansen, C., Klæboe, L., Lönn, S., Swerdlow, A. J., Tynes, T., & Salminen, T. (2007). Mobile phone use and risk of glioma in 5 North European countries. *International Journal of Cancer*, 120(8), 1769–1775. <https://doi.org/10.1002/ijc.22503>.
 10. Yoon, S., Choi, J.-W., Lee, E., An, H., Choi, H. D., & Kim, N. (2015). Mobile phone use and risk of glioma: A case-control study in Korea for 2002–2007. *Environmental health and toxicology*, 30, e2015015. <https://doi.org/10.5620/eh.t.e2015015>.
 11. Smith, T., Yuan, Y., Walker, E., & Davis, F. (2019). *Brain Tumor Registry of Canada (BTRC): Incidence Report 2010–2015*. Brain tumor registry of Canada. Retrieved from <https://braintumourregistry.ca/full-report/>
 12. Kang, J.-M., Ha, J., Hong, E. K., Ju, H. Y., Park, B. K., Shin, S.-H., et al. (2019). A Nationwide, population-based epidemiologic study of childhood brain tumors in Korea, 2005–2014: A comparison with United States data. *Cancer Epidemiology, Biomarkers & Prevention*, 28(2), 409–416. <https://doi.org/10.1158/1055-9965.EPI-18-0634>.
 13. Stiller, C. A., Bayne, A. M., Chakrabarty, A., Kenny, T., & Chumas, P. (2019). Incidence of childhood CNS tumours in Britain and variation in rates by definition of malignant behaviour: Population-based study. *BMC Cancer*, 19(1), 139. <https://doi.org/10.1186/s12885-019-5344-7>.
 14. Arora, R. S., Alston, R. D., Eden, T. O. B., Estlin, E. J., Moran, A., & Birch, J. M. (2009). Age-incidence patterns of primary CNS tumors in children, adolescents, and adults in England. *Neuro-oncology*, 11(4), 403–413. <https://doi.org/10.1215/15228517-2008-097>.
 15. El-Ayadi, M., Ansari, M., Sturm, D., Gielen, G. H., Warmuth-Metz, M., Kramm, C. M., & von Bueren, A. O. (2017). High-grade glioma in very young children: A rare and particular patient population. *Oncotarget*, 8(38), 64564–64578. <https://doi.org/10.18632/oncotarget.18478>.
 16. Ostrom, Q. T., de Blank, P. M., Kruchko, C., Petersen, C. M., Liao, P., Finlay, J. L., Stearns, D. S., Wolff, J. E., Wolinsky, Y., Letterio, J. J., & Barnholtz-Sloan, J. S. (2015). Alex's Lemonade Stand Foundation infant and childhood primary brain and central nervous system tumors diagnosed in the United States in 2007–2011. *Neuro-oncology*, 16(Suppl 10), x1–x36. <https://doi.org/10.1093/neuonc/nou327>.
 17. Wilne, S., Collier, J., Kennedy, C., Koller, K., Grundy, R., & Walker, D. (2007). Presentation of childhood CNS tumours: A systematic review and meta-analysis. *The Lancet Oncology*, 8(8), 685–695. [https://doi.org/10.1016/S1470-2045\(07\)70207-3](https://doi.org/10.1016/S1470-2045(07)70207-3).
 18. Sánchez Fernández, I., & Loddenkemper, T. (2017). Seizures caused by brain tumors in children. *Seizure*, 44, 98–107. <https://doi.org/10.1016/j.seizure.2016.11.028>.
 19. Patel, V., McNinch, N. L., & Rush, S. (2019). Diagnostic delay and morbidity of central nervous system tumors in children and young adults: A pediatric hospital experience. *Journal of Neuro-Oncology*, 143(2), 297–304. <https://doi.org/10.1007/s11060-019-03160-9>.
 20. Reulecke, B. C., Erker, C. G., Fiedler, B. J., Niederstadt, T.-U., & Kurlemann, G. (2008). Brain tumors in children: Initial symptoms and their influence on the time span between symptom onset and diagnosis. *Journal of Child Neurology*, 23(2), 178–183. <https://doi.org/10.1177/0883073807308692>.
 21. Mehta, V., Chapman, A., McNeely, P. D., Walling, S., & Howes, W. J. (2002). Latency between symptom onset and diagnosis of pediatric brain tumors: An eastern Canadian geographic study. *Neurosurgery*, 51(2), 365–372 discussion 372.
 22. Panigrahy, A., & Blüml, S. (2009). Neuroimaging of pediatric brain tumors: From basic to advanced magnetic resonance imaging (MRI). *Journal of Child Neurology*, 24(11), 1343–1365. <https://doi.org/10.1177/0883073809342129>.
 23. Dallery, F., Bouzerar, R., Michel, D., Attencourt, C., Promelle, V., Peltier, J., Constans, J. M., Balédent, O., & Gondry-Jouet, C. (2017). Perfusion magnetic resonance imaging in pediatric brain tumors. *Neuroradiology*, 59(11), 1143–1153. <https://doi.org/10.1007/s00234-017-1917-9>.
 24. Chaddad, A., Kucharczyk, M. J., Daniel, P., Sabri, S., Jean-Claude, B. J., Niazi, T., & Abdulkarim, B. (2019). Radiomics in glioblastoma: Current status and challenges facing clinical implementation. *Frontiers in Oncology*, 9, 374. <https://doi.org/10.3389/fonc.2019.00374>.
 25. Pan, C.-C., Liu, J., Tang, J., Chen, X., Chen, F., Wu, Y.-L., Geng, Y. B., Xu, C., Zhang, X., Wu, Z., Gao, P. Y., Zhang, J. T., Yan, H., Liao, H., & Zhang, L.-W. (2019). A machine learning-based prediction model of H3K27M mutations in brainstem gliomas using conventional MRI and clinical features. *Radiotherapy and Oncology*, 130, 172–179. <https://doi.org/10.1016/j.radonc.2018.07.011>.
 26. Collet, S., Valable, S., Constans, J. M., Lechapt-Zalcman, E., Roussel, S., Delcroix, N., Abbas, A., Ibazizene, M., Bernaudin, M., Barré, L., Derlon, J. M., & Guillamo, J. S. (2015). [(18)F]-fluoro-L-thymidine PET and advanced MRI for preoperative grading of gliomas. *NeuroImage. Clinical*, 8, 448–454. <https://doi.org/10.1016/j.nicl.2015.05.012>.
 27. Morana, G., Piccardo, A., Tortora, D., Puntoni, M., Severino, M., Nozza, P., Ravegnani, M., Consales, A., Mascelli, S., Raso, A., Cabria, M., Verrico, A., Milanaccio, C., & Rossi, A. (2017). Grading and outcome prediction of pediatric diffuse astrocytic tumors with diffusion and arterial spin labeling perfusion MRI in comparison with 18F-DOPA PET. *European Journal of Nuclear Medicine and Molecular Imaging*, 44(12), 2084–2093. <https://doi.org/10.1007/s00259-017-3777-2>.
 28. Zach, L., Guez, D., Last, D., Daniels, D., Grober, Y., Nissim, O., Hoffmann, C., Nass, D., Talianski, A., Spiegelmann, R., Cohen, Z. R., & Mardor, Y. (2012). Delayed contrast extravasation MRI for depicting tumor and non-tumoral tissues in primary and metastatic brain tumors. *PLoS One*, 7(12), e52008. <https://doi.org/10.1371/journal.pone.0052008>.
 29. Zach, L., Guez, D., Last, D., Daniels, D., Grober, Y., Nissim, O., Hoffmann, C., Nass, D., Talianski, A., Spiegelmann, R., Tsarfaty, G., Salomon, S., Hadani, M., Kanner, A., Blumenthal, D. T., Bukstein, F., Yalon, M., Zauberman, J., Roth, J., Shoshan, Y.,

- Fridman, E., Wygoda, M., Limon, D., Tzuk, T., Cohen, Z. R., & Mardor, Y. (2015). Delayed contrast extravasation MRI: A new paradigm in neuro-oncology. *Neuro-oncology*, *17*(3), 457–465. <https://doi.org/10.1093/neuonc/nou230>.
30. Davis, T., Doyle, H., Tobias, V., Ellison, D. W., & Ziegler, D. S. (2016). Case report of spontaneous resolution of a congenital glioblastoma. *Pediatrics*, *137*(4). <https://doi.org/10.1542/peds.2015-1241>.
 31. Kramm, C. M., Wagner, S., Van Gool, S., Schmid, H., Sträter, R., Gnekow, A., et al. (2006). Improved survival after gross total resection of malignant gliomas in pediatric patients from the HIT-GBM studies. *Anticancer Research*, *26*(5B), 3773–3779.
 32. Finlay, J. L., Boyett, J. M., Yates, A. J., Wisoff, J. H., Milstein, J. M., Geyer, J. R., Bertolone, S. J., McGuire, P., Cherlow, J. M., & Tefft, M. (1995). Randomized phase III trial in childhood high-grade astrocytoma comparing vincristine, lomustine, and prednisone with the eight-drugs-in-1-day regimen. Children's Cancer group. *Journal of Clinical Oncology*, *13*(1), 112–123. <https://doi.org/10.1200/JCO.1995.13.1.112>.
 33. Walston, S., Hamstra, D. A., Oh, K., Woods, G., Guiou, M., Olshefski, R. S., Chakravarti, A., & Williams, T. M. (2015). A multi-institutional experience in pediatric high-grade glioma. *Frontiers in Oncology*, *5*, 28. <https://doi.org/10.3389/fonc.2015.00028>.
 34. Adams, H., Adams, H. H. H., Jackson, C., Rincon-Torroella, J., Jallo, G. I., & Quiñones-Hinojosa, A. (2016). Evaluating extent of resection in pediatric glioblastoma: A multiple propensity score-adjusted population-based analysis. *Child's Nervous System*, *32*(3), 493–503. <https://doi.org/10.1007/s00381-015-3006-x>.
 35. Duffner, P. K., Horowitz, M. E., Krischer, J. P., Friedman, H. S., Burger, P. C., Cohen, M. E., Sanford, R. A., Mulhern, R. K., James, H. E., & Freeman, C. R. (1993). Postoperative chemotherapy and delayed radiation in children less than three years of age with malignant brain tumors. *The New England Journal of Medicine*, *328*(24), 1725–1731. <https://doi.org/10.1056/NEJM199306173282401>.
 36. Dufour, C., Grill, J., Lellouch-Tubiana, A., Puget, S., Chastagner, P., Frappaz, D., Doz, F., Pichon, F., Plantaz, D., Genet, J. C., Raquin, M. A., & Kalifa, C. (2006). High-grade glioma in children under 5 years of age: A chemotherapy only approach with the BBSFOP protocol. *European Journal of Cancer*, *42*(17), 2939–2945. <https://doi.org/10.1016/j.ejca.2006.06.021>.
 37. Roddy, E., Sear, K., Felton, E., Tamrazi, B., Gauvain, K., Torkildson, J., Buono, B. D., Samuel, D., Haas-Kogan, D. A., Chen, J., Goldsby, R. E., Banerjee, A., Lupo, J. M., Molinaro, A. M., Fullerton, H. J., & Mueller, S. (2016). Presence of cerebral microbleeds is associated with worse executive function in pediatric brain tumor survivors. *Neuro-oncology*, *18*(11), 1548–1558. <https://doi.org/10.1093/neuonc/nov163>.
 38. Mueller, S., Fullerton, H. J., Stratton, K., Leisenring, W., Weathers, R. E., Stovall, M., Armstrong, G. T., Goldsby, R. E., Packer, R. J., Sklar, C. A., Bowers, D. C., Robison, L. L., & Krull, K. R. (2013). Radiation, atherosclerotic risk factors, and stroke risk in survivors of pediatric cancer: A report from the childhood cancer survivor study. *International Journal of Radiation Oncology, Biology, Physics*, *86*(4), 649–655. <https://doi.org/10.1016/j.ijrobp.2013.03.034>.
 39. Fouladi, M., Gilger, E., Kocak, M., Wallace, D., Buchanan, G., Reeves, C., Robbins, N., Merchant, T., Kun, L. E., Khan, R., Gajjar, A., & Mulhern, R. (2005). Intellectual and functional outcome of children 3 years old or younger who have CNS malignancies. *Journal of Clinical Oncology*, *23*(28), 7152–7160. <https://doi.org/10.1200/JCO.2005.01.214>.
 40. Cohen, B. H., Packer, R. J., Siegel, K. R., Rorke, L. B., D'Angio, G., Sutton, L. N., et al. (1993). Brain tumors in children under 2 years: Treatment, survival and long-term prognosis. *Pediatric Neurosurgery*, *19*(4), 171–179. <https://doi.org/10.1159/000120727>.
 41. Brinkman, T. M., Krasin, M. J., Liu, W., Armstrong, G. T., Ojha, R. P., Sadighi, Z. S., Gupta, P., Kimberg, C., Srivastava, D., Merchant, T. E., Gajjar, A., Robison, L. L., Hudson, M. M., & Krull, K. R. (2016). Long-term neurocognitive functioning and social attainment in adult survivors of pediatric CNS tumors: Results from the St Jude lifetime cohort study. *Journal of Clinical Oncology*, *34*(12), 1358–1367. <https://doi.org/10.1200/JCO.2015.62.2589>.
 42. Ruben, J. D., Dally, M., Bailey, M., Smith, R., McLean, C. A., & Fedele, P. (2006). Cerebral radiation necrosis: Incidence, outcomes, and risk factors with emphasis on radiation parameters and chemotherapy. *International Journal of Radiation Oncology, Biology, Physics*, *65*(2), 499–508. <https://doi.org/10.1016/j.ijrobp.2005.12.002>.
 43. Tsang, D. S., Oliveira, C., Bouffet, E., Hawkins, C., Ramaswamy, V., Yee, R., et al. (2019). Repeat irradiation for children with supratentorial high-grade glioma. *Pediatric Blood & Cancer*, *66*(9), e27881. <https://doi.org/10.1002/pbc.27881>.
 44. Eaton, B. R., Esiashvili, N., Kim, S., Weyman, E. A., Thornton, L. T., Mazewski, C., MacDonald, T., Ebb, D., MacDonald, S., Tarbell, N. J., & Yock, T. I. (2016). Clinical outcomes among children with standard-risk medulloblastoma treated with proton and photon radiation therapy: A comparison of disease control and overall survival. *International Journal of Radiation Oncology, Biology, Physics*, *94*(1), 133–138. <https://doi.org/10.1016/j.ijrobp.2015.09.014>.
 45. Luu, Q. T., Loreda, L. N., Archambeau, J. O., Yonemoto, L. T., Slater, J. M., & Slater, J. D. (2006). Fractionated proton radiation treatment for pediatric craniopharyngioma: Preliminary report. *Cancer Journal*, *12*(2), 155–159.
 46. Eaton, B. R., Chowdhry, V., Weaver, K., Liu, L., Ebb, D., MacDonald, S. M., et al. (2015). Use of proton therapy for re-irradiation in pediatric intracranial ependymoma. *Radiotherapy and Oncology*, *116*(2), 301–308. <https://doi.org/10.1016/j.radonc.2015.07.023>.
 47. Mizumoto, M., Oshiro, Y., Takizawa, D., Fukushima, T., Fukushima, H., Yamamoto, T., Muroi, A., Okumura, T., Tsuboi, K., & Sakurai, H. (2015). Proton beam therapy for pediatric ependymoma. *Pediatrics International*, *57*(4), 567–571. <https://doi.org/10.1111/ped.12624>.
 48. Harrabi, S. B., Bougatf, N., Mohr, A., Haberer, T., Herfarth, K., Combs, S. E., Debus, J., & Adeberg, S. (2016). Dosimetric advantages of proton therapy over conventional radiotherapy with photons in young patients and adults with low-grade glioma. *Strahlentherapie und Onkologie*, *192*(11), 759–769. <https://doi.org/10.1007/s00066-016-1005-9>.
 49. Vora, S. A., Gondi, V., Tseng, Y. D., Vargas, C. E., Larson, G. L., Tsai, H. K., et al. (2018). Safety and efficacy of proton beam therapy for high-grade glioma: Initial report from the proton collaborative group (PCG). *International Journal of Radiation Oncology*Biophysics*Physics*, *102*(3), e362. <https://doi.org/10.1016/j.ijrobp.2018.07.1089>.
 50. Stupp, R., Mason, W. P., van den Bent, M. J., Weller, M., Fisher, B., Taphoorn, M. J. B., et al. (2005). Radiotherapy plus concomitant and adjuvant temozolomide for glioblastoma. *The New England Journal of Medicine*, *352*(10), 987–996. <https://doi.org/10.1056/NEJMoa043330>.
 51. Cohen, K. J., Heideman, R. L., Zhou, T., Holmes, E. J., Lavey, R. S., Bouffet, E., & Pollack, I. F. (2011). Temozolomide in the treatment of children with newly diagnosed diffuse intrinsic pontine gliomas: A report from the Children's Oncology Group. *Neuro-oncology*, *13*(4), 410–416. <https://doi.org/10.1093/neuonc/noq205>.

52. Jakacki, R. I., Cohen, K. J., Buxton, A., Krailo, M. D., Burger, P. C., Rosenblum, M. K., Brat, D. J., Hamilton, R. L., Eckel, S. P., Zhou, T., Lavey, R. S., & Pollack, I. F. (2016). Phase 2 study of concurrent radiotherapy and temozolomide followed by temozolomide and lomustine in the treatment of children with high-grade glioma: A report of the Children's Oncology Group ACNS0423 study. *Neuro-oncology*, *18*(10), 1442–1450. <https://doi.org/10.1093/neuonc/now038>.
53. Karremann, M., Krämer, N., Hoffmann, M., Wiese, M., Beilken, A., Corbacioglu, S., et al. (2017). Haematological malignancies following temozolomide treatment for paediatric high-grade glioma. *European Journal of Cancer*, *81*, 1–8. <https://doi.org/10.1016/j.ejca.2017.04.023>.
54. Mackay, A., Burford, A., Carvalho, D., Izquierdo, E., Fazal-Salom, J., Taylor, K. R., et al. (2017). Integrated molecular meta-analysis of 1,000 pediatric high-grade and diffuse intrinsic pontine glioma. *Cancer Cell*, *32*(4), 520–537.e5. <https://doi.org/10.1016/j.ccell.2017.08.017>.
55. Schwartzentruber, J., Korshunov, A., Liu, X.-Y., Jones, D. T. W., Pfaff, E., Jacob, K., et al. (2012). Driver mutations in histone H3.3 and chromatin remodelling genes in paediatric glioblastoma. *Nature*, *482*(7384), 226–231. <https://doi.org/10.1038/nature10833>.
56. Sturm, D., Witt, H., Hovestadt, V., Khuong-Quang, D.-A., Jones, D. T. W., Konermann, C., & Pfister, S. M. (2012). Hotspot mutations in H3F3A and IDH1 define distinct epigenetic and biological subgroups of glioblastoma. *Cancer Cell*, *22*(4), 425–437. <https://doi.org/10.1016/j.ccr.2012.08.024>.
57. Ferris, S. P., Goode, B., Joseph, N. M., Kline, C. N., Samuel, D., Gupta, N., Bollen, A., Perry, A., Mueller, S., & Solomon, D. A. (2016). IDH1 mutation can be present in diffuse astrocytomas and giant cell glioblastomas of young children under 10 years of age. *Acta Neuropathologica*, *132*(1), 153–155. <https://doi.org/10.1007/s00401-016-1579-4>.
58. Guerreiro Stucklin, A. S., Ryall, S., Fukuoka, K., Zapotocky, M., Lassaletta, A., Li, C., Bridge, T., Kim, B., Arnoldo, A., Kowalski, P. E., Zhong, Y., Johnson, M., Li, C., Ramani, A. K., Siddaway, R., Nobre, L. F., de Antonellis, P., Dunham, C., Cheng, S., Boué, D. R., Finlay, J. L., Coven, S. L., de Prada, I., Perez-Somarriba, M., Faria, C. C., Grotzer, M. A., Rushing, E., Sumerauer, D., Zamecnik, J., Krskova, L., Garcia Ariza, M., Cruz, O., Morales la Madrid, A., Solano, P., Terashima, K., Nakano, Y., Ichimura, K., Nagane, M., Sakamoto, H., Gil-da-Costa, M. J., Silva, R., Johnston, D. L., Michaud, J., Wilson, B., van Landeghem, F., Oviedo, A., McNeely, P., Crooks, B., Fried, I., Zhukova, N., Hansford, J. R., Nageswararao, A., Garzia, L., Shago, M., Brudno, M., Irwin, M. S., Bartels, U., Ramaswamy, V., Bouffet, E., Taylor, M. D., Tabori, U., & Hawkins, C. (2019). Alterations in ALK/ROS1/NTRK/MET drive a group of infantile hemispheric gliomas. *Nature Communications*, *10*(1), 4343. <https://doi.org/10.1038/s41467-019-12187-5>.
59. Wu, G., Diaz, A. K., Paugh, B. S., Rankin, S. L., Ju, B., Li, Y., Zhu, X., Qu, C., Chen, X., Zhang, J., Easton, J., Edmonson, M., Ma, X., Lu, C., Nagahawatte, P., Hedlund, E., Rusch, M., Pounds, S., Lin, T., Onar-Thomas, A., Huether, R., Kriwacki, R., Parker, M., Gupta, P., Becksfors, J., Wei, L., Mulder, H. L., Boggs, K., Vadodaria, B., Yergeau, D., Russell, J. C., Ochoa, K., Fulton, R. S., Fulton, L. L., Jones, C., Boop, F. A., Broniscer, A., Wetmore, C., Gajjar, A., Ding, L., Mardis, E. R., Wilson, R. K., Taylor, M. R., Downing, J. R., Ellison, D. W., Zhang, J., & Baker, S. J. (2014). The genomic landscape of diffuse intrinsic pontine glioma and pediatric non-brainstem high-grade glioma. *Nature Genetics*, *46*(5), 444–450. <https://doi.org/10.1038/ng.2938>.
60. Campbell, B. B., Light, N., Fabrizio, D., Zatzman, M., Fuligni, F., de Borja, R., et al. (2017). Comprehensive analysis of hypermutation in human cancer. *Cell*, *171*(5), 1042–1056.e10. <https://doi.org/10.1016/j.cell.2017.09.048>.
61. Amayiri, N., Tabori, U., Campbell, B., Bakry, D., Aronson, M., Durmo, C., et al. (2016). High frequency of mismatch repair deficiency among pediatric high grade gliomas in Jordan. *International Journal of Cancer*, *138*(2), 380–385. <https://doi.org/10.1002/ijc.29724>.
62. Ascierto, P. A. (2012). MEK inhibition in BRAF-mutated melanoma. *The New England Journal of Medicine*, *367*(14), 1364; author reply 1365. <https://doi.org/10.1056/NEJMc1209663>.
63. Toll, S. A., Tran, H. N., Cotter, J., Judkins, A. R., Tamrazi, B., Biegel, J. A., et al. (2019). Sustained response of three pediatric BRAFV600E mutated high-grade gliomas to combined BRAF and MEK inhibitor therapy. *Oncotarget*, *10*(4), 551–557. <https://doi.org/10.18632/oncotarget.26560>.
64. Lassaletta, A., Zapotocky, M., Mistry, M., Ramaswamy, V., Honnorat, M., Krishnatry, R., Guerreiro Stucklin, A., Zhukova, N., Arnoldo, A., Ryall, S., Ling, C., McKeown, T., Loukides, J., Cruz, O., de Torres, C., Ho, C. Y., Packer, R. J., Tatevossian, R., Qaddoumi, I., Harreld, J. H., Dalton, J. D., Mulcahy-Levy, J., Foreman, N., Karajannis, M. A., Wang, S., Snuderl, M., Nageswara Rao, A., Giannini, C., Kieran, M., Ligon, K. L., Garre, M. L., Nozza, P., Mascelli, S., Raso, A., Mueller, S., Nicolaidis, T., Silva, K., Perbet, R., Vasiljevic, A., Faure Conter, C., Frappaz, D., Leary, S., Crane, C., Chan, A., Ng, H. K., Shi, Z. F., Mao, Y., Finch, E., Eisenstat, D., Wilson, B., Carret, A. S., Hauser, P., Sumerauer, D., Krskova, L., Larouche, V., Fleming, A., Zelcer, S., Jabado, N., Rutka, J. T., Dirks, P., Taylor, M. D., Chen, S., Bartels, U., Huang, A., Ellison, D. W., Bouffet, E., Hawkins, C., & Tabori, U. (2017). Therapeutic and prognostic implications of BRAF V600E in pediatric low-grade gliomas. *Journal of Clinical Oncology*, *35*(25), 2934–2941. <https://doi.org/10.1200/JCO.2016.71.8726>.
65. Mistry, M., Zhukova, N., Merico, D., Rakopoulos, P., Krishnatry, R., Shago, M., Stavropoulos, J., Alon, N., Pole, J. D., Ray, P. N., Navickiene, V., Mangerel, J., Remke, M., Buczkowicz, P., Ramaswamy, V., Guerreiro Stucklin, A., Li, M., Young, E. J., Zhang, C., Castelo-Branco, P., Bakry, D., Laughlin, S., Shlien, A., Chan, J., Ligon, K. L., Rutka, J. T., Dirks, P. B., Taylor, M. D., Greenberg, M., Malkin, D., Huang, A., Bouffet, E., Hawkins, C. E., & Tabori, U. (2015). BRAF mutation and CDKN2A deletion define a clinically distinct subgroup of childhood secondary high-grade glioma. *Journal of Clinical Oncology*, *33*(9), 1015–1022. <https://doi.org/10.1200/JCO.2014.58.3922>.
66. Hargrave, D. R., Moreno, L., Broniscer, A., Bouffet, E., Aerts, I., Andre, N., et al. (2018). Dabrafenib in pediatric patients with BRAF V600-positive high-grade glioma (HGG). *Journal of Clinical Oncology*, *36*(15_suppl), 10505–10505. https://doi.org/10.1200/JCO.2018.36.15_suppl.10505.
67. Nicolaidis, T., Nazemi, K., Crawford, J., Kilburn, L., Mintum, J., Gajjar, A., et al. (2017). Pdc19. A safety study of vemurafenib, an oral inhibitor of brafv600e, in children with recurrent/refractory brafv600e mutant brain tumors: Pnoc-002. *Neuro-oncology*, *19*(suppl_6), vi188–vi188. <https://doi.org/10.1093/neuonc/nox168.761>.
68. Phillips, J. J., Gong, H., Chen, K., Joseph, N. M., van Ziffle, J., Bastian, B. C., Grenert, J. P., Kline, C. N., Mueller, S., Banerjee, A., Nicolaidis, T., Gupta, N., Berger, M. S., Lee, H. S., Pekmezci, M., Tihan, T., Bollen, A. W., Perry, A., Shieh, J. T. C., & Solomon, D. A. (2019). The genetic landscape of anaplastic pleomorphic xanthoastrocytoma. *Brain Pathology*, *29*(1), 85–96. <https://doi.org/10.1111/bpa.12639>.
69. Alexandrescu, S., Korshunov, A., Lai, S. H., Dabiri, S., Patil, S., Li, R., Shih, C. S., Bonnin, J. M., Baker, J. A., du, E., Scharnhorst, D. W., Samuel, D., Ellison, D. W., & Perry, A. (2016). Epithelioid glioblastomas and anaplastic epithelioid pleomorphic

- xanthoastrocytomas—same entity or first cousins? *Brain Pathology*, 26(2), 215–223. <https://doi.org/10.1111/bpa.12295>.
70. Ida, C. M., Rodriguez, F. J., Burger, P. C., Caron, A. A., Jenkins, S. M., Spears, G. M., Aranguren, D. L., Lachance, D. H., & Giannini, C. (2015). Pleomorphic xanthoastrocytoma: Natural history and long-term follow-up. *Brain Pathology*, 25(5), 575–586. <https://doi.org/10.1111/bpa.12217>.
 71. Amayiri, N., Swaidan, M., & Al, M. (n.d.). Sustained response to targeted therapy in a patient with disseminated anaplastic pleomorphic xanthoastrocytoma. *Hussaini*....
 72. Korshunov, A., Capper, D., Reuss, D., Schrimpf, D., Ryzhova, M., Hovestadt, V., Sturm, D., Meyer, J., Jones, C., Zheludkova, O., Kumirova, E., Golanov, A., Kool, M., Schüller, U., Mittelbronn, M., Hasselblatt, M., Schittenhelm, J., Reifenberger, G., Herold-Mende, C., Lichter, P., von Deimling, A., Pfister, S. M., & Jones, D. T. W. (2016). Histologically distinct neuroepithelial tumors with histone 3 G34 mutation are molecularly similar and comprise a single nosologic entity. *Acta Neuropathologica*, 131(1), 137–146. <https://doi.org/10.1007/s00401-015-1493-1>.
 73. Donson, A. M., Addo-Yobo, S. O., Handler, M. H., Gore, L., & Foreman, N. K. (2007). MGMT promoter methylation correlates with survival benefit and sensitivity to temozolomide in pediatric glioblastoma. *Pediatric Blood & Cancer*, 48(4), 403–407. <https://doi.org/10.1002/pbc.20803>.
 74. Bjerke, L., Mackay, A., Nandhabalan, M., Burford, A., Jury, A., Popov, S., Bax, D. A., Carvalho, D., Taylor, K. R., Vinci, M., Bajrami, I., McGonnell, I., Lord, C. J., Reis, R. M., Hargrave, D., Ashworth, A., Workman, P., & Jones, C. (2013). Histone H3.3. Mutations drive pediatric glioblastoma through upregulation of MYCN. *Cancer Discovery*, 3(5), 512–519. <https://doi.org/10.1158/2159-8290.CD-12-0426>.
 75. Cerrato, A., Morra, F., & Celetti, A. (2016). Use of poly ADP-ribose polymerase [PARP] inhibitors in cancer cells bearing DDR defects: The rationale for their inclusion in the clinic. *Journal of Experimental & Clinical Cancer Research*, 35(1), 179. <https://doi.org/10.1186/s13046-016-0456-2>.
 76. Sulkowski, P. L., Corso, C. D., Robinson, N. D., Scanlon, S. E., Purshouse, K. R., Bai, H., Liu, Y., Sundaram, R. K., Hegan, D. C., Fons, N. R., Breuer, G. A., Song, Y., Mishra-Gorur, K., de Feyter, H. M., de Graaf, R. A., Surovtseva, Y. V., Kachman, M., Halene, S., Günel, M., Glazer, P. M., & Bindra, R. S. (2017). 2-Hydroxyglutarate produced by neomorphic IDH mutations suppresses homologous recombination and induces PARP inhibitor sensitivity. *Science Translational Medicine*, 9(375). <https://doi.org/10.1126/scitranslmed.aal2463>.
 77. Lu, C., Ward, P. S., Kapoor, G. S., Rohle, D., Turcan, S., Abdel-Wahab, O., Edwards, C. R., Khanin, R., Figueroa, M. E., Melnick, A., Wellen, K. E., O'Rourke, D. M., Berger, S. L., Chan, T. A., Levine, R. L., Mellinghoff, I. K., & Thompson, C. B. (2012). IDH mutation impairs histone demethylation and results in a block to cell differentiation. *Nature*, 483(7390), 474–478. <https://doi.org/10.1038/nature10860>.
 78. Duffner, P. K., Krischer, J. P., Burger, P. C., Cohen, M. E., Backstrom, J. W., Horowitz, M. E., Sanford, R. A., Friedman, H. S., & Kun, L. E. (1996). Treatment of infants with malignant gliomas: The pediatric oncology group experience. *Journal of Neuro-Oncology*, 28(2–3), 245–256. <https://doi.org/10.1007/bf00250203>.
 79. Geyer, J. R., Sposto, R., Jennings, M., Boyett, J. M., Axtell, R. A., Breiger, D., et al. (2005). Multiagent chemotherapy and deferred radiotherapy in infants with malignant brain tumors: A report from the Children's Cancer group. *Journal of Clinical Oncology*, 23(30), 7621–7631. <https://doi.org/10.1200/JCO.2005.09.095>.
 80. Espinoza, J. C., Haley, K., Patel, N., Dhall, G., Gardner, S., Allen, J., Torkildson, J., Cornelius, A., Rassekh, R., Bedros, A., Ettl, M., Garvin, J., Pradhan, K., Corbett, R., Sullivan, M., McGowage, G., Stein, D., Jasty, R., Sands, S. A., Ji, L., Sposto, R., & Finlay, J. L. (2016). Outcome of young children with high-grade glioma treated with irradiation-avoiding intensive chemotherapy regimens: Final report of the head start II and III trials. *Pediatric Blood & Cancer*, 63(10), 1806–1813. <https://doi.org/10.1002/pbc.26118>.
 81. Grundy, R. G., Wilne, S. H., Robinson, K. J., Ironside, J. W., Cox, T., Chong, W. K., et al. (2010). Primary postoperative chemotherapy without radiotherapy for treatment of brain tumours other than ependymoma in children under 3 years: Results of the first UKCCSG/SIOP CNS 9204 trial. *European Journal of Cancer*, 46(1), 120–133. <https://doi.org/10.1016/j.ejca.2009.09.013>.
 82. Strother, D. R., Lafay-Cousin, L., Boyett, J. M., Burger, P., Aronin, P., Constine, L., Duffner, P., Kocak, M., Kun, L. E., Horowitz, M. E., & Gajjar, A. (2014). Benefit from prolonged dose-intensive chemotherapy for infants with malignant brain tumors is restricted to patients with ependymoma: A report of the pediatric oncology group randomized controlled trial 9233/34. *Neuro-oncology*, 16(3), 457–465. <https://doi.org/10.1093/neuonc/not163>.
 83. Miranda, C., Greco, A., Miele, C., Pierotti, M. A., & Van Obberghen, E. (2001). IRS-1 and IRS-2 are recruited by TrkA receptor and oncogenic TRK-T1. *Journal of Cellular Physiology*, 186(1), 35–46. [https://doi.org/10.1002/1097-4652\(200101\)186:1<35::AID-JCP1003>3.0.CO;2-X](https://doi.org/10.1002/1097-4652(200101)186:1<35::AID-JCP1003>3.0.CO;2-X).
 84. International Cancer Genome Consortium PedBrain Tumor Project. (2016). Recurrent MET fusion genes represent a drug target in pediatric glioblastoma. *Nature Medicine*, 22(11), 1314–1320. <https://doi.org/10.1038/nm.4204>.
 85. Jones, D. T. W., Hutter, B., Jäger, N., Korshunov, A., Kool, M., Warnatz, H.-J., et al. (2013). Recurrent somatic alterations of FGFR1 and NTRK2 in pilocytic astrocytoma. *Nature Genetics*, 45(8), 927–932. <https://doi.org/10.1038/ng.2682>.
 86. Desai, A. V., Brodeur, G. M., Foster, J., Shusterman, S., Sabnis, A. J., Macy, M., ... Fox, E. (2017). Abstract CT030: STARTRK-NG: A phase 1/1b study of entrectinib in children and adolescents with advanced solid tumors and primary CNS tumors, with or without TRK, ROS1, or ALK fusions. In *Clinical Trials* (pp. CT030-CT030). Presented at the Proceedings: AACR Annual Meeting 2017; April 1–5, 2017; Washington, DC, American Association for Cancer Research. <https://doi.org/10.1158/1538-7445.AM2017-CT030>.
 87. Rangaraju, S., Li, G., Christiansen, J., Hornby, Z., Multani, P., Esquibel, V., & Maneval, E. C. (2017). Trth-10. Pediatric phase 1/1b study of entrectinib in patients with primary brain tumors, neuroblastoma, and ntrk, ros1, or alk fusions. *Neuro-oncology*, 19(suppl_4), iv53–iv53. <https://doi.org/10.1093/neuonc/nox083.222>.
 88. Laetsch, T. W., DuBois, S. G., Mascarenhas, L., Turpin, B., Federman, N., Albert, C. M., et al. (2018). Larotrectinib for paediatric solid tumours harbouring NTRK gene fusions: Phase 1 results from a multicentre, open-label, phase 1/2 study. *The Lancet Oncology*, 19(5), 705–714. [https://doi.org/10.1016/S1470-2045\(18\)30119-0](https://doi.org/10.1016/S1470-2045(18)30119-0).
 89. Drilon, A., Laetsch, T. W., Kummar, S., DuBois, S. G., Lassen, U. N., Demetri, G. D., et al. (2018). Efficacy of larotrectinib in TRK fusion-positive cancers in adults and children. *The New England Journal of Medicine*, 378(8), 731–739. <https://doi.org/10.1056/NEJMoal714448>.
 90. Ziegler, D. S., Wong, M., Mayoh, C., Kumar, A., Tsoli, M., Mould, E., Tyrrell, V., Khuong-Quang, D. A., Pinese, M., Gayevskiy, V., Cohn, R. J., Lau, L. M. S., Reynolds, M., Cox, M. C., Gifford, A., Rodriguez, M., Cowley, M. J., Ekert, P. G., Marshall, G. M., & Haber, M. (2018). Brief report: Potent clinical and radiological response to larotrectinib in TRK fusion-driven high-grade glioma. *British Journal of Cancer*, 119(6), 693–696. <https://doi.org/10.1038/s41416-018-0251-2>.

91. Wimmer, K., Kratz, C. P., Vasen, H. F. A., Caron, O., Colas, C., Entz-Werle, N., et al. (2014). Diagnostic criteria for constitutional mismatch repair deficiency syndrome: Suggestions of the European consortium “care for CMMRD” (C4CMMRD). *Journal of Medical Genetics*, *51*(6), 355–365. <https://doi.org/10.1136/jmedgenet-2014-102284>.
92. Bakry, D., Aronson, M., Durno, C., Rimawi, H., Farah, R., Alharbi, Q. K., Alharbi, M., Shamvil, A., Ben-Shachar, S., Mistry, M., Constantini, S., Dvir, R., Qaddoumi, I., Gallinger, S., Lerner-Ellis, J., Pollett, A., Stephens, D., Kelies, S., Chao, E., Malkin, D., Bouffet, E., Hawkins, C., & Tabori, U. (2014). Genetic and clinical determinants of constitutional mismatch repair deficiency syndrome: Report from the constitutional mismatch repair deficiency consortium. *European Journal of Cancer*, *50*(5), 987–996. <https://doi.org/10.1016/j.ejca.2013.12.005>.
93. Zhang, J., Walsh, M. F., Wu, G., Edmonson, M. N., Gruber, T. A., Easton, J., Hedges, D., Ma, X., Zhou, X., Yergeau, D. A., Wilkinson, M. R., Vadodaria, B., Chen, X., McGee, R., Hines-Dowell, S., Nuccio, R., Quinn, E., Shurtleff, S. A., Rusch, M., Patel, A., Becksfort, J. B., Wang, S., Weaver, M. S., Ding, L., Mardis, E. R., Wilson, R. K., Gajjar, A., Ellison, D. W., Pappo, A. S., Pui, C. H., Nichols, K. E., & Downing, J. R. (2015). Germline mutations in predisposition genes in pediatric cancer. *The New England Journal of Medicine*, *373*(24), 2336–2346. <https://doi.org/10.1056/NEJMoa1508054>.
94. Sotiriou, C., & Fumagalli, D. (2014). The landscape of genomic alterations. *EUROPEAN ...*
95. Durno, C. A., Aronson, M., Tabori, U., Malkin, D., Gallinger, S., & Chan, H. S. L. (2012). Oncologic surveillance for subjects with biallelic mismatch repair gene mutations: 10 year follow-up of a kindred. *Pediatric Blood & Cancer*, *59*(4), 652–656. <https://doi.org/10.1002/pbc.24019>.
96. Gettinger, S. N., Horn, L., Gandhi, L., Spigel, D. R., Antonia, S. J., Rizvi, N. A., Powderly, J. D., Heist, R. S., Carvajal, R. D., Jackman, D. M., Sequist, L. V., Smith, D. C., Leming, P., Carbone, D. P., Pinder-Schenck, M. C., Topalian, S. L., Hodi, F. S., Sosman, J. A., Sznol, M., McDermott, D., Pardoll, D. M., Sankar, V., Ahlers, C. M., Salvati, M., Wigginton, J. M., Hellmann, M. D., Kollia, G. D., Gupta, A. K., & Brahmer, J. R. (2015). Overall survival and long-term safety of nivolumab (anti-programmed death 1 antibody, BMS-936558, ONO-4538) in patients with previously treated advanced non-small-cell lung cancer. *Journal of Clinical Oncology*, *33*(18), 2004–2012. <https://doi.org/10.1200/JCO.2014.58.3708>.
97. Ciombor, K. K., & Goldberg, R. M. (2018). Hypermutated tumors and immune checkpoint inhibition. *Drugs*, *78*(2), 155–162. <https://doi.org/10.1007/s40265-018-0863-0>.
98. Sharma, P., & Allison, J. P. (2015). The future of immune checkpoint therapy. *Science*, *348*(6230), 56–61. <https://doi.org/10.1126/science.aaa8172>.
99. Bouffet, E., Larouche, V., Campbell, B. B., Merico, D., de Borja, R., Aronson, M., Durno, C., Krueger, J., Cabric, V., Ramaswamy, V., Zhukova, N., Mason, G., Farah, R., Afzal, S., Yalon, M., Rechavi, G., Magimairajan, V., Walsh, M. F., Constantini, S., Dvir, R., Elhasid, R., Reddy, A., Osborn, M., Sullivan, M., Hansford, J., Dodgshun, A., Klauber-Demore, N., Peterson, L., Patel, S., Lindhorst, S., Atkinson, J., Cohen, Z., Laframboise, R., Dirks, P., Taylor, M., Malkin, D., Albrecht, S., Dudley, R. W., Jabado, N., Hawkins, C. E., Shlien, A., & Tabori, U. (2016). Immune checkpoint inhibition for hypermutant glioblastoma multiforme resulting from germline biallelic mismatch repair deficiency. *Journal of Clinical Oncology*, *34*(19), 2206–2211. <https://doi.org/10.1200/JCO.2016.66.6552>.
100. AlHarbi, M., Ali Mobark, N., AIMubarak, L., Aljelaify, R., AlSaeed, M., Almutairi, A., Alqubaishi, F., Hussain, M. E., Balbaid, A. A. O., Said Marie, A., AlSubaie, L., AlShieban, S., alTassan, N., Ramkissoon, S. H., & Abedalthagafi, M. (2018). Durable response to nivolumab in a pediatric patient with refractory glioblastoma and constitutional biallelic mismatch repair deficiency. *The Oncologist*, *23*(12), 1401–1406. <https://doi.org/10.1634/theoncologist.2018-0163>.
101. Larouche, V., Atkinson, J., Albrecht, S., Laframboise, R., Jabado, N., Tabori, U., Bouffet, E., & international bMMRD consortium international bMMRD consortium. (2018). Sustained complete response of recurrent glioblastoma to combined checkpoint inhibition in a young patient with constitutional mismatch repair deficiency. *Pediatric Blood & Cancer*, *65*(12), e27389. <https://doi.org/10.1002/pbc.27389>.
102. Peterson, K. M., Shao, C., McCarter, R., MacDonald, T. J., & Byrne, J. (2006). An analysis of SEER data of increasing risk of secondary malignant neoplasms among long-term survivors of childhood brain tumors. *Pediatric Blood & Cancer*, *47*(1), 83–88. <https://doi.org/10.1002/pbc.20690>.
103. Carret, A.-S., Tabori, U., Crooks, B., Hukin, J., Odame, I., Johnston, D. L., et al. (2006). Outcome of secondary high-grade glioma in children previously treated for a malignant condition: A study of the Canadian pediatric brain tumour consortium. *Radiotherapy and Oncology*, *81*(1), 33–38. <https://doi.org/10.1016/j.radonc.2006.08.005>.
104. López, G. Y., Van Ziffle, J., Onodera, C., Grenert, J. P., Yeh, I., Bastian, B. C., et al. (2019). The genetic landscape of gliomas arising after therapeutic radiation. *Acta Neuropathologica*, *137*(1), 139–150. <https://doi.org/10.1007/s00401-018-1906-z>.
105. Grill, J., Massimino, M., Bouffet, E., Azizi, A. A., McCowage, G., Cañete, A., Saran, F., le Deley, M. C., Varlet, P., Morgan, P. S., Jaspan, T., Jones, C., Giangaspero, F., Smith, H., Garcia, J., Elze, M. C., Rousseau, R. F., Abrey, L., Hargrave, D., & Vassal, G. (2018). Phase II, open-label, randomized, multicenter trial (HERBY) of bevacizumab in pediatric patients with newly diagnosed high-grade glioma. *Journal of Clinical Oncology*, *36*(10), 951–958. <https://doi.org/10.1200/JCO.2017.76.0611>.
106. Mackay, A., Burford, A., Molinari, V., Jones, D. T. W., Izquierdo, E., Brouwer-Visser, J., et al. (2018). Molecular, pathological, radiological, and immune profiling of non-brainstem pediatric high-grade glioma from the HERBY phase II randomized trial. *Cancer Cell*, *33*(5), 829–842.e5. <https://doi.org/10.1016/j.ccell.2018.04.004>.
107. Wick, W., Weller, M., van den Bent, M., Sanson, M., Weiler, M., von Deimling, A., Plass, C., Hegi, M., Platten, M., & Reifenberger, G. (2014). MGMT testing—the challenges for biomarker-based glioma treatment. *Nature Reviews. Neurology*, *10*(7), 372–385. <https://doi.org/10.1038/nrneurol.2014.100>.
108. Wang, S. S., Bandopadhyay, P., & Jenkins, M. R. (2019). Towards immunotherapy for pediatric brain tumors. *Trends in Immunology*, *40*(8), 748–761. <https://doi.org/10.1016/j.it.2019.05.009>.
109. Cloughesy, T. F., Mochizuki, A. Y., Orpilla, J. R., Hugo, W., Lee, A. H., Davidson, T. B., et al. (2019). Neoadjuvant anti-PD-1 immunotherapy promotes a survival benefit with intratumoral and systemic immune responses in recurrent glioblastoma. *Nature Medicine*, *25*(3), 477–486. <https://doi.org/10.1038/s41591-018-0337-7>.
110. Chiocca, E. A., Yu, J. S., Lukas, R. V., Solomon, I. H., Ligon, K. L., Nakashima, H., Triggs, D. A., Reardon, D. A., Wen, P., Stopa, B. M., Naik, A., Rudnick, J., Hu, J. L., Kumthekar, P., Yamini, B., Buck, J. Y., Demars, N., Barrett, J. A., Gelb, A. B., Zhou, J., Lebel, F., & Cooper, L. J. N. (2019). Regulatable interleukin-12 gene therapy in patients with recurrent high-grade glioma: Results of a phase 1 trial. *Science Translational Medicine*, *11*(505). <https://doi.org/10.1126/scitranslmed.aaw5680>.

111. Bobo, R. H., Laske, D. W., Akbasak, A., Morrison, P. F., Dedrick, R. L., & Oldfield, E. H. (1994). Convection-enhanced delivery of macromolecules in the brain. *Proceedings of the National Academy of Sciences of the United States of America*, *91*(6), 2076–2080. <https://doi.org/10.1073/pnas.91.6.2076>.
112. Kunwar, S., Chang, S., Westphal, M., Vogelbaum, M., Sampson, J., Barnett, G., et al. (2010). Phase III randomized trial of CED of IL13-PE38QQR vs Gliadel wafers for recurrent glioblastoma. *Neuro-oncology*, *12*(8), 871–881. <https://doi.org/10.1093/neuonc/nop054>.
113. Kunwar, S., Prados, M. D., & Chang, S. M. (2007). Direct intracerebral delivery of cintredekin besudotox (IL13-PE38QQR) in recurrent malignant glioma: a report by the Cintredekin Besudotox Intraparenchymal *Journal of Clinical ...*
114. Lidar, Z., Mardor, Y., Jonas, T., Pfeffer, R., Faibel, M., Nass, D., et al. (2004). Convection-enhanced delivery of paclitaxel for the treatment of recurrent malignant glioma: A phase I/II clinical study. *Journal of Neurosurgery*, *100*(3), 472–479. <https://doi.org/10.3171/jns.2004.100.3.0472>.
115. Souweidane, M. M., Kramer, K., Pandit-Taskar, N., Zhou, Z., Haque, S., Zanzonico, P., Carrasquillo, J. A., Lyashchenko, S. K., Thakur, S. B., Donzelli, M., Turner, R. S., Lewis, J. S., Cheung, N. V., Larson, S. M., & Dunkel, I. J. (2018). Convection-enhanced delivery for diffuse intrinsic pontine glioma: A single-centre, dose-escalation, phase 1 trial. *The Lancet Oncology*, *19*(8), 1040–1050. [https://doi.org/10.1016/S1470-2045\(18\)30322-X](https://doi.org/10.1016/S1470-2045(18)30322-X).
116. Hynynen, K., McDannold, N., Vykhodtseva, N., Raymond, S., Weissleder, R., Jolesz, F. A., & Sheikov, N. (2006). Focal disruption of the blood-brain barrier due to 260-kHz ultrasound bursts: A method for molecular imaging and targeted drug delivery. *Journal of Neurosurgery*, *105*(3), 445–454. <https://doi.org/10.3171/jns.2006.105.3.445>.
117. Zhu, P., & Zhu, J.-J. (2017). Tumor treating fields: A novel and effective therapy for glioblastoma: Mechanism, efficacy, safety and future perspectives. *Chinese Clinical Oncology*, *6*(4), 41. <https://doi.org/10.21037/cco.2017.06.29>.
118. Stupp, R., Taillibert, S., Kanner, A. A., Kesari, S., Steinberg, D. M., Toms, S. A., Taylor, L. P., Lieberman, F., Silvani, A., Fink, K. L., Barnett, G. H., Zhu, J. J., Henson, J. W., Engelhard, H. H., Chen, T. C., Tran, D. D., Sroubek, J., Tran, N. D., Hottinger, A. F., Landolfi, J., Desai, R., Caroli, M., Kew, Y., Honnorat, J., Idbaih, A., Kirson, E. D., Weinberg, U., Palti, Y., Hegi, M. E., & Ram, Z. (2015). Maintenance therapy with tumor-treating fields plus temozolomide vs temozolomide alone for glioblastoma: A randomized clinical trial. *The Journal of the American Medical Association*, *314*(23), 2535–2543. <https://doi.org/10.1001/jama.2015.16669>.
119. Miller, A. M., Shah, R. H., Pentsova, E. I., Pourmaleki, M., Briggs, S., Distefano, N., Zheng, Y., Skakodub, A., Mehta, S. A., Campos, C., Hsieh, W. Y., Selcuklu, S. D., Ling, L., Meng, F., Jing, X., Samoila, A., Bale, T. A., Tsui, D. W. Y., Grommes, C., Viale, A., Souweidane, M. M., Tabar, V., Brennan, C. W., Reiner, A. S., Rosenblum, M., Panageas, K. S., DeAngelis, L., Young, R. J., Berger, M. F., & Mellinghoff, I. K. (2019). Tracking tumour evolution in glioma through liquid biopsies of cerebrospinal fluid. *Nature*, *565*(7741), 654–658. <https://doi.org/10.1038/s41586-019-0882-3>.
120. De Mattos-Arruda, L., Mayor, R., Ng, C. K. Y., Weigelt, B., Martínez-Ricarte, F., Torrejon, D., et al. (2015). Cerebrospinal fluid-derived circulating tumour DNA better represents the genomic alterations of brain tumours than plasma. *Nature Communications*, *6*, 8839. <https://doi.org/10.1038/ncomms9839>.
121. Mueller, S., Jain, P., Liang, W. S., Kilburn, L., Kline, C., Gupta, N., et al. (2019). A pilot precision medicine trial for children with diffuse intrinsic pontine glioma-PNOC003: A report from the Pacific Pediatric Neuro-Oncology Consortium. *International Journal of Cancer*, *145*(7), 1889–1901. <https://doi.org/10.1002/ijc.32258>.

Publisher's note Springer Nature remains neutral with regard to jurisdictional claims in published maps and institutional affiliations.