



Case Report

Circumferential intradural meningioma of the thoracic spine: Case report and literature review

Sneha Bisht¹, Raphael Laurente², K. Joshi George²

¹Department of Neurosurgery, Kathmandu University, Kathmandu Medical College and Teaching Hospital, Kathmandu, Nepal, ²Department of Neurosurgery, Salford Royal NHS Foundation Trust, Salford, United Kingdom.

E-mail: *Sneha Bisht - yashmi.sb@gmail.com; Raphael Laurente - raphael.laurente@doctors.org.uk; K. Joshi George - joshi.george@srft.nhs.uk



***Corresponding author:**

Sneha Bisht,
Department of Neurosurgery,
Kathmandu University,
Kathmandu Medical College
and Teaching Hospital,
Kathmandu, Nepal.

yashmi.sb@gmail.com

Received : 03 December 2020

Accepted : 28 January 2021

Published : 24 March 2021

DOI

10.25259/SNI_869_2020

Quick Response Code:



ABSTRACT

Background: Meningiomas are common intradural extramedullary spinal tumors with a predilection for the thoracic spine. They are mostly benign (90%), with only a few showing malignant potential. However, circumferential intradural meningiomas surrounding the spinal cord are exceptionally rare. Here, we present a 40-year-old patient with a T6-T7 circumferential lesion who underwent surgery. In addition, we reviewed three similar cases previously reported in the literature.

Case Description: A 40-year-old female presented with paraparesis. Imaging demonstrated a T6-T7 thoracic circumferential intradural lesion, considered to most likely be a meningioma. At surgery, the posterolateral portion of the tumor was removed, but there was residual ventral disease. The tumor recurred several years later, and was again partially removed, now leaving her with a residual neurological deficit. Three similar cases of circumferential meningiomas, one cervical and two thoracic, were reported from the literature.

Conclusion: Circumferential meningiomas pose unique and significant surgical challenges, particularly since resection of the posterolateral components is feasible, but some tumor may have to be left ventrally to avoid injury to the anterior spinal artery, that may recur.

Keywords: Circumferential, Excision, Meningioma, Spine, Thoracic

INTRODUCTION

Meningiomas are common intradural extramedullary spinal lesions most often seen in the thoracic spine. Most lesions are benign (90%), and only rarely do they undergo malignant transformation.^[4] Circumferential intradural en plaque meningiomas are, however, rare. They are optimally treated with gross-total resection; partial resections may result in tumor recurrence within 5 postoperative years.^[1,3,7] Here, we present a 40-year-old female with T6-T7 circumferential meningioma whose residual anterior disease became symptomatic 5 years following the index operation.

CASE REPORT

Presentation

A 40-year-old female presented with an 18-month history of intermittent pelvic/lower extremity numbness, and 4 months of loss of balance and urinary/fecal incontinence. She was known to have

This is an open-access article distributed under the terms of the Creative Commons Attribution-Non Commercial-Share Alike 4.0 License, which allows others to remix, tweak, and build upon the work non-commercially, as long as the author is credited and the new creations are licensed under the identical terms.

©2021 Published by Scientific Scholar on behalf of Surgical Neurology International

Systemic Lupus Erythematosus and had been maintained on hydroxychloroquine. On neurological examination, she exhibited a sensory level at T10 with clonus and hyperreflexia in both lower extremities.

Diagnostic testing

The magnetic resonance imaging (MRI) findings demonstrate an intradural lesion at T6-7 that circumferentially encased the spinal cord [Figure 1]. A CT Thorax-Abdo-Pelvis additionally showed a ring enhancing lesion on the liver later confirmed to be a hemangioma (on MRI).

Intervention done and follow-up

The patient underwent a T6-T8 laminectomy for resection of the intradural lesion. Intraoperative neurophysiology monitoring was used. The tumor was found to be very adherent to the spinal cord. Although the lateral/dorsal segments of tumor were removed, the ventral portion was left behind to protect the anterior spinal artery. The histology confirmed a psammomatous meningioma (WHO Grade I). Postoperative recovery was unremarkable and the patient regained her mobility. Postoperative scans were satisfactory, and the patient was later discharged uneventfully [Figure 2].

Five years later, the patient again presented with 4 weeks of decreased mobility, worsening balance, and lower limb weakness. She demonstrated a T7 sensory level. The repeat MR scans showed tumor recurrence and cord compression at the T5 to T7 levels, and the tumor was now larger than noted at the initial presentation [Figure 3].

The patient underwent a second surgery for intradural debulking of the tumor, and fusion from T3 to T10 under intraoperative neurophysiological monitoring. The tumor was calcified and adherent to the cord, with only a small soft component being found. The posterior and lateral

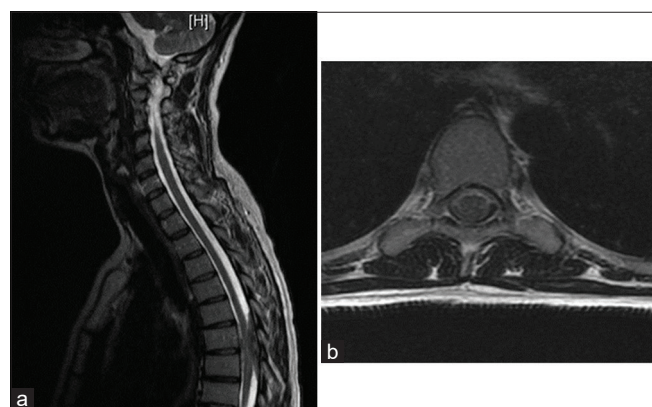


Figure 1: T2 sequenced magnetic resonance image of (a) sagittal and (b) axial section of thoracic spine showing a circumferential intradural lesion at T6-T7 compressing the spinal cord.

portions of the tumor were resected, while a small amount of tumor was left ventrally, again to protect the anterior spinal artery. Postoperatively, the patient had paraparesis with proprioceptive loss. After 6 months of neurorehabilitation, she was able to walk with a cane. The postoperative scans showed some residual tumor ventrally, and a small pseudo-meningocele [Figure 4].

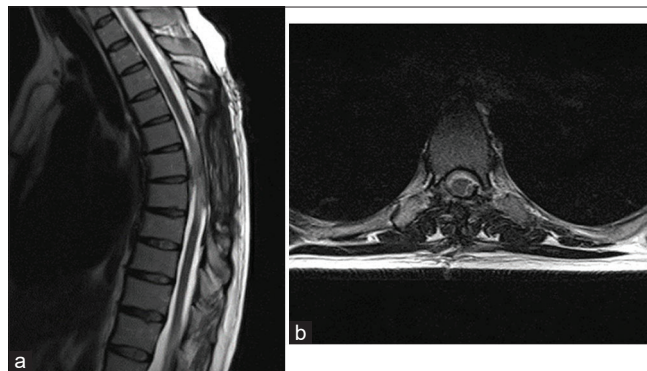


Figure 2: T2-sequenced magnetic resonance image of spinal cord at T7 level after T6-T8 laminectomy (a) sagittal and (b) axial views showing satisfactory decompression of spinal cord.

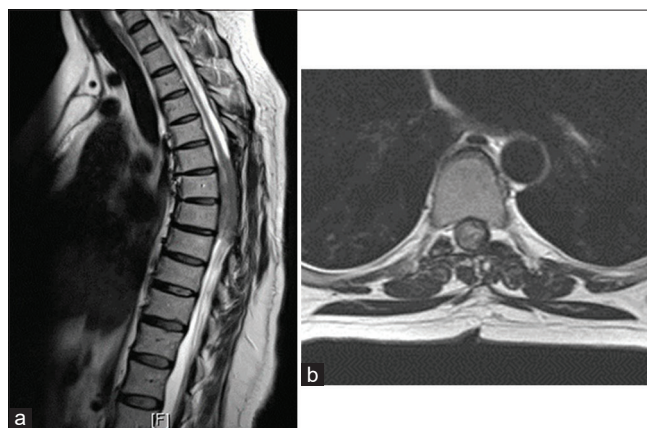


Figure 3: T2-sequenced magnetic resonance image showing recurrence of tumor at same level T7 (a) sagittal and (b) axial views.

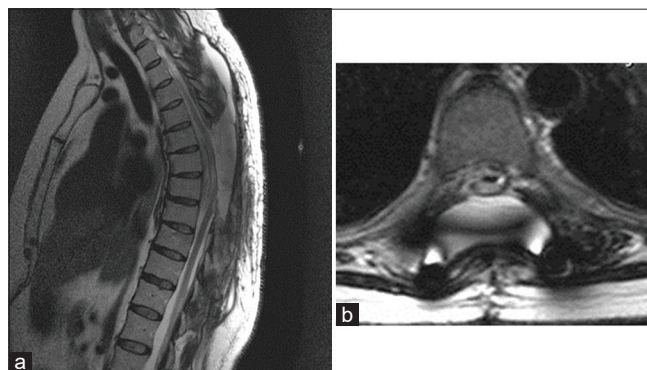


Figure 4: T2-sequenced magnetic resonance image of satisfactory decompression after further tumor debulking and T3-T10 fixation (a) sagittal and (b) axial views.

Table 1: Summary of cases reported.

Findings	A ^[7]	B ^[2]	C ^[6]
Age/Gender	89/M	40/F	40/M
Symptoms	Severe myelopathy/Paraparesis	Severe myelopathy/Paraparesis	Severe myelopathy/Quadriparesis
Imaging	CT Myelogram: T9-T10 Tumor surrounding the spinal cord	MR: T6-T7 Tumor surrounding the spinal cord	MR: C1-C4 Tumor surrounding the spinal cord
Tumor level	T9-T10	T6-T7	C1-C4
Treatment	T9-T10 laminectomy Complete excision	T6-T8 laminectomy Subtotal resection	C1-C4 laminectomy Partial resection Postop radiotherapy
Postop studies	No MR available	MR: subtotal resection with residual ventral tumor	MR: subtotal resection with residual ventral tumor
Prognosis	3 months, no residual paraparesis	6 months, no residual paraparesis	Quadriplegia present

DISCUSSION

Meningiomas are the most common primary tumors of the spine and are typically intradural extramedullary in location (100% in 25 patients; study by Gottfried, *et al.*). Approximately 83–94% are intradural, 5–14% have an extradural component, and 3–9% are completely extradural. They have a predilection for thoracic spine (67–84% thoracic meningiomas; Gottfried *et al.*).^[3,6] Although 90% are benign, 10% may undergo malignant degeneration (WHO Grade III are the malignant ones).^[4]

Meningiomas are frequently found in middle aged female (female:male ratio between 3 and 4. 2:1; mean age range 49–62 years) and the most common location of tumor in female is thoracic as evidenced in the study by Gottfried *et al.* and Levy *et al.*, respectively. Most tumors are located posterior/lateral to the spinal cord, with fewer found anteriorly.^[3,6]

En-Plaque circumferential meningiomas are extremely rare. The posterolateral portions of tumor are typically accessible for resection, while the anterior segment may have to be left behind to avoid damaging the anterior spinal artery. There is a high probability of recurrence with incomplete resection.^[2,5,7] A review of the literature revealed three similar cases of circumferential meningiomas; one cervical and two thoracic [Table 1].

Diagnostic studies and surgery for circumferential meningiomas

MR images with/without contrast, including those for circumferential en plaque lesions, are characteristically hypointense to isointense on T1, and isointense to hyperintense on T2, and homogeneously enhance. Surgery is the mainstay of treatment while lately gamma knife or cyber knife therapy is also recommended with variable success.^[5]

Surgery can be done through the anterior and/or posterior approach. These tumors are typically adherent to the

cord which makes surgery technically difficult and risk of spinal cord injury, high. Intraoperative neurophysiology is recommended.

In this patient, the ventral part of tumor was left behind during the first surgery to avoid injury to the anterior spinal artery and limit the potential for neurological injury. As evidenced in the literature, 5 years later, the patient again presented with myelopathy, the repeat MR scans confirmed tumor recurrence with cord compression. Although the posterolateral portion of tumor could again be removed, the ventral portion had to be partially left behind.

CONCLUSION

Circumferential en plaque meningiomas are rare; resection of the ventral tumor is complex and is occasionally avoided to protect the anterior spinal artery. This residual anterior disease typically recurs over a 5-year postoperative interval.

Declaration of patient consent

Patient's consent not required as patients identity is not disclosed or compromised.

Financial support and sponsorship

Nil.

Conflicts of interest

There are no conflicts of interest.

REFERENCES

1. Chamberlain MC, Blumenthal DT. Intracranial meningiomas: Diagnosis and treatment. *Expert Rev Neurother* 2004;4:641-8.
2. Foster M, Soh C, DuPlessis D, Karabatsou K. Circumferential intradural meningioma of the thoracic spinal cord. *Spine J* 2016;16:e479-83.
3. Gottfried ON, Gluf W, Quinones-Hinojosa A, Kan P,

- Schmidt MH. Spinal meningiomas: Surgical management and outcome. *Neurosurg Focus* 2003;14:1-7.
4. Harter PN, Braun Y, Plate KH. Classification of meningiomas—advances and controversies. *Chin Clin Oncol* 2017;6:S2.
 5. Singh BR, Agrawal A. En-plaque meningioma completely encircling the cervical cord: Case report. *Iran J Radiol* 2009;6:159-61.
 6. Tsai EC, Butler J, Benzel EC. In: Lee JH, editor. *Spinal Meningiomas*. London: Springer; 2009. p. 529-39.
 7. Vergara P. Is the complete excision of circumferential intradural spinal meningiomas achievable? *Acta Neurochir* 2017;159:2385-8.

How to cite this article: Bisht S, Laurente R, George KJ. Circumferential intradural meningioma of the thoracic spine: Case report and literature review. *Surg Neurol Int* 2021;12:120.