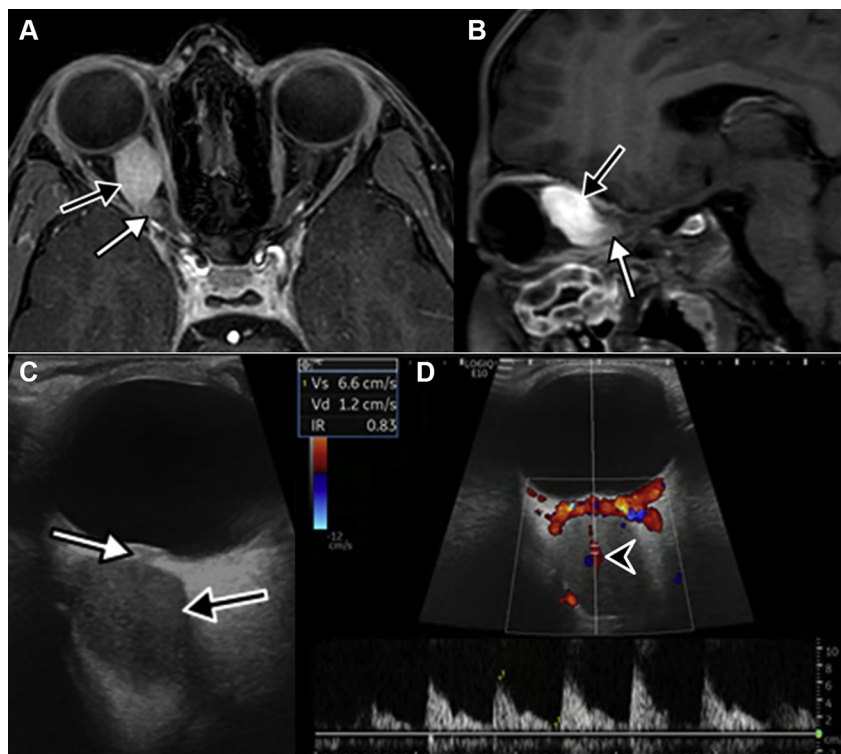


- on evaluation of glaucoma progression. *Ophthalmology*. 2013;120(12):2485–2492.
34. Medeiros FA, Sample PA, Zangwill LM, et al. A statistical approach to the evaluation of covariate effects on the receiver operating characteristic curves of diagnostic tests in glaucoma. *Invest Ophthalmol Vis Sci*. 2006;47(6):2520–2527.
 35. Bland JM, Altman DG. Measurement error. *BMJ*. 1996;312(7047):1654.
 36. Vianna JR, Danthurebandara VM, Sharpe GP, et al. Importance of normal aging in estimating the rate of glaucomatous neuroretinal rim and retinal nerve fiber layer loss. *Ophthalmology*. 2015;122(12):2392–2398.
 37. Saunders LJ, Medeiros FA, Weinreb RN, Zangwill LM. What rates of glaucoma progression are clinically significant? *Expert Rev Ophthalmol*. 2016;11(3):227–234.
 38. Kuang TM, Zhang C, Zangwill LM, et al. Estimating lead time gained by optical coherence tomography in detecting glaucoma before development of visual field defects. *Ophthalmology*. 2015;122(10):2002–2009.
 39. Medeiros FA, Gracitelli CP, Boer ER, et al. Longitudinal changes in quality of life and rates of progressive visual field loss in glaucoma patients. *Ophthalmology*. 2015;122(2):293–301.
 40. Centers for Disease Control and Prevention (CDC). Using telehealth to expand access to essential health services during the COVID-19 pandemic. <https://www.cdc.gov/coronavirus/2019-ncov/hcp/telehealth.html>; 2020. Accessed 25.06.20.
 41. Fortune B, Reynaud J, Cull G, et al. The effect of age on optic nerve axon counts, SDOCT scan quality, and peripapillary retinal nerve fiber layer thickness measurements in Rhesus monkeys. *Transl Vis Sci Technol*. 2014;3(3):2.

Pictures & Perspectives



Color-doppler Flow Imaging Might Help Diagnose Optic Nerve Glioma

A 10-year-old patient presented with painless progressive loss of vision in the right eye. Magnetic resonance imaging and ultrasound (Fig A–B) showed a right serpiginous orbital mass (*black arrow*) in continuity with the optic nerve at both ends (*white arrow*). Color-doppler flow imaging (CDFI, Fig C) revealed that the central retinal artery (Fig D, *black arrowhead*) was at the center of the mass, strongly suggesting the diagnosis of optic nerve glioma (ONG). Optic nerve tumors are challenging to biopsy, and imaging remains nonspecific. However, final diagnosis at this stage remains presumptive. Larger studies should be performed to evaluate if this CDFI sign could be sufficient in diagnosing ONG (Magnified version of Fig A–D is available online at www.aaojournal.org).

GÉRALDINE CHOTARD, MD¹

EDGARD FARAH, MD¹

AUGUSTIN LECLER, MD, PhD²

¹Department of Oculoplastics, Foundation Adolphe de Rothschild Hospital, Paris, France; ²Department of Neuro-Radiology, Foundation Adolphe de Rothschild Hospital, Paris, France