



Case Report

Chemotherapy-induced changes in tumor consistency can allow gross total resection of previously unresectable brainstem pilocytic astrocytoma

Douglas J. Chung¹, Bilal Arif², Yazmin Odia³, Vitaly Siomin⁴

Departments of ¹Neurological Surgery, ²Radiology, FIU Herbert Wertheim College of Medicine, ³Department of Neuro-Oncology, ⁴Department of Neurological Surgery, Miami Neuroscience Institute, Miami Cancer Institute, Miami, Florida, United States.

E-mail: *Douglas J. Chung - dchun011@fiu.edu; Bilal Arif - barif001@fiu.edu; Yazmin Odia - yazmino@baptisthealth.net; Vitaly Siomin - vitalys@baptisthealth.net



*Corresponding Author:

Douglas J. Chung,
Department of Neurological
Surgery, FIU Herbert Wertheim
College of Medicine, Miami,
Florida, United States.

dchun011@fiu.edu

Received : 30 August 2020
Accepted : 24 December 2020
Published : 13 January 2021

DOI
10.25259/SNI_594_2020

Quick Response Code:



ABSTRACT

Background: Low-grade gliomas (LGG) are described by the World Health Organization as Grades I and II. Among LGGs, the most common primary brain tumor is pilocytic astrocytoma (PA) and carries an excellent prognosis when treated with complete surgical resection. Cases, in which this is not possible, are associated with less favorable outcomes and worse progression-free survival.

Case Description: This report describes a case of a 22-year-old male, who presented with progression of a primary brainstem tumor previously treated with stereotactic radiosurgery and chemotherapy. Patient underwent surgical exploration and was diagnosed with juvenile PA, but debulking was limited by the very dense and fibrous tumor. Complete surgical resection was not possible at this time. Despite efforts to treat with chemotherapy, the patient presented a year later with clinical deterioration and severe neurologic deficits, prompting surgical re-exploration. During the second operation, the tumor was found to have undergone very significant softening in consistency, allowing for gross total resection (GTR)

Conclusion: Aggressive treatment of brainstem LGG should be pursued whenever possible, given its generally favorable prognosis. Repeat microsurgical resection, even with a different approach, might be reasonable and safe. Finally, chemotherapy may be associated with changes in the tumor consistency that can render previously unresectable lesions amenable to successful aggressive resection.

Keywords: Brainstem low-grade glioma, Chemotherapy, Gross total resection, Pilocytic astrocytoma, Tumor consistency

INTRODUCTION

Low-grade gliomas (LGG) have been described according to the World Health Organization (WHO), as Grades I and II.^[7] Among these LGGs, the most common primary brain tumor is PA, accounting for 5.1% of all primary brain and central nervous system gliomas, and are described as relatively benign Grade I neoplasms.^[7,9] It is the most prevalent primary brain tumor among children age 0–19 years, representing 15.3% of all cases.^[9] Among children age 0–14 years, PAs have an annual age-adjusted incidence rate of 1.01 (per 100,000) that significantly decreases (0.28/100,000) in adolescents and young adults (age 15–30 years).^[9] PAs in children

This is an open-access article distributed under the terms of the Creative Commons Attribution-Non Commercial-Share Alike 4.0 License, which allows others to remix, tweak, and build upon the work non-commercially, as long as the author is credited and the new creations are licensed under the identical terms.

©2020 Published by Scientific Scholar on behalf of Surgical Neurology International

most commonly occur in the cerebellum, optic pathway/hypothalamic region, and supratentorial hemispheres but less frequently may occur in the brainstem and spinal cord.^[2] PAs commonly arise sporadically but there is an increased risk occurrence in the optic pathway in patients with neurofibromatosis Type 1.^[3]

PAs are typically well-defined tumors with cystic formation occurring within the tumor or around the tumor with associated solid nodule.^[3] Histopathologically, PAs demonstrate a biphasic growth pattern with areas of highly fibrillated cells mixed with loose microcystic component accompanied by Rosenthal fibers and eosinophilic granular bodies.^[3] Microvascular proliferation is common but does not indicate malignancy like in diffuse high-grade gliomas.^[3] Recently, genetic alterations in the mitogen-activated protein kinase pathway of PAs have been described in literature with the most common alteration being a fusion between KIAA1549 and BRAF.^[3]

While PAs are considered to have an excellent prognosis with overall 10-year survival reported over 90%, tumors where complete surgical resection is unable to be carried out have less favorable progression-free survival (PFS) and overall survival.^[3,9] Primary treatment of these tumors is surgery, but radiotherapy and chemotherapy may be indicated in cases with incomplete resection or contraindication to surgery.^[3] Among reported brainstem LGGs treated with surgical resection or chemotherapy, there is a clear positive correlation with extent of surgical resection and PFS [Table 1].

For example, Ahmed *et al.* describes 21 patients who received gross total resection (GTR) or subtotal resection (STR) with 5-year overall survival of 85%, while Klimo *et al.* reported 9 patients who received GTR with 5-year PFS at 75%.^[1, 6]

However, the repeat microsurgical resection of partially resected tumors that have been treated with chemotherapy resulting in gross total resection (GTR) has not been previously reported. Here, we present a case of a 22-year-old male with an initially unresectable brainstem LGG treated with vincristine and carboplatin, subsequently undergoing changes in consistency allowing for GTR on repeat surgery.

CASE PRESENTATION

History

On March 2015, a 22-year-old right-handed male with a 2 month history of right sided weakness and numbness was diagnosed with a primary brainstem tumor on MRI. He was empirically treated with temozolomide, bevacizumab, and stereotactic radiosurgery (SRS). Six months later, while stable disease was noted on brain MRI, the patient was also treated with an additional hypo-fractionated course (~50Gy in 25 fractions over 2 months) of involved field radiation.

Patient received empiric chemotherapy and radiation therapy for 21 months and follow-up brain MRI on December 2016 revealed a stable, necrotic left midbrain mass lesion

Table 1: Summary of previously reported brainstem low-grade glioma managed with surgical resection or chemotherapy.

Citation	Patient Age	Surgical Resection	Chemotherapy	Outcomes
Upadhyaya <i>et al.</i> , 2017	25 patients (median age 6 years old)	GTR: 4 patients NTR or less: 21 patients	Adjuvant therapy: 10 patients	GTR: 10 year PFS at 100% (4/4) Entire cohort: 10 year PFS at 71%
Ronghe <i>et al.</i> , 2010	16 patients (median age 4.2 years old)	Partial or STR: 14 patients	Vincristine and Carboplatin: 16 patients	Median follow-up of 57 months PFS at 68.75% (11/16)
Kestle <i>et al.</i> , 2004	28 patients (median age 7.8 years old)	GTR or resection with linear enhancement: 12 patients Solid residual tumor or biopsy: 16 patients	Adjuvant therapy: 2 patients	GTR or resection with linear enhancement: 5 year PFS at 74% Solid residual tumor or biopsy: 5 year PFS at 19%
Lundar <i>et al.</i> , 2014	15 patients (median age 6 years old)	Primary tumor resection: 15 patients Repeat resection: 6 patients	Adjuvant therapy: 4 patients	Median follow up of 8 years with 80% survival rate (12/15)
Ahmed <i>et al.</i> , 2014 ^[1]	48 patients (median age 12 years old)	GTR: 4 patients STR: 17 patients Biopsy: 27 patients	Procarbazine, Lomustine, and Vincristine: 6 patients Post-operative radiotherapy: 29 patients	Median follow-up of 6 years GTR or STR: 5-year overall survival 85% Biopsy: 5-year overall survival 50% Entire cohort: 5-year overall survival 67%
Klimo <i>et al.</i> , 2013 ^[6]	52 patients (median age 6.5 years old)	GTR: 9 patients NTR: 17 patients STR: 9 patients Biopsy: 17 patients	Adjuvant chemo and radiotherapy: 27 patients	GTR: 5-year PFS at 75% NTR: 5-year PFS at 25.7% STR: 5-year PFS at 33.3% Entire cohort: 5-year overall survival 98%

GTR: Gross total resection, PFS: Progression-free survival, NTR: Near total resection, STR: Subtotal resection

measuring $2.5 \times 2.1 \times 1.8$ cm with subacute hemorrhage in the inferior posterior margin [Figure 1].

Nearly 2 years after the initial diagnosis, the patient presented to the clinic with progressively worsening gait instability and left greater than right weakness. Additional symptoms included transient confusion with malaise and dizziness. Brain MRI at this time revealed progression at medial and inferior margins along with interval mild ventriculomegaly consistent with obstructive hydrocephalus [Figure 2]. Decision was made to place the shunt and resect the tumor in a two-stage procedure during the same admission.

First operation – VP shunt placement and partial tumor resection/biopsy

The patient underwent an uneventful right occipital ventriculoperitoneal shunt placement with utilization of volumetric image guidance and laparoscopic assistance.

The following day, left posterior temporal-occipital craniotomy was performed with an intention to obtain tissue for diagnosis and remove as much of the brainstem tumor as safely as possible. Volumetric image guidance, microscope, neuro-monitoring, and intraoperative MRI were utilized. The brainstem lesion was approached through the posterior temporal-occipital supratentorial plane with sectioning of the tentorium to widen the exposure. The inferior posterior temporal gyrus was partially resected, allowing mobilization and preservation of the vein of Labbe. The midbrain was entered through the lateral mesencephalic safe entry zone. The tumor itself was very firm and moderately vascular. Usual microsurgical tools, including ultrasonic aspirator, were inefficient.

The tumor's firm consistency did not allow us to remove much of the lesion. The outer portions of the mass were very fibrous and could not be mobilized. Progress was very slow. The remaining tumor was "hard as a rock" in consistency, and surgical manipulation would move it as a

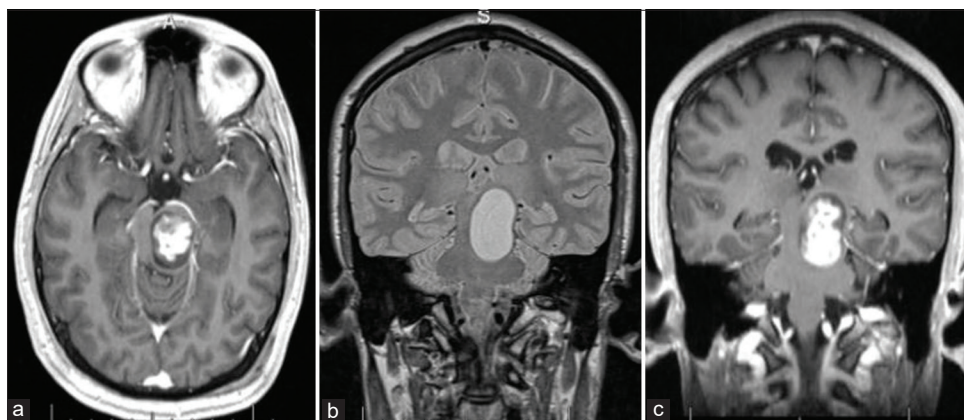


Figure 1: Initial brain MRI: (a) Axial T1 image with contrast; (b) coronal FLAIR and (c) coronal T1 with contrast images, showing large left midbrain-pontine lesion at the time of stereotactic radiosurgery.

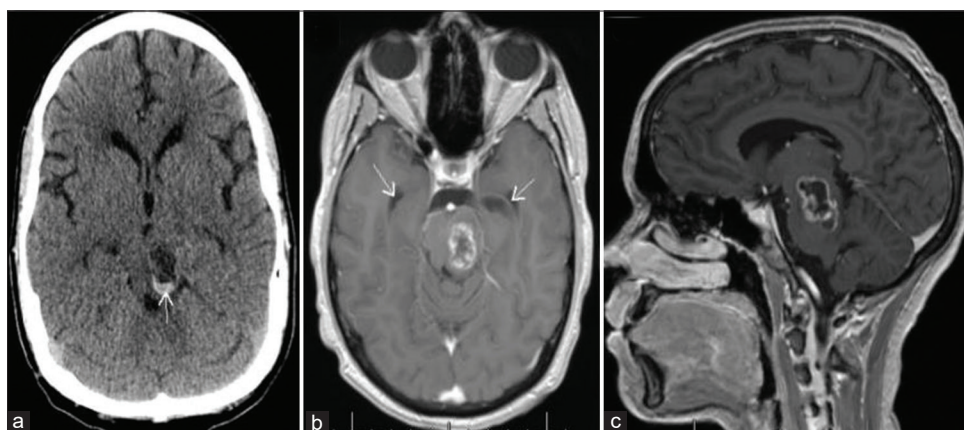


Figure 2: Two years after stereotactic radiosurgery and first round of chemotherapy: (a) Brain CT showing hemorrhage in the dorsal aspect of the tumor. Brain MRI with contrast: (b) Axial T1 image demonstrating the lesion in the left brainstem and prominent temporal horns (arrows), suggestive of an obstructive hydrocephalus; (c) sagittal T1 image showing ring-enhancing mass.

single block, distorting the entire brainstem. Considering the circumstances, it was felt that the safest choice would be to stop further dissection/tumor removal. Intraoperative MRI showed an approximately 40% decrease in tumor volume, but the peripherally enhancing capsule of the tumor remained unchanged, as expected given the consistency of the tumor encountered intraoperatively [Figure 3].

Pathology and postoperative course

Final pathology confirmed PA, negative for BRAF mutation or rearrangement, and the patient was started on combination therapy with carboplatin and vincristine. Unfortunately, chemotherapy was complicated with breakthrough seizures and brain MRI revealed symptomatic interval progression of the left midbrain tumor. Carboplatin and vincristine were discontinued, and seizures controlled with levetiracetam, gabapentin, and valproic acid. The patient was subsequently started on a 3 day monthly cycle of cisplatin and etoposide.

On May 2018, 14 months after the first operation, the patient presented to the emergency department for worsening headache, double vision, right-sided weakness, and gait ataxia. Clinically, he was noted to have significant right upper extremity

weakness to 1–2/5, hypophonia, and rapidly progressing functional decline. Brain CT showed known mass extending from the brainstem to the thalamus, slightly eccentric on the left. A hemorrhagic component within the mass and slight increase in size of the tumor was noted as well [Figure 4].

Second operation

The patient underwent suboccipital-torcular craniotomy with utilization of volumetric image guidance, microscope, and neuromonitoring. The lesion was approached through the supracerebellar infratentorial corridor through the infracollicular safe entry zone. Initially, the cystic portion was decompressed and motor oil-like fluid evacuated. The cyst walls collapsed and the brainstem relaxed. The solid portion of the tumor in the middle of the caudal midbrain and upper pons was considerably softer than in the first surgery, but more vascular with areas of hemorrhagic transformation. This

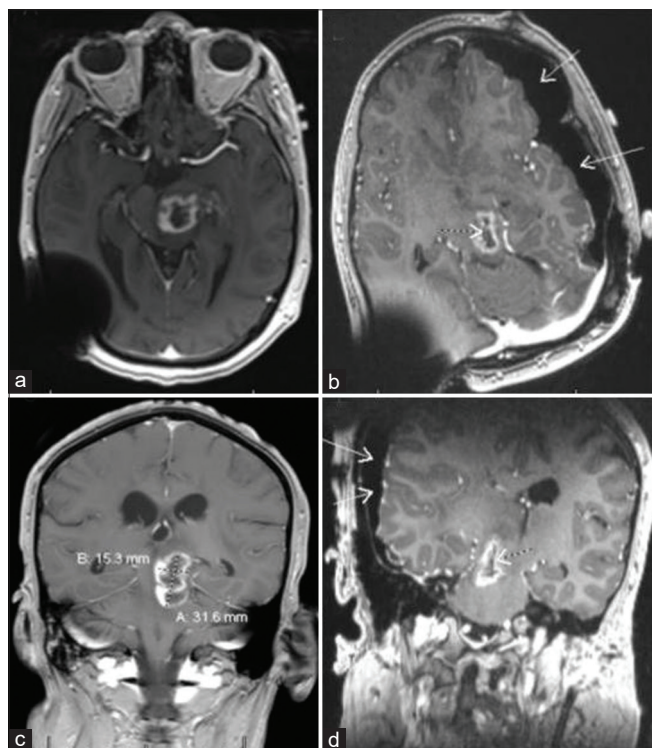


Figure 3: MRI images with contrast: (a) Immediate preoperative axial T1 views; (b) intraoperative Axial T1 views demonstrate an approximate 40% resection of the lesion (dotted arrow) and expected intraoperative pneumocephalus (solid arrows); (c) immediate preoperative coronal T1 views; (d) intraoperative coronal T1 views.

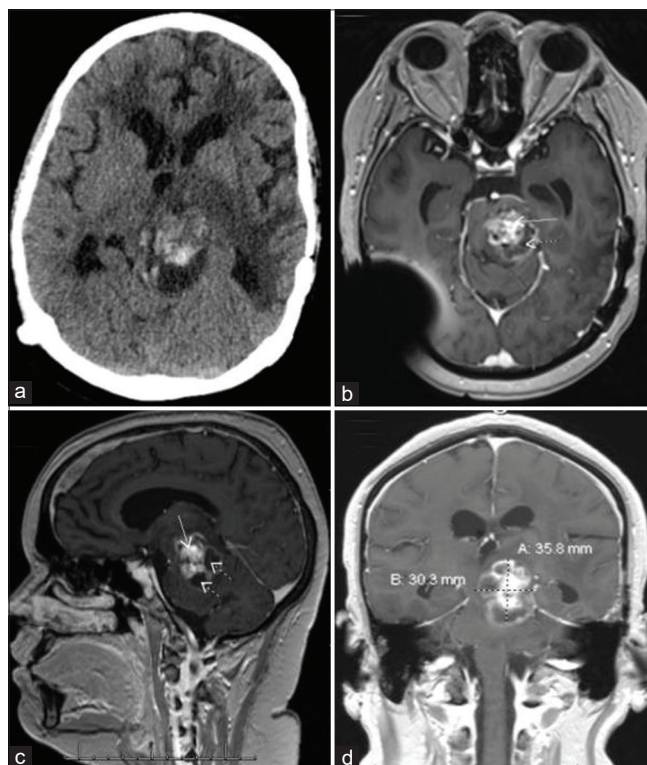


Figure 4: Four months after partial resection and shunting; (a) non-contrast brain CT shows hemorrhagic component mostly in the posterior aspect of the tumor; (b) axial, (c) sagittal, and (d) coronal T1 MRI views with contrast, showing significant interval tumor enlargement with solid (solid arrows) and cystic (dotted arrows) components. At this point in the patient's care, it was felt, he did not have many options left. He appeared to have either poorly tolerated, or did not respond to, chemotherapy. After two prior radiation treatments, he was ineligible for further radiation. Therefore, a multi-disciplinary decision was made to repeat neurosurgical intervention in an attempt to decompress the cyst and remove some more tumor, if feasible.

tumor was successfully mobilized and grossly resected with what appeared to be normal appearing brainstem underneath.

Postoperative brain MRI demonstrated GTR and marked decompression of the brainstem. Pathology confirmed mainly necrosis and hemorrhage with focal residual PA with little/no proliferation and Ki-67 in MID1 proliferation indices [Figure 5].

Postoperative complications

Five days after surgery, the patient experienced increased somnolence. Head CT revealed new bilateral parieto-occipital subdural and epidural retrocerebellar hemorrhage. The parieto-occipital convexity hemorrhages were likely related to intra- and postoperative brain shift and tearing of the bridging veins. Although supratentorial hematomas were not felt to require surgical intervention, the retrocerebellar hemorrhage was more significant. The patient was subsequently taken up for emergent re-opening of the torcular-suboccipital craniotomy for evacuation of the epidural hematoma. Postoperative CT revealed successful evacuation of the extra-axial hematoma.

Three months after surgery, follow-up brain MRI demonstrated evolving postoperative changes with no residual/recurrent tumor.

Twelve months after surgery, the patient's dysarthria improved. Motor exam revealed persistent right hemiparesis (improved to 3–4/5), arm weaker than the leg. Patient was now able to stand and walk short distances with assistance. Chronic steroids have been successfully weaned off, and the patient had a complete reversal of cushingoid appearance.

DISCUSSION

LGG have been described according to the WHO, as Grades I and II.^[7] Among these LGGs, the most common primary brain tumor is PA described as a relatively benign Grade I

neoplasm.^[7] The most common clinical presentation of brainstem PA is a focal neurological deficit of cranial nerves corresponding to the anatomical location of the tumor with or without involvement of the motor/sensory long tracts.^[2] Additional symptoms of hydrocephalus and headache may be present as well.^[2] While PAs are considered to have an excellent prognosis with overall 10-year survival reported over 90%, tumors where complete surgical resection is unable to be carried out have less favorable PFS and overall survival.^[3,9] In addition, brainstem PA is complicated with significant neurological morbidity secondary to their location.^[11]

The gold standard for approaching pediatric brainstem LGGs is initial treatment with safe maximal surgical resection, in conjunction with chemotherapy and radiation therapy as needed.^[11] Upadhyaya *et al.* studied 25 cases of pediatric non tectal brainstem LGGs treated with surgical resection. All three patients with GTR and histological diagnosis of PA demonstrated no evidence of disease at long-term follow-up.^[11] Overall, the study found a 10-year PFS rate of 71% in these 25 patients, of which 16 were cases of brainstem PA.^[11]

Kestle *et al.*'s study investigated 28 cases of pediatric brainstem PA, of which 25 were treated with neurosurgical resection.^[5] Kestle *et al.*'s study found a direct correlation between extent of tumor resection and long-term survival.^[5] Twelve patients had postoperative imaging demonstrating GTR or linear enhancement, with a 10-year PFS of 62%. In contrast, the 13 patients with postoperative scans revealing residual solid tumor only had a 10-year PFE of 19%.^[5] While patients with GTR saw long-term PFS, surgical resection was often associated with neurological dysfunction most apparent in the immediate postoperative phase.^[5] This deficit typically resolved but persisted in 6 of the 28 patients.^[5]

While GTR of brainstem PA clearly leads to favorable outcomes, adjuvant or neoadjuvant radiation therapy may also be used in the management of these tumors. Gagliardi

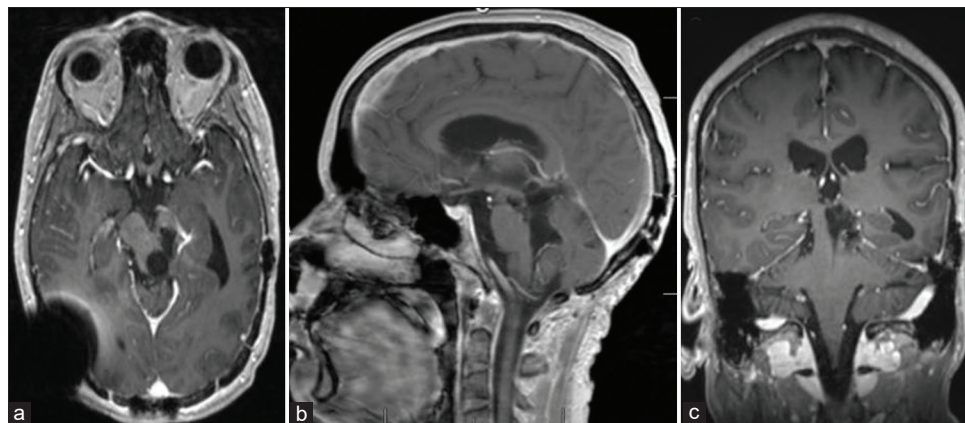


Figure 5: Postoperative brain MRI: (a) Axial T1 image; (b) sagittal T1 image; and (c) coronal T1 image, demonstrating postsurgical changes after GTR of the left dorsal midbrain-pontine tumor.

et al. investigated the use of radiotherapy for LGGs in 39 patients.^[4] Of these, four solid lesions converted into mixed tumors following GKRS.^[4] In addition, tumor progression was followed in patients and found cyst progression occurred more commonly in patients with a mixed lesion at the time of radiation therapy.^[4] Four of five reported incidents of cyst progression were found to be PA.^[4] Overall, this study found a 10-year PFS rate of 39.1% in those treated with Gamma Knife Radiosurgery.^[4]

The patient in this case report was not offered surgery as the first line of treatment. Instead, he was treated with SRS, another hypofractionated course of radiotherapy, and chemotherapy. It is conceivable that the tumor could acquire its very firm consistency as a consequence of these treatments. Hardening of the tumor due to radiation therapy is a well described phenomenon.^[10] Multiple authors reported surgical challenges associated with resection of previously irradiated tumors. Changes in the tumor consistency might be related to the development of fibrosis within the tumor and excessive perifocal scarring. Such changes were noted during the first surgery. However, the second round of chemotherapy with carboplatin and vincristine, along with another cycle with cisplatin and etoposide, was associated with considerable softening of the tumor and its partial hemorrhagic transformation that allowed for gross resection. This phenomenon has not been previously described in the literature. It could be also suggested that between [Figures 3 and 4], a newly enhancing tissue (best seen on the axial and coronal MR images) may represent a growth of radiotherapy-naïve tumor, which was softer and thus, more amenable to surgical resection. This hypothesis can be true only if the surgeons did not leave behind a considerable amount of solid tissue after the first surgical procedure, which was not the case. In addition, the tumor, new or old, could outgrow its blood supply and undergo necrotic transformation, which could also be influenced by chemotherapy. It is important to note, though, that the new radiotherapy-naïve component was exposed to chemotherapy, much like the hard tumor treated with XRT. At this point, we can only speculate about the extent to which the above potential mechanisms could have contributed to the apparent softening of the mass. Although not unequivocally proving the exact causality, the facts that remain clear are (1) very hard consistency of the tumor discovered on the first surgery and (2) a quite significant softening of previously unresectable lesion after chemotherapy. Therefore, the authors believe that chemotherapy could have contributed to the success of the second surgery.

We did not find any reports of repeat surgical interventions on adult patients with brainstem LGG. One study reported 12 pediatric patients with midbrain LGG who were treated with multiple repeat tumor resections due to disease progression with seemingly stable long-term results obtained in at least

nine patients.^[8] The surgeons treating brainstem LGG should be aware of possibility of chemotherapy induced tumor softening phenomenon and be prepared to offer repeat surgery, even if the lesion was initially deemed unresectable.

CONCLUSION

Aggressive treatment of brainstem LGG should be pursued whenever possible, given its generally favorable prognosis. Repeat microsurgical resection, even with a different approach, might be reasonable and safe. Finally, chemotherapy may be associated with changes in the tumor consistency that can render previously unresectable lesions amenable to successful aggressive resection.

Declaration of patient consent

The authors certify that they have obtained all appropriate patient consent.

Financial support and sponsorship

Nil.

Conflicts of interest

There are no conflicts of interest.

REFERENCES

1. Ahmed KA, Laack NN, Eckel LJ, Orme NM, Wetjen NM. Histologically proven, low-grade brainstem gliomas in children 30-year experience with long-term follow-up at mayo clinic. *Am J Clin Oncol* 2014;37:51-6.
2. Burkhard C, di Patre PL, Schüler D, Schüler G, Yaşargil NG, Yonekawa Y, *et al.* A population-based study of the incidence and survival rates in patients with pilocytic astrocytoma. *J Neurosurg* 2003;98:1170-4.
3. Collins VP, Jones DT, Giannini C. Pilocytic astrocytoma: Pathology, molecular mechanisms and markers. *Acta Neuropathol* 2015;129:775-88.
4. Gagliardi F, Bailo M, Spina A, Donofrio CA, Boari N, Franzin A, *et al.* Gamma knife radiosurgery for low-grade gliomas: Clinical results at long-term follow-up of tumor control and patients quality of life. *World Neurosurg* 2017;101:540-53.
5. Kestle J, Townsend JJ, Brockmeyer DL, Walker M. Juvenile pilocytic astrocytoma of the brainstem in children. *J Neurosurg* 2004;101 Suppl 1:1-6.
6. Klimo P, Panandiker AS, Thompson CJ, Boop FA, Qaddoumi I, Gajjar A, *et al.* Management and outcome of focal low-grade brainstem tumors in pediatric patients: The St. Jude experience. *J Neurosurg Pediatr* 2013;11:274-81.
7. Louis DN, Perry A, Reifenberger G, von Deimling A, Figarella-Branger D, Cavenee WK, *et al.* The 2016 World Health Organization classification of tumors of the central nervous system: A summary. *Acta Neuropathol* 2016;131:803-20.

8. Lundar T, Due-Tonnessen BJ, Egge A, Scheie D, Brandal P, Stensvold E, *et al.* Neurosurgical treatment of pediatric low-grade midbrain tumors: A single consecutive institutional series of 15 patients. *J Neurosurg Pediatr* 2014;14:598-603.
9. Ostrom QT, Gittleman H, Truitt G, Boscia A, Kruchko C, Barnholtz-Sloan JS. CBTRUS statistical report: Primary brain and other central nervous system tumors diagnosed in the United States in 2011-2015. *Neuro Oncol* 2018;20 Suppl 4:iv1-86.
10. Stubblefield MD. Radiation fibrosis syndrome: Neuromuscular and musculoskeletal complications in cancer survivors. *PM R* 2011;3:1041-54.
11. Upadhyaya SA, Koschmann C, Muraszko K, Venneti S, Garton HJ, Hamstra DA, *et al.* Brainstem low-grade gliomas in children-excellent outcomes with multimodality therapy. *J Child Neurol* 2016;32:194-203.

How to cite this article: Chung DJ, Arif B, Odia Y, Siomin V. Chemotherapy-induced changes in tumor consistency can allow gross total resection of previously unresectable brainstem pilocytic astrocytoma. *Surg Neurol Int* 2021;12:12.