

Cranial and Spinal Oligodendrogliomatosis: A Case Report and Review of the Literature

Abstract

Secondary leptomeningeal gliomatosis is a condition known as a result of invasion of the subarachnoid space or the ventricular system of primary intraparenchymal glioma. In this article, we present a 7-year-old boy presented with neck and back deformity and deterioration of gait. Cranial and spinal magnetic resonance imaging revealed lesions in the supratentorial and infratentorial areas, in the brainstem downward the spinal cord. Disseminated oligodendrogliomatosis is extremely rare and our case we present is the 24th in the literature.

Keywords: *1p19q deletion, leptomeningeal dissemination, oligodendrogliomatosis*

Introduction

Primary oligodendrogliomatosis is a rare entity involving intracranial and spinal leptomeninges without parenchymal focus with a poor prognosis. Secondary oligodendrogliomatosis is the dissemination of a primary parenchymal oligodendroglioma in leptomeninges via subarachnoid space or ventricular system. Early diagnosis is important for early initiation of radiotherapy/chemotherapy that will improve the patient's quality of life and contribute to long-term surveillance. In this article, we report a 7-year-old boy presented with deformity in his back and neck and gait disturbance that magnetic resonance imaging (MRI) demonstrates multiple hyperintense small cystic lesions predominantly in the infratentorial region and an intramedullary expansile contrast-enhanced lesion extending from T5 to T7 level.

Case Report

A 7-year-old boy was evaluated with a complaint of deformity in his back and neck which was noticed 2 months ago and worsening of walking. He was neurologically intact except spasticity in both lower extremities and hyperactivity in deep tendon reflexes. Routine laboratory values were normal. MRI revealed extra-axial multiple cystic lesions in both cerebellar

hemispheres and vermis and cerebellar peduncles, in brainstem most prominently in the periaqueductal area extending to the interpeduncular cistern, and in the hippocampus and parahippocampal area, 4 mm diameter nodular lesion on the posterior wall of the fourth ventricle, communicating hydrocephalus. Cystic lesions in the posterior fossa were also observed extensively along the spinal cord at the cervical, thoracic, and lumbar levels [Figure 1]. The patient was radiologically hydrocephalic but had no symptoms due to increased intracranial pressure. In addition, in T2-weighted images heterogeneous and hyperintense and contrast enhanced in T1-weighted MRI images, an intramedullary expansile lesion was observed extending from lower T5 to lower T7 level [Figure 2]. Baclofen was administered orally 3 × 5 mg for spasticity in lower extremities with the recommendation of pediatric neurology clinic and started on prophylactic anticonvulsant therapy with levetiracetam. Informed consent was received from the family and the patient underwent T6–7 laminoplasty, biopsy from the dural lesion, and duraplasty. Intraoperative somatosensory-evoked potential changes with amplitude reduction did not allow us to go beyond biopsy and more tumor removal. There was no postoperative additional neurological deficit.

**Koral Erdogan,
Orkhan
Mammadkhanli¹,
Ihsan Dogan,
Cevriye Cansiz
Ersoz²,
Aylin Heper Okcu²,
Mustafa Agahan
Unlu**

Department of Neurosurgery, Ankara University School of Medicine, Ibn-i Sina Hospital, ¹Department of Neurosurgery, Faculty of Medicine, Yuksek Ihtisas University, ²Department of Pathology, Ankara University School of Medicine, Ankara, Turkey

Address for correspondence:
Dr. Koral Erdogan,
Ibn-i Sina Hastanesi, Hacettepe Mah., Talatpasa Blv. No: 82, Altindag, Ankara 06230, Turkey.
E-mail: koralerdogan@gmail.com

This is an open access journal, and articles are distributed under the terms of the Creative Commons Attribution-NonCommercial-ShareAlike 4.0 License, which allows others to remix, tweak, and build upon the work non-commercially, as long as appropriate credit is given and the new creations are licensed under the identical terms.

For reprints contact: WKHLRPMedknow_reprints@wolterskluwer.com

How to cite this article: Erdogan K, Mammadkhanli O, Dogan I, Ersoz CC, Okcu AH, Unlu MA. Cranial and spinal oligodendrogliomatosis: A case report and review of the literature. *Asian J Neurosurg* 2021;16:626-9.

Submitted: 28-Nov-2020 **Revised:** 22-Jan-2021
Accepted: 15-Apr-2021 **Published:** 14-Sep-2021

Access this article online

Website: www.asianjns.org

DOI: 10.4103/ajns.AJNS_514_20

Quick Response Code:



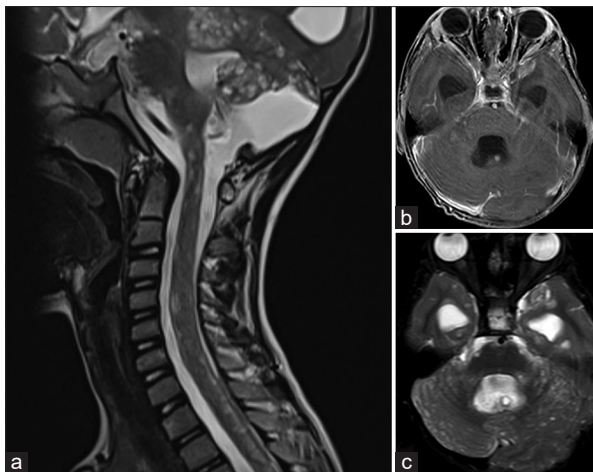


Figure 1: (a and c) T2 fluid-attenuated inversion recovery axial image shows multiple hyperintense cystic lesions in the cerebellum and cervical spine. (b) T1-weighted postcontrast image shows a nodular lesion on the posterior wall of fourth ventricle

Pathological result of the patient was reported as a diffuse leptomeningeal glioneuronal tumor [Figure 3]. The tumor cells were characterized by round-to-oval nuclei with finely granular dispersed chromatin, inconspicuous nucleoli with clear oligodendrocyte-like features with perinuclear haloes. No necrosis or endothelial vascular proliferation was observed in the tumor. Focal myxoid change and 1 mitosis per 10 HPF were detected. The neoplastic cells were diffusely immunopositive for S100 and SYNP and immunonegative for GFAP. No ATX loss was detected and IDH1 and p53 were negative. Ki67 proliferation index was 5%–7%. Fluorescence *in situ* hybridization analysis revealed deletion of 1p, whereas 19q was intact. The patient was referred to the pediatric oncology clinic for chemotherapy and radiation therapy. However, the parents preferred to take these treatments in other institutes.

Discussion

Primary diffuse leptomeningeal gliomatosis is pathologically available in two types: primary leptomeningeal astrocytoma and primary leptomeningeal oligodendroglioma. In the literature, primary oligodendrogliomatosis cases have been reported which Michotte *et al.* have compiled in their own study.^[1] Secondary oligodendrogliomatosis is the dissemination of a primary glial tumor by subarachnoid space or ventricular system. In addition to leptomeningeal lesions, intraparenchymal lesions can be seen. In this article, we present a case with cranial and fourth ventricular lesions involved the spinal cord. There are very few reported studies of secondary oligodendrogliomatosis in the literature. There were a total of 24 cases with a current patient, of which 10 were adults and 14 were children [Table 1]. Sudden death was seen in at least three of these cases.^[4,13,18] Only three patients have been reported that lived 5 years or more.^[10,11,14] Only two patients had 1p

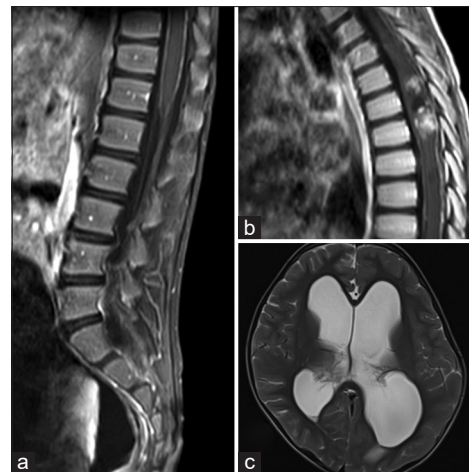


Figure 2: (a) Leptomeningeal contrast enhancement at the conus. (b) Sagittal contrast-enhanced T1-weighted image shows intramedullary lesion at T5–7 level. (c) T2 fluid-attenuated inversion recovery axial image shows hydrocephalus

19q deletion, 8 years and more of surveillance was reported in these cases, 1p deletion was observed in our case, but 19q deletion was not seen.^[1,14]

Oligodendrogliomatosis may be difficult to diagnose because it presents with progressive pial enhancement or various symptoms such as hydrocephalus and nonspecific imaging findings. Most patients with oligodendrogliomatosis present with neurological symptoms ranging from headache, nausea, and vomiting to sensory and motor disorders.^[10,13,16,17]

Since it is a rare disease, optimal treatment is controversial. To confirm the pathological diagnosis is the main purpose. Only partial resection was documented in all reported cases. In selected cases, neurosurgical intervention may be necessary for related findings such as hydrocephalus. Chemotherapy and craniospinal irradiation revealed good results. Bourne *et al.* reported stable disease after chemotherapy with cisplatin, vincristine, cyclophosphamide, and etoposide.^[15] Franceschi *et al.* recently announced the treatment with temozolomide.^[20] In general, the prognosis of this disease is poor. However, a higher quality of life has been reported following palliative treatment.

Conclusion

We reviewed the literature for oligodendrogliomatosis for treatment and management options in pediatric age that is a very rare disease that patients may present differently. We present a case who underwent surgery for a biopsy. After pathological diagnosis, chemotherapy and radiotherapy were started for the case that proven to prolong survival.

Declaration of patient consent

The authors certify that they have obtained all appropriate patient consent forms. In the form, the legal guardian has given his consent for images and other clinical information

Table 1: Review of the available literature

Patient number	Author	Age/sex	1p/19q deletion	Survival
1	Beck <i>et al.</i> ^[2]	6.5, female	NA	3 months
2		42, male	NA	3 years
3		29, male	NA	1 month
4		4, female	NA	3 months
5	Korein <i>et al.</i> ^[3]	16, male	NA	18 months
6	Best ^[4]	41, , male	NA	2 years
7		2.5, male	NA	Died during surgery
8	Pitt <i>et al.</i> ^[5]	16, male	NA	3 years
9	Rogers <i>et al.</i> ^[6]	21, male	NA	4 years and 2 months
10	Chen <i>et al.</i> ^[7]	17, female	NA	2 years 2 months
11	Ng <i>et al.</i> ^[8]	6, female	NA	2 months
12	Pradat <i>et al.</i> ^[9]	23, male	NA	117 weeks
13	Armao <i>et al.</i> ^[10]	8, male	NA	5 years
14	Gilmer-Hill <i>et al.</i> ^[11]	4, male	NA	>6 years
15	Stodberg <i>et al.</i> ^[12]	2, male	NA	NA
16	Ozkul <i>et al.</i> ^[13]	25, female	NA	Sudden death prior to biopsy
17	Guppy <i>et al.</i> ^[14]	30, female	+/+	>8 years
18	Michotte <i>et al.</i> ^[1]	61, male	+/+	Stable
19	Bourne <i>et al.</i> ^[15]	2, male	+/-	Stable
20	Chellathurai <i>et al.</i> ^[16]	2, male	-/-	3 months
21	Mathews <i>et al.</i> ^[17]	50, female	-/-	<2 months
22	Reynolds <i>et al.</i> ^[18]	37, female	-/-	Sudden death
23	Lee <i>et al.</i> ^[19]	15, male	-/-	>6 years
24	Present case	7, male	+/-	Stable

NA – Not available

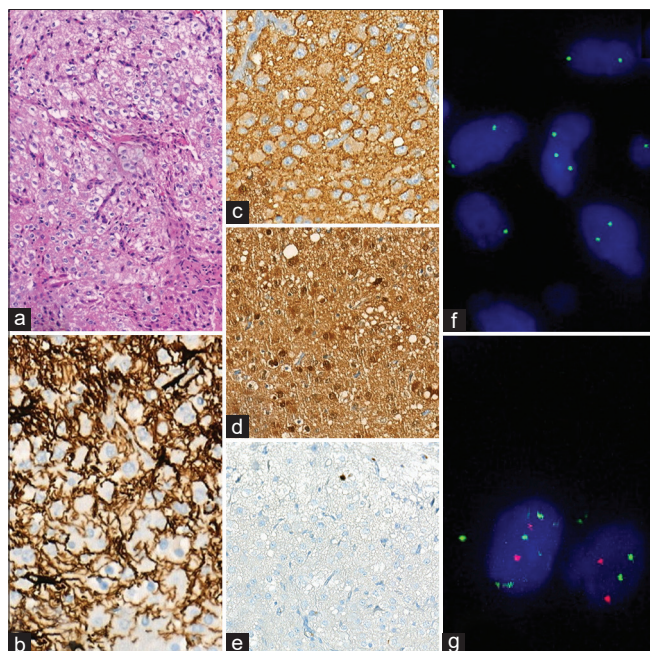


Figure 3: (a) An H and E section showed oligodendroglioma-like cytologic features with branching capillary networks. (b-d) The neoplastic cells were negative with GFAP (b); diffusely immunoreactive for synaptophysin (c); there was also strong and diffuse S100 immunopositivity (d). (e) Low proliferation activity detected by Ki67 immunostaining. (f and g) Fluorescence *in situ* hybridization analysis (f) 1p deletion of tumor cell nuclei; (g) 19q was intact

to be reported in the journal. The guardian understands that names and initials will not be published and due efforts will be made to conceal identity, but anonymity cannot be guaranteed.

Financial support and sponsorship

Nil.

Conflicts of interest

There are no conflicts of interest.

References

1. Michotte A, Chaskis C, Sadones J, Veld PI, Neyns B. Primary leptomeningeal anaplastic oligodendroglioma with a 1p36-19q13 deletion: Report of a unique case successfully treated with Temozolomide. *J Neurol Sci* 2009;287:267-70.
2. Beck DJ, Russell DS. Oligodendrogliomatosis of the cerebrospinal pathway. *Brain* 1942;65:352-72.
3. Korein J, Feigin I, Shapiro MF. Oligodendrogliomatosis with intracranial hypertension. *Neurology* 1957;7:589-94.
4. Best PV. Intracranial oligodendrogliomatosis. *J Neurol Neurosurg Psychiatry* 1963;26:249-56.
5. Pitt MA, Jones AW, Reeve RS, Cowie RA. Oligodendroglioma of the fourth ventricle with intracranial and spinal oligodendrogliomatosis: A case report. *Br J Neurosurg* 1992;6:371-4.
6. Rogers LR, Purvis JB, Lederman RJ, Rosenbloom SA, Tomsak RL, Estes ML, *et al.* Alternating sequential intracarotid

- BCNU and cisplatin in recurrent malignant glioma. *Cancer* 1991;68:15-21.
7. Chen R, Macdonald DR, Ramsay DA. Primary diffuse leptomeningeal oligodendroglioma. Case report. *J Neurosurg* 1995;83:724-8.
 8. Ng HK, Poon WS. Diffuse leptomeningeal gliomatosis with oligodendroglioma. *Pathology* 1999;31:59-63.
 9. Pradat PF, Hoang-Xuan K, Cornu P, Mokhtari K, Martin-Duverneuil N, Poisson M, *et al.* Treatment of meningeal gliomatosis. *J Neurooncol* 1999;44:163-8.
 10. Armao DM, Stone J, Castillo M, Mitchell KM, Bouldin TW, Suzuki K. Diffuse leptomeningeal oligodendrogliomatosis: Radiologic/pathologic correlation. *AJNR Am J Neuroradiol* 2000;21:1122-6.
 11. Gilmer-Hill HS, Ellis WG, Imbesi SG, Boggan JE. Spinal oligodendroglioma with gliomatosis in a child. Case report. *J Neurosurg* 2000;92:109-13.
 12. Stöbberg T, Deniz Y, Esteitie N, Jacobsson B, Mousavi-Jazi M, Dahl H, *et al.* A case of diffuse leptomeningeal oligodendrogliomatosis associated with HHV-6 variant A. *Neuropediatrics* 2002;33:266-70.
 13. Ozkul A, Meteoglu I, Tataroglu C, Akyol A. Primary diffuse leptomeningeal oligodendrogliomatosis causing sudden death. *J Neurooncol* 2007;81:75-9.
 14. Guppy KH, Akins PT, Moes GS, Prados MD. Spinal cord oligodendroglioma with 1p and 19q deletions presenting with cerebral oligodendrogliomatosis. *J Neurosurg Spine* 2009;10:557-63.
 15. Bourne TD, Mandell JW, Matsumoto JA, Jane JA Jr., Lopes MB. Primary disseminated leptomeningeal oligodendroglioma with 1p deletion. Case report. *J Neurosurg* 2006;105:465-9.
 16. Chellathurai A, Vaidya JS, Kathirvelu G, Alagappan P. Primary diffuse leptomeningeal oligodendrogliomatosis: A case report and literature review. *Indian J Radiol Imaging* 2016;26:337-41.
 17. Mathews MS, Paré LS, Kuo JV, Kim RC. Primary leptomeningeal oligodendrogliomatosis. *J Neurooncol* 2009;94:275-8.
 18. Reynolds RM, Boswell E, Hulette CM, Cummings TJ, Haglund MM, Boswell E, *et al.* Sudden death from diffuse leptomeningeal oligodendrogliomatosis. *J Neurosurg Spine* 2011;15:625-9.
 19. Lee SL, Wong A, Stadler JA 3rd, McClendon J Jr, Smith TR, Wadhvani NR, *et al.* Cranial and spinal oligodendrogliomatosis: A case report and review of the literature. *Childs Nerv Syst* 2015;31:147-53.
 20. Franceschi E, Cavallo G, Scopece L, Esposti RD, Paioli G, Paioli A, *et al.* Temozolomide-induced partial response in a patient with primary diffuse leptomeningeal gliomatosis. *J Neurooncol* 2005;73:261-4.