

A Rare Case of Third Ventricular Glioblastoma

Nadir Bir Üçüncü Ventriküler Glioblastoma Vakası

Asmira GACIC[®], Hakija BECULIC[®], Rasim SKOMORAC[®], Alma EFENDIC[®]

Ethics Committee Approval: Not Applicable.

Conflict of Interest: The authors declare that they have no conflict of interest.

Funding: None.

Informed Consent: Informed consent was taken.

Cite as: Gacic A, Beculic H, Skomorac R, Efendic A. A rare case of third ventricular glioblastoma. Medeni Med J. 2021;36:167-71.

ABSTRACT

Glioblastoma, also known as glioblastoma multiforme, is an aggressive type of cancer that is made up of abnormal astrocytic cells, but also contain a mixture of different cell types (including blood vessels) and areas of necrosis. It is often seen in the brain and spinal cord, but glioblastomas are rarely found in the third ventricle. In this case, it was diagnosed in a 22-year-old male patient and we intended to draw attention to its atypical localization and surgical access to this third ventricle glioblastoma.

Keywords: Glioblastoma, third ventricle, surgery

ÖZ

Glioblastoma multiforme olarak da bilinen glioblastoma, anormal astrositik hücrelerden oluşan agresif bir kanser türüdür, ancak aynı zamanda farklı hücre tipleri (kan damarları dahil) ve nekroz alanlarının bir karışımını da içerir. Sıklıkla beyinde ve omurilikte görülür, ancak glioblastomların nadiren bulunduğu yer üçüncü ventriküldür. Bu vakada 22 yaşında bir erkek hastaya teşhis koyuldu ve üçüncü ventrikül glioblastoma için atipik lokalizasyona ve cerrahi girişime dikkat çekmeyi amaçladık.

Anahtar kelimeler: Glioblastoma, üçüncü ventrikül, cerrahi

Received: 19 January 2021

Accepted: 30 March 2021

Online First: 18 June 2021

Corresponding Author:

A. Gacic

ORCID: 0000-0001-6501-6538

University of Zenica,

Faculty of Medicine,

Department of Anatomy,

Bosnia and Herzegovina

✉ asmirag99@gmail.com

H. Beculic

ORCID: 0000-0002-6904-2490

Cantonal Hospital Zenica,

Department of Neurosurgery,

University of Zenica,

Faculty of Medicine,

Department of Anatomy,

Bosnia and Herzegovina

R. Skomorac

ORCID: 0000-0002-7085-5720

Cantonal Hospital Zenica,

Department of Neurosurgery,

Bosnia and Herzegovina

A. Efendic

ORCID: 0000-0002-8834-2034

Cantonal Hospital Zenica,

Department of Radiology,

Bosnia and Herzegovina



INTRODUCTION

Glioblastomas are histopathologically defined by necrosis and endothelial proliferation and belong to the group of the most common and the most aggressive tumors of the central nervous system¹. Unfortunately, they are usually characterized by nonoptimistic prognoses, and poor quality of the patient's life. These tumors represent 12-15 % of intracranial neoplasms and 50-60% of astrocytic tumors². What sets this case apart is the location of the glioblastoma³. The third ventricular glioblastoma can be considered as an unusual case, considering the fact that there were only five well-described cases of this type of tumor mentioned in the literature whose location was precisely the third cerebral ventricle⁴. In this paper, we will report the treatment and access to this rare tumor detected in a 22-year-old patient.

CASE PRESENTATION

A 22-year-old male patient was admitted to the Cantonal Hospital Zenica with a diffuse type of headache and vomiting which occurred seven

days before hospitalization. A CT (Computed Tomography) scan was performed, followed by an MRI (Magnetic Resonance Imaging) of the head showing an intraaxial expansive lesion of the third ventricle and diencephalon with perifocal cerebral edema and obstructive hydrocephalus (Figure 1). Surgical treatment was indicated by examination of a neurosurgeon. The patient was medically cleared for surgery.

Anterior transcallosal approach was used for tumor resection. Surgery started with an incision of the skin in the projection of the coronary suture on the right side, which partly crossed the medial line. Then, two trepanation openings were made above the superior sagittal sinus and another two trepanation openings on the free part of the bone. These openings were joined with craniotomy, and a 7x7 cm bone flap was lifted. The dura of the skull base was incised toward a sagittal sinus and then the incision was gradually advanced in the interhemispheric route which was between falx and the right hemisphere extending to the corpus callosum. A callosotomy with a longitudinal diameter of 2 cm was performed behind the genu of corpus callosum which corresponded to the

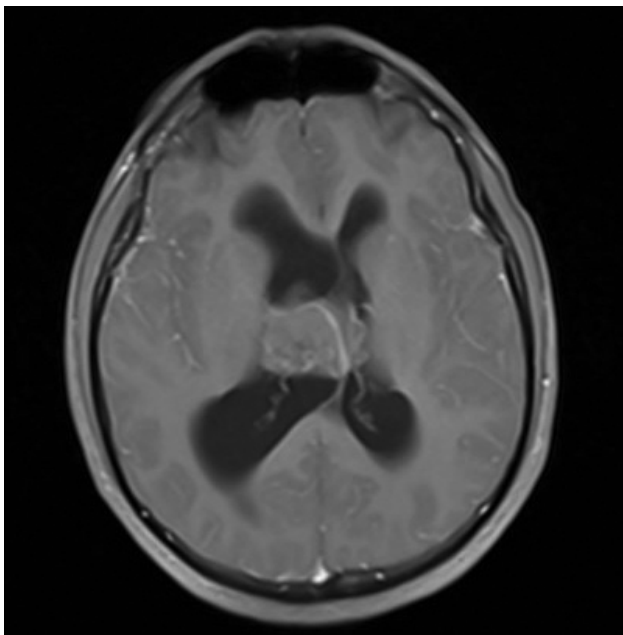


Figure 1.

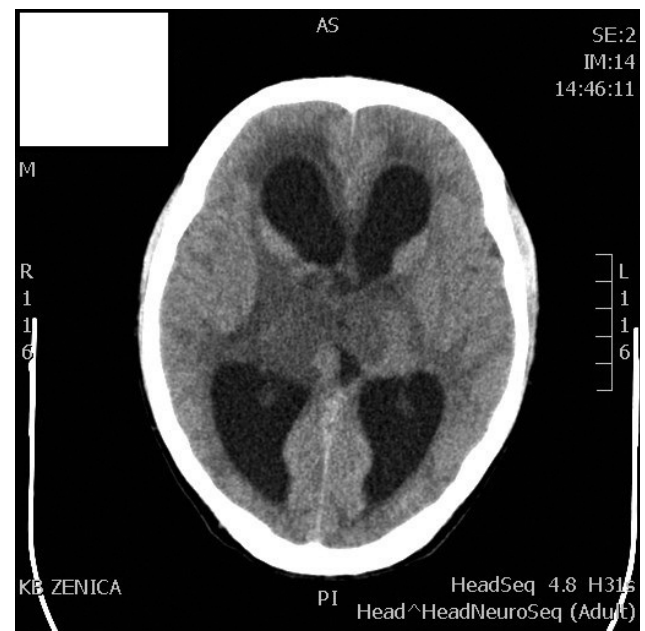


Figure 2.

entry of the right frontal horn of lateral ventricle. The cerebrospinal fluid was released under pressure; and the tumor which was clearly protruding towards the proximal direction was shown. The intervention continued with gradual resection of the gray to purple well vascularized tumor without clear borders to the surrounding tissue and with many thrombosed blood vessels (Figure 2). The transtumoral approach was used and the maximal reduction of the tumor was achieved. The floor of the third ventricle was shown distally, Sylvie's aqueduct was shown posteriorly. In the end of the procedure, hemostasis was established and a ventricular catheter, later connected to an external drainage system was placed. Surgery ended with suturing of dura mater, fixing a bone, application of epicranial drain and suturing of subcutaneous layer and the skin. Surgery was performed without any complication and the patient was stable. After surgery, the patient spent several days in the intensive care unit. Postoperative CT scan showed minimal venous infarction of the diencephalon with a smaller amount of blood in the third ventricle. Five days later, the external drainage was removed and the patient was transferred to the neurosurgery department where he was verticalized and received physical therapy. The patient was discharged 19 days after surgery without neurological deficits.

In this case, a pathohistological (PH) analysis was performed. In the PH analysis of biopsy specimens, fragments of densely cellular glial tumor made of small, medium-sized, and rarely an expressively large cells with irregular and hyperchromatic nuclei and with scarce to abundant cytoplasm were detected. Blood vessels were found in patchy areas of the tumor, and in some of them proliferation of endothelial cells was seen. Immunohistochemically, the tumor was positive for vimentin, S-100 and GFAP, and rarely large cells were positive on EMA. Tumor was neurofilament- negative and synaptophysin- negative. Morphological and immunohistoche-

mical features indicated the presence of glioblastoma multiforme.

Upon arrival of the PH findings, the patient was presented at the oncology council, where concomitant and radiation treatment and temodal chemotherapy were opted. The therapy went well. At the first check-up performed a month after the operation, the neurological findings were completely normal (Figure 3).

Despite the fact that the operation went well, four months later, patient was hospitalized again and



Figure 3.

he had the same symptoms as the first time as headache and vomiting, and also progressive deterioration of consciousness and loss of appetite. An emergency CT of the head was indicated which showed massive tumor recurrence at the site of resection with dilation of the ventricular system and signs of periventricular thinning (Figure 4). The tumor infiltrated both, the thalamus and the basal ganglia. After that, ventriculoperitoneal shunt operation was performed. Immediately after the operation, the patient felt better. He was opening eyes on call and he wasn't vomiting. He was fed via nasogastric tube, but he felt weakness in all four extremities. Seventh postoperative day, in the early hours, his consciousness suddenly deteriorated. The patient was somnolent, with high fever (40°C), hypotensive, tachypneic, euglycemic, non-performing orders. He was treated with antipyretics, and his body temperature fell down markedly (38°C). Clinical examination did not reveal the cause of sudden deterioration in his consciousness. The patient was treated with antipyretics, a broad-spectrum antibiotic, and two days after his consciousness improved.

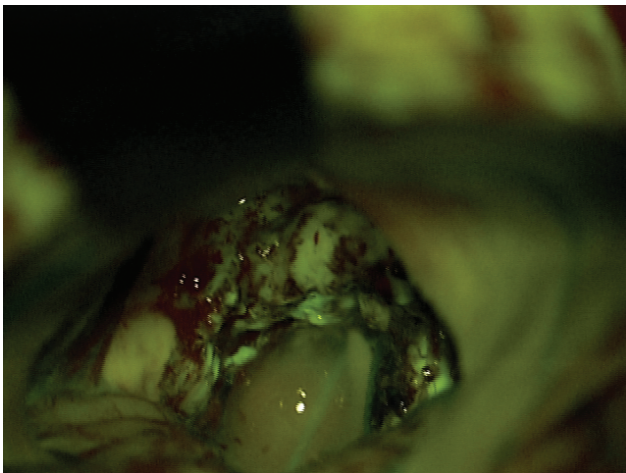


Figure 4.

On 29th January 2020, patient's consciousness deteriorated. The valve reservoir was punctured, and the cerebrospinal fluid is sent for analysis (finding was normal, without signs of neuro-

infection). Additionally, an internist and an infectologist were consulted to adjust the therapy in terms of adding antibiotic therapy, as well as attempts to regulate metabolic imbalance. The next day, due to dysphonic breathing, an anesthesiologist was consulted, and inhalation therapy with ventolin was ordered.

On 31st January, clinical deterioration occurred again in the late evening. Anesthesiologist was consulted and a control CT of the cranium was performed. Findings didn't show significant changes compared to the previous CT. The therapy recommended by the anesthesiologist was continued. Unfortunately, despite all efforts, two days later the patient's medical condition worsened, and he lost his life.

DISCUSSION

Glioblastomas are grade IV tumors and the most common primary malignant brain tumors⁵. Usually, glioblastomas occur in the brain, but they can be found in brain stem, cerebellum, and spinal cord³. Patients with glioblastomas develop symptoms such as vomiting, nausea, and severe headaches. Loss of appetite, balance difficulty, and memory problems are also common. Generally, these tumors have a dismal prognosis and the patient's quality of life deteriorates as the disease progresses⁶. Most patients lose their lives within less than one year after the diagnosis⁷.

We can certainly say that glioblastomas are the most malignant and most common brain tumors. Glioblastoma multiforme accounts for 80% of all malignant primary brain tumors, and more than 60% in all brain tumors in adults⁸. The treatment of these tumors is determined by their location and the primary treatment alternative is total resection.

Treating glioblastomas can be very difficult. However, the first step of treatment is surgical procedure to relieve pressure on the brain, and to

safely remove as much tumor as possible. Irradiation and chemotherapy are also used to slow down the growth of residual tumor after surgery and for tumors that cannot be removed with surgery.

Tumors in the third ventricle are extremely rare. Only five third ventricle glioblastoma cases were reported (Table 1), and this case report is the sixth one. For tumors in this location, surgical intervention is extremely demanding and complete resection is impossible because of its location and connection with vital structures. The treatment alternative is biopsy or tumor reduction and after that, irradiation and chemotherapy.

Atypical anatomical location is significant⁹. If the location of the glioblastoma is unusual, like the location in the third ventricle which is reported in this case, it is necessary to decide on the best possible surgical approach to the tumor. In this described situation, the neurosurgeon decided to use interhemispheric route, going between falx and the right hemisphere to the corpus callosum. After removing the mass, the neurosurgeon was able to see the floor of the third ventricle. This approach was the best route for removing as much tumor mass as possible.

One fact related to glioblastoma must not be forgotten: They may recur even if it was intensively treated and unfortunately, it is commonly fatal for the patient. Recurrent glioblastomas are more aggressive and therapy resistant¹⁰.

CONCLUSION

Magnetic resonance imaging is useful for detection of tumors in the third ventricle. To give a definitive diagnosis of glioblastoma multiforme, HP findings could be performed. Primary way of treatment is tumor resection and the best option for surgical approach to the tumor mass in the third ventricle is interhemispheric, anterior transcallosal route. Postoperative therapy includes irradiation and chemotherapy.

REFERENCES

1. Wirsching HG, Galanis E, Weller M. Glioblastoma. *Handb Clin Neurol*. 2016;134:381-97. [CrossRef]
2. Yılmaz B, Ekşi MŞ, Demir MK, et al. Isolated third ventricle glioblastoma. *Springerplus*. 2016;5:115. [CrossRef]
3. Davis ME. Glioblastoma: overview of disease and treatment. *Clin J Oncol Nurs*. 2016;20:S2-8. [CrossRef]
4. Prietoa R, Pascua JM, Roda JM. Third ventricle glioblastoma. Case report and review of literature. *Clin Neurol Neurosurg*. 2006;108:199-204. [CrossRef]
5. Omuro A, DeAngelis LM. Glioblastoma and other malignant gliomas: a clinical review. *JAMA*. 2013;310:1842-50. [CrossRef]
6. Alexander BM, Cloughesy TF. Adult glioblastoma. *J Clin Oncol*. 2017;35:2402-9. [CrossRef]
7. Parvez T. Present trend in the primary treatment of aggressive malignant glioma: glioblastoma multiforme. *Technol Cancer Res Treat*. 2008;7:241-8. [CrossRef]
8. Hanif F, Muzaffar K, Perveen K, Malhi SM, Simjee SU. Glioblastoma multiforme: a review of its epidemiology and pathogenesis through clinical presentation and treatment. *Asian Pac J Cancer Prev*. 2017;18:3-9. [CrossRef]
9. Hariri OR, Quadri SA, Farr S, et al. Third ventricular glioblastoma multiforme: case report and literature review. *J NeurolSurg Rep*. 2015;76:e227-32. [CrossRef]
10. Campos B, Olsen LR, Urup T, Poulsen HS. A comprehensive profile of recurrent glioblastoma. *Oncogene*. 2016;35:5819-25. [CrossRef]