

ORIGINAL ARTICLE

Proton re-irradiation of unresectable recurrent brain gliomas: clinical outcomes and toxicity

Igor Gulidov¹, Konstantin Gordon^{1,2}, Alexey Semenov¹, Danil Gogolin¹, Olga Lepilina¹, Olga Golovanova³, Sergey Dujenko³, Kira Medvedeva¹, Sergey Koryakin³, Sergey Ivanov⁴, Andrey Kaprin⁵

¹Department of proton therapy, A. Tsyb Medical radiological research center - branch of the National medical research radiological center, Obninsk, Russia. ²Department of histology, cytology and embryology, Medical Institution, People's Friendship University of Russia, Moscow, Russia. ³Department of radiophysics, A. Tsyb Medical radiological research center - branch of the National medical research radiological center, Obninsk, Russia. ⁴Director of A. Tsyb Medical radiological research center - branch of the National medical research radiological center, Obninsk, Russia. ⁵Director of National medical research radiological center, Moscow, Russia.

Summary

Purpose: To assess the efficacy and tolerance of proton re-irradiation in patients with unresectable recurrence of previously irradiated brain gliomas.

Methods: Between February 2016 and December 2019, 44 patients with in-field recurrence after prior irradiation of brain gliomas were irradiated with intensity-modulated proton therapy. Seven patients (15.9%) originally had low-grade (WHO grade I-II) gliomas, nine patients (20.4%) had anaplastic astrocytoma (WHO grade III), and 28 patients (63.7%) had glioblastoma (WHO grade IV). All tumors were unresectable due to their localization. After a median time from the prior irradiation of 28.0 months [range, 12 to 173], patients received PT with 2.0 and 3.0 GyRBE per fraction, with median proton EQD₂ ($\alpha/\beta=10$) to a tumor of 55.0 GyRBE [range, 46.0 to 61.75]. Adjuvant chemotherapy (Temozolomide, or Procarbazine, Lomustine and vincristine, or Bevacizumab with Irinotecan) received 86.9% of the patients (n=40). Treatment-related toxicity was reported following CTCAE.

Results: The median survival time was 12 months, with 1-year and 2-years overall survival (OS) amounting to 49.6% and 35.1%, respectively. The median progression-free survival (PFS) was 9 months, with 1- and 2-years PFS of 30.5% and 10.2%, respectively. Twenty-six patients died by the time of analysis; among them were 5 non-cancer deaths (19.2%), and 4 patients (15.4%) died of chemotherapy-associated severe toxicity. The incidence rate of radiation-induced necrosis was 6.8% (3 events).

Conclusions: Based on our results, we suggest re-irradiation of recurrent brain gliomas with proton therapy is able to achieve reasonable tumor control. Low adverse events rate and promising outcomes make it a safe treatment option with curative intent, even in unresectable cases.

Key words: proton therapy, re-irradiation, brain glioma, molecular imaging, unresectable

Introduction

Low and high grade malignant gliomas are the most common brain tumors, with a prevalence of 4 to 5 per 100.000 [1]. The current standard of care includes surgery, irradiation (RT), and systemic

treatment (i.e., chemotherapy (CTX), target or immune drugs), depending on the morphological and genetic types of glioma [2]. Due to their general infiltrative nature, most gliomas often recur [3].

Corresponding author: Konstantin Gordon, PhD. Department of Proton therapy, A. Tsyb Medical radiological research center - branch of the National medical research radiological center, 4 Korolev Street, Obninsk, 249036, Russia.
Tel: +7 910 518 41 48, Email: dr_gordon@yahoo.com
Received: 23/02/2021; Accepted: 09/03/2021

There is no standard of care in recurrence, but most treatment schemes advise repeating prior sequences, with maximal tumor resection first and adjuvant treatment after. Despite all current treatment approaches, recurrent gliomas grow mostly in their tumor bed, almost always laying in a primary irradiation volume. Until the last decades, the use of re-irradiation in recurrent brain tumors was limited by concerns of toxicity due to brain tissue vulnerability to repeated radiation influence [4].

Nevertheless, re-irradiation looks attractive as a result of recent progress in RT techniques and improvement of brain imaging as well (i.e., magnetic resonance spectroscopy, positron emission tomography (PET/CT) with amino acids) [5]. Commonly relapses occur in-field or by the field margin. Tumor visualization and accuracy of target volume definition in re-irradiation have a prognostic impact on overall survival (OS) in glioma patients. Usually, the standard target volume definition is based on magnetic resonance imaging (MRI) with contrast enhancement. In the meantime, MRI has low specificity for the determination of post-radiation changes and requires additional diagnostic methods to more accurately verify the nature of existing differences. PET/CT using drugs of the class of amino acids is necessary for precise diagnosis when examining patients with suspected relapse of gliomas. For example, ^{11}C -methionine PET (MET) has been approved as a useful diagnostic option for different, highly active metabolic tumors, with glioblastoma multiforme (GBM) among them. PET also helps determine the ametabolic zone (radionecrosis) and distinguish recurrence from pseudoprogression [6].

Prior studies have shown photon therapy, like radiosurgery (SRS) or hypofractionation (SRT), can be safely and effectively promoted for patients with small volumes of gliomas recurrence [7-9]. Compared with standard photon linear accelerators, proton therapy has dosimetry advantages determined by specificities of linear energy transfer called Bragg peak, characterized by a low incoming dose and the deposition of the majority of energy to a single point. Beyond this point (the target), energy declines sharply. These features make possible RT of targets with large volumes while minimizing the affection of normal tissues. Since local in-field failures of brain tumors after a previous RT course are widespread, it is critically important to reduce the dose to the surrounding brain tissue, which potentially allows us to increase the total dose. The conformity of re-irradiation affects both the quality of life of patients and the treatment's efficacy, providing an opportunity to deliver higher doses to the recurrent tumor.

Methods

A group of 44 patients with unresectable recurrence of previously irradiated brain gliomas was treated with proton therapy (PT) from February 2016 to December 2019. This retrospective study was approved by the institutional review board. Seven patients (15.9%) originally had low-grade gliomas (WHO grade I-II, LGG), nine patients (20.4%) had anaplastic astrocytoma (WHO grade III, AA), and 28 patients (63.7%) had GBM (WHO grade IV). All patients received prior RT and had in-field recurrences. The patients in the study were older than 18 years old, with biopsy-confirmed diagnosis at the initial treatment, and MET or ^{18}F -tyrosine (FET)-confirmed recurrence (with the median uptake level of 4.05 SUV [range, 1.7-6.1], without radiographic/metabolic signs of persistent brain edema or post-radiation necrosis). The patients had a minimum of 6 months of follow-up time, or until the time of death in case of <6 months event. Before the PT, the patient's medical history and treatment possibilities were discussed at the multidisciplinary tumor board. Patient, tumor, and treatment characteristics are summarized in Table 1.

Non-conformal treatment (still utilized in post-Soviet countries) had 11 patients (22.9%). The rest of the group received conformal treatment. The median biological effective dose (BED) of the 1st RT was 93.3 [83.3-100]. Since there is still a discussion about the optimal re-irradiation time [10], in our department, we usually choose 12 months as an optimal safe period from the initial RT to the second course.

Table 1. Patient and treatment characteristics

| <i>Patient characteristics</i> | <i>Number</i> |
|--|-------------------|
| Total number of patients | 44 |
| Median follow-up time in months | 16 (2-39) |
| Gender, n (%) | |
| Female | 23 (52.3) |
| Male | 21 (47.7) |
| Median age in years | 43 (24-69) |
| Median Karnofsky score | 70 (60-100) |
| Median prior RT BED in Gray | 93.3 (83.3-100) |
| Median interim from initial RT in months | 28 (12-173) |
| Conformal prior RT (3D-CRT/IMRT) | 33 (75) |
| Non-conformal prior RT, n (%) | 11 (25) |
| Initial histology | |
| LGG | 7 (15.9) |
| AA | 9 (20.4) |
| GBM | 28 (63.7) |
| Median SUV uptake level | 4.05 (1.7-6.1) |
| PT dosimetry | |
| Median GTV volume in cm ³ | 62.7 (6.9-274) |
| Median D ₉₅ | 96.7 (90.2-100) |
| Median total BED ($\alpha/\beta=3$) | 190 (170-214) |
| Median proton EQD ₂ ($\alpha/\beta=10$) | 55.0 (46.0-61.75) |

PT was delivered via a fixed horizontal spot-scanning beam in seated position, with image-guidance and standard immobilization [11]. Delineation of organs at risk (OARs) was done with the help of MR images, and gross target volume (GTV) was determined both by PET/CT and MRI scans. Differences in tumor volume between MRI and PET/CT were observed in 86.4% of the cases, always with larger PET-based GTV. Combined delineation also was intended to prevent re-RT of patients with pseudoprogression or toxicity after original RT. The median GTV volume was 68.1 cm³ (range, 6.9 to 274.0). For the planning target volume (PTV), the corresponding GTV was expanded by a 3-mm margin. For critical OARs (e.g., brain stem or optical structures), we also added a 3 mm safety margin.

Serial OARs (i.e., spinal cord, optic nerves, chiasma and brain stem) were allowed to receive a cumulative dose from both courses < 120-125% from the QUANTEC-limitations [12]. The PT dose was prescribed to the PTV with the aim of at least 95%, but in case of meeting OAR limitations, dose constraints usually prioritized target coverage. The median D₉₅ was 96.7% (range, 90.2 to 100). Relative biological effectiveness (RBE) of 1.1 for protons was assumed. An example of the proton dose distribution is illustrated in Figure 1. Patients were treated with 2.0 GyRBE (n=34) and 3.0 GyRBE (n=10) per fraction (Fx), with the median EQD₂ ($\alpha/\beta=10$) of 55.0 Gy (range, 46.0 to 61.75). An accelerated schedule was chosen for small volumes and/or poor performance status (GTV<50 cm³; Karnofsky score <70).

The patients did not receive concomitant CTX avoiding the potential increase of toxicity and treatment interruption. Adjuvant systemic therapy was delivered following the prescriptions of the treating medical oncologists. Forty patients (86.9%) received adjuvant CTX. Among them, temozolomide was prescribed for 12 patients (30.0%), 2 patients (5%) received a PCV regimen (procarbazine, lomustine and vincristine), and in 26 cases (65.0%), a combination of bevacizumab and irinotecan was chosen.

Patients were examined with regular MRI with contrast every 3 months and/or PET-CT if required when standard MRI could not determine radionecrosis

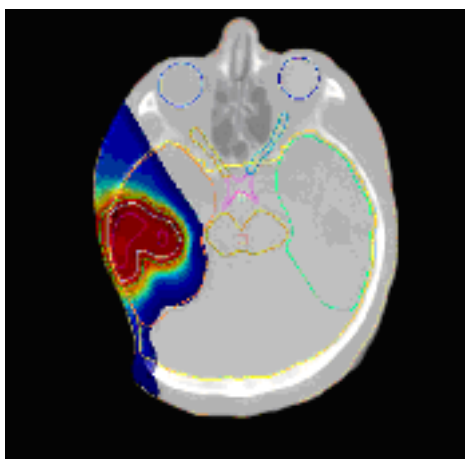


Figure 1. Representative proton re-irradiation plan.

versus tumor progression. Radiographic findings were described following the RANO criteria. Acute and late side effects were assessed by a radiation oncologist and recorded based on the CTCAE scale.

Statistics

Study endpoints were to estimate actuarial overall survival (OS), progression-free survival (PFS), and toxicity rate. Survival values were calculated using the Kaplan-Meier method (and reverse Kaplan-Meier for median follow-up time) with analysis performed in GraphPad Prism 8 (p value <0.05, assumed as statistically significant). Log-rank test and Pearson correlation coefficient were applied to compare the analyzed factors. As our study group contained a limited number of cases, we decided not to categorized patients by tumor grading or treatment parameters since small groups' separate results are non-representable significantly.

Results

The median follow-up time from proton re-irradiation was 16 months (range, 2.0 to 39). The median survival time was 12 months, and the 1-, 2- and 3-years OS were 49.6%, 35.0%, and 13.1%, respectively (Figure 2). Twenty-six patients (59.0%) died by the time of analysis, most of them due to tumor progression. Among them, 5 patients (19.2%) died of non-cancer reasons (cardiac attack in 2 patients, 3 cases with COVID-19 pneumonia), and 4

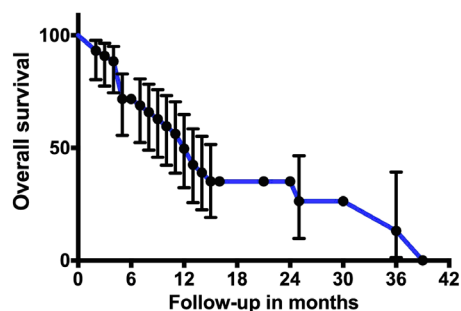


Figure 2. Overall survival from proton re-irradiation.

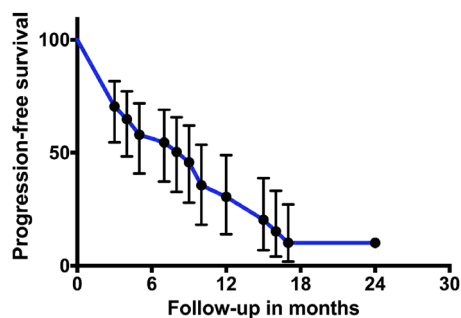


Figure 3. Progression-free survival from the beginning of re-irradiation.

Table 2. Correlation univariate analysis of prognostic factors and overall survival

| Factor | <i>p</i> value |
|-----------------|----------------|
| Initial grade | 0.005 |
| PET/CT uptake | 0.917 |
| RT interval | 0.422 |
| Proton PTV | 0.559 |
| Proton dose | 0.630 |
| Proton Fx | 0.875 |
| Total BED | 0.407 |
| Initial surgery | 0.118 |
| Adjuvant CTX | 0.125 |

patients (15.4%) died due to severe toxicity after the CTX courses. The median PFS, calculated from the time of patient enrollment, was 9 months, with 1- and 2-year PFS of 30.5% and 10.2%, respectively (Figure 3). Patterns of failure were analyzed, and local recurrence was reported in 22 cases (50.0%), distant failure in 5 patients (11.4%), and in/out-of-field relapse was reported twice (4.5%). In 34.1% of the cases, radiographic progression was not occurred either due to severe clinical progression or absence of RANO signs of progression. We repeated PT for 2 patients (4.5%) with out-of-field relapses since the new target did not overlap with the previously irradiated zones.

Following univariate analyses of original tumor histology, surgery at the time of initial diagnosis, FET/MET level of recurrent tumor, irradiation parameters (i.e., EQD₂ of PT, total BED, PTV volume, fractionation, time to prior RT, D₉₅ %), adjuvant CTX, age was evaluated (Table 2). Only one factor (initial tumor grade, *p*=0.005) had a statistically significant influence on OS.

All patients tolerated proton irradiation well, without interruptions. Acute toxicity was represented by local alopecia (*n*=14) and in-field skin epidermitis grade 1-2 (*n*=29). We did not observe an increase in already persistent neurological deficits. Three asymptomatic radionecroses (6.8%) were recorded at 16, 21, and 30 months of observation. Following linear energy transfer (LET) assessment of treatment plans did not show a correlation between high-LET points and necrotic areas. In 2 cases, there was steroid-resistant edema. Among other adverse events, there was one patient who experienced vision loss. The patient's blindness was expected due to the chiasma tolerance exhausted after prior RT and relapse, involving visual structures. Also, neurocognitive dysfunction was observed testing 4 patients, among those who survived >12 months. However, these patients did not notice a remarkable decrease in quality of life.

Discussion

The problem of gliomas is their local recurrence. It determines the intensity and optimization of local therapy options like surgery and radiotherapy as prior treatment. Treatment of brain glioma relapses remains a complicated problem of neurooncological science, with limited health care options. Even though there is no standard scheme, a comprehensive strategy is required, which usually means maximal surgical resection followed by radiotherapy and CTX. Re-operation is recommended in the first place, but only in patients with good performance status and in whom the recurrence size and location are amenable to resection. So quite frequently, gross tumor resection might not be reachable due to the most infiltrative nature of gliomas, especially in case of recurrence in deep parts of the brain [13].

Although there are advancements in drug therapy, glioma patients still have minimal benefit from CTX. Recent clinical trials did not report significant advantages of immune therapy for recurrent GBM [14]. It has to be noted that systemic treatment is also associated with toxicity, e.g., hypertension or an increased risk of thromboembolic complications [15]. In our study, we observed 4 deaths due to severe CTX toxicity and 2 cases of heart infarct that potentially might also be drug-related. Anyhow, CTX did not show a significant influence on the survival of our patients (*p*=0.125).

For a long time, re-RT was considered a risky treatment with a high expectancy of adverse events, especially radiation necrosis. A prospective study by Shepherd et al in 1997 demonstrated an extreme level of necrosis in 36% of the cases [16]. Meanwhile, re-RT with advanced photon units shows positive outcomes as a therapeutic option for glioma relapse. By this time, the most representative research by Navarra et al showed the efficacy and toxicity of re-RT in a group of 300 patients, even with a small median dose of 43 Gy [17]. The median OS was 9.7 months, with 1- and 2-year OS of 41% and 17.7%, respectively, and limited toxicity. In 2001, Vengina et al reported 42 patients' re-RT, with a higher median re-RT dose of 46 Gy. The authors also correlated tumor grade with longer OS and increased severe toxicity with total BED exceeding 204 Gy [18]. Combs et al reported 32 cases of re-treatment with SRS, with a median OS of 10 months. By their results, a target volume >10 cm³ was associated with a higher toxicity rate [19]. This suggestion was also supported by Hall et al who showed the RT-volume >28 cm³ and dose >20 Gy in 1 Fx associated with radiation necrosis risk [20].

Re-RT is a complicated procedure and needs advances in target volume definition. But currently, the standard target volume definition is usually based on MRI with contrast enhancement. Due to the infiltrative nature of malignant glial tumors' growth, the actual target volume may not correspond to the T1-weighted image mode's contrast zone. Distinguishing between progression and pseudoprogression of brain necrosis is based on the difference in the accumulation of the tracer in brain tissues, with an altered blood-brain barrier. Based on PET/CT studies' meta-analyses, and it was found that the tumor to brain ratio (TBR) shows the presence of a pathological process with high accuracy and method sensitivity of 90.1%, based on pathomorphological comparison and verification [21]. Hotta et al showed that TBR 1.85-2.74 was inherent in radionecrosis and 2.35-3.56 in relapse, respectively [22]. Pseudoprogression is a complicated clinical situation expressed in transitory stereotypical tracer hyperfixation and usually not related to further progression. Skvortsova et al described a metabolic mismatch phenomenon due to the transient diffuse high MET uptake in the cerebral cortex [23]. PET with tyrosine showed to be more specific in determining the metabolic activity of previously irradiated glial tumors [24]. Focusing on SUV 1.6 as the border of the defined active tumor tissue, more accurate contouring is possible, corresponding to the biological tumor volume [6]. In the meantime, up to a 95% difference in GTV delineated by MRI and biological tumor volume by PET/CT scans was shown [25]. Our results (86.6% volume differences and absence of "misdiagnosis") suggest a combined PET/CT and MRI tumor volume delineation as a necessary procedure for re-RT planning in glioma recurrence. However, we did not find a correlation between uptake level and survival outcomes ($p=0.917$).

In variable clinical situations, PT was shown to achieve maximal dose-to-normal tissue sparing with survival improvements compared to photon linear accelerators [26], and re-RT can potentially benefit from its dose distribution. However, there is a small number of articles regarding PT re-RT in brain tumors, in turn containing a limited number of patients. The study by Desai et al described 21 cases of proton re-RT in gliomas with a 50.5 Gy total dose. The median survival was 10.5 months, and only twice radionecrosis was observed [27]. Another study presented by Mizumoto et al with 26 patients enrolled, showed PT as a feasible and effective treatment [28]. Thereby most of the studies identify the effectiveness and good tolerance of PT in patients with recurrent gliomas.

Our study has limitations due to its retrospective nature, non-heterogeneity of the pathological

diagnosis, and limited number of patients too. Even though re-RT with a high median proton dose of 55 GyRBE demonstrated positive outcomes, with almost half of the patients surviving one year, and 35.1% overcoming at least 2 years. A small number of adverse events (3 necrosis, 1 vision loss) occurred, despite the relatively large median tumor volume (62.7 cm^3) and dose escalation, compared to other studies. The only significant factor that influenced OS was the original pathological diagnosis. This result is in agreement with the outcomes from Galle et al, who demonstrated in a study with 20 patients a favorable long-term survival associated with originally grade I-III gliomas [29]. The Proton Collaborative Group revealed another important survival impact factor in the 01-009 trial: tumor resection before re-RT was strongly associated with better outcomes (91.3% decreased risk of death) [30]. Due to this fact, the initial prognosis of our group was relatively poor since only unresectable cases were included. Despite this, re-treatment with PT was able to achieve considerable survival results.

Regarding proton therapy, there are still concerns about its evidence. Most of the recent publications have limitations in a number of patients but yet show promising outcomes. Our data suggest PT effectiveness and safety for recurrent glioma in a complicated group of patients with unresectable tumors.

Statement of Ethics

All procedures were performed following the ethical standards of the responsible committee on human experimentation and with the Helsinki Declaration of 1964, as revised in 2013. This study was approved by the local ethical committee and the institutional review board of A. Tsyb Medical radiological research center branch of the National medical research radiological center, and additionally approved by the Ministry of Health of Russia, including waiver of informed consent due to its retrospective nature.

Author contributions

IG, KG conceived and planned the study. KG, AS, OG, DG, OL, KM, SK, SD carried out the treatment and planning. KG, IG contributed to the interpretation of the results. KG, IG took the lead in writing the manuscript. SI, AK made the final approval. All authors provided critical feedback and helped shape the research, analysis and manuscript.

Conflict of interests

The authors declare no conflict of interests.

References

- URL: <http://gco.iarc.fr/today/data/factsheets/cancers/31-Brain-central-nervous-system-fact-sheet.pdf>
- NCCN Guidelines Version 3.2020 Central nervous system cancers. URL: https://www.nccn.org/professionals/physician_gls/pdf/cns.pdf
- Wallner KE, Galicich JH, Krol G, Arbit E, Malkin MG. Patterns of failure following treatment for glioblastoma multiforme and anaplastic astrocytoma. *Int J Radiat Oncol Biol Phys* 1989;16:1405-9.
- Mayer R, Sminia P. Reirradiation tolerance of the human brain. *Int J Radiat Oncol Biol Phys* 2008;70:1350-60.
- Donche S, Verhoeven J, Descamps B et al. The Path Toward PET-Guided Radiation Therapy for Glioblastoma in Laboratory Animals: A Mini Review. *Front Med (Lausanne)*. 2019;6:5. doi:10.3389/fmed.2019.00005
- Suchorska B, Jansen NL, Linn J et al. Biological tumor volume in 18FET-PET before radiochemotherapy correlates with survival in GBM. *Neurology* 2015;84:710-9. doi:10.1212/WNL.0000000000001262
- Redmond KJ, Mehta M. Stereotactic Radiosurgery for Glioblastoma. *Cureus* 2015;7:e413. doi:10.7759/cureus.413
- Elaimy A, Mackay A, Lamoreaux W et al. Clinical outcomes of gamma knife radiosurgery in the salvage treatment of patients with recurrent high-grade glioma. *World Neurosurg* 2013;80:872-8. doi:10.1016/j.wneu.2013.02.030
- Ekici K, Ozseker N, Mayadagli A, Erdogan KM, Olmezoglu A. Efficacy of stereotactic radiotherapy as salvage treatment for recurrent malignant gliomas *JBUON* 2014;19:1029-34.
- Krauze AV, Attia A, Braunstein S et al. Expert consensus on re-irradiation for recurrent glioma [published correction appears in *Radiat Oncol*. 2018 Jan 18;13(1):8]. *Radiat Oncol* 2017;12:194. Published 2017 Dec 1. doi:10.1186/s13014-017-0928-3
- Gulidov I, Gordon K, Gogolin D et al. Reirradiation of intracranial tumors with active beam scanning protons. *Siberian J Oncol* 2017;16:63-70. doi:10.21294/1814-4861-2017-16-5-63-70 [Russian]
- Ang KK, Price RE, Stephens LC et al. The tolerance of primate spinal cord to re-irradiation. *Int J Radiat Oncol Biol Phys* 1993;25:459-64. doi:10.1016/0360-3016(93)90067-6
- Harsh GR 4th, Levin VA, Gutin PH, Seager M, Silver P, Wilson CB. Reoperation for recurrent glioblastoma and anaplastic astrocytoma. *Neurosurgery* 1987;21:615-21. doi:10.1227/00006123-198711000-00002
- McGranahan T, Therkelsen KE, Ahmad S, Nagpal S. Current State of Immunotherapy for Treatment of Glioblastoma. *Curr Treat Options Oncol* 2019;20:24. Published 2019 Feb 21. doi:10.1007/s11864-019-0619-4
- Friedman HS, Prados MD, Wen PY et al. Bevacizumab alone and in combination with irinotecan in recurrent glioblastoma. *J Clin Oncol* 2009;27:4733-40.
- Shepherd SF, Laing RW, Cosgrove VP et al. Hypofractionated stereotactic radiotherapy in the management of recurrent glioma. *Int J Radiat Oncol Biol Phys* 1997;37:393-8. doi:10.1016/S0360-3016(97)00455-5
- Navarria P, Minniti G, Clerici E et al. Re-irradiation for recurrent glioma: outcome evaluation, toxicity and prognostic factors assessment. A multicenter study of the Radiation Oncology Italian Association (AIRO). *J Neurooncol* 2019;142:59-67. doi:10.1007/s11060-018-03059-x
- Veninga T, Langendijk HA, Slotman BJ et al. Reirradiation of primary brain tumours: survival, clinical response and prognostic factors. *Radiother Oncol* 2001;59:127-37. doi:10.1016/s0167-8140(01)00299-7
- Combs SE, Widmer V, Thilmann C, Hof H, Debus J, Schulz-Ertner D. Stereotactic radiosurgery (SRS): treatment option for recurrent glioblastoma multiforme (GBM). *Cancer* 2005;104:2168-73. doi:10.1002/cncr.21429.
- Hall WA, Djalilian HR, Sperduto PW et al. Stereotactic radiosurgery for recurrent malignant gliomas. *J Clin Oncol* 1995;13:1642-8. doi:10.1200/JCO.1995.13.7.1642
- Xu W, Gao L, Shao A, Zheng J, Zhang J. The performance of ¹¹C-Methionine PET in the differential diagnosis of glioma recurrence. *Oncotarget* 2017;8:91030-39. doi:10.18632/oncotarget.19024
- Hotta M, Minamimoto R, Miwa K. ¹¹C-methionine-PET for differentiating recurrent brain tumor from radiation necrosis: radiomics approach with random forest classifier. *Sci Rep* 2019;9:15666. doi:10.1038/s41598-019-52279-2
- Skvortsova T, Savintseva Z, Gurchin A, Trofimova T. Metabolic pseudoprogression as new phenomenon on ¹¹C-methionine PET/CT during treatment monitoring of patients with malignant cerebral glioma. *Diagnostic Radiol Radiother* 2019:21-30. doi.org/10.22328/2079-5343-2018-4-21-30 [In Russian]
- Galldiks N, Langen KJ. Amino Acid PET - An Imaging Option to Identify Treatment Response, Posttherapeutic Effects, and Tumor Recurrence? *Front Neurol* 2016;7:120. Published 2016 Jul 28. doi:10.3389/fneur.2016.00120
- Kosztyla R, Chan EK, Hsu F et al. High-grade glioma radiation therapy target volumes and patterns of failure obtained from magnetic resonance imaging and 18F-FDOPA positron emission tomography delineations from multiple observers. *Int J Radiat Oncol Biol Phys* 2013;87:1100-06. doi:10.1016/j.ijrobp.2013.09.008
- Doyen J, Falk AT, Floquet V, Héroult J, Hannoun-Lévi JM. Proton beams in cancer treatments: Clinical outcomes and dosimetric comparisons with photon therapy. *Cancer Treat Rev* 2016;43:104-12. doi:10.1016/j.ctrv.2015.12.007
- Desai BM, Rockne RC, Rademaker AW et al. Overall Survival (OS) and Toxicity Outcomes Following Large-Volume Re-irradiation Using Proton Therapy

- (PT) for Recurrent Glioma. *Int J Radiat Oncol Biol Phys* 2014;90:Suppl. S286.
28. Mizumoto M, Okumura T, Ishikawa E et al. Reirradiation for recurrent malignant brain tumor with radiotherapy or proton beam therapy. *Strahlenther Onkol* 2013;189:656-63. doi: 10.1007/s00066-013-0390-6.
29. Galle JO, McDonald MW, Simoneaux V, Buchsbaum JC. Reirradiation with Proton Therapy for Recurrent Gliomas. *Int J Particle Ther* 2015;2:11-8. doi: 10.14338/theijpt-14-00029.1.
30. Saeed AM, Khairnar R, Sharma AM et al. Clinical Outcomes in Patients with Recurrent Glioblastoma Treated with Proton Beam Therapy Reirradiation: Analysis of the Multi-Institutional Proton Collaborative Group Registry. *Adv Radiat Oncol* 2020;5:978-83. doi:10.1016/j.adro.2020.03.022