

Received: 2021.01.11  
Accepted: 2021.03.19  
Available online: 2021.03.23  
Published: 2021.03.31

# Allogeneic Natural Killer and Cytomegalovirus (CMV)-pp65 Pulsed Dendritic Cells Induced Complete Response Through 15 Months in a Patient with Recurrent Glioblastoma: A Case Study

Authors' Contribution:  
Study Design A  
Data Collection B  
Statistical Analysis C  
Data Interpretation D  
Manuscript Preparation E  
Literature Search F  
Funds Collection G

ABDEF 1,2,3  
ABCD 1,2,3  
B 1,2  
BCG 1,2  
AD 1,2

**Serhat Gumrukcu**  
**Tung X. Nguyen**  
**Rachel L. White**  
**Gregory T. Howell**  
**Phillip Musikanth**

1 Seraph Research Institute, Los Angeles, CA, U.S.A.  
2 Seraph Medical Clinic, Los Angeles, CA, U.S.A.  
3 Enochian Biosciences, Inc., Los Angeles, CA, U.S.A.

**Corresponding Author:** Serhat Gumrukcu, e-mail: [drs@seraphinstitute.org](mailto:drs@seraphinstitute.org)

**Conflict of interest:** None declared

**Patient:** Male, 36-year-old  
**Final Diagnosis:** Glioblastoma multiforme  
**Symptoms:** Headache • seizure • tumor  
**Medication:** —  
**Clinical Procedure:** Immunotherapy  
**Specialty:** Immunology • Oncology

**Objective:** Unusual or unexpected effect of treatment


**Background:** Glioblastoma (GBM) is a highly aggressive brain tumor with poor survival outcomes. While conventional treatment strategies such as surgery, radiation, and chemotherapy can extend survival, the prognosis for GBM patients after 2 years remains low. One-year progression-free survival (PFS) and complete response (CR) with recurrent GBM is extremely low. Recent clinical trials using either engineered chimeric antigen receptor (CAR) T cells, autologous dendritic cell (DC) vaccination, or natural killer (NK) cells have shown promise for patients with GBM following initial diagnosis. Despite these significant immunotherapeutic advancements, new strategies need to be developed to address the poor survival outcomes for GBM.

**Case Report:** A 36-year-old male patient with recurrent bilateral parietal GBM, following subtotal resection, was treated using an immunotherapeutic strategy combining lymphosuppressive conditioning with intravenous administration of highly purified allogeneic NK cells (mismatched for inhibitory killer Ig-like receptor [KIR]-human leukocyte antigen [HLA] ligand interactions), celecoxib, temozolomide (TMZ), tetanus-diphtheria vaccination, and multiple intradermal injections of human cytomegalovirus (CMV)-pp65 pulsed dendritic cells. This treatment did not exhibit any toxic effects and resulted in regression of intracranial residual disease on both hemispheres. Additionally, the clinical response was durable, persisting for more than 15 months after the first infusion of KIR-HLA-mismatched purified allogeneic NK cells.

**Conclusions:** A patient with recurrent GBM achieved durable CR with a novel treatment strategy with allogeneic NK cells and DC pulsed with CMV-pp65 following subtotal surgical resection. If confirmed in additional patients, this combination approach could offer an effective therapeutic option for people with an otherwise dismal prognosis.

**Keywords:** Adoptive Transfer • Cancer Vaccines • Cell- and Tissue-Based Therapy • Dendritic Cells • Glioblastoma

Full-text PDF: <https://www.amjcaserep.com/abstract/index/idArt/931030>



1367



—



3



30



## Background

Glioblastoma (GBM) is a highly aggressive brain tumor with poor survival outcomes [1,2]. While conventional treatment strategies such as surgery, radiation, and chemotherapy can extend survival, the prognosis for GBM patients after 2 years remains low [3-5]. Long-term progression-free survival (PFS) and complete response (CR) with unresected recurrent GBM are extremely poor [6,7]. Outcomes are still considerably worse for patients with residual tumor following surgical resection with poor PFS, and CR at 1 year is rare [6-9], and is likely even rarer with post-resection residual disease. However, PFS and CR are also correlated with age and location of the tumor [10,11].

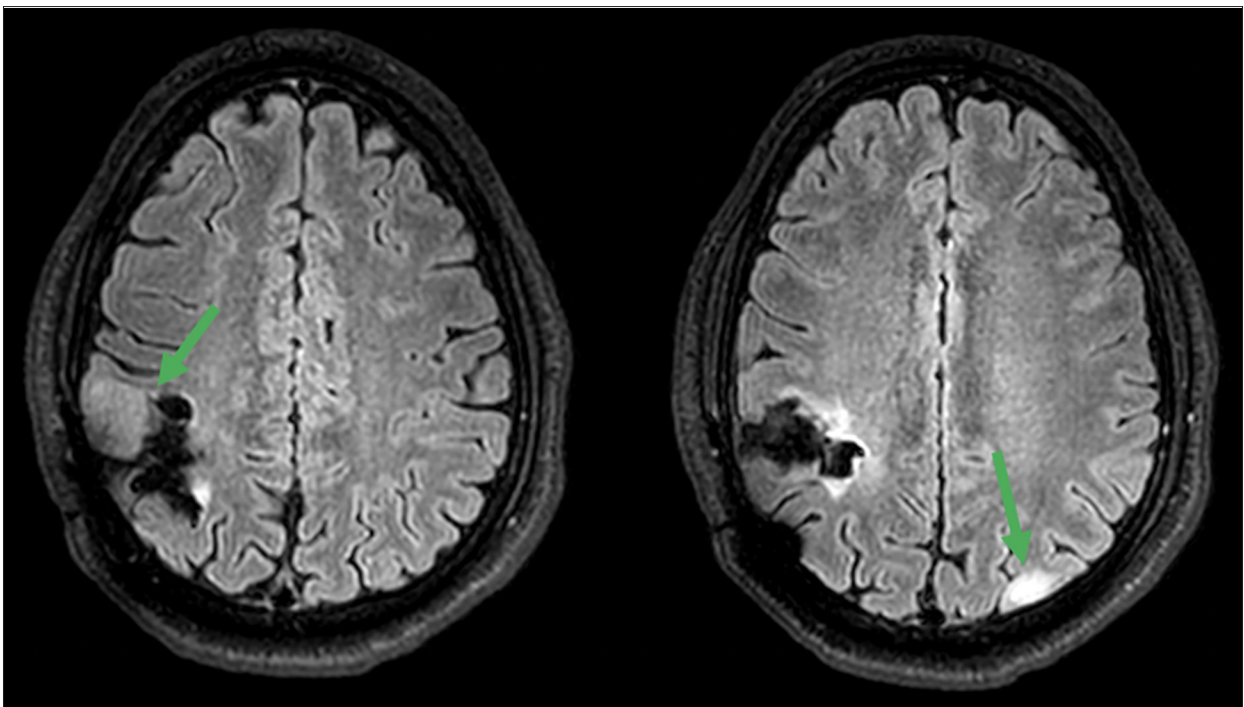
These poor outcomes necessitate continued research efforts to develop new therapeutic interventions to improve treatment outcomes in the GBM clinical setting. The concept of using intentionally HLA-mismatched donor NK cells in clinical settings for the treatment of chemotherapy-resistant patients with solid tumors has been previously reported [12]. Recent clinical trials using either engineered chimeric antigen receptor (CAR) T cells [13], autologous dendritic cell (DC) vaccination [14], or NK cells [15-17] have shown promise for patients with GBM following initial diagnosis. Despite these significant immunotherapeutic advancements, new strategies are needed to address the poor survival outcomes for patients with GBM.

We hypothesized that a combination immunotherapy could be effective. We report the case of a patient with recurrent GBM with residual tumor post-surgical resection who achieved CR after 1 month of temozolomide (TMZ)-adjunctive therapy with allogeneic haploidentical NK and cytomegalovirus-p65 pulsed dendritic cells. His CR has persisted for 15 months.

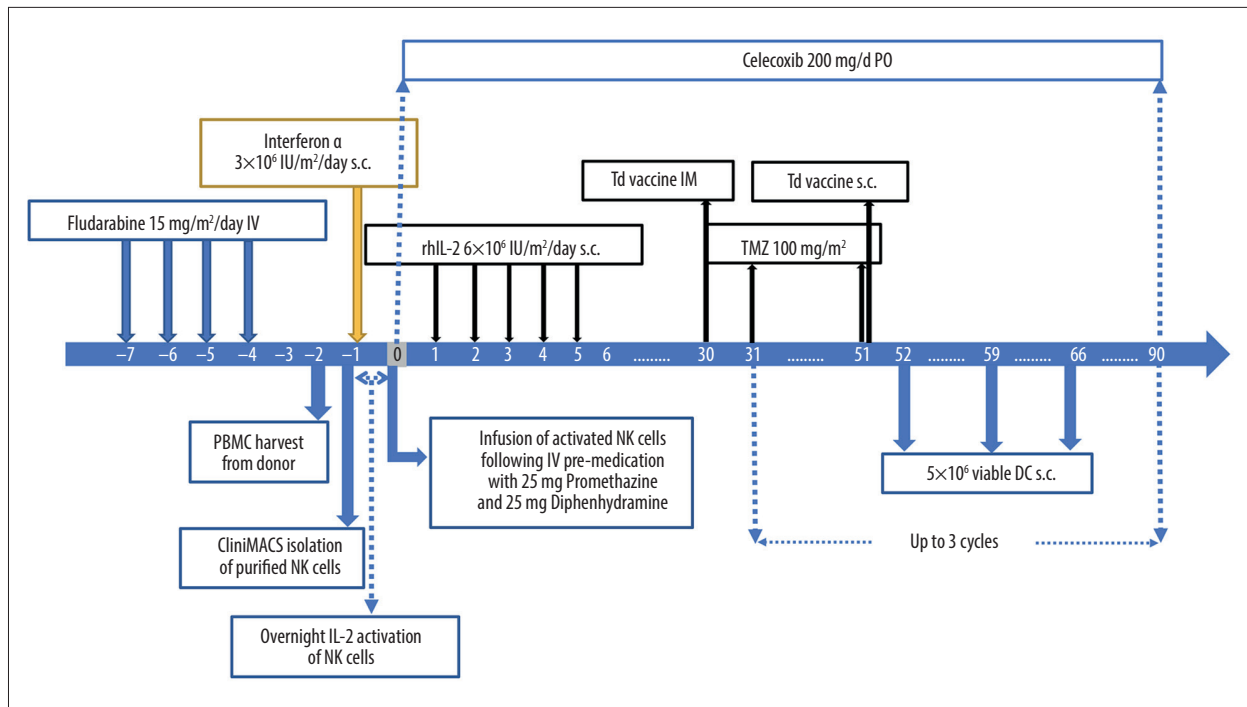
## Case Report

In 2015, 32-year-old man presented with IDH-mutant diffuse astrocytoma, with a lesion in the right frontoparietal lobe. Six months after surgical resection, the tumor recurred in the same region, leading to a second resection followed by radiation therapy. In May 2019, he presented with neurological symptoms. A perfusion MRI revealed lesions in the right frontoparietal (2.5 cm) and left parieto-occipital lobes (1 cm) (Figure 1). Subtotal surgical resection of the tumors (as revealed on a perfusion MRI) in July 2019 revealed a pathological diagnosis of GBM, IDH-mutant. As standard of care, the patient received adjuvant chemoradiation therapy with 59.4 Gy/33 fractions radiation and 75 mg/m<sup>2</sup> temozolomide (TMZ) from July to August 2019.

The patient was then enrolled in an IRB-approved experimental combination immunotherapy. Consistent with FDA Regulations Title 21 CFR Part 1721 for tissue/cell-based treatment practices, an inhibitory KIR-HLA-mismatched haploidentical relative



**Figure 1.** Pre-operative axial T2 FLAIR MRI images of the brain. Axial T2 FLAIR MRI images of the brain from June 2019 show tumors in the right frontoparietal and left parieto-occipital lobes.



**Figure 2.** Experimental treatment protocol, including low-dose lymphosuppressive pre-conditioning followed by haploidentical allogeneic IL-2 activated NK cell infusion and DC vaccine protocol.

was identified as a cell donor. The protocol was based on a previously reported approach for intentionally mismatched NK cells [12].

The patient received the experimental therapy from November 2019 through January 2020 (Figure 2). Between days -7 and -4, a moderate (15 mg/m<sup>2</sup>/d) dose of fludarabine was administered for pre-conditioning. On day -1, 3 million/m<sup>2</sup> IU interferon alpha (Intron A) was subcutaneously injected. On day 0, 1.6 billion (18 million/kg) allogeneic, highly purified (>95%) IL-2 activated NK cells were administered via intravenous infusion, followed by 5 daily sub-cutaneous injections of IL-2 (Proleukin, 6 million IU/m<sup>2</sup>). Thirty days after NK cell infusion, the patient received 1 intramuscular injection of tetanus-diphtheria (td) vaccine to prime a cellular immune response. The following day, the patient started a dose-intensified (di)-TMZ regimen for 21 days (100 mg/m<sup>2</sup>), and on day 21 of the cycle, the patient received a td vaccine intradermally into his right groin area. On days 22, 29, and 36, the patient received 5 million viable allogeneic, monocyte-derived DC pulsed with CMV-pp65 antigen intradermally into the right groin area. A Cox-2 inhibitor, Celebrex 200 mg/day, was administered throughout the regimen to limit the inflammatory symptoms of the immunotherapy and immune tolerance buildup against cancer by controlling regulatory T cells.

There were no grade III or IV adverse events. The patient experienced mild, self-limited fever on the days of the cell therapies

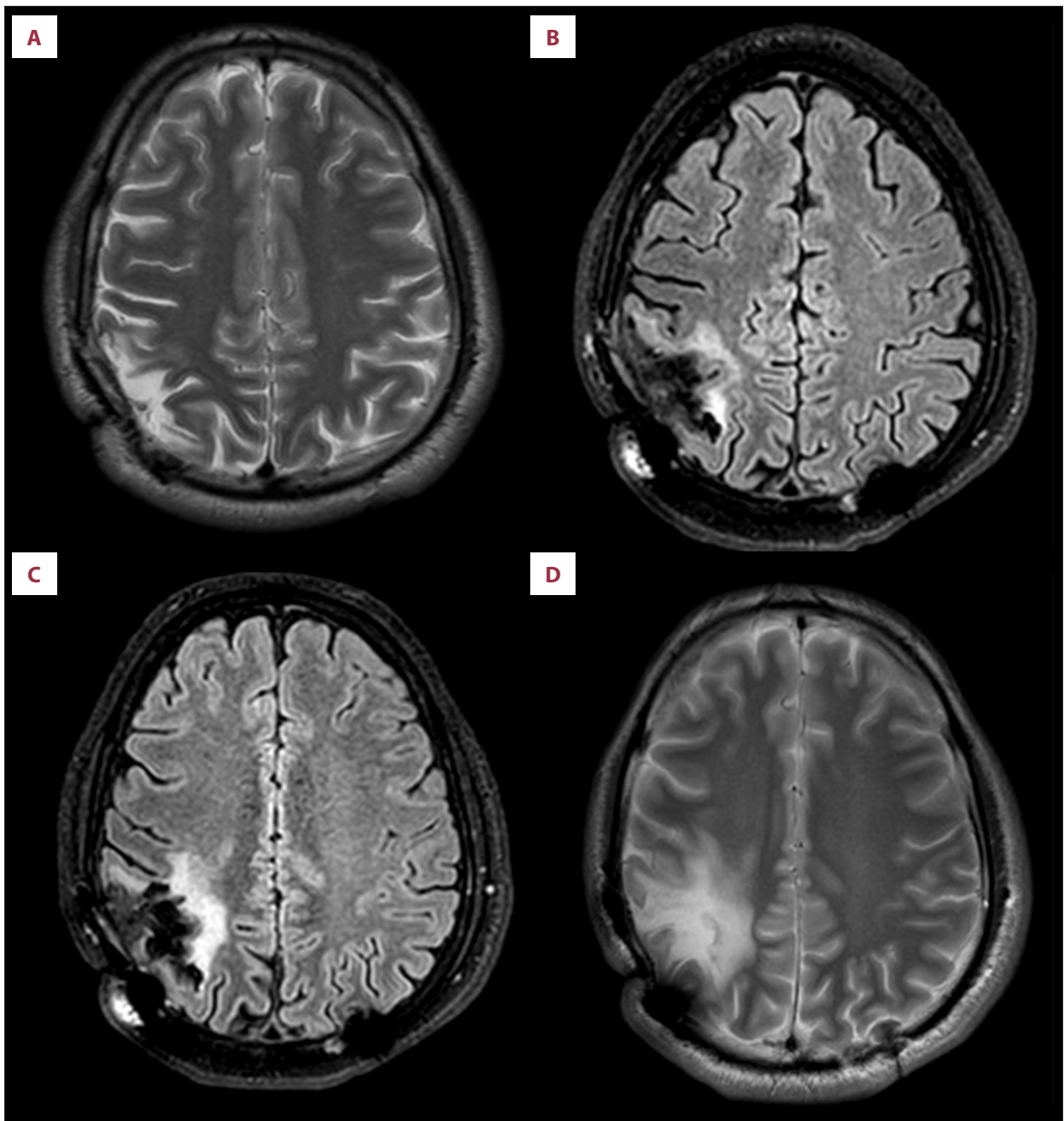
and grade 1 lymphopenia at the end of di-TMZ regimens. One month following NK cell infusion and 1 week following the first DC injection, no residual tumor was visible by contrast-enhanced MRI. Perfusion MRIs from months 3, 6, 12, and 15 showed continued CR (Figure 3A-3D, respectively).

## Discussion

There have been clinical studies that utilized CMV-pp65 antigen loaded DC vaccines for GBM patients with significant clinical response [18]. However, those studies were done with autologous DCs and on patients at the state of remission or minimal residual disease before any recurrence. In addition, the effectiveness of CMV vaccination alone versus in combination with, or use of, mismatched NK cells alone for the treatment of GBM requires further investigation.

Based on previous reports of various immunotherapies, we hypothesized that a combination of allogeneic NK and DC pulsed with CMV-pp65 could be effective in treating recurrent GBM [12-17].

GBM are associated with complex immunosuppressive effects within the tumor microenvironment (such as secretion of IL-10 and TGF-β), recruitment of M2-macrophages and regulatory T cells (Tregs) and their upregulation of immune checkpoint ligands and major histocompatibility (MHC) class I receptors



**Figure 3.** Post-immunotherapy follow-up axial T2 FLAIR MRI images of the brain. (A) 3-month, (B) 6-month, (C) 12-month, (D) 15-month contrast-enhanced MRI images with evidence of no tumor recurrence, demonstrating durable CR.

on their surface [19,20]. While adoptive transfer of T cells has been efficacious in GBM, NK cells, at least in mice, demonstrate a robust ability to eliminate GBM with the added benefit of minimal graft versus host disease (GVHD) in comparison to T cells [21]. Although there are elevated levels of MHC class I molecules on the surface of GBM cells [20], which can induce inhibition of NK cytolytic function (resulting in GBM immune evasion), this may be overcome with allogeneic NK transplantation from an MHC class I-mismatched donor [22]. The use

of KIR-HLA-mismatched NK cell therapy is known to improve the elimination of glioma stem cells [19], and has demonstrated efficacy in GBM patient-derived xenograft animal models [23,24], and in the clinic in patients with advanced non-small cell lung cancer [25].

DCs play a vital role by providing a direct link from innate immunity to adaptive immune response by digestion and presentation of antigen to the adaptive immune system. A recent

clinical trial employing DC vaccination with concomitant standard therapy demonstrated prolonged GBM patient survival [14]. Additionally, autologous DC vaccination with adjuvant TMZ enhanced NK activation and extended survival in GBM patients [18]. Vaccination with DC primed with CMV, which is expressed in over 90% of GBM [26,27], has shown both increased PFS and increased overall survival treating GBM in a clinical trial of patients with non-recurrent GBM [18,28,29].

Although 25% of GBM patients receiving TMZ can survive 2 years, the median overall survival is 9.5 months [30]. However, the outcomes are better in those who receive long-term TMZ and those who do not have residual tumor following surgical resection [6,7].

In this case study, a young man with recurrent GBM, residual tumor, and only 1 cycle of TMZ received a combination immunotherapy consisting of allogeneic NK cells and DCs that were intentionally mismatched for inhibitory KIR/HLA. Although the vaccine aspect seems to be similar to existing protocols currently in trials, and the mismatched NK protocol is based on previous reports [12], the combination of both cell therapies has never previously been administered to a GBM patient with residual tumor and achieved complete remission for over 1 year. Our rationale to use of intentionally mismatched NK cells as the first step of the combination immunotherapy was to

address and potentially eliminate residual disease, based on the premise of NK cells' reported ability to target chemotherapy-resistant cancer cells and GBM stem-like cells [12,17,22]. After the residual disease is addressed, the tumor surveillance elicited by a vaccine-based immunotherapy would have a better potential to control the disease and prevent relapse.

It is possible that individual components (eg, TMZ, NK, or DC) with or without CMV-pp65 could have been the cause of the CR. However, based on previously reported data as discussed above, we believe the results of this case study could offer new immunotherapy strategies and ideas to the field by demonstrating the potential enhanced immunotherapeutic effects of intentionally and strategically mismatched allogeneic cell therapies compared to existing autologous therapy models in clinical development. However, additional investigation is needed.

## Conclusions

A patient with recurrent GBM achieved durable CR with a novel treatment strategy with allogeneic NK cells and DC pulsed with CMV-pp65 despite having residual tumor following surgical resection. If confirmed in additional patients, this approach could offer an effective therapeutic option for people with an otherwise dismal prognosis.

## References:

1. Omuro A, DeAngelis LM. Glioblastoma and other malignant gliomas: A clinical review. *JAMA*. 2013;310(17):1842-50
2. Ostrom QT, Gittleman H, Truitt G, et al. CBRUS Statistical Report: Primary brain and other central nervous system tumors diagnosed in the United States in 2011-2015. *Neuro Oncol*. 2018;20(Suppl. 4): iv1-86
3. Tsao MN, Mehta MP, Whelan TJ, et al. The American Society for Therapeutic Radiology and Oncology (ASTRO) evidence-based review of the role of radio-surgery for malignant glioma. *Int J Radiat Oncol Biol Phys*. 2005;63(1):47-55
4. Omuro A, Chan TA, Abrey LE, et al. Phase II trial of continuous low-dose temozolomide for patients with recurrent malignant glioma. *Neuro Oncol*. 2013;15(2):242-50
5. Batchelor TT, Mulholland P, Neyns B, et al. Phase III randomized trial comparing the efficacy of cediranib as monotherapy, and in combination with lomustine, vs lomustine alone in patients with recurrent glioblastoma. *J Clin Oncol*. 2013;31(26):3212-18
6. Bloch O, Han SJ, Cha S, et al. Impact of extent of resection for recurrent glioblastoma on overall survival: clinical article. *J Neurosurg*. 2012;117(6):1032-38
7. Quick J, Gessler F, Dützmänn S, et al. Benefit of tumor resection for recurrent glioblastoma. *J Neurooncol*. 2014;117(2):365-72
8. Cloughesy TF, Landolfi J, Vogelbaum MA, et al. Durable complete responses in some recurrent high-grade glioma patients treated with Toca 511 + Toca FC. *Neuro Oncol*. 2018;20(10):1383-92
9. Kushnirsky M, Feun LG, Gultekin SH, de la Fuente MI. Prolonged complete response with combined dabrafenib and trametinib after BRAF inhibitor failure in BRAF-mutant glioblastoma. *JCO Precis Oncol*. 2020;4:PO.19.00272
10. Jeswani S, Nuño M, Folkerts V, et al. Comparison of survival between cerebellar and supratentorial glioblastoma patients: Surveillance, epidemiology, and end results (SEER) analysis. *Neurosurgery*. 2013;73(2):240-46; discussion 246; quiz 246
11. Okada M, Miyake K, Tamiya T. Glioblastoma treatment in the elderly. *Neurol Med Chir*. 2017;57(12):667-76
12. Slavin S, Ackerstein A, Or R, et al. Immunotherapy in high-risk chemotherapy-resistant patients with metastatic solid tumors and hematological malignancies using intentionally mismatched donor lymphocytes activated with rIL-2: A phase I study. *Cancer Immunol Immunother*. 2010;59(10):1511-19
13. Brown CE, Alizadeh D, Starr R, et al. Regression of glioblastoma after chimeric antigen receptor T-cell therapy. *N Engl J Med*. 2016;375:2561-69
14. Liu LM, Ashkan K, Tran DD, et al. First results on survival from a large phase 3 clinical trial of an autologous dendritic cell vaccine in newly diagnosed glioblastoma. *J Transl Med*. 2018;16(1):142
15. Ishikawa E, Tsuboi K, Saijo K, et al. Autologous natural killer cell therapy for human recurrent malignant glioma. *Anticancer Res*. 2004;24:1861-71
16. Bielamowicz K, Khawja S, Ahmed N. Adoptive cell therapies for glioblastoma. *Front Oncol*. 2013;3:275
17. Zhang C, Oberoi P, Oelsner S, et al. Chimeric antigen receptor-engineered NK-92 cells: An off-the-shelf cellular therapeutic for targeted elimination of cancer cells and induction of protective antitumor immunity. *Front Immunol*. 2017;8:533
18. Iliopoulou EG, Kountourakis P, Karamouzis MV, et al. A phase I trial of adoptive transfer of allogeneic natural killer cells in patients with advanced non-small cell lung cancer. *Cancer Immunol Immunother*. 2010;59:1781-89
19. Broekman ML, Maas SLN, Abels ER, et al. Multidimensional communication in the microenviroms of glioblastoma. *Nat Rev Neuro*. 2018;14:482-95
20. Kmiecik J, Poli A, Brons NH, et al. Elevated CD3+ and CD8+ tumor-infiltrating immune cells correlate with prolonged survival in glioblastoma patients despite integrated immunosuppressive mechanisms in the tumor microenvironment and at the systemic level. *J Neuroimmunol*. 2013;264:71-83
21. Olson JA, Leveson-Gower DB, Gill S, et al. NK cells mediate reduction of GVHD by inhibiting activated, alloreactive T cells while retaining GVT effects. *Blood*. 2010;115(21):4293-301
22. Talerico R, Todaro M, Di Franco S, et al. 2013. Human NK cells selective targeting of colon cancer-initiating cells: A role for natural cytotoxicity receptors and MHC class I molecules. *J Immunol*. 2013;190:2381-90
23. Haspels HN, Rahman MA, Joseph JV, et al. Glioblastoma stem-like cells are more susceptible than differentiated cells to natural killer cell lysis mediated through killer immunoglobulin-like receptors-human leukocyte antigen ligand mismatch and activation receptor-ligand interactions. *Front Immunol*. 2018;9:1345
24. Gras Navarro A, Kmiecik J, Leiss L, et al. NK cells with KIR2DS2 immunogenotype have a functional activation advantage to efficiently kill glioblastoma and prolong animal survival. *J Immunol*. 2014;193(12):6192-206
25. Lee SJ, Kang WY, Yoon Y, et al. Natural killer (NK) cells inhibit systemic metastasis of glioblastoma cells and have therapeutic effects against glioblastomas in the brain. *BMC Cancer*. 2015;15:1011
26. Pellegatta S, Eoli M, Cuccarini V, et al. Survival gain in glioblastoma patients treated with dendritic cell immunotherapy is associated with increased NK but not CD8+ T cell activation in the presence of adjuvant temozolomide. *Oncoimmunology*. 2018;7(4):e1412901
27. Cobbs CS, Harkins L, Samanta M, et al. Human cytomegalovirus infection and expression in human malignant glioma. *Cancer Res*. 2002;62:3347-50
28. Mitchell DA, Xie W, Schmittling R, et al. Sensitive detection of human cytomegalovirus in tumors and peripheral blood of patients diagnosed with glioblastoma. *Neuro Oncol*. 2008;10:10-18
29. Batich KA, Reap EA, Archer GE, et al. Long-term survival in glioblastoma with cytomegalovirus pp65-targeted vaccination. *Clin Cancer Res*. 2017;23(8):1898-909
30. van Linde ME, Brahm CG, de Witt Hamer PC, et al. Treatment outcome of patients with recurrent glioblastoma multiforme: A retrospective multicenter analysis. *J Neurooncol*. 2017;135(1):183-92