

## Role of Preoperative Embolization in Management of Central Nervous System Tumours

Ummei Hani,<sup>1</sup> Ahmer Nasir Baig,<sup>2</sup> Muhammad Shahzad Shamim,<sup>3</sup> Basit Salam<sup>4</sup>

### Abstract

Preoperative embolization plays a significant role as an adjunct to surgical intervention in the cases of certain vascular tumours of the brain. While the procedure has resulted in facilitated resection of the tumour, and has reduced morbidity and mortality, its application remains debatable within the neurosurgical community, owing to rare, but major post-procedural complications. Herein, we have reviewed the literature to assess the safety and efficacy of preoperative angiographic embolization for brain tumours.

**Keywords:** embolization; brain tumor; skull base tumor; angiographic embolization;

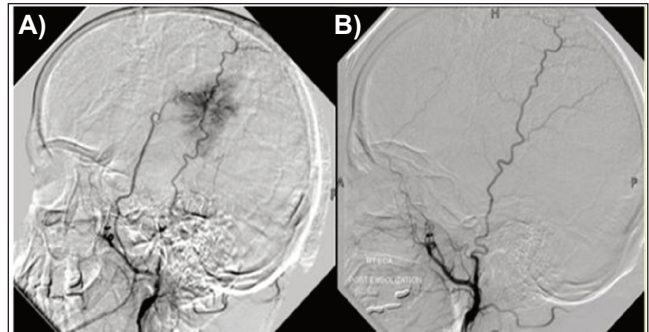
### Introduction

Despite advances in microsurgical techniques, management of vascular brain tumours is complex, and requires a multi-disciplinary approach.<sup>1,2</sup> Pre-operative embolization (PEm) was first described in the 1970s, and has slowly gained acceptance amongst the neurosurgical community, as an adjunct to brain tumour surgery for hyper-vascular tumours.<sup>1</sup> Tumour embolization refers to any procedure performed either percutaneously, through a direct puncture of the tumour (DPT), or via a trans-arterial approach, in which embolic material is injected with the goal of reducing tumour vascularity, hence, minimizing morbidity and improving chances of successful tumour resection.<sup>1</sup> The latter is facilitated through necrotic softening of the tumour, making it more easily resectable.<sup>3</sup>

Embolization of extra-axial tumours such as meningiomas, performed in the territory of external carotid artery (ECA), is generally safer than embolization of intra-axial tumours such as haemangioblastoma, which derive their vascular supply from internal carotid artery (ICA) or vertebrobasilar artery (VBA).<sup>2</sup> Most commonly employed embolizates include particles such as Poly Vinyl Alcohol (PVA) and trisacryl gelatin microspheres (TAGM), as well as liquid embolic agents such as Onyx and N-Butyl Cyanoacrylate (NBCA).<sup>3</sup> There are multiple objectives for pre-operative devascularization of the tumour, the most important being minimizing blood loss, and decreasing operating time. Other benefits include their use in palliation, by decreasing

<sup>1</sup>Final Year Student, Jinnah Sindh Medical University, <sup>2-4</sup>The Aga Khan University Hospital, Karachi, Pakistan.

**Correspondence:** Muhammad Shahzad Shamim. e-mail: shahzad.shamim@aku.edu



**Figure:** A) and B), Digital subtraction angiogram, pre and post embolization lateral views, of a meningioma supplied by the ECA.

tumour size and reducing pain in patients not fit for surgery.<sup>1</sup>

However, some authors have questioned the utility of PEm, in the light of questionable cost-effectiveness and the risk of post-procedural complications. In this paper, we have reviewed the technical efficacy, safety, and outcomes of pre-operative brain tumour embolization.

### Review of Literature

Kubota et al., published a case of a patient undergoing surgery for a huge, right-sided tentorial epithelioid haemangi endothelioma (E-HE), in which authors had to abort surgery due to haemorrhage. The patient underwent embolization with PVA of the right ECA partially feeding the tumour five days before second surgery. Subsequent gross-total removal of the tumour was relatively bloodless, and no recurrence was reported even nine years later, suggesting PEm to be rational in cases of E-HE.<sup>4</sup> Duffis et al., proposed their highly cited guidelines for embolization in 2012.<sup>1</sup> Non-invasive imaging was suggested to allow delineation of the extent of tumour and digital subtraction angiography (DSA), along with super-selective catheterization of ECA was recommended to allow for identification of displaced feeders, presence of collateral flow distal to the involved carotid; and to reveal intracranial anastomoses. Tumour blush was proposed as a radiologic measure of procedural efficacy. According to the authors, tumour resection within 24 hours of embolization was to be avoided and a delay of 1 to 8 days from embolization was recommended. However, the timing for surgery after embolization remains controversial and some authors advocate resecting the neoplasm immediately, or within a

day, to avoid potential worsening of peritumoral oedema.<sup>5</sup> Steroid use was also advised in tumours at risk of post-embolization oedema.

Wang et al., published the outcome of PEm in eight paediatric brain tumour patients over eight years, and reported good results with embolization as a surgical adjunct.<sup>2</sup> Embolization was done with either NBCA or TAGM. Four out of the eight cases were of choroid plexus papilloma, and two of these patients, both embolized with TAGM, developed tumour bleeds.<sup>2</sup> Hanak et al., retrospectively reviewed 15 patients, who underwent 17 PEm for haemangiopericytomas (HPC) at two centers. More extensive devascularization was achieved for HPCs with primarily ECA blood supply, than those with ICA/VBA circulation. The authors reported an average time interval of 2.2 days between embolization and surgery, with no greater than 500 ml blood loss in tumours that achieved 80% devascularization. The authors, however, did not notice any significant difference in gross total removal of embolized versus non-embolized tumours.<sup>3</sup>

In a systematic review of PEm for intradural spinal haemangioblastoma (HB), Ampie et al., analyzed 29 reported cases. The most commonly utilized embolisate was (PVA), followed by TAGM and NBCA. Excellent rates of gross total resection (GTR) were reported, with estimated blood loss (EBL) averaging up to 187.5 ml. Complications from embolization and surgery were minimal, with no deaths or permanent neurological morbidity. The authors, however, noted excellent outcomes from microsurgery alone from historical series, questioning the rationale behind PEm.<sup>6</sup> In another systematic review for intracranial HB, Ampie et al., reported that PEm did not increase GTR rates and failed to reduce blood loss and complications, rather itself significantly carrying the aforementioned risks. In a total of 111 patients compared to 392 non embolized ones, GTR was achieved in 83.7% and 95.6% of the patients, respectively. Intraoperative blood transfusion was required in 15.3% of embolized and 0.51% of non-embolized controls, while rates of postoperative haemorrhage were 8.4% and 1.6%, respectively. Complication rates from embolization were 11.7% and following consequent surgery were 20.7%, deeming PEm as inconsequential in the authors' view.<sup>5</sup>

Ampreechakul et al., examined the efficacy of PEm in a retrospective analysis of 37 tumours, which included 18 meningiomas, six haemangioblastomas, and six haemangiopericytomas, among others.<sup>7</sup> Indications to embolize included bleeding diatheses, hypervascular tumour type, presence of multiple flow-voids on MRI, deep-seated tumours, and tumours with intratumoral aneurysms. Failure of PEm occurred in four patients and

median time to surgery after PEm was seven days. Statistically significant negative correlation of angiographic devascularization percentage and EBL was noticed, proving the former to be the only true predictor of procedural efficacy. In a prospective study of 14 patients, Gruber et al., described longitudinal image changes in supratentorial hemispheric meningiomas based on MRI after PEm using calibrated microspheres. The authors reported sustainable tissue transformation and significant decrease in specific parameters such as baseline apparent diffusion coefficient; baseline mean ratios of relative cerebral blood volume, relative cerebral blood flow, and viable enhanced baseline mean tumour volume, within 6 hours and 48 hours of embolization.<sup>8</sup>

More recently, Barros et al., published their retrospective analysis of 139 meningiomas, describing anatomic locations and vascular supplies to identify characteristics predictive of successful PEm. Seventy-eight percent of tumours were successfully embolized, with a 2.8% periprocedural complication rate. Within the subset of patients with successful embolization, 31% achieved complete angiographic embolization. Significant multivariate predictors of embolization were meningo-hypophyseal trunk, middle meningeal artery, and ascending pharyngeal artery supply, as well as convexity or parasagittal location, the latter two most likely to achieve complete angiographic embolization.<sup>9</sup>

Duffis et al., reported stroke and intracerebral haemorrhage in up to 3-6% cases of PEm. While both particulate and liquid embolisates were used, the former was linked to greater complication rates, a notion supported by Wang et al., too.<sup>1,2</sup> In another study with intradural spinal HB cases undergoing PEm, transient post-embolization complications were rare, and included swallowing difficulty (3.5%), decreased position sense (3.5%), and spasticity (3.5%).<sup>6</sup> However, in the cerebellar subset of the same tumour, complications were more common, and included post-procedural haemorrhage, ischaemic infarcts, dysarthria, hemiparesis, and hemisensory impairment, although mortality rates were not significantly different compared to non-embolized cohort.<sup>5</sup> In their retrospective review of 39 patients, Tanaka et al., described five patients with worsening of existing neurological symptoms, explained as an inflammatory response, a condition they termed as post-embolization neurological syndrome (PENS).<sup>10</sup> In another retrospective analysis of PEm in meningioma patients by Barros et al., the authors reported three procedure-related complications including middle meningeal artery that required coiling; self-resolved catheter-induced vasospasm, and a cervical ICA dissection.<sup>9</sup>

## Conclusion

PEm of hypervascular brain tumours has a high technical success rate as a surgical adjunct, but also carries a reasonable risk of complications. The authors therefore recommend judicious utilization of this treatment adjunct.

## References

1. Duffis EJ, Gandhi CD, Prestigiacomo CJ, Abruzzo T, Albuquerque F, Bulsara KR, et al. Head, neck, and brain tumor embolization guidelines. *J. Neurointerv. Surg.* 2012;4:251-5.
2. Wang HH, Luo CB, Guo WY, Wu HM, Lirng JF, Wong TT, et al. Preoperative embolization of hypervascular pediatric brain tumors: evaluation of technical safety and outcome. *Official journal of the International Society for Pediatric Neurosurgery. Childs Nerv Syst* 2013;29:2043-9.
3. Hanak BW, Haussen DC, Ambekar S, Ferreira M, Jr., Ghodke BV, Peterson EC. Preoperative embolization of intracranial hemangiopericytomas: case series and introduction of the transtumoral embolization technique. *J. Neurointerv. Surg.* 2016;8:1084-94.
4. Kubota T, Sato K, Takeuchi H, Handa Y. Successful removal after radiotherapy and vascular embolization in a huge tentorial epithelioid hemangioendothelioma: a case report. *J Neuro-oncol.* 2004;68:177-83.
5. Ampie L, Choy W, Lamano JB, Kesavabhotla K, Kaur R, Parsa AT, et al. Safety and outcomes of preoperative embolization of intracranial hemangioblastomas: A systematic review. *Clin. Neurol. Neurosurg.* 2016;150:143-51.
6. Ampie L, Choy W, Khanna R, Smith ZA, Dahdaleh NS, Parsa AT, et al. Role of preoperative embolization for intradural spinal hemangioblastomas. *J. Clin. Neurosci: official journal of the Neurosurgical Society of Australasia.* 2016;24:83-7.
7. Iampreechakul P, Tirakotai W, Lertbutsayanukul P, Siriwimonmas S, Liengudom A. Pre-operative Embolization of Intracranial and Extracranial Tumors: A Review of 37 Cases. *J Med Assoc Thai.* 2016;99 Suppl 3:S91-119.
8. Gruber P, Schwyzer L, Klinger E, Burn F, Diepers M, Anon J, et al. Longitudinal Imaging of Tumor Volume, Diffusivity, and Perfusion After Preoperative Endovascular Embolization in Supratentorial Hemispheric Meningiomas. *World Neurosurg.* 2018;120:e357-e64.
9. Barros G, Feroze AH, Sen R, Kelly CM, Barber J, Hallam DK, et al. Predictors of preoperative endovascular embolization of meningiomas: subanalysis of anatomic location and arterial supply. *J. Neurointerv. Surg.* 2020;12:204-8.
10. Tanaka Y, Hashimoto T, Watanabe D, Okada H, Kato D, Aoyagi S, et al. Post-embolization neurological syndrome after embolization for intracranial and skull base tumors: transient exacerbation of neurological symptoms with inflammatory responses. *Neuroradiol.* 2018; 60: 843-51.