



# High Grade Glioma Surgery – Clinical Aspects and Prognosis

Milan Mladenovski, Iliya Valkov, Mladen Ovcharov, Nikolay Vasilev, Iliya Duhlenki

*Clinic of Neurosurgery, Medical University of Pleven, Pleven, Bulgaria*

**Corresponding author:** Milan Mladenovski, Clinic of Neurosurgery, Medical University of Pleven, 1 St Kliment Ohridski St., 5800 Pleven, Bulgaria;  
E-mail: mladenovskinhk@gmail.com; Tel.: +359 877 778 926

**Received:** 9 June 2020 ♦ **Accepted:** 4 Sep 2020 ♦ **Published:** 28 Feb 2021

**Citation:** Mladenovski M, Valkov I, Ovcharov M, Vasilev N, Duhlenki I. High grade glioma surgery – clinical aspects and prognosis. *Folia Med (Plovdiv)* 2021;63(1):35-41. doi: 10.3897/folmed.63.e55255.

## Abstract

**Introduction:** High grade gliomas (HGG) are a group of tumors with infiltrative nature in general. Surgery is the first step in their treatment. It can be beneficial in two aspects: firstly, in establishing normal intracranial pressure and, secondly, in reducing the tumour volume. The choice of method depends on the location of the lesion, the expected grade of malignancy, and the general condition of the patient. Despite constant development of neuro-oncology and microsurgical techniques, the 5-year survival rate in patients with HGG remains less than 10% and the median survival is still less than 2 years.

**Aim:** At present, there is no final therapeutic “segment” to provide a better outcome than the complex treatment of HGG. Moreover, the treatment’s relative efficacy and recurrence of these tumours carry an additional problem. The aim of this study was to estimate the overall survival of patients with HGG operated in our clinic and compare it with literature data.

**Materials and methods:** One hundred twenty-one cranial operations for HGG were reviewed (conducted between 2014 and 2019). Summary characteristics of the various parameters were presented in respect to the radical nature of the operative intervention using Kaplan-Meier analysis and chi square tests. All patients were followed up at regular check-ups.

**Results:** HGGs were 103 or 85.12% of all gliomas operated for the 2014-2019 period. The most common cases were in the 51 to 60 age group. The cases in men were twice as common. The most common localization of the neoplasm is in the temporal region (36.36%) and the rarest was found in the occipital region (3.30%). It was estimated that our operated patients with HGG had 12.23 months overall survival. Gross total resected patients had a median survival (OS) of 14.53 months, while subtotal resected patients had a median survival (OS) of 10.44 months. It is estimated 7.97 months free tumor survival period (time to relapse - FTS) for our operated patients with HGG. Gross total resected patients had a median FTS of 10.88 months, while subtotal resected patients had median FTS of 5.70 months. We noticed permanent new neurological deficit (NND) in 20 patients (19.45%) operated with GTR, and in 5 patients (4.85%) operated with STR.

**Conclusions:** Median survival - OS, free tumor survival period - FTS and new neurological deficit - NND were statistically significant ( $p < 0.05$ ) with extent of resection – GTR or STR in our study. Maximal safe radical (total) or supratotal resection is preferred in treating HGG.

## Keywords

extent of resection, gross total, high grade glioma, prognosis, subtotal resection

## INTRODUCTION

High grade gliomas (HGG) are a group of tumors with infiltrative nature in general. Traditionally, they have been divided into primary and secondary (arising de novo (90%) and developed from a pre-existing lower grade tumor (10%)). High grade gliomas account for 15% of all intracranial neoplasms and approximately 50% of all astrocytomas. HGGs can arise anywhere within the brain; they have a predilection for the subcortical white matter and deep grey matter of the cerebral hemispheres, particularly the temporal lobe. They have a tendency to undergo cystic degeneration with resultant intratumoural necrosis and hemorrhages. The vast majority of HGGs are sporadic. Rarely, they are related to prior radiation exposure (radiation-induced GBM). Surgery can be beneficial in two aspects of HGGs treatment: to establish the normal intracranial pressure and to reduce the tumour volume. The choice of method depends on the location of the lesion, the expected grade of malignancy/infiltration, and the general condition of the patient. Despite constant development of neuro-oncology and microsurgical techniques, the 5-year survival rate in patients with high grade gliomas remains less than 10% and the median survival is still less than 2 years.<sup>1,2</sup> However, patients with extensive resection and adjunctive therapy such as radiation and temozolamide (TMZ) chemotherapy show a longer survival.<sup>3</sup> Accumulated knowledge of the glioblastoma significant molecular, immunohistochemical and gene heterogeneity, make prognostic expectations less enthusiastic.<sup>4</sup>

## AIM

At present, there is no final therapeutic “segment” to provide a better outcome than the complex treatment of HGG. Moreover, the treatment relative efficacy and recurrence of these tumors present some additional problems. The aim of this study was to estimate the overall survival of patients with HGG operated in our clinic and compare it with literature data.

## MATERIALS AND METHODS

Operative surgery reports from 2014 to 2019 were reviewed. One hundred twenty-one cranial operations for HGG were reviewed. All craniotomies were planned by using four methods: craniometric points, CT scans/topograms, MRI scans/topograms, and intraoperative real-time ultrasonography.<sup>5</sup> Summary characteristics of the various parameters were presented in respect to the radical nature of the operative intervention using Kaplan-Meier analysis and chi square tests. All patients were followed up at regular check-ups (1 month, 3 month, 1<sup>st</sup> year, 2<sup>nd</sup> year, 3<sup>rd</sup> year) estimating the clinical status.

## RESULTS

HGGs were 103 or 85.12% of all gliomas operated for the study period. The most common cases are in the 51 to 60 age group. The cases in men were twice as common. In 64.46% of cases, the patient's condition was assessed by 90 points on the Karnofsky scale. Classic clinical presentation was presented in all cases. The most common localization of the neoplasm was in the temporal region (36.36%) and the rarest one was in the occipital region (3.30%). Infratentorial localization was identified in 1.66% of cases. Eloquent brain areas were affected by 60.33% of neoplasms, 36.36% of tumours were >6 cm in their largest diameter. Twelve (09.91%) reoperations were performed (see **Table 1 and 2**).

## DISCUSSION

HGG surgical resection appears to be vital. A cause for future recurrences is the existence of viable tumor cells over and above the enhancing tumor margins. This suggests why surgical resection is more useful as part of multimodal treatment.<sup>6,7</sup>

The impact of HGG surgery is a constant debate among neurosurgeons. The infiltrative nature of HGG makes unimaginable the curative resection. The recurrence delay and prolonging the OS is likely due to a wider margin resection coupled with adjuvant therapy.<sup>1,2,7</sup>

Stummer et al. described the influence on the survival using 5-aminolevulinic acid (ALA) in HGG tumor surgery.<sup>8</sup> The authors reported for comparison of cytoreductive surgery using 5-ALA (n=161) versus conventional white light microscopy (n=161). The researchers concluded that surgical resection using 5-ALA facilitates more complete resections of contrast-enhancing tumour.

Lacroix et al.<sup>9</sup> described 416 patients operated for glioblastoma over a 6-year period. Pre- and post-operative assessment of tumour volume was done using computer image analyses. The authors reported 5 independent predictors of survival: age, KPS, extent of tumor resection, and the amount of necrosis and enhancement on preoperative MRI studies. Resection of 98% or more of the tumor was associated with significant survival advantage [(13 months versus 8.8 months median survival in patients operated with gross total resection (98% or greater)] and less than 98% resection respectively ( $p=0.02$ ). This study supports the concept of aggressive cytoreductive surgery as part of the management of high grade gliomas.

Maximal safe tumour resection is the correct surgical treatment of glioblastomas and other HGG gliomas. Technological development in the OR is improved by neuronavigation, awake craniotomy and supratotal resection by fluorescence microscopy (not applied in the clinic).<sup>10-17</sup> However, no extremely significant improvement in the OS through the use of these technologies has been achieved.

**Table 1.** Summary of characteristics in 121 patients harbouring glial tumors

Characteristic	No (%)
Age (years)	
>60	40 (33.05)
51-60	49 (40.49)
41-50	20 (16.52)
31-40	9 (07.43)
0-30	3 (02.47)
Age at operation (years)	
Median	47.5 (/)
Range	14-81 (/)
Female	44 (36.36)
Male	77 (63.64)
Karnofsky scale (KPS score preoperative)	
100	12 (09.91)
90	78 (64.46)
80	21 (17.35)
<80	10 (08.26)
History of seizures	44 (36.36)
Cognitive deficit	80 (66.11)
Headache, dizziness, vomiting	50 (41.32)
Neurological deficit	37 (30.57)
Neoplasm location	
Frontal	31 (25.61)
Temporal	44 (36.36)
Parietal	23 (19.01)
Insular	19 (15.70)
Occipital	4 (03.30)
Supratentorial location	119 (98.34)
Infratentorial location	2 (01.66)
Eloquent zone	73 (60.33)
Maximal tumor diameter in cm	
Median	5.1 (/)
Range	1.4-11 (/)
Tumor diameter in cm	
>6	44 (36.36)
4.1-6.0	38 (31.40)
2.1-4.0	35 (28.92)
<2.0	4 (03.30)
Reoperations	12 (09.91)
Low grade gliomas	18 (14.88)
High grade gliomas	103 (85.12)
	88 glioblastomas
	7 gliosarcomas
	3 astrocytomas grade III
	3 oligodendrogliomas grade III
	2 medulloblastomas

HGG reoperation has also been debated in the neurosurgical society and there are many studies showing improvement of survival with re-resection.<sup>18,19</sup> Surgical resection of glioblastoma and other HGGs recidivisms should be seriously considered in terms of quality of life and median survival. Chemotherapy with bevacizumab (inhibits angiogenesis) is the only widely accepted non-surgical treatment for recurrent gliomas.<sup>15</sup>

HGG treatment is a complex strategy including: surgical tumor resection, radiation therapy, chemotherapy (temozolamide, bevacizumab) and other investigational therapies.

TTF or tumor treating fields (FDA-approved 2015) - Increase 2-year survival from 29% (radiotherapy + TMZ) to 43% in patients treated with TTF in satisfactory postoperative status. Other methods and therapies remain unclear or are still unproven.<sup>3</sup>

Our results (following the country's comprehensive treatment algorithm for this pathology) are poorer in terms of postoperative survival as reported in highly specialized neuro-oncology centres in America and Europe (24-months median survival).<sup>1,12,13,16</sup> Post-operative survival of at least 24 months with a high quality of life reaches 58% of the patients operated in San Francisco.<sup>1,2</sup>

It is clear that effective methods for the treatment of HGG will be more likely to be found in the scientific laboratories than in ORs. Unfortunately, the biological and molecular HGG heterogeneity (even in the same tumour) is a significant barrier for effective therapies.<sup>20</sup>

The ultimate goal of surgery remains the radical (under fluoroscopic microscopy - supratotal) resection and the preservation of brain functions at the same time. Any neurological deficit postoperatively leads to an undesirable risk/benefit ratio for the patient.<sup>12-14</sup>

Molecular biology and immunology have found molecular markers (MGMT, methyl-guanine-methyl-transferase gene, docking receptors) that are of prognostic significance, thus making conventional histological diagnosis inadequate today. More aggressive treatment is needed to improve the median survival for glioblastoma and other HGGs. More efforts are still needed to provide hope for patients, though it is not clear how to achieve this.

## CONCLUSION

Maximal safe radical (total) or supratotal resection is preferred in treating HGG. In our study, the extent of the tumour resection is a statistically significant advantage that influences the median survival, free tumor survival period, and new neurological deficit. After 30 years of researching, the prognosis for HGG patients is still disappointing. New and original approaches originating from scientific laboratories are needed. It seems reasonable to start with a proposal for all patients to be included in clinical trials.

**Table 2.** Summary results (median survival, time to diagnosed relapse, new neurological deficit, and postoperative Karnofsky performance scale) in correlation with type of resection - GTR or STR

Resection type of HGG	GTR (radical )	STR (subtotal)
No (%)	45 (43.68)	58 (56.32)
OS Median	14.5 months	10.4 months
FTS Median	10.8 months	7.9 months
NND (permanent)	20 (19.45)	5 (4.85)
KPS score (post-op.)	>80 = 17 <80 = 28	>80 = 41 <80 = 17

OS: overall survival rate (in months) or median survival rate; FTS: free tumor survival rate; NND (permanent): permanent new neurological deficit; KPS: Karnofsky performance score.

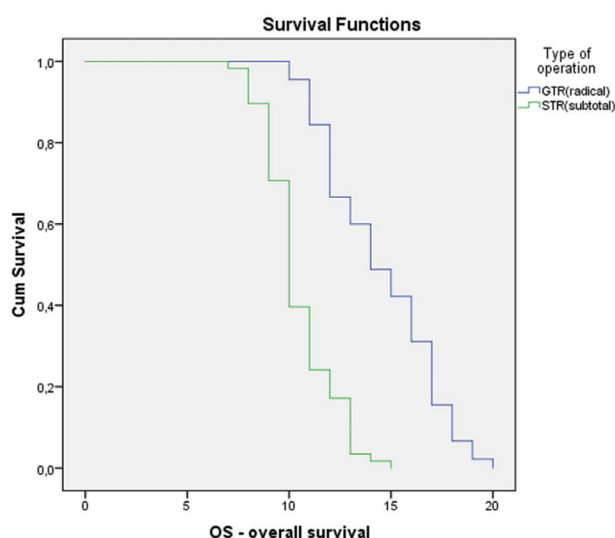
Median survival (OS), free tumor survival period (FTS) and new neurological deficit (NND) are statistically significant ( $p < 0.05$ ) with extent of resection – GTR or STR. See **Tables 3, 4, and 5.**

**Table 3.** Kaplan-Meier analysis for overall survival

Type of operation	Means and medians for survival time							
	Mean <sup>a</sup>				Median			
	Estimate	Std. error	95% Confidence interval		Estimate	Std. error	95% Confidence interval	
		Lower bound	Upper bound			Lower bound	Upper Bound	
GTR (radical)	14.533	0.411	13.727	15.340	14.000	0.838	12.357	15.643
STR (subtotal)	10.448	0.224	10.009	10.888	10.000	0.207	9.594	10.406
Overall	12.233	0.297	11.652	12.814	12.000	0.380	11.254	12.746

**Overall Comparisons**

	Chi-Square	df	Sig.
Log Rank (Mantel-Cox)	54.502	1	0.000



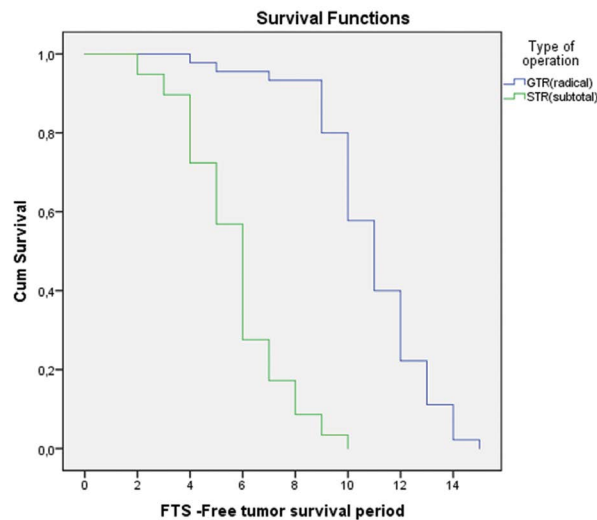
Our operated patients with HGG were estimated to have 12.23 months of overall survival. Gross total resected patients had median survival (OS) of 14.53 months, while subtotal resected patients had median survival (OS) of 10.44 months. Long Rank (Mantel-Cox) comparisons show significance for radical resection.

**Table 4.** Kaplan-Meier analysis for free tumor survival period

Type of operation	Means and medians for free tumor survival period							
	Mean <sup>a</sup>				Median			
	Estimate	Std. error	95% Confidence interval		Estimate	Std. error	95% Confidence interval	
		Lower bound	Upper bound			Lower bound	Upper Bound	
GTR (radical)	10.889	0.329	10.244	11.534	11.000	0.411	0.411	11.805
STR (subtotal)	5.707	0.248	5.220	6.194	6.000	0.200	0.200	6.392
Overall	7.971	0.323	7.337	8.605	8.000	0.722	0.722	9.415

	Chi-Square	df	Sig.
Log Rank (Mantel-Cox)	82.143	1	0.000



The HGG patients we operated were estimated to have 7.97 months of free tumor survival period (time to relapse). The gross total resected patients had median FTS of 10.88 months, while subtotal resected patients had median FTS of 5.70 months. Long Rank (Mentel-Cox) comparisons shows significance for radical resection.

**Table 5.** Correlation between type of operation and patients' new neurological deficit

Type of operation		NND - new neurological deficit		Total
		Yes	No	
GTR(radical)	Count	20	25	45
	% within type of operation	44.4%	55.6%	100.0%
	% within NND	80.0%	32.1%	43.7%
STR(subtotal)	Count	5	53	58
	% within type of operation	8.6%	91.4%	100.0%
	% within NND	20.0%	67.9%	56.3%
Total	Count	25	78	103
	% within type of operation	24.3%	75.7%	100.0%
	% within NND	100.0%	100.0%	100.0%

**Chi-Square Tests**

	Value	df	Asymptotic Significance (2-sided)	Exact Significance (2-sided)	Exact Significance (1-sided)
Pearson Chi-square	17.692 <sup>a</sup>	1	0.000		
Continuity correction <sup>b</sup>	15.797	1	0.000		
Likelihood ratio	18.271	1	0.000		
Fisher's exact test				0.000	0.000
Linear-by-linear association	17.521	1	0.000		
N of valid cases	103				

Fisher exact test ( $p < 0.001$ ) shows significance of getting temporary NND after gross total resection. Patients operated with GTR had 44.4% chances to get NND, while patients operated with STR had 8.6% chances to get NND. We noticed permanent NND reducing twice in our cohort [20 patients (19.45%) operated with GTR, and in 5 patients (4.85%) operated with STR]. This percentage could be reduced by using neuronavigation, awake craniotomy and supratotal resection by fluorescence microscopy (not applied in the clinic).

## REFERENCES

1. Sanai N, Berger MS. Surgical oncology for gliomas: the state of the art. *Nat Rev Clin Oncol* 2018; 15(2):112–25.
2. Sanai N, Polley MY, McDermott MW, et al. An extent of resection threshold for newly diagnosed glioblastomas. *J Neurosurg* 2011; 115(1):3–8.
3. Stupp R, Taillibert S, Kanner AA, et al. Maintenance therapy with tumor-treating fields plus temozolomide vs temozolomide alone for glioblastoma: a randomized clinical trial. *JAMA* 2015; 314(23):2535–43.
4. Louis DN, Perry A, Reifenberger G, et al. The 2016 World Health Organization classification of tumors of the central nervous system: a summary. *Acta Neuropathol* 2016; 131(6):803–20.
5. Mladenovski M, Vasilev V, Ovcharov M, et al. Basic neuronavigation options for cortical and subcortical brain lesions surgery. *J Biomed Clin Res* 2018; 11(2):141–9.
6. Laws Jr ER. Radical resection for the treatment of glioma. *Clin Neurosurg* 1995; 42:480–7.
7. Pang B-C, Wan W-H, Lee C-K, et al. The role of surgery in high-grade glioma – is surgical resection justified? a review of the current knowledge. *Ann Acad Med Singapore* 2007; 36:358–63.
8. Stummer W, Pichlmeier U, Meinel T, et al. Fluorescence-guided surgery with 5-aminolevulinic acid for resection of malignant glioma: a randomised controlled multicentre phase III trial. *Lancet Oncol* 2006; 7(5):392–401.
9. Lacroix M, Abi-Said D, Fourney DR, et al. A multivariate analysis of 416 patients with glioblastoma multiforme: prognosis, extent of resection, and survival. *J Neurosurg* 2001; 95(2):190–8.
10. Ferracci FX, Duffau H. Improving surgical outcome for gliomas with intraoperative mapping. *Exp Rev Neurother* 2018; 18:333–41.
11. Southwell DG, Hervey-Jumper SL, Perry DW, et al. Intraoperative mapping during repeat awake craniotomy reveals the functional plasticity of adult cortex. *J Neurosurg* 2016; 124:1460–9.
12. Stummer W, Suero Molina E. Fluorescence imaging/agents in tumor resection. *Neurosurg Clin N Am.* 2017; 28:569–83.
13. Duffau H. Is supratotal resection of glioblastoma in noneloquent areas possible? *World Neurosurg.* 2014; 82:e101–3.
14. Eseonu CI, ReFaey K, Garcia O, et al. Volumetric analysis of extent of resection, survival, and surgical outcomes for insular gliomas. *World Neurosurg* 2017; 103:265–74.
15. Omuro A, DeAngelis LM. Glioblastoma and other malignant gliomas: a clinical review. *JAMA* 2013; 310(17):1842–50.
16. Hervey-Jumper SL, Li J, Lau D, et al. Awake craniotomy to maximize glioma resection: methods and technical nuances over a 27-year period. *J Neurosurg* 2015; 123(2):325–39.
17. Schatlo B, Fandino J, Smoll NR, et al. Outcomes after combined use of intraoperative MRI and 5-aminolevulinic acid in high-grade glioma surgery. *Neuro Oncol* 2015; 17(12):1560–7.
18. Helseth R, Helseth E, Johannesen TB, et al. Overall survival, prognostic factors, and repeated surgery in a consecutive series of 516 patients with glioblastoma multiforme. *Acta Neurol Scand* 2010; 122:159–67.
19. Sughrue ME, Sheean T, Bonney PA, et al. Aggressive repeat surgery for focally recurrent primary glioblastoma: outcomes and theoretical framework. *Neurosurg Focus* 2015; 38(3):E11.
20. Furnari FB, Fenton T, Bachoo RM, et al. Malignant astrocytic glioma: genetics, biology, and paths to treatment. *Genes Dev* 2007; 21(21):2683–710.

# Хирургия глиомы высокой степени злокачественности – клинические аспекты и прогноз

Милан Младеновски, Илия Валков, Младен Овчаров, Николай Василев, Илия Духленски

Клиника нейрохирургии, Медицинский университет – Плевен, Плевен, Болгария

**Адрес для корреспонденции:** Милан Младеновски, Клиника нейрохирургии, Медицинский университет – Плевен, ул. „Св. Климент Охридски“ № 1, 5800 Плевен, Болгария; E-mail: mladenovskinhk@gmail.com; Тел.: +359 877 778 926

**Дата получения:** 9 июня 2020 ♦ **Дата приемки:** 4 сентября 2020 ♦ **Дата публикации:** 28 февраля 2021

**Образец цитирования:** Mladenovski M, Valkov I, Ovcharov M, Vasilev N, Duhlenki I. High grade glioma surgery – clinical aspects and prognosis. Folia Med (Plovdiv) 2021;63(1):35-41. doi: 10.3897/folmed.63.e55255.

## Резюме

**Введение:** Глиомы высокой степени злокачественности (ГВСЗ) – это группа опухолей инфильтративного характера. Хирургия – это первый шаг в их лечении. Это может быть полезно двумя способами: во-первых, для установления нормального внутричерепного давления, а во-вторых, для уменьшения объёма опухоли. Выбор метода зависит от локализации поражения, ожидаемой степени злокачественности и общего состояния пациента. Несмотря на постоянное развитие методов неврологической онкологии и микрохирургии, 5-летняя выживаемость у пациентов с ГВСЗ остаётся ниже 10% уровня, а средняя выживаемость всё ещё составляет менее 2 лет.

**Цель:** В настоящее время не существует терапевтического «сегмента», обеспечивающего лучший результат, чем комплексное лечение ГВСЗ. Кроме того, дополнительной проблемой является относительная эффективность лечения и рецидивы этих опухолей. Целью данного исследования было оценить общую выживаемость пациентов с ГВСЗ, прооперированных в нашей клинике, и сравнить её с данными в научной литературе.

**Материалы и методы:** Проанализировано сто двадцать одна операция ГВСЗ (проведённых в период с 2014 по 2019 год). Обзорные характеристики различных параметров относительно радикального характера хирургического вмешательства были представлены с использованием анализа Каплана-Мейера и критерия хи-квадрат ( $\chi^2$ ). Все пациенты проходили регулярные осмотры.

**Результаты:** В период 2014-2019 гг. было прооперировано 103 случая ГВСЗ или 85.12% от всех глиом. Наиболее частые случаи были в возрастной группе от 51 до 60 лет. Случаи среди мужчин были вдвое чаще. Наиболее частая локализация новообразования – височная область (36.36%), наиболее редкая – в затылочной области (3.30%). Был сделан вывод, что общая выживаемость наших прооперированных пациентов с ГВСЗ составила 12.23 месяца. Пациенты, перенесшие полную резекцию (ПР), имели выживаемость (ОВ) 10.44 месяца. Для наших оперированных пациентов с ГВСЗ период общей выживаемости (free tumor survival period (FTS) составил 7.97 месяцев, а пациенты с полной резекцией опухоли имели средний FTS – 10.88 месяцев, в то время как пациенты с субтотальной резекцией (СТР) имели средний FTS – 5.70 месяцев, и мы обнаружили стойкие новые неврологические дефициты (ННД) у 20 пациентов (19.45%), прооперированных на ГВСЗ, и у 5 пациентов (4.85%), прооперированных с СТР.

**Заключение:** Общая выживаемость, период FTS и новый неврологический дефицит – ННД были статистически значимыми ( $p < 0.05$ ) со степенью резекции – ТР или СТР в нашем исследовании. Максимальная радикальная (тотальная) или субтотальная резекция предпочтительнее при лечении ГВСЗ.

## Ключевые слова

степень резекции, общий объём, глиома высокой степени, прогноз, субтотальная резекция