



Case Report

Pulsed reduced dose-rate radiotherapy for previously irradiated tumors in the brain and spine

Arpan V. Prabhu¹, Madison Lee², Edvaldo Galhardo¹, Madison Newkirk¹, Analiz Rodriguez², Fen Xia¹

Departments of ¹Radiation Oncology and ²Neurological Surgery, University of Arkansas for Medical Sciences, Little Rock, Arkansas, United States.

E-mail: Arpan V. Prabhu - avprabhu@uams.edu; Madison Lee - mplee@uams.edu; Edvaldo Galhardo - edvaldo.galhardo@gmail.com; Madison Newkirk - mnewkirk@uams.edu; Analiz Rodriguez - arodriguez@uams.edu; *Fen Xia - FXia@uams.edu



*Corresponding author:

Fen Xia, M.D., Ph.D.,
Chair and Professor,
Department of Radiation
Oncology, University of
Arkansas for Medical Sciences,
UAMS Winthrop P. Rockefeller
Cancer Institute. Little Rock,
AR 72205, USA.

FXia@uams.edu

Received : 29 August 2020

Accepted : 27 April 2021

Published : 14 June 2021

DOI

10.25259/SNI_589_2020

Quick Response Code:



ABSTRACT

Background: Patients with unresectable locoregional cancer recurrences have limited management options. Re-irradiation increases the risk of toxicity, particularly when perilesional dose-volume constraints are exceeded. We present and discuss two cases of previously irradiated tumors in the central nervous system (CNS) that was re-irradiated using the pulsed reduced dose-rate radiotherapy (PRDR) technique.

Case Description: A 58-year-old female with a history of metastatic small cell lung cancer to the brain status post multiple rounds of radiation and chemotherapy presented with increasing weakness in her right arm and leg. Magnetic resonance imaging (MRI) revealed a growly peripherally enhancing 1.2 cm mass in the left precentral gyrus that had previously received prophylactic cranial irradiation and stereotactic radiosurgery. The patient was re-irradiated with 35 Gy in 100 fractions over 3 weeks, using PRDR with improved motor function at 3-month follow-up. A 41-year-old male with recurrent glioblastoma of the thoracic spinal cord presented with worsening neurological symptoms, including inability to ambulate due to bilateral leg weakness, causing wheelchair use. MRI thoracic spine revealed a recurrent thoracic lesion 2.2 × 1 × 0.8 cm. In addition to chronic chemotherapy, the patient was retreated palliatively in the same area at 50 Gy in 250 fractions, over 6 weeks, using PRDR. The treated lesion was stable on follow-up imaging, and the patient was able to walk with the assistance of a walker.

Conclusion: In our two cases, PRDR proved effective in the treatment of recurrent malignant CNS tumors that were previously irradiated. Prospective studies are needed to delineate the efficacy and toxicity of PRDR.

Keywords: Glioblastoma multiforme, Metastatic cancer, Pulsed reduced dose-rate radiotherapy, Reirradiation, Small cell lung cancer

INTRODUCTION

Patients with unresectable locoregional recurrence of their cancer have management options, including supportive care only, chemotherapy alone, or re-irradiation with or without concurrent chemotherapy.^[21] Treatment with re-irradiation of previously radiated lesions may increase the risk of toxicities as the radiation tolerances of structures are exceeded.^[24]

Pulsed reduced dose-rate radiotherapy (PRDR) is a relatively novel radiation technique that was developed at the University of Wisconsin to treat recurrent malignant lesions.^[4,24] PRDR breaks treatment into a number of subfractions, delivering radiation pulses of 0.2 Gray (Gy) separated by 3-min intervals slowly over a period of 45–60 min each day of treatment, creating an apparent low dose rate treatment regime. Its effectiveness has been studied in a variety of

This is an open-access article distributed under the terms of the Creative Commons Attribution-Non Commercial-Share Alike 4.0 License, which allows others to remix, tweak, and build upon the work non-commercially, as long as the author is credited and the new creations are licensed under the identical terms.

©2021 Published by Scientific Scholar on behalf of Surgical Neurology International

human cell lines^[8,10-14,28,29,33] and is theorized to stem from the fixed time interval normal tissues are provided to repair sublethal damage.^[7,18] PRDR reirradiation has been reported as a feasible treatment option with reasonable toxicity for recurrent large volume central nervous system (CNS) tumors.^[21]

In this manuscript, we describe two cases in which the CNS tumor is located within the eloquent brain and the intramedullary spine, respectively, not allowing for safe surgical resection. Both patients had clinical neurologic improvement, indicating that PRDR is a reasonable approach even in locations where toxicity can cause potential significant neurologic deficits.

CLINICAL PRESENTATION

Case 1

A 58-year-old female with a history of metastatic small cell lung cancer (SCLC) with known recurrent brain metastases and bone metastases status post multiple rounds of radiation and chemotherapy treatments presented with weakness in her right arm and leg, lethargy, and confusion over 1 week. Magnetic resonance imaging (MRI) revealed a growing peripherally enhancing 1.2 cm mass (0.8 cm 2 months prior) in the left precentral gyrus that had previously received linear-accelerator-based stereotactic radiosurgery (SRS) to 20 Gy 9 months prior (with 99% coverage of the target volume), a new left cerebellar 0.4 cm lesion, and a growing left posterior temporal/medial occipital 0.6 cm lesion (0.4 cm 2 months prior) [Figure 1]. The patient was awake and alert with cranial nerves grossly intact. She had an Eastern Cooperative Oncology Group (ECOG) performance status of 1.

The patient had a complicated oncological treatment history, including a previous diagnosis of right breast

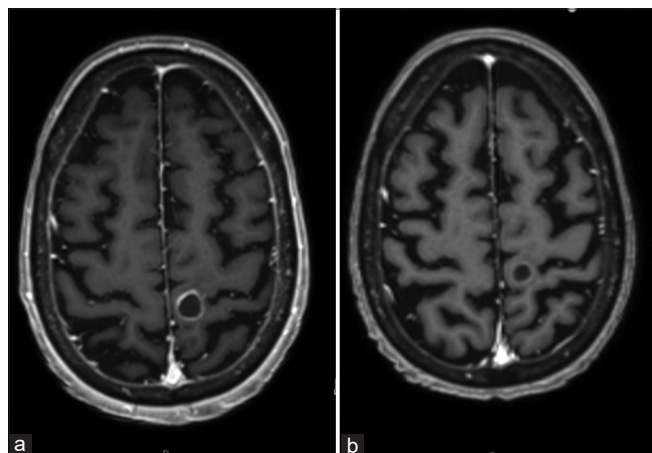


Figure 1: Left precentral gyrus metastatic small cell lung cancer lesion on axial T1-weighted MRI with gadolinium contrast before (a) and 3 months after (b) pulsed reduced dose-rate radiotherapy.

adenocarcinoma status post breast-conserving surgery and adjuvant chemoradiation, concurrent definitive chemoradiation for her originally diagnosed limited-stage SCLC, prophylactic cranial irradiation (PCI), and SRS to multiple brain metastases. [Figure 2] provides a timeline summarizing her major treatments.

Following discussion at a multidisciplinary tumor board, the patient underwent craniotomy and resection of her left precentral gyrus lesion, with pathology demonstrating metastatic SCLC. Given that the target area had previously received radiation therapy with PCI and SRS, the patient was given 35 Gy in 100 fractions over the course of 3 weeks, using PRDR for re-irradiation treatment at an apparent dose rate of 0.178 Gy/min for a cumulative dose of 80 Gy. TomoHDA™ Planning Station Version 5.1.1.6 (Accuray Inc., Sunnyvale, CA, USA) was used [Figure 3]. [Figure 4] provides a cumulative dose-volume histogram on the organs at risk along with the PRDR targets based on the treatments to the brain using MIM software (MIM Software Inc., Cleveland, OH, USA).

At follow-up in 3 months after PRDR treatment, the patient noted improved motor function of her right hand and foot. MRI brain showed improvement with marked reduction in enhancement in the lesions in the left precentral gyrus, left occipital, and left cerebellar lesions. The patient was started on palliative carboplatin and etoposide. In 5 months following the PRDR treatment, the patient maintained good motor function of her right hand but developed progression of disease with two new 3 mm brain metastases in the right temporal and left parietal regions that were outside the previously treated PRDR field. She received 24 Gy SRS to those lesions. She then developed progression in the mediastinum and retroperitoneum, although there was no evidence of recurrence within the PRDR-treated radiation field. The patient was started on palliative pembrolizumab but in the coming months had a gradual decrease in her overall performance status with increased altered mental status and hospitalizations. After discussion with neurosurgery and palliative care, the patient switched her care to home hospice, which she continues with 14 years elapsing since her initial diagnosis.

Case 2

[Figure 5] provides a flowchart summary of this case. A 41-year-old male was referred to our outpatient radiation oncology clinic with recurrent glioblastoma of the thoracic spinal cord. He had originally been diagnosed 3 years prior after presenting with progressive back pain and left leg weakness. At that time, imaging revealed a T11-12 intramedullary tumor measuring 5 × 1.3 × 1.2 cm in dimension. There were multiloculated cystic components which had peripheral enhancement. He underwent a

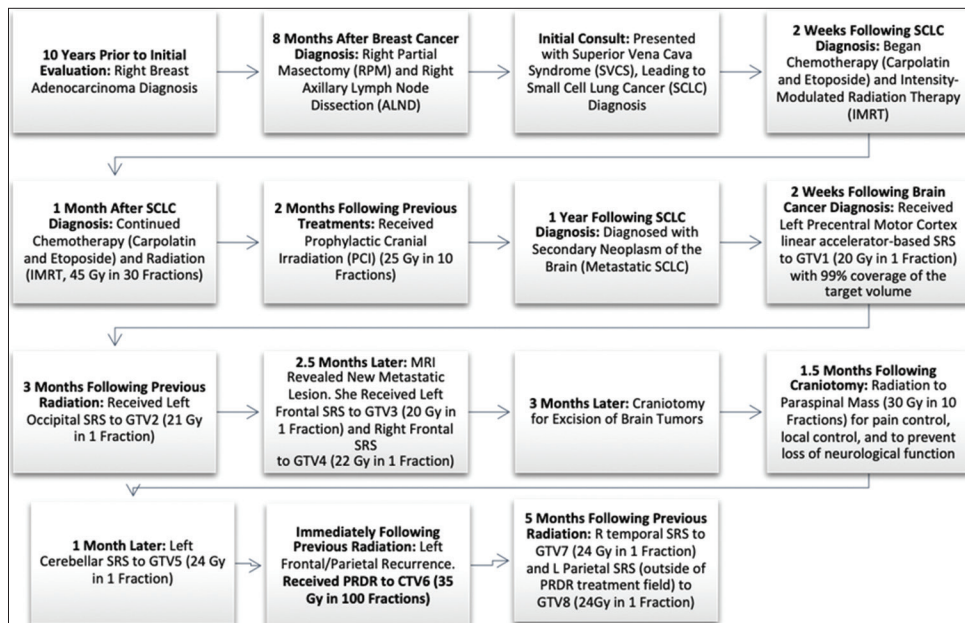


Figure 2: Case 1 cancer diagnosis and treatment timeline.

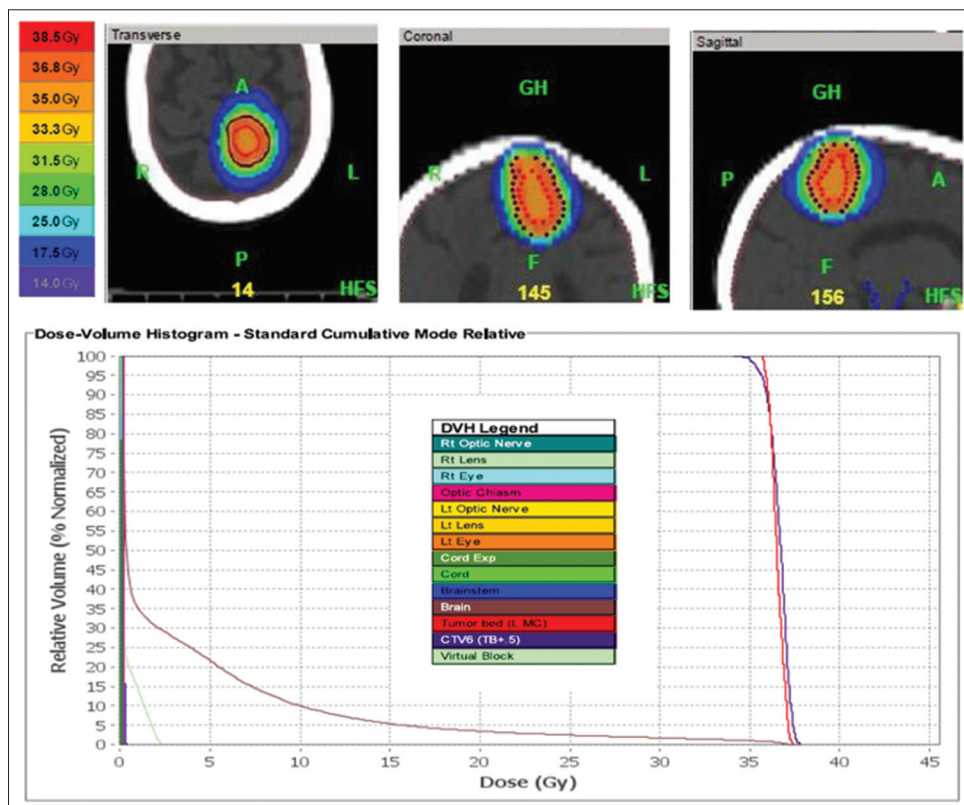


Figure 3: Left precentral motor cortex lesion re-treatment plan with dose-volume histogram. This patient was re-treated with 35 Gy in 100 fractions, over the course of 3 weeks, to her surgical cavity of her left precentral gyrus lesion. Pulsed reduced dose-rate radiotherapy was used with TomoHDA™ Planning Station Version 5.1.1.6, and 97% of the target volume received 35 Gy. The colors in the top of the figure correspond to isodose distributions, with orange corresponding to the volume receiving 35 Gy (100% dose area). The dose-volume histogram relates radiation dose to tissue volume and includes both the target structure as well as organs at risk.

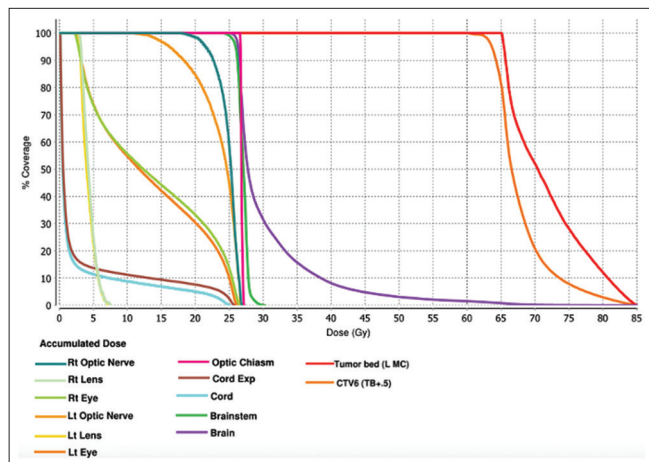


Figure 4: Comprehensive dose-volume histogram based on a summation of the patient's previous radiation treatments detailed in Figure 2 on the organs at risk along with the pulsed reduced dose-rate radiotherapy targets based on the treatments to the brain, compiled using MIM software (MIM Software Inc., Cleveland, OH, USA). The colors in the figure correspond to the volumes as shown in the key receiving doses of radiation.

thoracolumbar laminectomy and microsurgical resection of the spinal cord tumor 3 weeks later. Final pathology was consistent with a WHO grade 4 glioblastoma, KI-67-10%, IDH-1 negative, and ATRX expression retained, to which concurrent chemotherapy and radiation were recommended. He underwent adjuvant 50.4 Gy in 28 fractions of radiation to the thoracic resection cavity with 12 cycles of temozolomide.

Two and a half years after the original resection, his left leg weakness progressed, and an MRI of the thoracic spine showed definite tumor progression. Additional chemotherapy with temozolomide, Avastin, isotretinoin, and lomustine did not slow the progression of the tumor. At the time of evaluation, the patient reported a 6-month history of a 20-pound weight loss, worsening bilateral leg weakness, numbness and tingling in both legs, erectile dysfunction, inability to ambulate with both legs causing wheelchair use, increased urinary frequency, and occasional difficulty holding bowel movements. He denied any pain. His ECOG performance status was 3.

MRI thoracic spine revealed a recurrent thoracic lesion 2.2 × 1 × 0.8 cm [Figure 6]. His bevacizumab and lomustine were placed on hold due to myelosuppression, with the bevacizumab restarted after a break. The patient was retreated with palliative radiation in the same area at 50 Gy in 250 fractions over the course of 6 weeks, using PRDR technique at an apparent dose rate of 0.0562 Gy/min for a cumulative dose of 100.4 Gy. TomoHDA™ Planning Station Version 5.1.1.6 (Accuray Inc., Sunnyvale, CA, USA) was used [Figure 7]. Bevacizumab 10 mg/kg every 2 weeks was given concurrently with radiation with the goal of decreasing the risk of radiation-

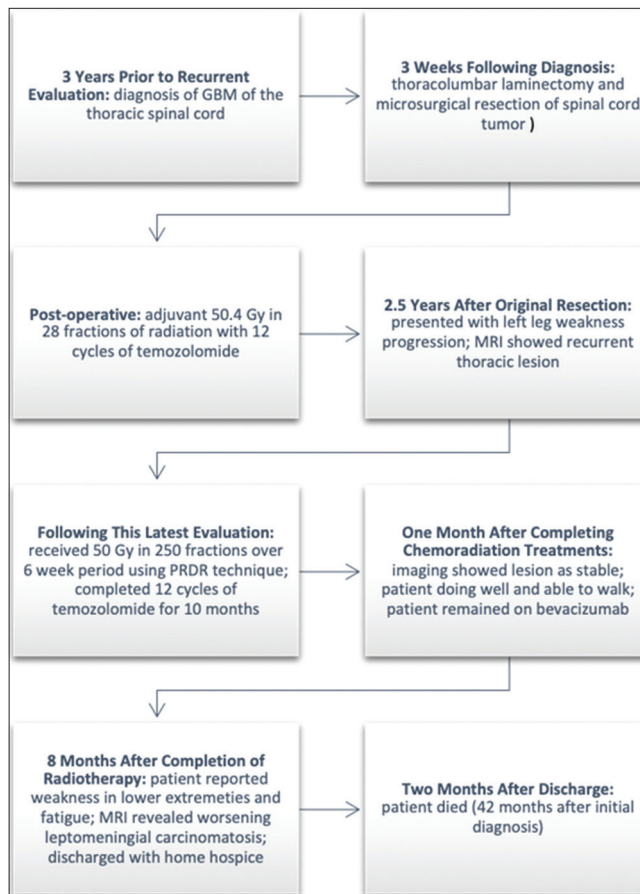


Figure 5: Case 2 cancer diagnosis and treatment timeline.

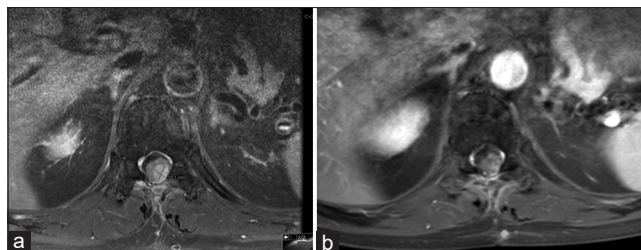


Figure 6: Glioblastoma multiforme at T11-12 seen on T1-weighted axial magnetic resonance image with gadolinium contrast before (a) and 1 month after (b) pulsed reduced dose-rate radiotherapy.

induced injury, including edema and radiation necrosis, in the context of re-irradiation with PRDR.^[9,27]

[Figure 8] provides a cumulative dose-volume histogram on the organs at risk along with the PRDR targets based on the treatments to the brain using MIM software (MIM Software Inc., Cleveland, OH, USA).

Imaging showed the lesion as stable at the 1-month follow-up appointment. He was able to walk with the assistance of a walker, which was an improvement from previously being bound by a wheelchair. Overall, the patient did not develop

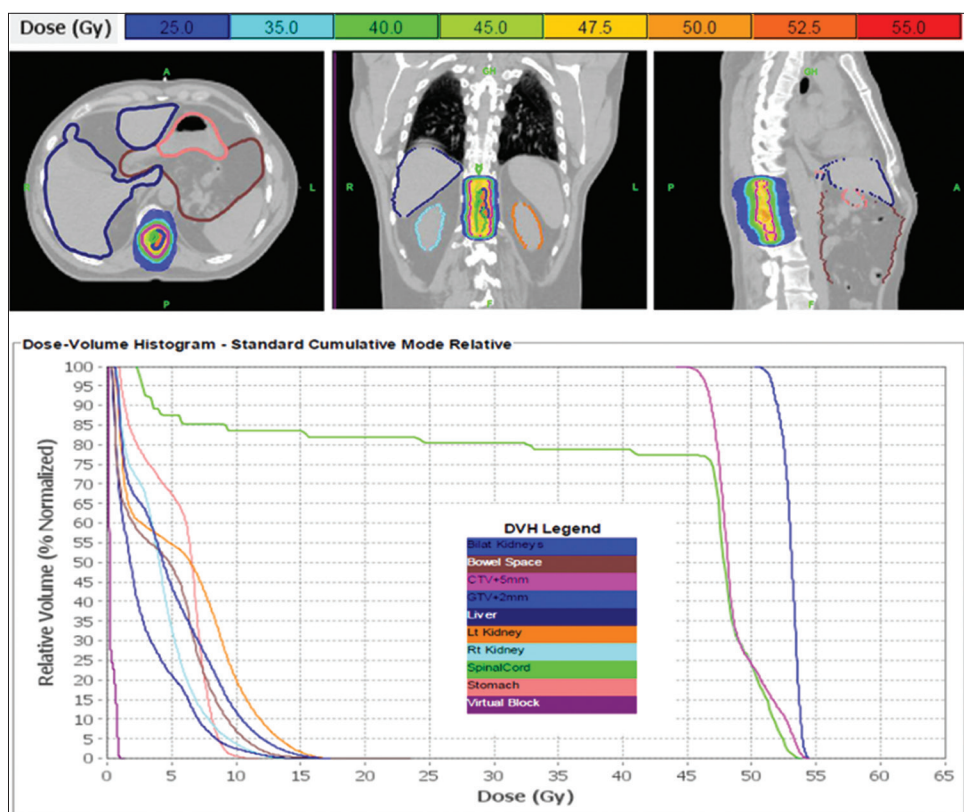


Figure 7: Thoracic spinal glioblastoma multifforme re-treatment plan with dose-volume histogram. This patient was re-treated with 50 Gy in 250 fractions, over the course of 6 weeks, to his recurrent thoracic lesion. Pulsed reduced dose-rate radiotherapy was used with TomoHDA™ Planning Station Version 5.1.1.6, and 99% of the target volume received 50 Gy. The colors in the top of the figure correspond to isodose distributions for the treatment target in the thoracic spine, with orange corresponding to the volume receiving 50 Gy (100% dose area). Organs at risk are delineated in the top of the figure as well. The dose-volume histogram relates radiation dose to tissue volume and includes both the target structure as well as organs at risk.

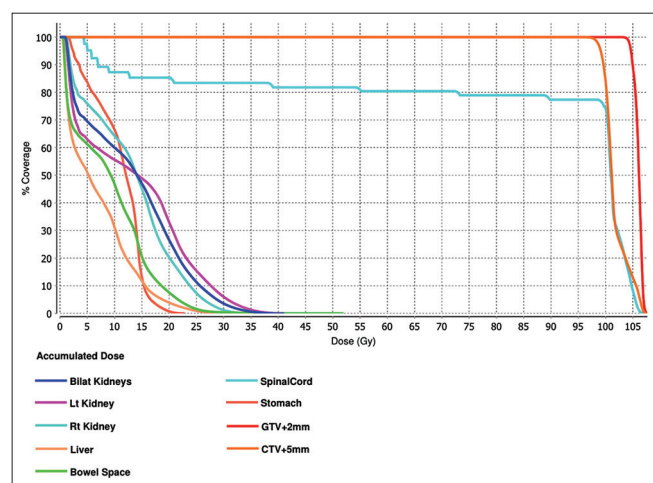


Figure 8: Comprehensive dose-volume histogram based on a summation of the patient's previous radiation treatments detailed in Figure 5 on the organs at risk along with the pulsed reduced dose-rate radiotherapy targets based on the treatments to the brain, compiled using MIM software (MIM Software Inc., Cleveland, OH, USA). The colors in the figure correspond to the volumes as shown in the key receiving doses of radiation.

significant acute radiation side effects and reported to be very satisfied with his response to treatment.

Eight months after completion of radiation treatment, the patient remained on bevacizumab under the care of his oncologist. The patient reported progressive weakness in his lower extremities and ongoing fatigue. MRI of the spine revealed worsening leptomeningeal carcinomatosis, and the patient was discharged with home hospice. He died 2 months later, about 42 months after his initial diagnosis.

DISCUSSION

For patients with CNS cancers that have been previously irradiated, increased risks of radiation-induced complications discourage radiation oncologists from pursuing re-irradiation. Re-irradiation is difficult due to normal tissue tolerances. Normal tissues that receive re-irradiation may experience more severe acute and late radiation complications compared with the initial course. Historically, there has been a lack of enthusiasm for re-irradiation based on the assumption that unsuccessful

initial radiation begets poor results with salvage irradiation. In addition to nervous tissue toxicity, the total radiation dose, volume, interval between radiation treatments, and performance status of the patient are taken into account when deciding the feasibility of reirradiation.^[4,22,23]

PRDR is a radiation technique that has been radiobiologically derived to exploit the differences between normal neural tissue and glial neoplasms for repair of radiation damage. It breaks

treatment into a number of subfractions, delivering radiation pulses of 0.2 Gy separated by 3 min intervals, creating an apparent low dose rate treatment regime.^[7,18] During this time, normal tissues may be able to repair sublethal damage.^[6-8,19] Limited clinical data do suggest that PRDR treatment is well tolerated with minimal acute and late toxicities with cumulative doses up to 162 Gy in the CNS,^[15,25] although there is the risk for adverse effects. Both of our patients treated here had a good clinical response to PRDR and no apparent toxicities, though we acknowledge it is difficult to separate toxicities from re-treatment compared to tumor progression, as aggressive cancers that have proven to be resistant to treatment are often being encountered. Furthermore, patients with brain metastases or glioblastoma multiforme have relatively short projected overall survivals that may limit the manifestation of late radiation-related toxicities, as may have been the case with our second patient. No studies have yet provided evidence favoring a particular treatment in the setting of recurrent brain metastases after initial radiotherapy or shared experiences after the third course of radiation for the secondary relapse of brain metastases and any resulting toxicities.^[15] Systemic treatment, hypofractionated and single-fraction re-irradiation (linear accelerator or Gamma Knife based), surgical resection followed by adjuvant therapy, and laser thermal ablation can be considered.^[30,31] Of course, treatment should be individualized based on the patient's functional status, previous treatment and type of primary cancer, anatomical location of cancer, state of primary cancer, and recurrent or progressing metastatic brain tumor.

PRDR has been used in a variety of cancers, including recurrent high-grade gliomas,^[3] newly diagnosed glioblastomas^[2] and recurrent glioblastomas,^[4] spinal and brain ependymomas in pediatric and adult patients,^[20] meningiomas,^[32] brain metastases,^[15] and a number of extracranial primaries such as nasopharyngeal cancer,^[16] recurrent breast cancers,^[24] pancreatic, and prostate cancers.^[17] It has been shown to have clinically meaningful tumor control without increased normal tissue toxicity in the management of recurrent glioblastoma and breast cancer.^[1,4,24] Interestingly, there is a tendency to minimize volume when re-irradiating brain tissue, although previous literature suggests that greater palliative benefit may be realized by expanding the treatment volume to include the entire craniospinal axis.^[4]

The exact mechanism of PRDR is unknown. [Table 1] provides a summary of potential mechanisms discussed in the literature.

There are limitations to the PRDR technique. Treatment time is longer, potentially decreasing the overall dose delivery accuracy if the target deviates from its original position. Daily 3D cone beam computed tomography scans and treatment fixation devices were used for our patients, including a head and neck mask and immobilization cushion devices. Other

Table 1: Potential mechanisms for PRDR.

Mechanism	Explanation
Low dose hyperradiosensitivity	<p>It has been theorized that tumor cells, as opposed to non-proliferating normal tissue cells, have increased radiosensitivity to doses <0.3–0.5 Gy, especially between 0.01 and 1 Gy/min.^[1-4,9,18]</p> <p>It is postulated that cycling cells are blockaded in the G₂M phase of the cell cycle, where they are relatively more radiosensitive than cells in the G₁ and S phases, allowed increased cell death during PRDR^[4,5,34]</p> <p>20+ different human cell lines (colorectal carcinoma, bladder carcinoma, melanoma, prostate carcinoma, cervical squamous carcinoma, lung adenocarcinoma, neuroblastoma, and glioma) have been studied, showing a steeper reduction in cell survival at low doses of radiation^[8,10-14,28,29,33]</p>
Increased normal tissue repair	<p>Exploit damage repair mechanisms between normal tissue and tumor^[25]</p> <p>Delivery of reduced dose rates allows sub-lethal damage repair in normal tissue while simultaneously affecting tumor cells as much as conventional radiation treatment</p> <p>During conventional radiation treatment, a dose of 1.8–2 Gy is delivered at a dose rate of 4–6 Gy/min. In PRDR, the effective dose rate is reduced and treatment time is increased</p> <p>The increased treatment time may allow normal tissues to repair sublethal damage^[3-5,10]</p> <p>This reduced dose-rate can be delivered via a continuous low dose-rate irradiator, which is not widely available, or by dividing the standard 2 Gy fraction into equal sub-fractions that are delivered in radiation pulses as seen in our cases (radiation pulses of ~0.2 Gy separated by 3 min intervals)</p>

PRDR: Pulsed reduced dose-rate radiotherapy

reports suggest performing two megavoltage computed tomography scans before the first and fourth subfractions to determine if there is any trend of target deviation.^[26]

PRDR is palliative in nature yet may offer sustained tumor control, prolongation of survival, and symptom relief. Indeed, the two patients presented here improved clinically until there was disease progression.

CONCLUSION

In our two cases, PRDR proved effective in the treatment of recurrent malignant CNS tumors that were previously irradiated. Prospective studies are needed to delineate the efficacy and toxicity of PRDR.

Declaration of patient consent

Institutional Review Board (IRB) permission obtained for the study.

Financial support and sponsorship

Nil.

Conflicts of interest

There are no conflicts of interest.

REFERENCES

- Adkison JB, Tome W, Seo S, Richards GM, Robins HI, Rassmussen K, *et al.* Reirradiation of large-volume recurrent glioma with pulsed reduced-dose-rate radiotherapy. *Int J Radiat Oncol Biol Phys* 2011;79:835-41.
- Almahariq ME, Quinn TJ, Arden JD, Roskos PT, Wilson GD, Marples B, *et al.* Pulsed radiation therapy for the treatment of newly diagnosed glioblastoma. *Neuro Oncol* 2020;23:447-56.
- Bovi JA, Prah MA, Retzlaff AA, Schmainda KM, Connelly JM, Rand SD, *et al.* Pulsed reduced dose rate radiotherapy in conjunction with bevacizumab or bevacizumab alone in recurrent high-grade glioma: Survival outcomes. *Int J Radiat Oncol Biol Phys* 2020;108:979-86.
- Cannon GM, Tome WA, Robins HI, Howard SP. Pulsed reduced dose-rate radiotherapy: Case report: A novel re-treatment strategy in the management of recurrent glioblastoma multiforme. *J Neurooncol* 2007;83:307-11.
- Hall EJ, Brenner DJ. The dose-rate effect revisited: Radiobiological considerations of importance in radiotherapy. *Int J Radiat Oncol Biol Phys* 1991;21:1403-14.
- Hall EJ, Giaccia AJ. *Radiobiology for the Radiologist*. 6th ed. Philadelphia, PA: Lippincott Williams & Wilkins; 2006.
- Harney J, Short SC, Shah N, Joiner M, Saunders MI. Low dose hyper-radiosensitivity in metastatic tumors. *Int J Radiat Oncol Biol Phys* 2004;59:1190-5.
- Joiner MC, Marples B, Lambin P, Short SC, Turesson I. Low-dose hypersensitivity: Current status and possible mechanisms. *Int J Radiat Oncol Biol Phys* 2001;49:379-89.
- Khan M, Zhao Z, Arooj S, Liao G. Bevacizumab for radiation necrosis following radiotherapy of brain metastatic disease: A systematic review and meta-analysis. *BMC Cancer* 2021;21:167.
- Lambin P, Coco-Martin J, Legal JD, Begg AC, Parmentier C, Joiner MC, *et al.* Intrinsic radiosensitivity and chromosome aberration analysis using fluorescence *in situ* hybridization in cells of two human tumor cell lines. *Radiat Res* 1994;138 Suppl 1:S40-3.
- Lambin P, Fertil B, Malaise EP, Joiner MC. Multiphasic survival curves for cells of human tumor cell lines: Induced repair or hypersensitive subpopulation? *Radiat Res* 1994;138 Suppl 1:S32-6.
- Lambin P, Malaise EP, Joiner MC. The effect of very low radiation doses on the human bladder carcinoma cell line RT112. *Radiat Oncol* 1994;32:63-72.
- Lambin P, Malaise EP, Joiner MC. Might intrinsic radioresistance of human tumour cells be induced by radiation? *Int J Radiat Biol* 1996;69:279-90.
- Lambin P, Marples B, Fertil B, Malaise EP, Joiner MC. Hypersensitivity of a human tumour cell line to very low radiation doses. *Int J Radiat Biol* 1993;63:639-50.
- Li GH, Liu Y, Tang JL, Zhang D, Zhou P, Yang DQ, *et al.* Pulsed reduced dose-rate radiotherapy as re-irradiation for brain metastasis in a patient with lung squamous-celled carcinoma. *Jpn J Clin Oncol* 2012;42:856-60.
- Li GH, Zhu B, Yang F, Ma CK, Yang DQ. Use of cetuximab in combination with pulsed reduced dose-rate radiotherapy in a patient with recurrence of nasopharyngeal carcinoma in the neck. *Exp Ther Med* 2012;3:869-72.
- Li J, Lang J, Wang P, Kang S, Lin MH, Chen X, *et al.* Intensity-modulated radiation therapy for pancreatic and prostate cancer using pulsed low-dose rate delivery techniques. *Med Dosim* 2014;39:330-6.
- Lin PS, Wu A. Not all 2 Gray radiation prescriptions are equivalent: Cytotoxic effect depends on delivery sequences of partial fractionated doses. *Int J Radiat Oncol Biol Phys* 2005;63:536-44.
- Marples B. Is low-dose hyper-radiosensitivity a measure of G2-phase cell radiosensitivity? *Cancer Metastasis Rev* 2004;23:197-207.
- Mohindra P, Robins HI, Tome WA, Hayes L, Howard SP. Wide-field pulsed reduced dose rate radiotherapy (PRDR) for recurrent ependymoma in pediatric and young adult patients. *Anticancer Res* 2013;33:2611-8.
- Murphy ES, Rogacki K, Godley A, Qi P, Reddy CA, Ahluwalia MS, *et al.* Intensity modulated radiation therapy with pulsed reduced dose rate as a reirradiation strategy for recurrent central nervous system tumors: An institutional series and literature review. *Pract Radiat Oncol* 2017;7:e391-9.
- Nieder C, Andratschke NH, Grosu AL. Re-irradiation for recurrent primary brain tumors. *Anticancer Res* 2016;36:4985-95.
- Nieder C, Gaspar LE, Ruyscher D, Guckenberger M, Mehta MP, Rusthoven CG, *et al.* Repeat reirradiation of the spinal cord: Multi-national expert treatment recommendations. *Strahlenther Onkol* 2018;194:365-74.
- Richards GM, Tome WA, Robins HI, Stewart JA, Welsh JS, Mahler PA, *et al.* Pulsed reduced dose-rate radiotherapy: A novel

- locoregional retreatment strategy for breast cancer recurrence in the previously irradiated chest wall, axilla, or supraclavicular region. *Breast Cancer Res Treat* 2009;114:307-13.
25. Rogacki KC, Chao ST, Yu J, Godley A, Balagamwala E, Suh JH, *et al.* Review of pulsed reduced dose rate re-irradiation for recurrent tumors. *J Cancer Clin Trials* 2018;3:2.
 26. Rong Y, Paliwal B, Howard SP, Welsh J. Treatment planning for pulsed reduced dose-rate radiotherapy in helical tomotherapy. *Int J Radiat Oncol Biol Phys* 2011;79:934-42.
 27. Shen G, Wang YJ, Guan YJ, Dong DP, Yang G, Li D, *et al.* Relief effect of bevacizumab on severe edema induced by re-irradiation in brain tumor patients. *Chin Med J (Engl)* 2015;128:2126-9.
 28. Short S, Mayes C, Woodcock M, Johns H, Joiner MC. Low dose hypersensitivity in the T98G human glioblastoma cell line. *Int J Radiat Biol* 1999;75:847-55.
 29. Short SC, Mitchell SA, Boulton P, Woodcock M, Joiner MC. The response of human glioma cell lines to low-dose radiation exposure. *Int J Radiat Biol* 1999;75:1341-8.
 30. Thomas JG, Rao G, Kew Y, Prabhu SS. Laser interstitial thermal therapy for newly diagnosed and recurrent glioblastoma. *Neurosurg Focus* 2016;41:E12.
 31. van Linde ME, Brahm CG, de Witt Hamer PC, Reijneveld JC, Bruynzeel AM, Vandertop WP, *et al.* Treatment outcome of patients with recurrent glioblastoma multiforme: A retrospective multicenter analysis. *J Neurooncol* 2017;135:183-92.
 32. Witt JS, Musunuru HB, Bayliss RA, Howard SP. Large volume re-irradiation for recurrent meningioma with pulsed reduced dose rate radiotherapy. *J Neurooncol* 2019;141:103-9.
 33. Wouters BG, Sy AM, Skarsgard LD. Low-dose hypersensitivity and increased radioresistance in a panel of human tumor cell lines with different radiosensitivity. *Radiat Res* 1996;146:399-413.
 34. Zhang P, Wang B, Chen X, Cvetkovic D, Chen L, Lang J, *et al.* Local tumor control and normal tissue toxicity of pulsed low-dose rate radiotherapy for recurrent lung cancer: An *in vivo* animal study. *Dose Response* 2015;13:1559325815588507.

How to cite this article: Prabhu AV, Lee M, Galhardo E, Newkirk M, Rodriguez A, Xia F. Pulsed reduced dose-rate radiotherapy for previously irradiated tumors in the brain and spine. *Surg Neurol Int* 2021;12:280.