

Extra-Axial Cerebello-Pontine Angle Medulloblastoma in an Infant: A Rare Case Report with Review of Literature

Abstract

Medulloblastoma is a fairly common neoplastic growth seen majorly in children, presenting as an intra-axial midline mass arising from the cerebellar vermis. However, its presentation as an extra-axial mass in the cerebellopontine angle (CPA) is extremely rare, such that, only 39 cases have been reported in the world literature till 2016. Only one case has ever been reported of an extra-axial CPA medulloblastoma in an infant; who was aged 1 year. We present a case report of an 8-month-old infant, with an extra-axial CPA medulloblastoma and discuss its management strategy.

Keywords: Cerebellopontine angle, chemotherapy, medulloblastoma, radiotherapy

**Santosh Prabhu,
Sidharth Agarwal,
Sujata Prabhu,
Akash Prabhu**

*Department of Neurosurgery,
Western India Institute of
Neurosciences, Kolhapur,
Maharashtra, India*

Introduction

Medulloblastoma is a high grade, malignant tumor seen mainly in the pediatric age group.^[1] They constitute around 9.2% of all pediatric brain tumors. Upto 30% of the cases have been reported in adults.^[2] In pediatric tumors, a bimodal peak is seen at age groups 3–4 years and 8–10 years.^[2] They usually arise from the cerebellar vermis, presenting as a midline solid homogeneously enhancing mass growing toward the 4th ventricle.^[3] In adults, their location is likely to be more laterally in the cerebellum,^[4] but very rarely they may be located as far lateral as the cerebellopontine angle (CPA), an extra-axial presentation is even rarer. In children too, they are commonly seen at age 3–4 years, and a medulloblastoma presenting at an age of 8 months is unheard of.

Medulloblastomas are known to be particularly aggressive in their growth. Treatment modalities include surgery, chemotherapy, and radiotherapy.^[3] The overall prognosis is poor, especially in children of age less than 3 years, where radiation therapy is not indicated. Another factor that adds to the aggressive nature of this tumor is their potential to produce drop metastasis causing leptomeningeal spread as well as supratentorial spread.^[3] Although, such drop metastasis to the spine from CPA

medulloblastomas have not been reported in the literature.^[3]

Materials and Methods

An 8-month-old male child presented to another hospital, with complaints of persistent neck rotation to the right, marked facial asymmetry while crying with incomplete eye closure, and restricted outward movement of the right eye for 2 months. For the past 8–10 days, the baby had become more irritable, started crying inconsolably but with a decrease in the volume of the cry. There were episodes of vomiting after feeds.

A magnetic resonance imaging (MRI) was done which showed a well-defined heterogeneous T2 iso to hypointense lobulated lesion in the right CPA about 1.4 cm × 0.9 cm × 1.0 cm, extending into the right internal auditory canal (IAC) with mild bony widening of the IAC. Postcontrast, the lesion showed moderate heterogenous lesional enhancement. The lateral half of the cisternal and canalicular segments of the vestibulocochlear and the facial nerve were not seen distinctly separate from the above-mentioned lesion. A diagnosis of right-sided vestibulocochlear schwannoma was made [Figure 1].

This hospital decided to observe the patient and repeat an MRI after a few months.

This is an open access journal, and articles are distributed under the terms of the Creative Commons Attribution-NonCommercial-ShareAlike 4.0 License, which allows others to remix, tweak, and build upon the work non-commercially, as long as appropriate credit is given and the new creations are licensed under the identical terms.

For reprints contact: WKHLRPMedknow_reprints@wolterskluwer.com

How to cite this article: Prabhu S, Agarwal S, Prabhu S, Prabhu A. Extra-axial cerebello-pontine angle medulloblastoma in an infant: A rare case report with review of literature. *Asian J Neurosurg* 2021;16:447-51.

Submitted: 22-Feb-2021

Revised: 08-Apr-2021

Accepted: 18-Apr-2021

Published: 14-Sep-2021

Address for Correspondence:

*Prof. Santosh Prabhu,
183/B, Nagala Park,
Kolhapur - 416 002,
Maharashtra, India.
E-mail: sprabhuneuro@gmail.
com*

Access this article online

Website: www.asianjns.org

DOI: 10.4103/ajns.AJNS_79_21

Quick Response Code:



The baby presented to our outpatient department with the above-mentioned complaints, about 1 and a half months after the first consultation elsewhere. A repeated MRI showed a markedly increased size of the lesion now showing a large, well-defined, mixed solid and cystic, extra-axial right CPA lesion with a small intracanalicular component, measuring approximately 3.9 cm × 3.2 cm × 5.3 cm in size. The solid component appeared slight hyperintense on T2-weighted images, slightly hypointense on T1-weighted images with moderate postcontrast enhancement. The cystic component was hyperintense on T2-weighted images and hypointense on T1-weighted images with thin peripheral postcontrast enhancement. Few tiny areas of gradient blooming were seen within suggesting intralesional microhemorrhages. The solid component showed restricted diffusion, suggesting high cellularity. Widening of the IAC was seen. Mass effect was seen on the pons, medulla, middle cerebellar peduncle, and cerebellum with distortion of the 4th ventricle. Mild dilatation of the lateral and 3rd ventricles was seen. Anteriorly, the mass was seen extending into

the prepontine and the parapontine cistern encasing the adjacent basilar artery with intact flow void. The right VII and VIII nerves could not be identified separately from the lesion and there was the distortion of the cisternal part of the right V nerve. A radiological provisional diagnosis of right-sided vestibular schwannoma was again given by the radiologist [Figure 2].

We decided to operate on the tumor. The baby was operated via a suboccipital retromastoid craniotomy. The tumor was pinkish gray in color, moderately vascular, and firm inconsistency. A near-total excision was done using Cavitron Ultra Sonic Aspirator (CUSA) [Figure 3]. No new deficits were produced. Histopathology showed undifferentiated embryonal cells, had round to spindle-shaped nuclei with scanty cytoplasm. The tumor cells were mitotically active and also showed apoptotic bodies. Loose-less cellular areas without significant desmoplasia were also seen. The stroma showed blood vessels. The findings were suggestive of a classic medulloblastoma [Figure 4].

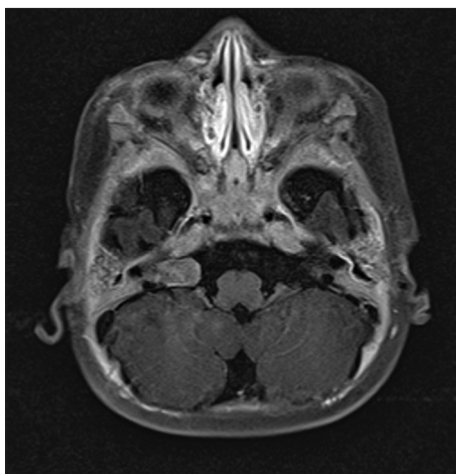


Figure 1: First magnetic resonance imaging of patient diagnosed as Rt cerebellopontine angle vestibulocochlear schwannoma due to internal auditory canal extension

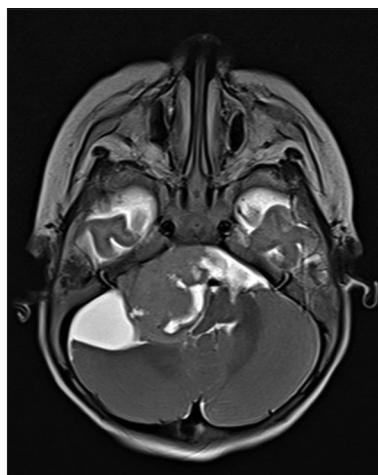


Figure 2: Much enlarged tumor in R cerebellopontine angle, again diagnosed as a schwannoma on imaging

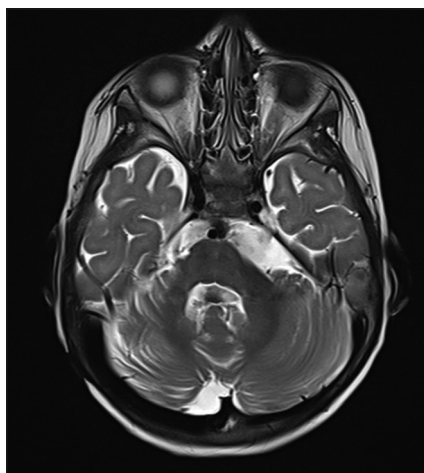


Figure 3: Post op magnetic resonance imaging showing gross total excision

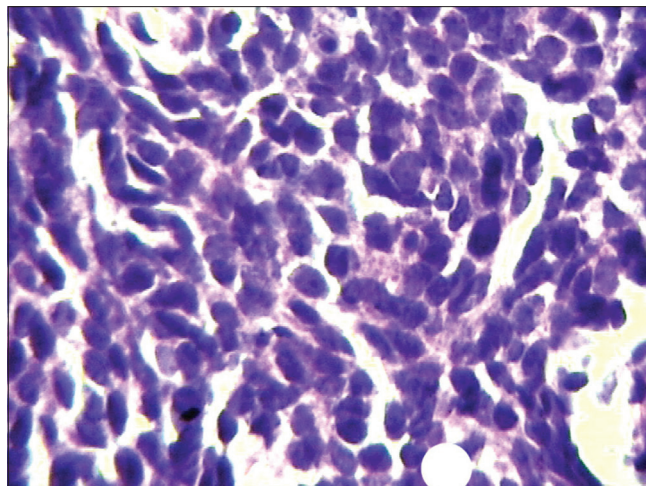


Figure 4: HPE classic medulloblastoma

Cerebrospinal fluid (CSF) by lumbar puncture analysis for malignant cells did not yield any malignant cells.

Postop recovery was uneventful, the patient was referred for adjuvant therapy decision to a Cancer Center. He has completed nine sessions of chemotherapy and is currently doing well with no new complaints, at last, follow-up.

Discussion

Medulloblastomas are a group of tumors found frequently in the pediatric age groups and primarily in the posterior fossa.^[5] Medulloblastomas were first described by Bailey and Cushing in the year 1925, referred to as highly malignant small cell tumor of the mid-line cerebellum.^[6] These tumors constitute approximately 20%–25% of all pediatric neoplasms. They are usually intra-axial, arising in the mid-line cerebellar vermis. Extra-axially located lesions are rare and further extra-axial medulloblastomas in the CPA are extremely rare.^[3] According to recent reviews, upto 30% of the medulloblastomas may be found in adults,^[2] in whom they are usually placed more laterally in the cerebellar hemispheres as compared to the pediatric medulloblastomas.^[7]

With controversies regarding the origin and development of the medulloblastomas, it has been postulated by some authors that they may originate either from germinal cells or their remnants situated at the end of the posterior medullary velum from remnants of the external granular layer.^[8,9] In the CPA too, they may have an origin from the remnants of the external granular layer in the cerebellar hemisphere, including the flocculus which faces the CPA.^[3]

Typical medulloblastomas though seen more in pediatric patients; in a case series of 14 patients with CPA medulloblastomas by Jaiswal *et al.*, 9 (around 64%) cases were in adults (age group 22–53) and only 5 (around 36%) were in the age group below 22 years age.^[5] Till 2016, only 39 cases of a CPA medulloblastoma have been reported in the literature. Of these 39 cases, only 24% were in the pediatric age group.^[10] CPA tumors in children account for approximately 1% of all intracranial tumors consisting mainly of epidermoids, schwannomas, and meningiomas. Other lesions such as medulloblastomas account for about 1% of all the tumors found in the Pediatric CPA.^[10]

Medulloblastomas have a bimodal peak of presentation at 3–4 years age and 8–10 years of age.^[2] They are rare below 3 years. There has been only one reported case of an extra-axial CPA medulloblastoma occurring in an infant 1-year-old.^[3] Our patient became symptomatic at 6 months age, but was operated 2 months later as the repeated MRI showed marked enlargement of tumor.

Due to the rarity of presentation, no typical signs to differentiate medulloblastomas from other CPA tumors have yet been identified radiologically or clinically.^[10] The midline medulloblastomas usually present with signs

of cerebellar dysfunction, truncal ataxia, signs of raised intracranial pressure, and hydrocephalus if the 4th ventricle is obstructed.

Presentation in the CPA region can be variable. They present with signs of local involvement such as cranial nerve dysfunctions on the side of lesion, or cerebellar signs due to compression of the cerebellum.^[3] Headache, nausea, vomiting along with history, and findings suggestive of multiple lower cranial nerve involvement were the presenting feature in most patients.^[11,12] Cranial nerve impairments from V to lower cranial nerves have been reported in various publications.^[1] Although hearing impairment and VIII nerve involvement as a first symptom was a less common presentation (5 out of 38 patients in reported cases till 2016) as reported by Boukobza and Polivka.^[1] Large tumors as discussed above may cause mass effect on the pons, medulla, cerebellar peduncles, and even cause distortion of the 4th ventricle leading to hydrocephalus. Our patient also showed mild dilatation of the lateral and the 3rd ventricles and had a right 6th nerve palsy.

On computed tomography scan medulloblastomas are seen as a well-defined mass with heterogenous contrast enhancement with small internal areas of hypointensity indicating necrosis.^[5] MRI remains the main modality of diagnosis, wherein these lesions have a homogenous hypointensity on T1 weighted images and heterogenous hyperintensity was seen on T2 weighted imaged and FLAIR sequence. These lesions show a strong heterogenous enhancement on contrast studies.^[1,5] For further diagnosis, it has been advised to do diffusion-weighted images (DWI), Apparent diffusion coefficient (ADC), and spectroscopy studies.^[1] ADC is usually low, and there may be a DWI hyperintensity.^[13,14] Restricted diffusion on DWI, suggests high cellularity and the possibility of a high-grade tumor. This finding may suggest a possibility of a medulloblastoma.^[10] On spectroscopic studies, the ratio of N-Acetyl-Aspartate (NAA)/Choline and of NAA/Creatine are decreased; the ratio of Choline/Creatine is increased; and showed a low peak of taurine.^[15]

In our patient, the MRI was reported to have solid plus cystic components. The hypointensity may be due to cyst formation in the tumor or necrosis or due to calcification.^[1,2] There was also evidence of micro-bleeds inside the tumor. Britton^[16] suggested that a normal IAC was more suggestive that the lesion is not a vestibular schwannoma; as vestibular schwannomas usually show widening and erosion of the IAC. This is in contrast to findings in our patient, where both consecutive MRIs showed a widening of the IAC, and the lesion was seen extending into the IAC.

Prior to 2016, the medulloblastomas were classified on the basis of their histological findings (as per WHO classification 2007). They were subdivided into classic, desmoplastic or nodular, medulloblastoma with extensive

nodularity, anaplastic medulloblastomas, and large cell medulloblastomas. Two additional histological patterns have been recognized but are not considered as distinct variants are melanocytic medulloblastomas and medulloblastomas with rhabdomyoblastic cells.^[2] Classic and desmoplastic variants were most commonly found. Although in the evaluated 38 cases of CPA medulloblastoma 26 (17 out of 26 adults and 9 out of 12 children) were classic medulloblastomas.^[1]

In the WHO classification of central nervous system tumors 2016, some major changes were made in the classification of gliomas and medulloblastomas; the molecular characteristics of the tumors were used in the classification of these tumors. Four molecular groups have been shown in this classification: WNT (wingless) activated, Sonic Hedge Hog (SHH) activated (includes TP53 mutant and the wild types), Group 3 Medulloblastoma (non WNT and non SHH), and Group 4 Medulloblastoma (non WNT and non SHH). An integrated diagnosis containing both the molecular characteristics as well as the histological characteristics has been suggested.^[17] SHH activated sub group is found both in adults as well as children, whereas the remaining variants are found in pediatric patients only. The molecular classification provides an idea about the prognosis of the disease. Prognosis is varied in the SHH subgroup with better results in the desmoplastic variants whereas Group 3 has a poor prognosis. Prognosis of the WNT group and Group 4 are good and intermediate, respectively.^[12] In our patient, molecular studies were not done as this facility was not available in our city.

Medulloblastomas are known to be highly malignant and aggressive tumors. As reported by Goudihalli *et al.*, these tumors usually present with short duration of histories and symptoms ranging from few weeks to 2–3 months.^[11] Medulloblastomas are known to metastasize to leptomeninges or the supratentorial compartments or the spinal cord by drop metastasis through the CSF pathways. However, spinal drop metastasis from a CPA medulloblastomas has not been reported in the literature,^[3] nor was it found in our patient. Although, Kumar *et al.* in their series of four patients suggested a higher malignant potential in medulloblastomas of the CPA as compared to the vermian origin counterparts.^[18] It is, hence, advised to get the CSF collected by lumbar puncture evaluated for malignant cells in all patients with medulloblastoma.

An estimate of the rate of growth and invasiveness can also be derived from the scans of this patient and the interval change between the two scans. The two scans were done at an interval of 1 month and 20 days. During this period of 50 days, an aggressive growth of the tumor from 1.4 cm × 0.9 cm × 1.0 cm to 3.9 cm × 3.2 cm × 5.3 cm was seen. The tumor had grown significantly and had encroached the basilar artery indicating an aggressive nature of the tumor. Intraoperatively, these tumors have been described to be highly vascular.^[11]

Microsurgical decompression of the lesion followed by chemotherapy combined with radiotherapy is the best modality available to treat these lesions.^[4] In addition to microsurgical resection, further management by chemotherapy or radiotherapy varies widely, based on the age of the patient, extent of the disease, the risks of recurrence, and neurocognitive effect of the radiation therapy.^[2] Radiation therapy to the whole craniospinal axis is indicated.^[4] An improvement on treatment with vincristine-based regimens of chemotherapy has been reported.^[19] Other drugs such as cisplatin, lomustine, and cyclophosphamide are also used in combination.^[2]

The treatment in children below the age of 3 years varies significantly as compared to those above 3 years, as radiation therapy is not indicated below 3 years of age. Surgery followed by chemotherapy is usually the preferred treatment. As suggested in various trials, more drug regimens were added to chemotherapy consisting of vincristine, etoposide, cisplatin, cyclophosphamide, carboplatin, ifosfamide, thiopeta, and methotrexate. All these trials used varied combination of drugs with varied results. The results of chemotherapy also depended on the histological characteristics of the tumor. Better outcomes were seen in desmoplastic/nodular variants as compared to the other variants.^[2]

Although, medulloblastomas have seen an overall poor prognosis; over the past decade, we have seen increased survival in patients with medulloblastomas.^[2] This could be attributed to better surgical technique due to usage of CUSA, Intraop Neurophysiology Monitoring (IONM), and more focused chemotherapy and radiotherapy. The prognosis also depends on the histological and molecular characteristics of the tumor. As our understanding of these molecular and histological features improves, better regimens may be available in the future.

Conclusion

Medulloblastomas in the CPA though quite rare and with more prevalence in the adults; should also be considered as a differential diagnosis in pediatric age groups including infants. Medulloblastoma should particularly be thought of when the patient has rapidly progressed over a short period of time. With the use of meticulous surgical resection, CUSA, IONM, and chemotherapy along with radiotherapy, patients with medulloblastomas have seen an increasing survival recently. However, how far this is true for CPA medulloblastomas is difficult to say due to their rare occurrence; thus, longer follow-ups may be needed before any conclusion can be drawn.

Declaration of patient consent

The authors certify that they have obtained all appropriate patient consent forms. In the form the patient(s) has/have given his/her/their consent for his/her/their images and other clinical information to be reported in the journal. The

patients understand that their names and initials will not be published and due efforts will be made to conceal their identity, but anonymity cannot be guaranteed.

Financial Support and Sponsorship

NIL.

Conflicts of Interest

There are no conflicts of Interest.

References

- Boukobza M, Polivka M. Medulloblastoma of the cerebellopontine angle in a child. A case report and review of the literature. *J Mol Biomark Diagn* 2016;7:284.
- Millard NE, de Braganca KC. Medulloblastoma. *J Child Neurol* 2016;31:1341-53.
- Bhaskar MK, Jaiswal M, Ojha BK, Singh SK, Chandra A, Meel M, *et al.* Extra-axial cerebellopontine angle medulloblastoma in an infant. *Pediatr Neurosurg* 2017;52:122-6.
- Kumar R, Bhowmick U, Kalra SK, Mahapatra AK. Pediatric cerebellopontine angle medulloblastomas. *J Pediatr Neurosci* 2008;3:127-30.
- Jaiswal AK, Mahapatra AK, Sharma MC. Cerebellopontine angle medulloblastoma. *J Clin Neurosci* 2004;11:42-5.
- Bailey P, Cushing H. Medulloblastoma cerebelli, a common type of mid-cerebellar glioma of childhood. *Arch Neurol Psychiatry* 1925;14:192-224.
- Hubbard JL, Scheithauer BW, Kispert DB, Carpenter SM, Wick MR, Law ER Jr. Adult cerebellar medulloblastomas: The Pathological radiological and clinical disease spectrum. *J Neurosurg* 1989;70:536-44.
- Raaf J, Kernohan JW. Relation of abnormal collections of cells in posterior medullary velum of cerebellum to origin of medulloblastoma. *Arch Neurol Psychiatry* 1944;52:163-9.
- Stevenson L, Echlim F. Nature and origin of some tumors of cerebellum: Medulloblastoma. *Arch Neurol Psychiatry* 1934;31:93-109.
- Noiphithak R, Yindeedej V, Thamwongskul C. Cerebellopontine angle medulloblastoma with extensive nodularity in a child: Case report and review of the literature. *Childs Nerv Syst* 2017;33:839-42.
- Goudihalli SR, Pathak A, Brar R, Mundi I. Reappraisal of cerebellopontine angle medulloblastomas: Report of a fatal case and lessons learned. *Interdiscip Neurosurg* 2018;12:20-3.
- Pant I, Chaturvedi S, Gautam VK, Pandey P, Kumari R. Extra-axial medulloblastoma in the cerebellopontine angle: Report of a rare entity with review of literature. *J Pediatr Neurosci* 2016;11:331-4.
- Yamasaki F, Kurisu K, Satoh K, Arita K, Sugiyama K, Ohtaki M, *et al.* Apparent diffusion coefficient of human brain tumors at MR imaging. *Radiology* 2005;235:985-91.
- Bull JG, Saunders DE, Clark CA. Discrimination of paediatric brain tumours using apparent diffusion coefficient histograms. *Eur Radiol* 2012;22:447-57.
- Wu G, Pang H, Ghimire P, Liu GH. Magnetic resonance spectroscopy and diffusion weighted imaging findings of medulloblastoma in 3.0T MRI: A retrospective analysis of 17 cases. *Neural Regen Res* 2012;15:2554-9.
- Britton BH. Adult medulloblastoma, neurological manifestations. *Ann Otol* 1975;84:364-7.
- Louis DN, Perry A, Reifenberger G, von Deimling A, Figarella-Branger D, Cavenee WK, *et al.* The 2016 world health organization classification of tumors of the central nervous system: A summary. *Acta Neuropathol* 2016;131:803-20.
- Kumar R, Achari G, Mishra A, Chhabra DK. Medulloblastomas of the cerebellopontine angle. *Neurol India* 2001;49:380-3.
- Cordon BJ, Strauss LC, Killmond T, Carson BS, Wharam MD, Kumar AJ *et al.* Cisplatin, Ara C. Etoposide (PAE) in treatment of recurrent childhood brain tumors. *Journal of Neuro-Oncology* 1991;11:57-63.