



Case Report

The positive effects of surgery on symptomatic stereotactic radiation-induced peritumoral brain edema: A report of three cases

Roberto Stefani¹, Stefano Peron¹, Alessandro Lacamera², Andrea Cividini¹, Pietro Fiaschi³, Giovanni Marco Sicuri¹

¹Department of Neurosurgery, ASST Ovest Milanese, Legnano, ²Department of Neurosurgery, ASST Grande Ospedale Metropolitano Niguarda, Milano,

³Department of Neurosurgery, San Martino IST University Hospital, Genova, Italy.

E-mail: Roberto Stefani - roberto.stefani@asst-ovestmi.it; Stefano Peron - stefano.peron@asst-ovestmi.it; Alessandro Lacamera - alessandro.lacamera@ospedaleniguarda.it; Andrea Cividini - andrea.cividini@asst-ovestmi.it; Pietro Fiaschi - pietro.fiaschi@unige.it; *Giovanni Marco Sicuri - giovannimarco.sicuri@asst-ovestmi.it



*Corresponding author:

Giovanni Marco Sicuri,
Department of Neurosurgery,
ASST Ovest Milanese, Legnano,
Milan, Italy.

giovannimarco.sicuri@asst-ovestmi.it

Received : 05 February 2021

Accepted : 08 June 2021

Published : 19 July 2021

DOI

10.25259/SNI_111_2021

Quick Response Code:



ABSTRACT

Background: Peritumoral brain edema is an uncommon but life-threatening side effect of brain tumors radiosurgery. Medical therapy usually alleviates symptoms until edema spontaneously disappears. However, when peritumoral brain edema endangers the patient's life or medical therapy fails to guarantee an acceptable quality of life, surgery might be considered.

Case Description: Our report focuses on three patients who developed extensive peritumoral brain edema after radiosurgery. Two were affected by vestibular schwannomas and one by a skull-base meningioma. Peritumoral brain edema worsened despite maximal medical therapy in all cases; therefore, surgical removal of the radiated lesion was carried out. In the first patient, surgery was overdue and resulted in a fatal outcome. On the other hand, in the latter two cases surgery was quickly effective. In all three cases, an unmanageable brain swelling was not found at surgery.

Conclusion: Surgical removal of brain tumors previously treated with radiosurgery was safe and effective in resolving shortly peritumoral brain edema. This solution should be considered in patients who do not respond to medical therapy and before worsening of clinical conditions. Interestingly, the expected brain swelling was not confirmed intraoperatively. In our experience, this magnetic resonance finding should not be considered a criterion to delay surgery.

Keywords: Brain swelling, Meningioma, Peritumoral brain edema, Radiosurgery, Vestibular schwannoma

INTRODUCTION

The treatment strategy for newly diagnosed skull-based meningiomas and vestibular schwannomas provides several options including active surveillance, surgery, and radiosurgery. The best treatment strategy for asymptomatic or mildly symptomatic patients with small (<2 cm) or medium sized (2–3 cm) skull-base tumors is still debated. In meningiomas and vestibular schwannomas, radiosurgery offers a long-term local tumor control rate of 87–98% at 5–10 years.^[14,15,23,29] However, peritumoral brain edema (PTBE) after radiosurgery may occur in a small but significant group of patients, ranging from 8% to 15%, and can seriously affect survival.^[3-5,7-9,13,16,19,28,30] It usually develops a few weeks - months after radiosurgery and resolves

This is an open-access article distributed under the terms of the Creative Commons Attribution-Non Commercial-Share Alike 4.0 License, which allows others to remix, tweak, and build upon the work non-commercially, as long as the author is credited and the new creations are licensed under the identical terms.

©2021 Published by Scientific Scholar on behalf of Surgical Neurology International

within 2 years. In case of mass-effect symptoms, not much is available in terms of pharmacological treatment; most patients are administered steroids and osmotic agents with uncertain efficacy. Bevacizumab, though not commonly used in clinical practice to treat peritumoral edema, might be considered in case of PTBE with or without concurrent malignant tumor progression as well as in case of radiation-induced PTBE.^[12,25,31,32] However, its use is often precluded by national and institutional guidelines as well as the degree of urgency for neurosurgical intervention. We present a small series of three patients with skull-base tumors who developed PTBE induced by stereotactic radiosurgery (SRS) and eventually underwent surgery.

CLINICAL PRESENTATION

Case 1

A 70-year-old man had been experiencing slowly-progressive hearing loss in the right ear for 3 years. A brain MRI revealed an acoustic neuroma in the right cerebellopontine angle (CPA), Koos Grade III, with peritumoral edema and brainstem compression [Figure 1a]. Radiosurgical treatment with gamma-knife radiosurgery (GKR) was chosen because the patient refused surgery (PTV 8.85 cc, 12 Gy at 50%; PTV was equal to GTV; the procedure was frame-based with Gamma Knife Perfexion). Nine months later he started to complain of headache, nystagmus, and right limb ataxia with frequent falls. A brain MRI showed an extensive cerebellar PTBE with fourth ventricle compression and obstructive hydrocephalus [Figure 1b]. A ventriculoperitoneal shunt was performed; the surgical option was again ruled out due to the fear of brain swelling during surgery. Medical treatment with corticosteroids was protracted intermittently for 2 years; nevertheless, progressive neurological deterioration occurred and an MRI showed progressive cerebellar edema with unchanged tumor size. The severity of the neurological status warranted then the surgical removal of the schwannoma. No significant intraoperative cerebellar or brainstem swelling

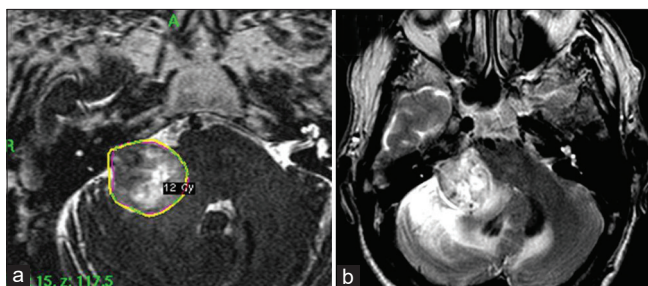


Figure 1: Right vestibular schwannoma with maximum diameter of 28 × 25 × 26 mm. MRI T2 image of Gamma Knife Radiosurgery (GKR) treatment planning (a). MRI T2 image 21 months after GKR (b). Extensive peritumoral brain edema with fourth ventricle compression is evident.

was reported. Histopathological examination confirmed a schwannoma (Grade I WHO). Few days after surgery, the patient developed severe sepsis caused by bowel perforation that was ascribed to the long use of corticosteroid together with the surgical stress.^[21] The patient died 2 weeks after surgery.

Case 2

A 45-year-old woman with right-sided hearing loss underwent a brain MRI that showed a right CPA mass [Figure 2a]. The patient underwent surgery with subtotal removal of the lesion through a right translabyrinthine approach. A residue was left in place because tenaciously attached to the facial nerve and the brainstem. Histopathological diagnosis was schwannoma. Postoperatively, she developed cerebellar symptoms and right vocal cord paresis that gradually resolved. Nine months after surgery, an MRI showed a millimeter increase in the residue and the appearance of a cyst in the tumor. Surgery was not considered because of the risk of a permanent injury of the facial nerve. The patient was sent for GKR in a single fraction (PTV 3.14 cc, 13 Gy isodose 50%). We did not add any margins (PTV was equal to GTV). The procedure was frame-based (Gamma Knife Perfexion) [Figure 2b]. Ten months later a persistent headache appeared without other

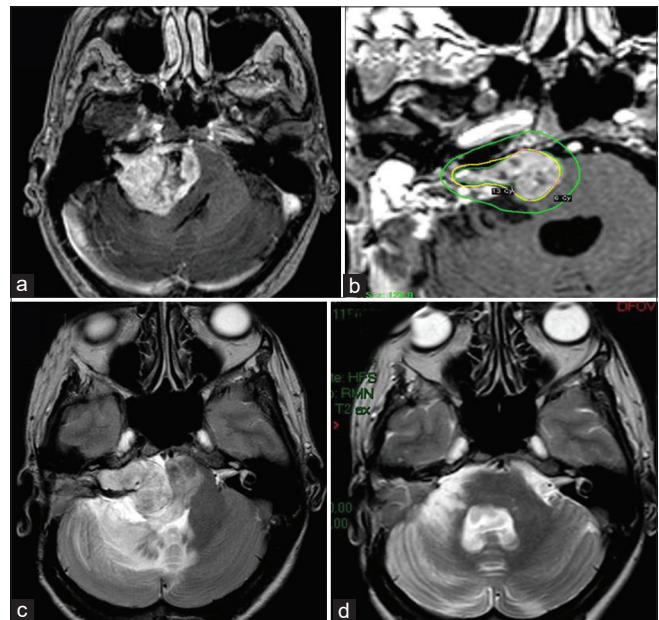


Figure 2: Right vestibular schwannoma with maximum diameter of 41 × 35 × 35mm. MRI T1 contrast-enhanced image before first surgery (a). MRI T1 contrast-enhanced image of Gamma Knife Radiosurgery (GKR) treatment planning (b). MRI T2 image at 18 months after GKR (c); peritumoral brain edema (PTBE) in the right cerebellar hemisphere and brain stem is clearly visible. MRI T2 at image 3 months after surgical removal showing complete PTBE resolution (d).

neurological symptoms. High dose corticosteroid therapy was administered for 1 month without clinical improvement. A brain MRI revealed an important increase in the size of the residual tumor with large PTBE in cerebellum and brainstem with fourth ventricle compression and hydrocephalus [Figure 2c]; this potentially life-threatening condition led us to prompt surgery. A macroscopically radical removal of the tumor with facial nerve sacrifice was performed. Of note, no evident signs of brainstem or cerebellar swelling were found during surgery. Histopathological analysis reconfirmed the presence of a schwannoma. Three months after surgery, brain MRI showed the complete reabsorption of PTBE in cerebellum and brainstem [Figure 2d]. At 2 year follow-up the MRI showed no tumor recurrence.

Case 3

A 60-year-old woman had an incidental diagnosis of right clinoid meningioma. The lesion was about 2 cm diameter with moderate PTBE [Figure 3a]. She underwent upfront GKR in five fractions (PTV 6.263 cm³, 25 Gy isodose 50%) at another Institution. In this patient, the procedure was performed with Gamma Knife Icon, 5 Gy per fraction. Eight months later, she started to complain of headache, dizziness, and asthenia. A brain MRI showed a significant increase

in PTBE with compression of the frontal horn of the right lateral ventricle and a millimetric shift of the midline. At that time, surgical treatment was excluded due to possible risks of swelling related to extensive PTBE. Therefore, long lasting high-dose corticosteroid therapy was instituted without benefit, while iatrogenic Cushing disease and psychiatric disorders appeared. She presented at our institution after 12 months and, in light of our previous experience, we proposed radical surgical removal of the lesion. The brain did not appear swollen, allowing the removal of the tumor without the use of retractors. Histopathological examination confirmed a meningothelial meningioma (Grade I WHO) [Figure 3b]. Steroids were immediately reduced and a rapid improvement in symptoms was observed in a few weeks. A brain MRI performed 2 months after surgery showed near complete resolution of the pre-existing PTBE [Figure 3c and d]. At 2 year follow-up, the patient is well and brain MRI does not show tumor recurrence.

DISCUSSION

Herein, we present three cases of extensive PTBE after SRS where surgery was carried out after medical therapy had failed. All patients had some risk factors for developing PTBE. While symptomatic PTBE is normally treated with high-dose of steroids or osmotherapy, severe side effects such bowel perforation or Cushing disease, as described in Cases 1 and 3, respectively, must be considered. A relief effect of bevacizumab on edema induced by radiotherapy, mainly in malignant tumors, has been described.^[12,25,31,32] However, there is still no hard evidence of an impact on overall survival and toxicity-related data remain limited. Italian Authorities approved the use of bevacizumab in the context of recurrent cerebral neoplasms and radiation-induced peritumoral edema since January 2021; therefore, it was not routinely used in our institution. Interestingly, although not the case for meningiomas, bevacizumab has been shown to have longstanding local control on Neurofibromatosis-2 related schwannomas.^[18,20] Our report supports the idea of taking early into consideration the surgical removal of the tumor to reduce PTBE whenever it is critical and symptomatic.^[24] This management would avoid the occurrence of the severe side effects of long-term steroid administration and prevent worsening of neurological symptoms.

Moreover, the presence of massive PTBE did not imply dangerous intraoperative brain swelling in our series. Cerebral edema is sometimes thought of as synonymous of brain swelling that is quite true in neurotraumatology and in cerebral infarction. However, equally important are the biomechanical properties of the brain, such as its ability for elastic distortion. In radiated meningiomas hyperpermeability of blood vessels^[6,11] and disruption of the arachnoid and pia mater membranes, which are natural

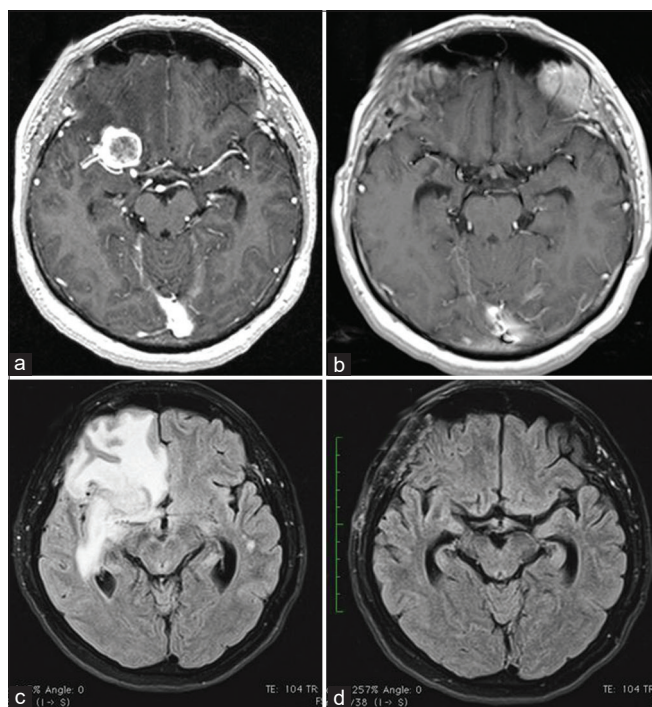


Figure 3: Right clinoid meningioma. MRI T1 contrast-enhanced images before (a) and after (b) surgery showing complete removal of the meningioma. MRI flair images highlight peritumoral brain edema before surgery (c) and at 2 months after surgery (d); an almost complete resolution is clear.

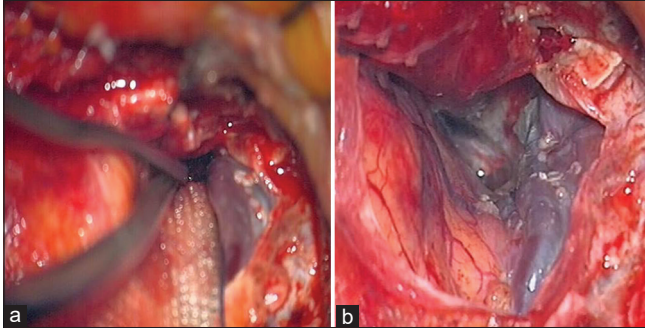


Figure 4: Right clinoid meningioma. Arterialized sylvian vein dissected opening the sylvian fissure before tumor removal (a). At the end of tumor removal, the color of the vein turned blue (b).

barriers to free movement of water, electrolytes, and proteins, have been observed. This condition promotes the flow of molecules from tumor necrosis to adjacent cerebral white matter. As a result, the extracellular fluid increases and edema develops, while the blood-brain barrier is not primarily injured, unlike in ischemia and trauma. Therefore, the radiated tumor and damaged tumor-brain contact interface are the true source of edema.^[2,3,10] As the integrity of the peritumoral blood-brain barrier in extra-axial brain tumors (i.e. meningiomas and schwannomas) is well recognized,^[1] the proposed pathophysiology would explain the delay of months between radiation and PTBE formation. We speculate that the integrity of the blood-brain barrier reduces brain elastic capacity, thereby increasing brain stiffness and decreasing its tendency to swell.

Regional impairment of venous drainage from the brain may also contribute to PTBE formation. Indeed, in case 3 a completely arterialized sylvian vein was noticed [Figure 4]. We believe that this was strictly related to the massive PTBE, as it is described in convexity meningiomas treated with SRS.

CONCLUSION

Although it is common knowledge that extensive PTBE complicates surgery and influences surgical outcome, prognosis, and risk of recurrence,^[17,22,26,27] the absence in our experience of significant brain swelling during surgery should encourage the neurosurgeon to aggressively treat without delay those cases that show widespread radiological edema associated with neurological worsening. In addition, long-term side effects of high dose corticosteroid might be very burdensome and their systemic use should be minimized.

In this setting indications for surgery are the presence of symptomatic PTBE induced by SRS, evident brain shift due to extensive PTBE, ineffective long-lasting medical treatment, and low surgical risks. However, decision-making must be individualized according to patient features, to the existence

of a possible rapid evolving neurological worsening, and to the response to medical therapy and its side effects.

Declaration of patient consent

Patient's consent not required as patients identity is not disclosed or compromised.

Financial support and sponsorship

Nil.

Conflicts of interest

There are no conflicts of interest.

REFERENCES

1. Bhowmik A, Khan R, Ghosh MK. Blood brain barrier: A challenge for effectual therapy of brain tumors. *Biomed Res Int* 2015;2015:320941.
2. Budday S, Sommer G, Birkl C, Langkammer C, Haybaeck J, Kohnert J, *et al.* Mechanical characterization of human brain tissue. *Acta Biomater* 2017;48:319-40.
3. Cai R, Barnett GH, Novak E, Chao ST, Suh JH. Principal risk of peritumoral edema after stereotactic radiosurgery for intracranial meningioma is tumor-brain contact interface area. *Neurosurgery* 2010;66:513-22.
4. Chang JH, Chang JW, Choi JY, Park YG, Chung SS. Complications after gamma knife radiosurgery for benign meningiomas. *J Neurol Neurosurg Psychiatry* 2003;74:226-30.
5. El Shehaby A, Ganz JC, Reda WA, Hafez A. Mechanisms of edema after gamma knife surgery for meningiomas-report of two cases. *J Neurosurg* 2005;102:1-3.
6. Gilbert JJ, Paulseth JE, Coates RK, Malott D. Cerebral edema associated with meningiomas. *Neurosurgery* 1983;12:599-605.
7. Hasegawa T, Kida Y, Kato T, Iizuka H, Kuramitsu S, Yamamoto T. Long-term safety and efficacy of stereotactic radiosurgery for vestibular schwannomas: Evaluation of 440 patients more than 10 years after treatment with Gamma Knife surgery. *J Neurosurg* 2013;118:557-65.
8. Hasegawa T, Kida Y, Kobayashi T, Yoshimoto M, Mori Y, Yoshida J. Long-term outcomes in patients with vestibular schwannomas treated using gamma knife surgery: 10-year follow up. *J Neurosurg* 2005;102:10-6.
9. Hoe Y, Choi YJ, Kim JH, Kwon DH, Kim CJ, Cho YH. Peritumoral brain edema after stereotactic radiosurgery for asymptomatic intracranial meningiomas: Risks and pattern of evolution. *J Korean Neurosurg Soc* 2015;58:379-84.
10. Hossmann KA, Wechsler W, Wilmes F. Experimental peritumorous edema, Morphological and pathophysiological observations. *Acta Neuropathol* 1979;45:195-203.
11. Hou J, Kshetry VR, Selman WR, Bambakidis NC. Peritumoral brain edema in intracranial meningiomas: The emergence of vascular endothelial growth factor-directed therapy. *Neurosurg Focus* 2013;35:E2.
12. Khan M, Zhao Z, Arooj S, Liao G. Bevacizumab for radiation necrosis following radiotherapy of brain metastatic disease:

- A systematic review and meta-analysis. *BMC Cancer* 2021;21:167.
13. Kobayashi T, Kida Y, Mori Y. Long-term results of stereotactic gamma radiosurgery of meningiomas. *Surg Neurol* 2001;55:325-31.
 14. Lunsford LD, Niranjan A, Flickinger JC, Maitz A, Kondziolka D. Radiosurgery of vestibular schwannomas: Summary of experience in 829 cases. *J Neurosurg* 2005;102:195-9.
 15. Mindermann T, Schlegel I. Grading of vestibular schwannomas and corresponding tumor volumes: Ramifications for radiosurgery. *Acta Neurochir (Wien)* 2013;155:71-4.
 16. Morgan TM, Zaenger D, Switchenko JM, Eaton BR, Crocker IR, Ali AN, *et al.* Fractionated radiotherapy is associated with lower rates of treatment-related edema than stereotactic radiosurgery in magnetic resonance imaging-defined meningiomas. *World Neurosurg* 2019;121:e640-6.
 17. Novotný J Jr., Kollová A, Liscák R. Prediction of intracranial edema after radiosurgery of meningiomas. *J Neurosurg* 2006;105:120-6.
 18. Nunes FP, Merker VL, Jennings D, Caruso PA, di Tomaso E, Muzikansky A, *et al.* Bevacizumab treatment for meningiomas in NF2: A retrospective analysis of 15 patients. *PLoS One* 2013;8:e59941.
 19. O'Connor KP, Algan O, Vesely SK, Palejwala AH, Briggs RG, Conner AK, *et al.* Factors associated with treatment failure and radiosurgery-related edema in WHO grade 1 and 2 meningioma patients receiving gamma knife radiosurgery. *World Neurosurg* 2019;130:e558-65.
 20. Plotkin SR, Duda DG, Muzikansky A, Allen J, Blakeley J, Rosser T, *et al.* Multicenter, prospective, Phase II and biomarker study of high-dose bevacizumab as induction therapy in patients with neurofibromatosis Type 2 and progressive vestibular schwannoma. *J Clin Oncol* 2019;37:3446-54.
 21. ReMine SG, McIlrath DC. Bowel perforation in steroid-treated patients. *Ann Surg* 1980;192:581-6.
 22. Salpietro FM, Alafaci C, Lucerna S, Iacopino DG, Todaro C, Tomasello F. Peritumoral edema in meningiomas: Microsurgical observations of different brain tumor interfaces related to computed tomography. *Neurosurgery* 1994;35:638-41.
 23. Santacrose A, Walier M, Régis J, Liščák R, Motti E, Lindquist C, *et al.* Long-term tumor control of benign intracranial meningiomas after radiosurgery in a series of 4565 patients. *Neurosurgery* 2012;70:32-9.
 24. Sheehan JP, Lee CC, Xu Z, Przybylowski CJ, Melmer PD, Schlesinger D. Edema following Gamma knife radiosurgery for parasagittal and parafalcine meningiomas. *J Neurosurg* 2015;123:1287-93.
 25. Shen G, Wang YJ, Guan YJ, Dong DP, Yang G, Li D, *et al.* Relief effect of bevacizumab on severe edema induced by re-irradiation in brain tumor patients. *Chin Med J (Engl)* 2015;128:2126-9.
 26. Shirotani T, Shima K, Chigasaki H. Resolution of peritumoral brain edema following excision of meningioma. *Acta Neurochir Suppl (Wien)* 1994;60:416-8.
 27. Sindou M, Alaywan M. Role of pia-mater vascularization of the tumour in the surgical outcome of intracranial meningiomas. *Acta Neurochir* 1994;130:90-3.
 28. Singh VP, Kansai S, Vaishya S, Julka PK, Mehta VS. Early complications following gamma knife radiosurgery for intracranial meningiomas. *J Neurosurg* 2000;93 Suppl 3:57-61.
 29. Stafford SL, Pollock BE, Foote RL, Link MJ, Gorman DA, Schomberg PJ, *et al.* Meningioma radiosurgery: Tumor control, outcomes, and complications among 190 consecutive patients. *Neurosurgery* 2001;49:1029-37.
 30. Unger KR, Lominska CE, Chanyasulkit J, Randolph-Jackson P, White RL, Aulisi E, *et al.* Risk factors for posttreatment edema in patients treated with stereotactic radiosurgery for meningiomas. *Neurosurgery* 2012;70:639-45.
 31. Yamasaki F, Kolakshyapati M, Takano M, Yonezawa U, Nishibuchi I, Imano N, *et al.* Effect of bevacizumab against cystic components of brain tumors. *Cancer Med* 2019;8:6519-27.
 32. Zhuang H, Shi S, Yuan Z, Chang JY. Bevacizumab treatment for radiation brain necrosis: Mechanism, efficacy and issues. *Mol Cancer* 2019;18:21.

How to cite this article: Stefini R, Peron S, Lacamera A, Cividini A, Fiaschi P, Sicuri GM. The positive effects of surgery on symptomatic stereotactic radiation-induced peritumoral brain edema: A report of three cases. *Surg Neurol Int* 2021;12:358.