


RESEARCH ARTICLE

Open Access



# Experience using mTOR inhibitors for subependymal giant cell astrocytoma in tuberous sclerosis complex at a single facility

Kyoichi Tomoto<sup>1</sup>, Ayataka Fujimoto<sup>1,2\*</sup> , Chikanori Inenaga<sup>1</sup>, Tohru Okanishi<sup>2</sup>, Shin Imai<sup>2</sup>, Masaaki Ogai<sup>2</sup>, Akiko Fukunaga<sup>2</sup>, Hidenori Nakamura<sup>2</sup>, Keishiro Sato<sup>2</sup>, Akira Obana<sup>2</sup>, Takayuki Masui<sup>2</sup>, Yoshifumi Arai<sup>2</sup> and Hideo Enoki<sup>2</sup>

## Abstract

**Background:** Subependymal giant cell astrocytoma (SEGA) is occasionally seen in tuberous sclerosis complex (TSC). Two main options are currently available for treating SEGA: surgical resection or pharmacotherapy using mammalian target of rapamycin inhibitors (mTORi). We hypothesized that opportunities for surgical resection of SEGA would have reduced with the advent of mTORi.

**Methods:** We retrospectively reviewed the charts of patients treated between August 1979 and July 2020, divided into a pre-mTORi era group (Pre-group) of patients treated before November 2012, and a post-mTORi era group (Post-group) comprising patients treated from November 2012, when mTORi became available in Japan for SEGA. We compared groups in terms of treatment with surgery or mTORi. We also reviewed SEGA size, rate of acute hydrocephalus, recurrence of SEGA, malignant transformation and adverse effects of mTORi.

**Results:** In total, 120 patients with TSC visited our facility, including 24 patients with SEGA. Surgical resection was significantly more frequent in the Pre-group (6 of 7 patients, 86 %) than in the Post-group (2 of 17 patients, 12 %;  $p = 0.001$ ). Acute hydrocephalus was seen in 1 patient (4 %), and no patients showed malignant transformation of SEGA. The group treated using mTORi showed significantly smaller SEGA compared with the group treated under a wait-and-see policy ( $p = 0.012$ ). Adverse effects of pharmacotherapy were identified in seven (64 %; 6 oral ulcers, 1 irregular menstruation) of the 11 patients receiving mTORi.

**Conclusions:** The Post-group underwent surgery significantly less often than the Pre-group. Since the treatment option to use mTORi in the treatment of SEGA in TSC became available, opportunities for surgical resection have decreased in our facility.

**Keywords:** Subependymal giant cell astrocytoma (SEGA), Tuberous sclerosis complex (TSC), Mammalian target of rapamycin inhibitor (mTORi), Surgery, Hydrocephalus, Interdisciplinary team

\* Correspondence: [afujimotoscienceacademy@gmail.com](mailto:afujimotoscienceacademy@gmail.com)

<sup>1</sup>Department of Neurosurgery, Seirei Hamamatsu General Hospital, 2-12-12 Sumiyoshi, Nakaku, Hamamatsu 430-8558 Shizuoka, Japan

<sup>2</sup>Tuberous Sclerosis Complex Board, Seirei Hamamatsu General Hospital, 2-12-12 Sumiyoshi, Nakaku, Hamamatsu 430-8558 Shizuoka, Japan



© The Author(s). 2021 **Open Access** This article is licensed under a Creative Commons Attribution 4.0 International License, which permits use, sharing, adaptation, distribution and reproduction in any medium or format, as long as you give appropriate credit to the original author(s) and the source, provide a link to the Creative Commons licence, and indicate if changes were made. The images or other third party material in this article are included in the article's Creative Commons licence, unless indicated otherwise in a credit line to the material. If material is not included in the article's Creative Commons licence and your intended use is not permitted by statutory regulation or exceeds the permitted use, you will need to obtain permission directly from the copyright holder. To view a copy of this licence, visit <http://creativecommons.org/licenses/by/4.0/>. The Creative Commons Public Domain Dedication waiver (<http://creativecommons.org/publicdomain/zero/1.0/>) applies to the data made available in this article, unless otherwise stated in a credit line to the data.

## Background

Subependymal giant cell astrocytoma (SEGA) is often seen in patients with tuberous sclerosis complex (TSC), with a reported frequency of 1–27.4% [1–7]. Management of SEGA used to involve resection in open cranial surgery [8, 9], because SEGA may cause hydrocephalus [10], and, in rare cases, malignant transformation [11] or intra-tumoral hemorrhage [12]. Patients with SEGA may even undergo laser ablation [13, 14] or endoscopic surgery [15–19]. However, as TSC is a systemic disease, most patients with TSC suffer from not only SEGA, but also pathologies such as renal, pulmonary, dermatological, and ophthalmological diseases. This is because the mechanisms underlying TSC involve abnormal up-regulation of the mammalian target of rapamycin (mTOR) pathway in patients with TSC and subsequent tumor growth in various organs. Interdisciplinary medical management is thus required for the treatment of TSC [3, 20, 21]. The importance of interdisciplinary medical management for TSC is nowadays acknowledged by many physicians who treat patients with TSC. This is probably due to the availability of mTOR inhibitors (mTORi) [7]. As mTORi show efficacy against not only SEGA, but also pathologies such as renal angiomyolipoma [22, 23], epileptic seizures [24], neuropsychiatric disorders [25], and lymphangioliomyoma [26, 27] over a wide age range [28], the situation surrounding patients with TSC has become more complicated. Patients with SEGA should thus be followed-up by a well-organized interdisciplinary team including internal and surgical physicians [3, 20]. The current treatment strategy for SEGA entails two treatment options: surgical removal or a pharmacotherapeutic approach using mTORi [29]. Theoretically, given these two options, the probability of a patient undergoing resective surgery would be reduced. In this study, we hypothesized that opportunities for surgical treatment of SEGA would have decreased since the introduction of mTORi. The purpose of this study was thus to compare the frequency of surgical treatment for SEGA between the pre- and post-mTORi eras as a primary outcome measure. We also monitored the size of SEGA and the adverse effects of mTORi, and examined differences in treatment goals for SEGA before and after the advent of mTORi by reviewing rates of acute hydrocephalus, malignant transformation and reasons for surgery as secondary outcome measures.

## Methods

### Study design

Participants in this cross-sectional, observational, non-randomized study were identified from a retrospective review of medical charts for patients treated between August 1979 and July 2020 by the Tuberous Sclerosis Board at Seirei Hamamatsu General Hospital. This study

was conducted as an analytical comparative study, and not as a descriptive study, so it did not represent a case-series study. Moreover, since results were obtained retrospectively and interventions were not applied to patients to obtain the data for this study, it did not represent an interventional study.

### Clinical information

We retrospectively reviewed patients with TSC who were diagnosed genetically or clinically in accordance with the clinical diagnostic criteria [30]. Inclusion criteria were: (1) uni- or bilateral SEGA observed on magnetic resonance imaging (MRI) of the brain; (2) MRI or computed tomography (CT) of the brain performed every 1–3 years; and (3) follow-up at >1 year. The neuroradiological criterion was included in accordance with the recommendations of the International Tuberous Sclerosis Complex Consensus Conference [31, 32]. SEGAs in this study were defined as lesions within the cerebral ventricles with maximum diameter  $\geq 10$  mm. We regarded lesions with maximum diameter < 10 mm as subependymal nodules and excluded those cases from the present study [33, 34].

### Outcome measurements

Among the enrolled patients, those patients diagnosed with SEGA before November 2012 were categorized into the pre-mTORi era group (Pre-group). Patients diagnosed with SEGA after November 2012 were categorized into the post-mTORi era group (Post-group). The cut-off of November 2012 was applied as the time when mTORi (everolimus) became available in Japan. Patients in the Post-group who exhibited tumor growth on serial MRI or CT took everolimus at 3 mg/m<sup>2</sup>/day. If no tumor growth was observed and other pathologies did not require everolimus, we adopted a wait-and-see policy. When a patient exhibited adverse effects from everolimus, the dose was reduced to every other day to 3 days/week, depending on symptoms. If adverse effects lasted a long time, patients could suspend the use of everolimus for a period of up to 1 month. Patients who stopped use of everolimus for >1 month were excluded from analysis in this study. We compared groups in terms of surgical and mTORi treatment.

We also reviewed the rate of acute hydrocephalus, the reason for surgical resection, rates of SEGA recurrence in the surgical and non-surgical subgroups, and the rate of malignant transformation. We monitored SEGA size before and after mTORi administration by serial MRI or CT for patients who receiving mTORi. Serial neuroimages were obtained every 1–3 years, in line with the recommendations of the International TSC consensus conference [32]. SEGA size was defined as the largest diameter on axial, coronal or sagittal MRI or axial CT.

We also reviewed adverse effects attributed to mTORi. For the reference, we also measured SEGA size just before SEGA resective surgery in the Pre-group.

### Statistical analysis

For statistical analyses of clinical data, we used Student's *t*-tests, and the Mann-Whitney U-tests, as well as Fisher's exact probability tests to compare patients who underwent resective surgery in the pre- and post-mTORi eras. Values of  $p < 0.05$  were considered statistically significant. All statistical analyses were performed using Sigma Plot version 14.0 software (Systat Software, San Jose, CA, USA).

## Results

### Clinical information

A total of 120 patients with TSC visited our facility, including 23 patients (19%) with SEGA who met the inclusion criteria for the study. One patient (Patient 4) had bilateral SEGAs. In that patient, one SEGA was surgically removed in the pre-mTORi era and the other was treated using mTORi. This patient was therefore counted twice. As a result, we analyzed 24 patients (16 males, 8 females) in total (Table 1). Age at presentation to our hospital ( $p = 0.031$ ) and current age ( $p = 0.002$ ) were both significantly lower in the Post-group than in the Pre-group.

### Outcome measurements

Six of the seven patients in the Pre-group underwent surgical resection of SEGA, while a wait-and-see policy was adopted for the remaining patient. In the Post-group, two of the 17 patients underwent surgical resection. An mTORi was administered (11 patients) or a wait-and-see policy was adopted (four patients) in the remaining 15 patients. Surgical resection of the SEGA was thus significantly more frequent in the pre-Group ( $p = 0.001$ ).

Clinical characteristics of the eight patients who underwent surgical resection across both eras are shown in Table 2. Five of these eight patients displayed an enlarged lateral ventricle on neuroimaging, but only one patient (Patient 3) exhibited symptoms of increased intracranial pressure (iICP), was diagnosed with

symptomatic acute hydrocephalus and underwent emergency surgery. All patients who did not undergo surgery were asymptomatic. Thus, only one of the 24 patients (4%) presented with acute iICP.

Only one patient (Patient 4) experienced SEGA growth, arising on the contra-surgical side. We administered mTORi for this tumor growth, and the tumor subsequently decreased in size. No cases of recurrence or malignant transformation were seen in any other patients.

Size of the SEGA treated by mTORi and size of the SEGA treated under a wait-and-see policy are shown in Fig. 1. SEGA size in the group administered mTORi ranged from 10.19 mm to 23.18 mm (mean, 12.87 mm; SD, 3.68 mm; median, 11.42 mm). SEGA size in the wait-and-see policy group ranged from 10.23 mm to 15.42 mm (mean, 12.72 mm; SD, 2.69 mm; median, 12.6 mm). The group treated by mTORi showed a significantly reduced SEGA size compared with the group treated using a wait-and-see policy ( $p = 0.012$ ). Adverse effects from mTORi were identified in seven (64%) of the 11 patients. Of these, six patients (54%) exhibited oral ulcers and one (10%) exhibited irregular menstruation. SEGA size just before resective surgery ranged from 10.98 mm to 31.1 mm (mean, 19.39 mm; SD, 7.65 mm; median, 18.62 mm). SEGA size in the group treated by resective surgery was not significantly larger than that in the mTORi treatment group ( $p = 0.054$ ). These data were only for the reference because neuroimages could not be collected just before the resective surgery from two of the patients and thus were not included in this measurement.

### Discussion

Obviously, the Post-group used mTORi more frequently than the Pre-group in our facility. This study, however, confirmed that the frequency of surgical resection was indeed reduced following the advent of mTORi.

In this study, only one of the 24 patients (4%) clinically exhibited acute iICP symptoms. However, other studies have reported a high rate of acute hydrocephalus, even with high mortality rates [9]. In the present study, only one patient showed acute hydrocephalus and no mortality occurred. SEGA size is related to the rate of

**Table 1** Clinical information for the pre- and post-mTORi eras

|                                       | pre-mTORi era                                 | post-mTORi era                                  | <i>p</i> -value |
|---------------------------------------|---|---|-----------------|
| Age at SEGA removal operation (years) | 6, 6-19 years, mean 10, median 8.5, SD 5.02   | 2, 1-9 years, mean 5, median 5, SD 5.65         | 0.407           |
| Age at mTORi administration (years)   | n/a   | 11, 0.8-24 years, mean 12.3, median 14, SD 8.17 | n/a             |
| Age at presentation to our hospital   | 7, 9-41 years, mean 22.6, median 19, SD 11.3  | 17, 0.8-23 years, mean 10.5, median 12, SD 7.7  | 0.031*          |
| Current age (years)                   | 7, 19-43 years, mean 29.9, median 29, SD 8.78 | 17, 1-29 years, mean 14, median 15, SD 8.16     | 0.002*          |
| Sex (male / female)                   | 3 f / 4 m                                     | 5 f / 12 m                                      |                 |

mTORi Mammalian target of rapamycin inhibitor, n/a Not available, SD Standard deviation, SEGA Subependymal giant cell astrocytoma

**Table 2** Clinical characteristics of 8 cases with surgically resected SEGA associated with TSC

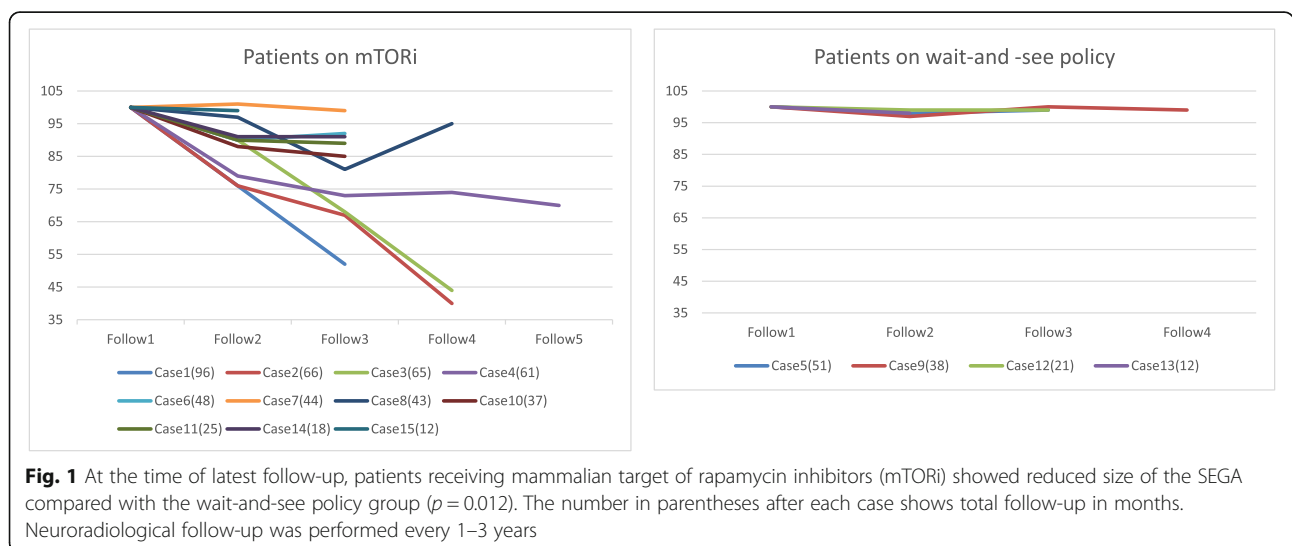
| Patient no. | Sex | Age at operation | Date of operation | Approaches to the SEGA                            | Symptoms of SEGA (reason for surgery)     |
|-------------|-----|------------------|-------------------|---|---|
| 1           | M   | 6                | pre-mTORi era     | surgical removal                                  | enlarged lateral ventricle (prophylactic) |
| 2           | M   | 10               | pre-mTORi era     | surgical removal (+ frontal lobe focus resection) | enlarged lateral ventricle (prophylactic) |
| 3           | F   | 19               | pre-mTORi era     | surgical removal (emergency)                      | acute hydrocephalus (cure of iICP)        |
| 4           | F   | 6                | pre-mTORi era     | VP shunt, then surgical removal                   | enlarged lateral ventricle (prophylactic) |
| 5           | M   | 12               | pre-mTORi era     | surgical removal                                  | none (prophylactic)                       |
| 6           | M   | 7                | pre-mTORi era     | surgical removal, then VP shunt                   | enlarged lateral ventricle (prophylactic) |
| 7           | M   | 9                | post-mTORi era    | surgical removal                                  | none (prophylactic)                       |
| 8           | F   | 1                | post-mTORi era    | surgical removal (+ total corpus callosotomy)     | none (prophylactic)                       |

F Female, M Male, SEGA Subependymal giant cell astrocytoma, VP shunt Ventriculoperitoneal shunt, iICP Increased intracranial pressure

hydrocephalus [35] and early diagnosis and early treatment by the mTORi are reported to successfully prevent hydrocephalus [36]. As age at presentation to our hospital was lower in the Post-group than in the Pre-group in this study, SEGA identification while still small might explain the lower rate of acute hydrocephalus.

Many reports have stated that SEGA grows near and occludes the foramen of Monro, leading to obstructive hydrocephalus. However, we know that some cases show apparent occlusion of the foramen on MRI while not exhibiting iICP symptoms and others do not show clear occlusion of the foramen but still exhibit symptoms of iICP. The theory of obstructive and communicating hydrocephalus is now known to be inadequate for explaining the pathophysiology of hydrocephalus. More complicated causative mechanisms must therefore be involved in hydrocephalus, such as brain compliance and osmotic pressure due to cerebrospinal fluid protein [37–40]. However, the classical theory is still often applied to the mechanisms underlying hydrocephalus with SEGA. The actual rate of acute hydrocephalus remains unclear,

with a wide variation in reported values of 38–80% [8, 9, 29, 41–44]. A huge discrepancy exists between the present study (4%) and those previous investigations. This was probably due to differences between treatment by an interdisciplinary team or a single department. A single department such as neurosurgery may see a patient with SEGA who visits their department with iICP symptoms. However, as tumor growth is age-dependent and the natural history of this pathological entity is well-known [45], expertise ranging from pediatrics to adult neurology and neurosurgery is required in terms of dealing with the hydrocephalus. Surgical and internal medical treatments have both positive and negative aspects [36, 46–48]. Among these, we must choose the best treatment for patients with SEGA in a well-organized interdisciplinary team. The present study found that we mostly treated SEGA prophylactically for fear of possible hydrocephalus, with only one patient with symptomatic hydrocephalus undergoing emergency tumor resection. Considering the high mortality and morbidity rates in patients with SEGA [45, 49], shifting the treatment



concept of SEGA from emergent hydrocephalus treatment by a single department to prophylactic treatment by an interdisciplinary team appears warranted.

Some differences between SEGA with and without iICP, such as variations in immunohistochemical features, genetic differences, and anaplastic features [50–52] or protein-producing functions [53, 54], may relate to brain compliance or osmotic pressure. However, this study could not address this question. In addition, whether mTORi ceased or reduced the protein-producing function of SEGA was also unclear in this study. As a perspective on future investigations, studies involving multiple facilities are required to clarify risk factors for SEGA with iICP in advance of determining optimal treatments.

## Conclusions

Since the treatment option to use mTORi in the treatment of SEGA in TSC became available, opportunities for surgical resection have decreased in our facility.

## Abbreviations

CT: Computed tomography; iICP: Increased intracranial pressure; mTOR: Mammalian target of rapamycin; mTORi: Mammalian target of rapamycin inhibitor; MRI: Magnetic resonance imaging; SEGA: Subependymal giant cell astrocytoma; TSC: Tuberous sclerosis complex

## Acknowledgements

We are grateful to all the medical staff on our interdisciplinary team for treating the patients with tuberous sclerosis complex.

## Authors' contributions

All authors made substantial contributions to the conception, validation, design, acquisition of data, or analysis and interpretation of data, as follows: methodology, KT, AF1; TO; investigation, KS, AF1, CI; resources, AF1, SI, MO, AF2; data curation, HN, KS, AO, TM; writing of the original draft, AF1; writing, review, and editing, AF1; visualization, YA; supervision, AO, HE; and project administration, AF1. All authors read and approved the final manuscript.

## Funding

No external funding was received for this research.

## Availability of data and materials

All data in support of our findings are presented within this manuscript.

## Declarations

### Ethics approval, and consent to participate

The ethics committee at Seirei Hamamatsu General Hospital approved the protocol for this study (approval no. 3390), which was performed in accordance with the principles of the Declaration of Helsinki. All patients, or the parents of pediatric patients, provided written informed consent for the publication of case details.

### Consent for publication

Written consent for publication was obtained from all patients and/or parents of the patients in this study.

### Competing interests

The authors declare no conflicts of interest.

Received: 1 October 2020 Accepted: 15 March 2021

Published online: 31 March 2021

## References

- Russo C, Nastro A, Cicala D, De Liso M, Covelli EM, Cinalli G. Neuroimaging in tuberous sclerosis complex. *Childs Nerv Syst.* 2020. <https://doi.org/10.1007/s00381-020-04705-4>.
- Wahaya-Kaneda M, Tanaka M, Hamasaki T, Katayama I. Trends in the prevalence of tuberous sclerosis complex manifestations: an epidemiological study of 166 Japanese patients. *PloS one.* 2013;8:e63910. <https://doi.org/10.1371/journal.pone.0063910>.
- Fujimoto A, Okanishi T, Imai S, Ogai M, Fukunaga A, Nakamura H, Sato K, Obana A, Masui T, Arai Y, Enoki H. Establishment of a regional interdisciplinary medical system for managing patients with tuberous sclerosis complex (TSC). *Sci Rep.* 2018;8:16747. <https://doi.org/10.1038/s41598-018-35168-y>.
- Jansen AC, Belousova E, Benedik MP, Carter T, Cottin V, Curatolo P, D'Amato L, Beure d'Augères G, de Vries PJ, Ferreira JC, Feucht M, Fladrowski C, Hertzberg C, Jozwiak S, Lawson JA, Macaya A, Marques R, Nabbout R, O'Callaghan F, Qin J, Sander V, Sauter M, Shah S, Takahashi Y, Touraine R, Youroukos S, Zonnenberg B, Kingswood JC. Newly diagnosed and growing subependymal giant cell astrocytoma in adults with tuberous sclerosis complex: results from the international TOSCA study. *Front Neurol.* 2019;10:821. <https://doi.org/10.3389/fneur.2019.00821>.
- Jansen AC, Belousova E, Benedik MP, Carter T, Cottin V, Curatolo P, Dahlin M, D'Amato L, d'Augères GB, de Vries PJ, Ferreira JC, Feucht M, Fladrowski C, Hertzberg C, Jozwiak S, Lawson JA, Macaya A, Marques R, Nabbout R, O'Callaghan F, Qin J, Sander V, Sauter M, Shah S, Takahashi Y, Touraine R, Youroukos S, Zonnenberg B, Kingswood JC. Clinical characteristics of subependymal giant cell astrocytoma in tuberous sclerosis complex. *Front Neurol.* 2019;10:705. <https://doi.org/10.3389/fneur.2019.00705>.
- Curatolo P, Bjørnvold M, Dill PE, Ferreira JC, Feucht M, Hertzberg C, Jansen A, Józwiak S, Kingswood JC, Kotulska K, Macaya A, Moavero R, Nabbout R, Zonnenberg BA. The role of mTOR inhibitors in the treatment of patients with tuberous sclerosis complex: evidence-based and expert opinions. *Drugs.* 2016;76:551–65. <https://doi.org/10.1007/s40265-016-0552-9>.
- Franz DN, Belousova E, Sparagana S, Bebin EM, Frost M, Kuperman R, Witt O, Kohrman MH, Flamini JR, Wu JY, Curatolo P, de Vries PJ, Berkowitz N, Anak O, Niolat J, Jozwiak S. Everolimus for subependymal giant cell astrocytoma in patients with tuberous sclerosis complex: 2-year open-label extension of the randomised EXIST-1 study. *Lancet Oncol.* 2014;15:1513–20. [https://doi.org/10.1016/s1470-2045\(14\)70489-9](https://doi.org/10.1016/s1470-2045(14)70489-9).
- Fohlen M, Ferrand-Sorbets S, Delalande O, Dorfmueller G. Surgery for subependymal giant cell astrocytomas in children with tuberous sclerosis complex. *Childs Nerv Syst.* 2018;34:1511–9. <https://doi.org/10.1007/s00381-018-3826-6>.
- Giordano F, Moscheo C, Lenge M, Biagiotti R, Mari F, Sardi I, Buccoliero AM, Mongardi L, Aronica E, Guerrini R, Genitori L. Neurosurgical treatment of subependymal giant cell astrocytomas in tuberous sclerosis complex: a series of 44 surgical procedures in 31 patients. *Childs Nerv Syst.* 2020;36:951–60. <https://doi.org/10.1007/s00381-019-04449-w>.
- Lu DS, Karas PJ, Krueger DA, Weiner HL. Central nervous system manifestations of tuberous sclerosis complex. *Am J Med Genet C Semin Med Genet.* 2018;178:291–8. <https://doi.org/10.1002/ajmg.c.31647>.
- Chan DL, Calder T, Lawson JA, Mowat D, Kennedy SE. The natural history of subependymal giant cell astrocytomas in tuberous sclerosis complex: a review. *Rev Neurosci.* 2018;29:295–301. <https://doi.org/10.1515/revneuro-2017-0027>.
- Ouyang T, Zhang N, Benjamin T, Wang L, Jiao J, Zhao Y, Chen J. Subependymal giant cell astrocytoma: current concepts, management, and future directions. *Childs Nerv Syst.* 2014;30:561–70. <https://doi.org/10.1007/s00381-014-2383-x>.
- Desai VR, Jenson AV, Hoverson E, Desai RM, Boghani Z, Lee MR. Stereotactic laser ablation for subependymal giant cell astrocytomas: personal experience and review of the literature. *Childs Nerv Syst.* 2020. <https://doi.org/10.1007/s00381-020-04638-y>.
- Feroze AH, McGrath M, Williams JR, Young CC, Ene CI, Buckley RT, Cole BL, Ojemann JG, Hauptman JS. Laser interstitial thermal therapy for pediatric atypical teratoid/rhabdoid tumor: case report. *Neurosurg Focus.* 2020;48:E11. <https://doi.org/10.3171/2019.10.Focus19746>.

15. Cinalli G, Imperato A, Mirone G, Di Martino G, Nicosia G, Ruggiero C, Aliberti F, Spennato P. Initial experience with endoscopic ultrasonic aspirator in purely neuroendoscopic removal of intraventricular tumors. *J Neurosurg Pediatr.* 2017;19:325–32. <https://doi.org/10.3171/2016.10.Peds16352>.
16. Harter DH, Bassani L, Rodgers SD, Roth J, Devinsky O, Carlson C, Wisoff JH, Weiner HL. A management strategy for intraventricular subependymal giant cell astrocytomas in tuberous sclerosis complex. *J Neurosurg Pediatr.* 2014;13:21–8. <https://doi.org/10.3171/2013.9.Peds13193>.
17. Hidalgo ET, Ali A, Weiner HL, Harter DH. Resection of intraventricular tumors in children by purely endoscopic means. *World Neurosurg.* 2016;87:372–80. <https://doi.org/10.1016/j.wneu.2015.11.052>.
18. Rodgers SD, Bassani L, Weiner HL, Harter DH. Stereotactic endoscopic resection and surgical management of a subependymal giant cell astrocytoma: case report. *J Neurosurg Pediatr.* 2012;9:417–20. <https://doi.org/10.3171/2011.12.Peds11349>.
19. Tawk RG, Akinduro OO, Grewal SS, Brasiliense L, Grand W, Grotenhuis A. Endoscopic transforaminal transchoroidal approach to the third ventricle for cystic and solid tumors. *World Neurosurg.* 2020;134:e453–9. <https://doi.org/10.1016/j.wneu.2019.10.099>.
20. Auvin S, Bissler JJ, Cottin V, Fujimoto A, Hofbauer GFL, Jansen AC, Jóźwiak S, Kerecuk L, Kingswood JC, Moavero R, Torra R, Villanueva V. A step-wise approach for establishing a multidisciplinary team for the management of tuberous sclerosis complex: a Delphi consensus report. *Orphanet J Rare Dis.* 2019;14:91. <https://doi.org/10.1186/s13023-019-1072-y>.
21. Alsawat D, Zak M, McCoy B, Kabir N, Al-Mehmadi S, Chan V, Whitney R. A review of investigations for patients with tuberous sclerosis complex who were referred to the tuberous sclerosis clinic at the hospital for sick children: identifying gaps in surveillance. *Pediatr Neurol.* 2020;102:44–8. <https://doi.org/10.1016/j.pediatrneurol.2019.06.018>.
22. Franz DN, Belousova E, Sparagana S, Bebin EM, Frost MD, Kuperman R, Witt O, Kohrman MH, Flamini JR, Wu JY, Curatolo P, de Vries PJ, Berkowitz N, Niolat J, Jóźwiak S. Long-term use of everolimus in patients with tuberous sclerosis complex: final results from the EXIST-1 study. *PloS one.* 2016;11:e0158476. <https://doi.org/10.1371/journal.pone.0158476>.
23. Kingswood JC, Jozwiak S, Belousova ED, Frost MD, Kuperman RA, Bebin EM, Korf BR, Flamini JR, Kohrman MH, Sparagana SP, Wu JY, Brechenmacher T, Stein K, Berkowitz N, Bissler JJ, Franz DN. The effect of everolimus on renal angiomyolipoma in patients with tuberous sclerosis complex being treated for subependymal giant cell astrocytoma: subgroup results from the randomized, placebo-controlled, Phase 3 trial EXIST-1. *Nephrol Dial Transplant.* 2014;29:1203–10. <https://doi.org/10.1093/ndt/gfu013>.
24. Franz DN, Lawson JA, Yapici Z, Ikeda H, Polster T, Nabbout R, Curatolo P, de Vries PJ, Dlugos DJ, Voi M, Fan J, Vaury A, Pelov D, French JA. Everolimus for treatment-refractory seizures in TSC: Extension of a randomized controlled trial. *Neurol Clin Pract.* 2018;8:412–20. <https://doi.org/10.1212/cpj.0000000000000514>.
25. Krueger DA. Management of CNS-related disease manifestations in patients with tuberous sclerosis complex. *Curr Treat Options Neurol.* 2013;15:618–33. <https://doi.org/10.1007/s11940-013-0249-2>.
26. Taveira-DaSilva AM, Moss J. Management of lymphangioliomyomatosis. *F1000 Prime Rep.* 2014;6:116. <https://doi.org/10.12703/p6-116>.
27. Chebib N, Archer F, Bobet-Erny A, Leroux C, Cottin V. Dysregulation of the endothelin pathway in lymphangioliomyomatosis with no direct effect on cell proliferation and migration. *Sci Rep.* 2018;8:14698. <https://doi.org/10.1038/s41598-018-32795-3>.
28. Krueger DA, Capal JK, Curatolo P, Devinsky O, Ess K, Tzadok M, Koenig MK, Narayanan V, Ramos F, Jozwiak S, de Vries P, Jansen AC, Wong M, Mowat D, Lawson J, Bruns S, Franz DN. Short-term safety of mTOR inhibitors in infants and very young children with tuberous sclerosis complex (TSC): Multicentre clinical experience. *Eur J Paediatr Neurol.* 2018;22:1066–73. <https://doi.org/10.1016/j.ejpn.2018.06.007>.
29. Weidman DR, Palasamudram S, Zak M, Whitney R, McCoy B, Bouffet E, Taylor M, Shroff M, Bartels U. The effect of mTOR inhibition on obstructive hydrocephalus in patients with tuberous sclerosis complex (TSC) related subependymal giant cell astrocytoma (SEGA). *J Neurooncol.* 2020;147:731–6. <https://doi.org/10.1007/s11060-020-03487-8>.
30. Roach ES, Gomez MR, Northrup H. Tuberous sclerosis complex consensus conference: revised clinical diagnostic criteria. *J Child Neurol.* 1998;13:624–8. <https://doi.org/10.1177/088307389801301206>.
31. Northrup H, Krueger DA, Northrup H, Krueger DA, Roberds S, Smith K, Sampson J, Korf B, Kwiatkowski DJ, Mowat D, Nellist M, Northrup H, Povey S, de Vries P, Byars A, Dunn D, Ess K, Hook D, Jansen A, King B, Sahin M, Whittemore V, Thiele E, Bebin EM, Chugani HT, Crino P, Curatolo P, Holmes G, Nabbout R, O'Callaghan F, Wheless J, Wu J, Darling TN, Cowen EW, Gosnell E, Hebert A, Mlynarczyk G, Soltani K, Teng J, Wataya-Kaneda M, Witman PM, Kingswood C, Bissler J, Budde K, Hulbert J, Guay-Woodford L, Sampson J, Sauter M, Zonneberg B, Jóźwiak S, Bartels U, Berhouma M, Franz DN, Koenig MK, Krueger DA, Roach ES, Roth J, Wang H, Weiner H, McCormack FX, Almoosa K, Brody A, Burger C, Cottin V, Finlay G, Glass J, Henske EP, Johnson S, Kotloff R, Lynch D, Moss J, Smith K, Rhu J, Da Silva AT, Young LR, Knilans T, Hinton R, Prakash A, Romp R, Singh AD, DebRoy A, Chen P-L, Sparagana S, Frost MD. Tuberous sclerosis complex diagnostic criteria update: recommendations of the 2012 international tuberous sclerosis complex consensus conference. *Pediatr Neurol.* 2013;49:243–54. <https://doi.org/10.1016/j.pediatrneurol.2013.08.0012013.08.001>.
32. Krueger DA, Northrup H, Northrup H, Krueger DA, Roberds S, Smith K, Sampson J, Korf B, Kwiatkowski DJ, Mowat D, Nellist M, Northrup H, Povey S, de Vries P, Byars A, Dunn D, Ess K, Hook D, Jansen A, King B, Sahin M, Whittemore V, Thiele E, Bebin EM, Chugani HT, Crino P, Curatolo P, Holmes G, Nabbout R, O'Callaghan F, Wheless J, Wu J, Darling TN, Cowen EW, Witman PM, Kingswood C, Bissler J, Budde K, Hulbert J, Guay-Woodford L, Sampson J, Sauter M, Zonneberg B, Jóźwiak S, Bartels U, Berhouma M, Franz DN, Koenig MK, Krueger DA, Roach ES, Roth J, Wang H, Weiner H, McCormack FX, Almoosa K, Brody A, Burger C, Cottin V, Finlay G, Glass J, Henske EP, Johnson S, Kotloff R, Lynch D, Moss J, Smith K, Rhu J, Da Silva AT, Young LR, Knilans T, Hinton R, Prakash A, Romp R, Singh AD, DebRoy A, Chen P-L, Sparagana S, Frost MD. Tuberous sclerosis complex surveillance and management: recommendations of the 2012 international tuberous sclerosis complex consensus conference. *Pediatr Neurol.* 2013;49:255–65. <https://doi.org/10.1016/j.pediatrneurol.2013.08.0022013.08.002>.
33. Nabbout R, Santos M, Rolland Y, Delalande O, Dulac O, Chiron C. Early diagnosis of subependymal giant cell astrocytoma in children with tuberous sclerosis. *J Neurol Neurosurg Psychiatry.* 1999;66:370–5. <https://doi.org/10.1136/jnnp.66.3.370>.
34. Roth J, Roach ES, Bartels U, Jóźwiak S, Koenig MK, Weiner HL, Franz DN, Wang HZ. Subependymal giant cell astrocytoma: diagnosis, screening, and treatment recommendations from the international tuberous sclerosis complex consensus conference 2012. *Pediatr Neurol.* 2013;49:439–44. <https://doi.org/10.1016/j.pediatrneurol.2013.08.0172013.08.017>.
35. Jóźwiak S, Mander A, Mlynarski W. Natural history and current treatment options for subependymal giant cell astrocytoma in tuberous sclerosis complex. *Semin Pediatr Neurol.* 2015;22:274–81. <https://doi.org/10.1016/j.spen.2015.10.003>.
36. Moavero R, Carai A, Mastronuzzi A, Marciano S, Graziola F, Vigeveno F, Curatolo P. Everolimus alleviates obstructive hydrocephalus due to subependymal giant cell astrocytomas. *Pediatr Neurol.* 2017;68:59–63. <https://doi.org/10.1016/j.pediatrneurol.2016.11.003>.
37. Orešković D, Klarica M. Development of hydrocephalus and classical hypothesis of cerebrospinal fluid hydrodynamics: facts and illusions. *Prog Neurobiol.* 2011;94:238–58. <https://doi.org/10.1016/j.pneurobio.2011.05.005>.
38. Arroyo MS, Krueger DA, Broomall E, Stevenson CB, Franz DN. Acute management of symptomatic subependymal giant cell astrocytoma with everolimus. *Pediatr Neurol.* 2017. <https://doi.org/10.1016/j.pediatrneurol.2017.04.008>.
39. Fujimoto A, Matsumura A, Maruno T, Yasuda S, Yamamoto M, Nose T. Normal pressure hydrocephalus after gamma knife radiosurgery for cerebellopontine angle meningioma. *J Clin Neurosci.* 2004;11:785–7. <https://doi.org/10.1016/j.jocn.2003.12.016>.
40. Orešković D, Maraković J, Varda R, Radoš M, Jurjević I, Klarica M. New insight into the mechanism of mannitol effects on cerebrospinal fluid pressure decrease and craniospinal fluid redistribution. *Neuroscience.* 2018;392:164–71. <https://doi.org/10.1016/j.neuroscience.2018.09.029>.
41. Cuccia V, Zuccaro G, Sosa F, Monges J, Lubienieký F, Taratuto AL. Subependymal giant cell astrocytoma in children with tuberous sclerosis. *Childs Nerv Syst.* 2003;19:232–43. <https://doi.org/10.1007/s00381-002-0700-2>.
42. Park KJ, Kano H, Kondziolka D, Niranjana A, Flickinger JC, Lunsford LD. Gamma Knife surgery for subependymal giant cell astrocytomas. *Clinical article. J Neurosurg.* 2011;114:808–13. <https://doi.org/10.3171/2010.9.Jns10816>.

43. Adriaensen ME, Schaefer-Prokop CM, Stijnen T, Duyndam DA, Zonnenberg BA, Prokop M. Prevalence of subependymal giant cell tumors in patients with tuberous sclerosis and a review of the literature. *Eur J Neurol.* 2009;16:691–6. <https://doi.org/10.1111/j.1468-1331.2009.02567.x>.
44. Kotulska K, Borkowska J, Manderla M, Roszkowski M, Jurkiewicz E, Grajkowska W, Bilka M, Jóźwiak S. Congenital subependymal giant cell astrocytomas in patients with tuberous sclerosis complex. *Childs Nerv Syst.* 2014;30:2037–42. <https://doi.org/10.1007/s00381-014-2555-8>.
45. Moavero R, Romagnoli G, Graziola F, Curatolo P. Mammalian target of rapamycin inhibitors and life-threatening conditions in tuberous sclerosis complex. *Semin Pediatr Neurol.* 2015;22:282–94. <https://doi.org/10.1016/j.spen.2015.10.006>.
46. Sun P, Kohrman M, Liu J, Guo A, Rogerio J, Krueger D. Outcomes of resecting subependymal giant cell astrocytoma (SEGA) among patients with SEGA-related tuberous sclerosis complex: a national claims database analysis. *Curr Med Res Opin.* 2012;28:657–63. <https://doi.org/10.1185/03007995.2012.658907>.
47. Berhouma M, Dubourg J, Messerer M. 2012 Neurology: Letter to the editor. Re: Sun P, Kohrman M, Liu J, et al. Outcomes of resecting subependymal giant cell astrocytoma (SEGA) among patients with SEGA-related tuberous sclerosis complex: a national claims database analysis. *Curr Med Res Opin.* 2012;28:657–63. <https://doi.org/10.1185/03007995.2012.719865> Current medical research and opinion 28: 1571–1572; author reply 1572–1573.
48. Li M, Zhou Y, Chen C, Yang T, Zhou S, Chen S, Wu Y, Cui Y. Efficacy and safety of mTOR inhibitors (rapamycin and its analogues) for tuberous sclerosis complex: a meta-analysis. *Orphanet J Rare Dis.* 2019;14:39. <https://doi.org/10.1186/s13023-019-1012-x>.
49. Jóźwiak S, Nabbout R, Curatolo P. Management of subependymal giant cell astrocytoma (SEGA) associated with tuberous sclerosis complex (TSC): Clinical recommendations. *Eur J Paediatr Neurol.* 2013;17:348–52. <https://doi.org/10.1016/j.ejpn.2012.12.008>.
50. Taraszewska A, Kroh H, Majchrowski A. Subependymal giant cell astrocytoma: clinical, histologic and immunohistochemical characteristic of 3 cases. *Folia Neuropathol.* 1997;35:181–6.
51. Grajkowska W, Kotulska K, Jurkiewicz E, Roszkowski M, Daszkiewicz P, Jóźwiak S, Matyja E. Subependymal giant cell astrocytomas with atypical histological features mimicking malignant gliomas. *Folia Neuropathol.* 2011;49:39–46.
52. Bongaarts A, de Jong JM, Broekaart DWM, van Scheppingen J, Anink JJ, Mijnsbergen C, Jansen FE, Spliet WGM, den Dunnen WFA, Gruber VE, Scholl T, Hainfellner JA, Feucht M, Borkowska J, Kotulska K, Jozwiak S, Grajkowska W, Buccoliero AM, Caporalini C, Giordano F, Genitori L, Scicluna BP, -van SchoutenMeeteren AYN, van Vliet EA, Mühlebner A, Mills JD, Aronica E. Dysregulation of the MMP/TIMP proteolytic system in subependymal giant cell astrocytomas in patients with tuberous sclerosis complex: modulation of MMP by MicroRNA-320d in vitro. *J Neuropathol Exp Neurol.* 2020;79:777–90. <https://doi.org/10.1093/jnen/nlaa040>.
53. Kasper E, Laviv Y, Sebai ME, Lin N, Butler W. Subependymal giant cell astrocytoma: associated hyperproteinorrachia causing shunt failures and nonobstructive hydrocephalus - report of successful treatment with long-term follow-up. *Asian J Neurosurg.* 2017;12:746–50. [https://doi.org/10.4103/ajs.AJNS\\_231\\_16](https://doi.org/10.4103/ajs.AJNS_231_16).
54. Laviv Y, Jackson S, Rappaport ZH. Persistent communicating hydrocephalus in adult tuberous sclerosis patients: a possible therapeutic role for everolimus. *Acta Neurochir (Wien).* 2015;157:241–5. <https://doi.org/10.1007/s00701-014-2309-0>.

## Publisher's Note

Springer Nature remains neutral with regard to jurisdictional claims in published maps and institutional affiliations.

**Ready to submit your research? Choose BMC and benefit from:**

- fast, convenient online submission
- thorough peer review by experienced researchers in your field
- rapid publication on acceptance
- support for research data, including large and complex data types
- gold Open Access which fosters wider collaboration and increased citations
- maximum visibility for your research: over 100M website views per year

**At BMC, research is always in progress.**

Learn more [biomedcentral.com/submissions](https://biomedcentral.com/submissions)

