



# Stereotactic Radiosurgery Versus Observation for Treating Incidental Meningiomas: A Systematic Review and Meta-Analysis

Changfu ZHANG<sup>1,2</sup>, Hengzhu ZHANG<sup>1,2</sup>

<sup>1</sup>Dalian Medical University, College of the First Clinical Medicine, Department of Neurosurgery, Dalian, China

<sup>2</sup>Clinical Medical College of Yangzhou University, Department of Neurosurgery, Yangzhou, China

Corresponding author: Hengzhu ZHANG ✉ zhanghengzhu@sina.com

## ABSTRACT

**AIM:** To evaluate the clinical outcomes of incidental meningiomas (IM) treated with stereotactic radiosurgery (SRS) or observation.

**MATERIAL and METHODS:** The PubMed, Cochrane Library and MEDLINE (Ovid) databases were comprehensively searched for eligible studies about IM that were managed with serial imaging follow-up or SRS. We performed a systematic review and meta-analysis of the tumor progression rate between these two groups. The SRS-related morbidity was qualitatively analyzed. To predict potential tumor growth, the correlation between rapid tumor growth and the following factors, MRI T2 hyperintensity, initial tumor diameter and age were also analyzed by meta-analysis.

**RESULTS:** Sixteen studies were included. The SRS treatment group had significantly higher tumor control than the observation group in a mean follow-up of more than 3 years (pooled OR: 0.06, 95% CI: 0.01-0.20,  $p < 0.0001$ ; random effects model). Additionally, there was an acceptable level of SRS-associated morbidity. Tumor progression was positively associated with MRI T2 hyperintensity (pooled OR: 1.93, 95% CI: 1.30-2.87,  $p < 0.05$ , fixed effects model), initial large tumor diameter (pooled OR: 3.19, 95% CI: 0.94-5.44,  $p < 0.05$ , fixed effects model) and younger age to some extent (pooled OR: -3.80, 95% CI: -9.13-1.53,  $p > 0.05$ , random effects model). Absence of calcification was consistently shown to be a risk factor for progressive IM based on the existing literature.

**CONCLUSION:** SRS is a rational treatment for incidental meningioma in consideration of the higher tumor control rate and acceptable complications compared with treatment via observation. The integration of risk factors such as absence of calcification, MRI T2 hyperintensity and initial large tumor size may contribute to accurately predicting rapid tumor growth.

**KEYWORDS:** Incidental meningioma, Observation, Stereotactic Radiosurgery

**ABBREVIATIONS:** **IM:** Incidental meningioma, **SRS:** Stereotactic radiosurgery, **FU:** Follow-up, **MRI:** Magnetic resonance imaging, **SRT:** Stereotactic radiotherapy, **PFS:** Progression-free survival, **CI:** Confidence intervals, **OR:** Odds ratio, **GKRS:** Gamma Knife Radiosurgery, **WHO:** World Health Organization, **FSRT:** Fractionated stereotactic radiotherapy

## INTRODUCTION

Meningioma is one of the most common intracranial benign tumors, accounting for 13-26% of all primary intracranial tumors (4,25). These tumors are usually asymptomatic and smaller than 2 cm in diameter (29). Due to advances in neuroimaging technology and amplified use of brain imaging for minor head injuries and nonspecific

neurological symptoms, more incidental asymptomatic meningiomas have been detected (7,15,23,29,34,42). A recent investigation using magnetic resonance imaging (MRI) showed a frequency of meningioma of 2.5% as an incidental finding in a population-based neuroimaging study in middle-aged and older patients (5). The treatment of these incidental meningiomas (IMs) remains controversial (7,20,28,34,45). These management strategies consist of

observation, surgical resection, stereotactic radiosurgery (SRS) and fractionated stereotactic radiotherapy (FSRT). Due to the slow growth of most asymptomatic meningiomas, only a small proportion of these tumors tended to have volumetric increases or become symptomatic. The current opinion about IM is that serial imaging follow-up (FU) is advised, and further intervention (microsurgery or radiosurgery) is recommended until radiological progression or symptomatic progression. However, masses growing in meningiomas may lead to permanent neuropathies and complicate further intervention due to enlarged tumors and deteriorating conditions of patients with age (9,29). Additionally, recent studies have demonstrated that compared with the invasive procedure (surgical resection) or observation, primary SRS provides equivalent or even better tumor control and an acceptable rate of toxicities for patients with small- to medium-sized IM (10,14,20-22,25,40). In addition, faced with asymptomatic meningioma, we do not recommend surgery immediately in most cases (7,20,28,42), and these patients may prefer to choose the treatment of SRS or serial imaging FU (10,22). To illuminate whether SRS provided better clinical outcomes than observation, we performed a meta-analysis of the clinical outcomes of incidental imaging-diagnosed intracranial meningioma treated with SRS or observation.

The aim of this systematic review is to evaluate the clinical outcomes of incidental imaging-diagnosed intracranial meningioma treated with SRS or observation.

## ■ MATERIAL and METHODS

### Eligibility Criteria

#### *Type of Studies and Patients*

We included experimental and observational studies, such as case series, retrospective and prospective analyses, that were published in English and were focused on adult patients with incidental radiological diagnoses of intracranial meningioma. Studies of neurofibromatosis type II-associated and radiation-induced meningiomas were excluded. Moreover, studies including patients who underwent any therapy for their tumor prior to the beginning of SRS or observation were excluded. Additionally, studies enrolling a fewer than five patients for each arm (SRS or observation) were excluded.

#### *Interventions*

SRS was considered the primary treatment for IM. On the other hand, observation considered the control treatment.

#### *Outcome Measures*

The outcomes were tumor progression rate, defined as the proportion of patients with an increase in tumor diameter or volume at fixed time points, and progression-free survival (PFS) rate, defined as the rate of freedom from progression or death at fixed time points. Studies were considered eligible if the tumor progression rate was assessed with a minimum FU of 3 years. Tumor control was defined as the rate of patients with stable meningioma during FU imaging.

### Search Strategy

The PubMed, Cochrane Library and MEDLINE (Ovid) databases were searched for abstracts and keywords of relevant studies published in English until 26 March 2020. These key words consisted of “meningioma,” “observation,” “natural history,” “untreated,” “incidental,” “radiation therapy,” and “radiosurgery”. The included studies were selected after a two-step process. In the first step, two reviewers independently checked the titles, abstracts and key words of the identified papers. In the second step, two other independent reviewers evaluated the full texts of the included studies by matching all of the inclusion criteria.

### Date Extraction

Two independent investigators extracted all relevant information on study design (prospective, retrospective, single or multicenter and FU duration), patients (age, sex and number of enrolled and analyzed patients), incidental imaging-diagnosed meningioma characteristics (initial volume and/or diameter at diagnosis, T2 hyperintensity, calcification) and results (tumor progression and PFS rate). Volumetric measurements were converted to diametric measurements using the formula: Volume = (0.72 × maximum diameter)<sup>3</sup> (29). Disagreements about any data extraction between the two investigators were resolved by consulting a third reviewer.

### Statistical Methods

Review Manager v. 5.2 was applied for data analysis. Studies for quantitative analysis were evaluated using the NIH Quality Assessment Tool for Observational Cohort and Cross-Sectional Studies. Comparisons of binary and continuous variables were performed with the pooled estimates of ORs and mean difference, respectively, as well as the 95% CIs. A *p* value <0.05 was considered statistically significant. Between-study heterogeneity was evaluated using the *I*<sup>2</sup> statistic. If *I*<sup>2</sup>>50%, it indicated statistically significant heterogeneity. If heterogeneity was significant, the random effects model was adopted; otherwise, the fixed effects model was used. Sensitivity analysis was performed to evaluate the stability of the pooled estimates by excluding specific studies.

## ■ RESULTS

### Literature Research and Study Characteristics

Initially, 1185 records were retrieved from the three databases; 21 duplicates were removed, leaving 1164 articles to review. After screening the titles and abstracts, 38 articles were potentially eligible. Then, after the full texts were reviewed, 7 articles were excluded, including 5 due to the full text being unavailable and 2 for not being published in English. Moreover, 15 articles were removed because the outcome measures of IM were not included in these studies. Finally, 16 articles were included in the final analysis, including 4 for quantitative analysis (20,21,35,41) and 12 for narrative analysis (2,14-16,19,28,34,38-40,45,46). Table I shows the details of the included studies. In addition, the detailed search processes are listed in Figure 1.

Table 1: Baseline Characteristics of Included Studies

Study	Year	Country	No of patients (RS/Ob)	Mean age, year (RS/Ob)	Mean FU, mo (RS/Ob)	Definition of TP	Progression free survival
Park et al. *, (35)	2006	South Korea	21 (12/9)	44/64	52/63	NS	NS
Jo et al. *, (20)	2011	South Korea	146 (69/77)	54.9/63.1	63.0/59.7	25% or more increase in TV	RS/Ob(4years):100%/77.2%; RS/Ob(5years):100%/61.8%
Seifert*, (41)	2010	Germany	53 (29/24)	NS	range: 4-242	NS	NS
Kim et al. *, (21)	2018	South Korea	354(153/201)	56.6/58.3	46/47	30% or more increase in TV	Radiological PFS: RS/Ob(3years):94.4%/60.2%; RS/Ob(5years):94.4%/38.5%; RS/Ob(10years):88.5%/7.9%.
Study	Year	Country	No of patients (RS or Ob)	Mean age, year (RS or Ob)	Mean FU, mo (RS or Ob)	Definition of TP	Tumor control
Salvetti et al. #, (40)	2013	USA	RS only: 21	NS	NS	15% or more increase in TV	Acturial TC: 100%, 95% and 95% at 2, 5, 10 years
Gupta et al. #, (14)	2019	USA	RS only: 71	NS	NS	20% or more increase in TV	Radiological TC:98.6% and 95.4% at 5,10 years
Hashiba* et al., (15)	2009	Japan	Ob only:70	61.6	39.3	15% or more increase in TV	TC: 26 patients (37%)
Behbahani et al. #, (2)	2019	Norway	Ob only:64	64	60	15% or more increase in TV	TC: 16 patients (25%)
Jadid et al. #, (19)	2015	Sweden	Ob only:65	68	74	2mm increase of any Dia	TC: 39 patients (64.6%)
Romani et al. #, (38)	2018	UK	Ob only:136	65	43	3 mm increase of the maximum Dia	TC: 86 patients (63%)
Oya et al. #, (34)	2011	USA	Ob only:244	60.5	45.6	2 mm increase of the maximum Dia	TC: 153 tumors (153/273=56%)
Herscovici et al. #, (16)	2004	Israel	Ob only:43	65	67	2mm progression of tumor Dia	TC: 27 patients (63%)
Rubin et al. #, (39)	2011	Israel	Ob only: 56	64	65	NS	TC: 35 patients (62.5%)
Yano and Kuratsu #, (45)	2006	Japan	Ob only:67	64.4	91.2	NS	TC: 42patients (62.7%)
Nakamura et al. #, (28)	2003	Germany	Ob only:41	60.9	43	1 cu cm annual increase in TV	TC: 27 patients (66%)
Yoneoka et al. #, (46)	2000	Japan	Ob only: 37	56.8	45.6	1 cu cm annual increase in TV	TC: 28 patients (75.6%)

“#” means included for quantitative study, “\*” means included for narrative study, **No**: Number, **Dia**: Diameter, **FU**: Follow-up, **RS**: Radiosurgery, **Ob**: Observation, **Mo**: Months, **TP**: Tumor progression, **TV**: Tumor volume, **TC**: Tumor control, **NS**: Not specified.

**Meta-Analysis Results of IM Treated with SRS or Observation**

Figure 2 shows the forest plots for SRS versus observation, and the outcome measure was the tumor progression rate. It demonstrated that incidental imaging-diagnosed intracranial meningiomas treated with SRS had significantly higher tumor control than observations within FU of more than 3 years (pooled OR: 0.06, 95% CI: 0.01-0.20,  $p < 0.0001$ ; random effects model). Moreover, the difference in PFS between gamma knife radiosurgery (GKRS) and observation was statistically significant at 5 or 10 years ( $p < 0.001$ ), and patients treated with SRS had a higher PFS rate (20,21). Additionally,

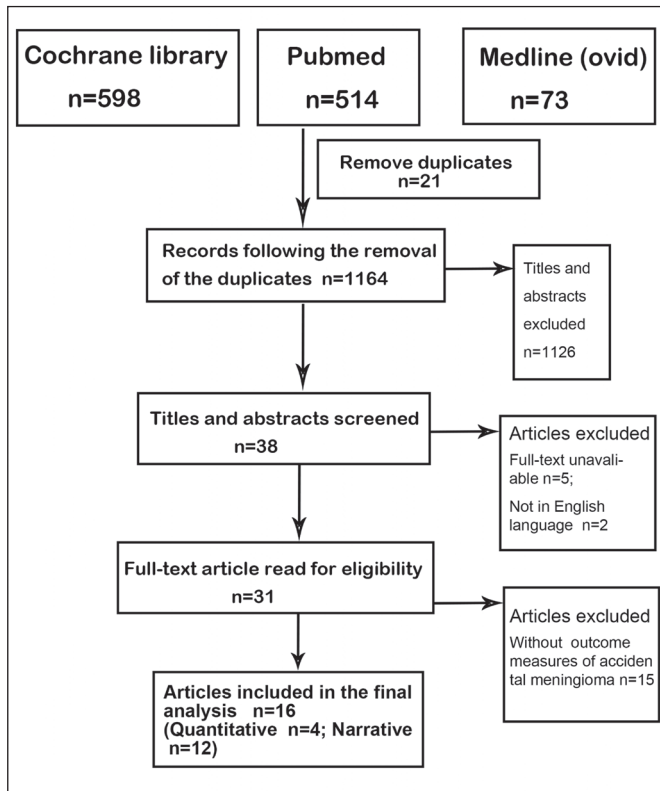


Figure 1: Flowchart for selection of included studies.

according to previous single-arm studies on IMs treated with GKRS (14,40), tumor control was more than 95% at 5 or 10 years. In addition, other IMs managed with serial imaging FU had a tumor control of approximately 56.5%, which was obtained from the mean values of diameter (16,19,34,38), volume (2,15), growth rate (28,46) and other unspecific (39,45) criterion-based tumor progression.

**Acceptable SRS-Related Morbidity in IM**

The risk of SRS-related complications is an important issue drawing much attention (12-14,20,21,25). The complication rates for IM treated with SRS ranged from 8.3% to 39.1%. Flickinger et al. demonstrated that the actuarial rate of developing any postradiosurgical injury reaction was 8.8% at 5 and 10 years within 219 imaging-diagnosed intracranial meningiomas (13). A nearly identical post-SRS complication rate, 8.3%, was shown in the study of Dibiase, and 10 patients developed new neurological deficits among 121 intracranial meningiomas with serial MRI analysis (12).

Recent studies have revealed that the adverse events post-SRS are transient in most cases (14,20,21). Twenty-six of 195 (13.3%) asymptomatic meningiomas had GKRS-related adverse events during a median FU period of 53 months. Twenty-five of them were transient and did not have permanent disability after treatment with steroids. However, one patient had a serious adverse event, namely, severe brain edema requiring surgical treatment (21). Gupta et al. found that 21 of 117 patients (18%) experienced post-GKRS new deficits. Eight of these patients recovered, and the other patients showed no improvement (14). In contrast to the lower SRS-related morbidity of the above studies, 27 of 69 (39.1%) asymptomatic meningiomas had transient complications after GKRS treatment in the study of Jo et al. (20). These complications consisted of headache, scalp paresthesia, alopecia, ocular pain, tinnitus, dizziness, cognitive dysfunction and focal neurological deficit related to brain edema. However, all 27 patients' symptoms were alleviated after treatment with corticosteroids or analgesics, and permanent neurological deficit events did not occur. Table II shows the details of the above studies about SRS-associated complications.

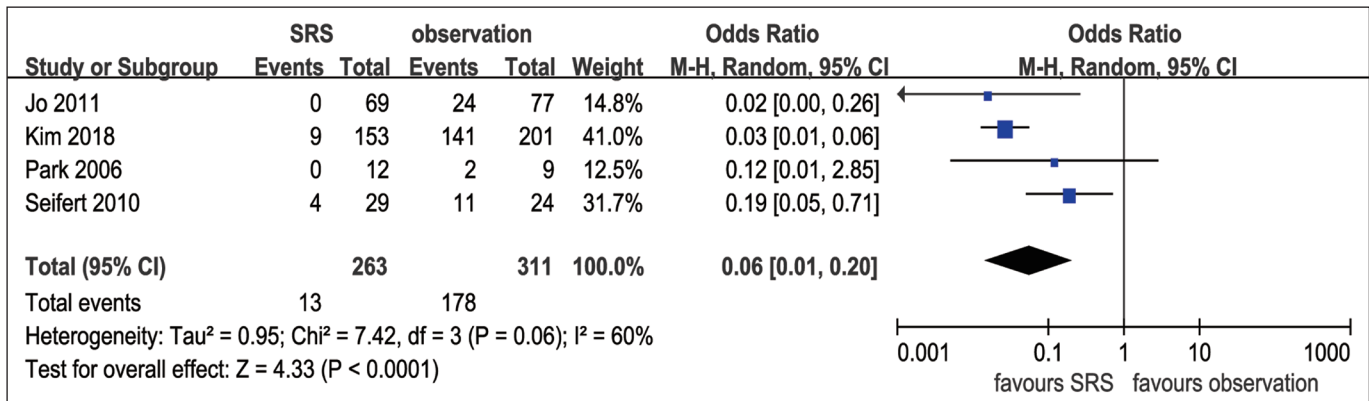


Figure 2: The forest plot for SRS versus observation.

**Table II:** Several Studies About SRS Associated Complications in Imaging Diagnosed Meningioma

Study	Country	No of patients with SRS	No of patients with complications (%)	Specific details of complications	Outcome of complications	Factors related to complications
Flickinger et al. (13), 2003	USA	IDM: 219	12 (8.8%)	headache:4, worsening hemiparesis: 2, mental status changes:2, trigeminal nerve problems: 3, temporary visual field deficit:1	mental status changes: 1 needing steroids, 1 needing VP shunt	treatment volume (p=0.05)
DiBiase et al. (12), 2004	USA	IDM : 85; residual tumor with prior resection: 52	10 (8.3%)	edema with headaches:9, positional vertigo:1	headaches:2 developed seizures, 1 required VP, 1 required ST; positional vertigo: recovered	NA
Jo et al. (20), 2011	South Korea	asymptomatic meningioma: 69	27 (39.1%)	headache:11, scalp paresthesia:6, dizziness:5, focal alopecia:5, tinnitus:4, ocular pain:4, right side weakness:1	all complications abated after treatment with corticosteroids or analgesics	NA
Kim et al. (21), 2018	South Korea	asymptomatic meningioma: 195	26 (13.3%)	headache and/or dizziness:18, transient neurological deficits:6, short-term alopecia: 2	25 were transient after treatment with steroids, 1 required ST due to severe brain edema	Peritumoral edema (p=0.004), tumor located in convexity, falx, and parasagittal area (p=0.398)
Gupta et al. (14), 2019	USA	asymptomatic meningioma: 117	21 (18%)	Cranial nerve deficits 8, memory loss 7, gait ataxia 3, seizures 2, and UE numbness 1	8 of them recovered, the remainder showed no improvement	Tumor located in petroclival, CPA and JF area (p=0.3)

**UE:** Upper extremity, **No:** Number, **VP:** Ventriculoperitoneal, **CPA:** Cerebellopontine angle, **JF:** Jugular foramen, **ST:** Surgical treatment, **IDM:** imaging diagnosed meningioma, **NA:** Not available.

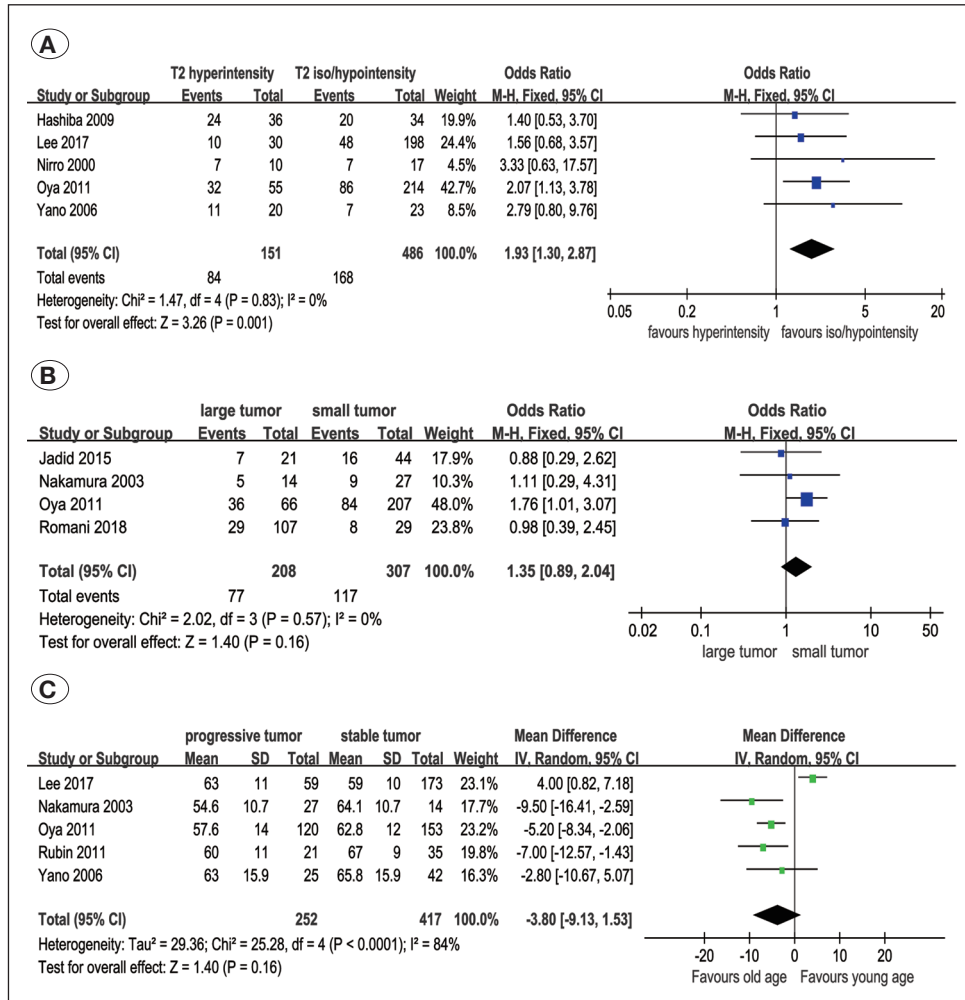
### Important Factors to Predict the Rapid Growth of IM

Faced with IM, it is very important to identify the independent risk factors for rapid growth; identifying these risk factors can contribute to making wise and reasonable treatment decisions in the early stage of IM rather than waiting until radiological or clinical progression (17,18,24,29,31,34,39,42). According to previous studies, the following factors may contribute to radiological progression of IM: absence of calcification (15,21,28,31,34,38,39,45), MRI T2-hyperintensity (21,28,34,38,45), younger age (16,21,28,30,39), initial large tumor diameter or volume (2,33,34) and peritumoral edema (34, 38). A prospective study demonstrated that the growth rate of IM was higher in older patients than in younger patients (2). However, the presence of calcification was the most consistent factor predicting stable meningioma. Therefore, we conducted a meta-analysis of MRI T2 hyperintensity (as shown in Figure 3A) (15,24,33,34,45), age (as shown in Figure 3B) (24,28,34,39,45), and initial tumor size (as shown in Figure 3C) (19,28,34,38) to further illuminate whether these factors could promote rapid growth of IM. According to Figure 3,

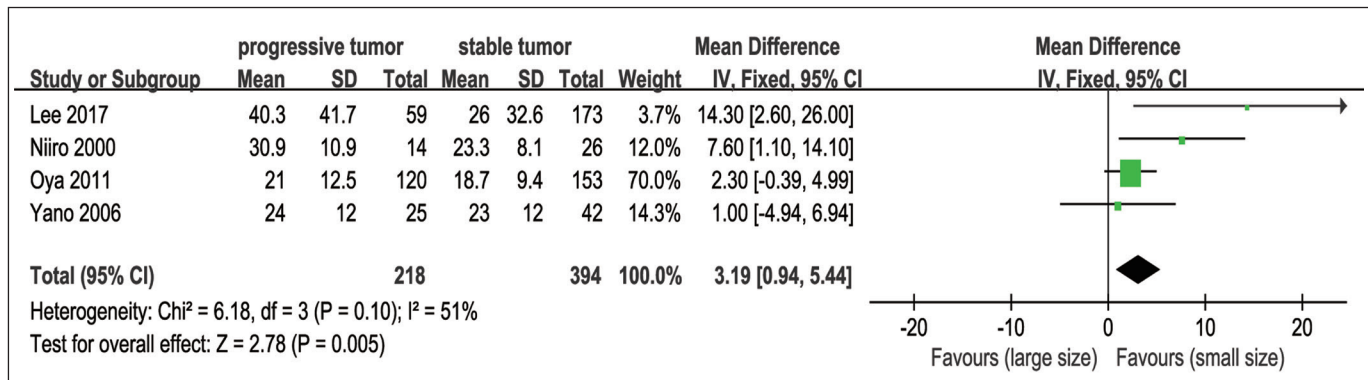
MRI T2-hyperintensity was significantly correlated with rapid growth of IM compared with T2-iso/hypointensity (pooled OR: 1.93, 95% CI: 1.30-2.87, P=0.001, fixed effects model, Figure 3A). In addition, younger age and initial large tumor size may be related to the progression of IM, but the overall effect was not significant (pooled OR: 1.35, 95% CI: 0.89-2.04, P=0.16, fixed effects model, Figure 3B; pooled OR: -3.80, 95% CI: -9.13-1.53, P=0.16, random effects model, Figure 3C). To further study the relationship between IM progression and initial tumor size, we performed another meta-analysis based on the mean  $\pm$  SD of tumor diameter (24,33,34,45), which was different from the analysis based on OR in Figure 3B. This meta-analysis showed that a large IM had a greater chance of progression (pooled OR: 3.19, 95% CI: 0.94-5.44, P=0.005, fixed effects model, Figure 4).

### Subgroup and Sensitivity Analysis

To determine whether the pooled data of the tumor progression of IM treated with SRS or observation were influenced by different definitions of tumor growth, the subgroups of specific (20,21) and unspecific (35,41) tumor progression definitions



**Figure 3:** Forest plots for the correlation between tumor progression and the following risk factors, MRI T2 hyperintensity (A), initial tumor diameter (B) and age (C).



**Figure 4:** Forest plot for the association between tumor progression and initial tumor diameter(Mean difference).

were further classified, and the pooled OR of the two subgroups was 0.02 (95% CI: 0.01-0.05,  $P < 0.0001$ ;  $I^2 = 0\%$ , fixed effects model) and 0.17 (95% CI: 0.05-0.59,  $p < 0.01$ ;  $I^2 = 0\%$ , fixed effects model), respectively. The overall effect was also statistically significant, and the  $I^2$  value decreased from 60% to 0%. On the other hand, the studies of Park et al. and Seifert et al. focused on asymptomatic petroclival

meningioma, which may be a potential source of heterogeneity ( $I^2 = 60\%$ , Figure 2). Quality assessment results for quantitative analysis are summarized in Table III. Two studies were rated “good”, and two were rated “fair”. To examine the consistency of the results of the meta-analysis, sensitivity analysis was conducted by excluding one study at a time, and we found that the overall effects shown in Figure 2, Figure 3A and Figure

**Table III:** Results of the Quality Assessment Performed for Studies for Quantitative Analysis

Authors	Year	Q1	Q2	Q3	Q4	Q5	Q6	Q7	Q8	Q9	Q10	Q11	Q12	Q13	Q14	Overall score
Park et al., (35)	2006	+	-	NA	NR	NA	+	+	+	+	NR	-	NR	+	-	Fair
Jo et al., (20)	2011	+	+	NA	+	NA	+	-	+	+	NR	+	NR	+	-	Good
Seifert (41)	2010	+	+	NA	-	NA	+	+	+	+	NR	-	NR	+	-	Fair
Kim et al., (21)	2018	+	+	NA	+	NA	+	+	+	+	NR	+	NR	+	+	Good

(+) *sign*: Yes, (-) *sign*: No, *NA*: Not applicable, *NR*: Not reported.

4 were not affected by excluding any study. Regarding the predictive factor of age (Figure 3B), after exclusion of the study of Lee et al., the overall effect became significant ( $p < 0.0001$ ), and  $I^2$  decreased from 84% to 0%.

## DISCUSSION

The systematic review mainly aimed to evaluate the tumor control of IM treated with SRS or serial imaging FU. Compared with observation, SRS provided a higher tumor control rate ( $p < 0.0001$ ) and acceptable radiosurgery-related complications, the majority of which could abate with or without steroid treatment. Additionally, in the absence of calcification, MRI T2 hyperintensity significantly predicted the rapid growth of IM. Younger age and initial large tumor size were also associated with the progression of IM to some extent.

It was reported that the incidence of asymptomatic IM was approximately 2% to 3% (43). Due to the rapid development of imaging technology and more neurological check-ups for minor head injuries and nonspecific neurological symptoms, an increasing number of IMs have been detected. The current treatment of IM is still controversial (2,14,20,34,40). Serial imaging FU may be the first choice for some cases of IM at diagnosis. Further treatment, such as SRS or microsurgery, should be considered if IM shows documented tumor growth or symptomatic progression. However, there were some patients with low compliance or who were lost to FU at a fixed time in clinical practice (2,14). IM could not draw the patients' attention until tumor progression. At that time, permanent neuropathies could occur, and further intervention would become complicated due to enlarged tumors and deteriorating conditions of patients with age. Additionally, compared with invasive procedure-microsurgery, SRS can be recommended as the primary treatment for IM with minimal invasiveness and lower morbidity (36,37). The efficacy of SRS treatment on IM has been well established in recent years (14,20,21,40), and this meta-analysis confirmed the high tumor control of SRS. Additionally, according to a previous single-arm study about IM treated with observation or SRS (shown in Table I), the average tumor control of IM with serial imaging FU was 56.5%, which was lower than that of IM treated with SRS (more than 95%) from the study of Salvetti et al. and Gupta et al.

Obviously, there were some complications related to radiosurgery treatment, such as headache, alopecia, tinnitus, dizziness, scalp paresthesia, ocular pain, cognitive dysfunction

and focal neurological deficit related to brain edema. These adverse events were more likely to occur in IM with a large size or close location to important organs (25). Additionally, the rate of SRS-associated complications was lower in previous studies (3,12-14,21,25) compared with microsurgery-related adverse events (37). Notably, Jo et al. revealed that GKRS-related complications occurred in 39.1% of patients, but there were no permanent deficits, and only 3 patients (4.8%) required treatment with steroids for more than 2 weeks. According to a study by Kim et al., 13.3% of IM patients had GKRS-related adverse events. Only one patient had severe brain edema requiring surgical treatment. Therefore, the majority of SRS-related complications could abate with or without steroid treatment, and their morbidity was acceptable. Additionally, Chang et al. found that radiological adverse events occurred in 25% of GKRS-treated benign meningiomas, which were more likely to be located in the convexity, parasagittal region and falx cerebri rather than the skull base (8). In contrast, Kim et al. reported that the occurrence of adverse events was significantly related to the presence of peritumoral edema prior to GKRS ( $p = 0.004$ ) and not associated with tumor location in convexity, parasagittal and falx areas (21). Moreover, Gupta et al. demonstrated that new neurological deficits may be more likely to occur in the petroclival, cerebellopontine angle and jugular foramen area than in the convexity, parasagittal and falx areas, although the differences are not significant (14). The difference between the above three findings may be due to the smaller initial tumor size in the study of Gupta and Kim because there was a significant correlation between increasing tumor size and SRS-related toxicity according to the study of Bloch et al. (3). Recently, FSRT has been proven to be an effective treatment for intracranial meningioma with a large diameter or close distance to the critical structure (11,25-27,32). Compared with conventional radiotherapy, FSRT delivered more localized irradiation with a steeper dose gradient between the tumor and adjacent normal tissue, reducing the risk of radiation-induced complications. Fractionated techniques took additional advantage of the biological benefit of fractionation with regard to tumor control and toxicity (32). In summary, FSRT combined precision with the radiobiological advantages of fractionation with a dose per fraction below radiation tolerance levels of normal brain structures and critical organs (11). Manabe et al. recommended that SRS might be indicated for small tumors that are less than 11 ml (2.56 cm in diameter) and not close to critical organs (optic nerve, chiasma or brain stem). For large tumors (>13.5 ml, 3.0 cm in diameter) or small tumors close to vital organs, normof-

racted stereotactic radiotherapy (1.8-2 Gy per fraction) might be considered (25). Therefore, if IM patients are able to tolerate minor radiosurgery-associated complications, SRS can be considered the primary treatment. Last but not least, we clinicians should evaluate the probability of adverse events and take the following factors, tumor location, the distance to critical structure, initial tumor size and peritumoral edema, into consideration before SRS treatment (Table II).

In a valuable review study, Sughrue et al. demonstrated that 51% of untreated meningiomas  $\leq 2.5$  cm showed no growth over a median FU of 4.6 years (42). However, not all radiologically diagnosed IMs were histologically proven to be benign meningiomas. Five percent of the imaging-diagnosed IM turned out to be anaplastic (WHO grade 2) or malignant (WHO grade 3) in the study of Wiemels et al. (44). A prospective study of Behbahani revealed that 3% of IMs were histologically diagnosed as atypical (2). Moreover, Flickinger et al. reported that the actuarial rate of a diagnosis other than meningioma was 2.3% in cases of imaging-diagnosed intracranial meningioma (13). Additionally, several studies revealed that nearly 20%-25% of IM showed exponential growth (2,24,31). Therefore, accurately predicting the growth potential of IM is paramount for timely intervention and reasonable management. Several clinicoradiological parameters have been suggested as risk factors for tumor growth, including the absence of calcification (15,21,28,31,34,38,39,45), MRI T2 hyperintensity (21,28,34,38,45), initial large tumor size (2,33,34) and peritumoral edema (34,38). The presence of calcification was the most consistent factor predicting no growth of IM. In addition, our study confirmed that MRI T2 hyperintensity and initial large tumor diameter (mean  $\pm$  SD) were also significantly associated with the progression of IM ( $p < 0.05$ ). Nevertheless, it is unclear whether younger age (16,21,28,30,39) or older age (2,24) contributes to tumor growth. The present study showed that younger age was more likely to promote the rapid growth of IM ( $p = 0.16$ , Figure 3B), although the difference was not significant. Recently, to quantify the risk of rapid tumor growth, Lee et al. developed a weighted scoring system based on clinicoradiological factors (initial tumor diameter, calcification, peritumoral edema and signal on T2-weighted MRI) to estimate the probability of tumor progression (24). Tumor size was divided into 3 groups of  $< 2.5$  cm,  $\geq 2.5$  to  $< 4.0$  cm, and  $\geq 4.0$  cm in diameter and awarded a score of 0, 3, and 6, respectively. The presence or absence of calcification and peritumoral edema were given a score of 0 or 2 and 1 or 0, respectively. Hypointensity and hyperintensity/isointensity on T2-weighted MRI were given a score of 0 or 2, respectively. This scoring system integrated the relative weights of these risk factors and contributed to accurately predicting the overall risk of rapid tumor growth. Moreover, two studies have recently validated the good predictive value of this scoring system for the rapid growth of IM (1,6).

#### Limitations of Study

Although this study has demonstrated the more favorable results of SRS treatment on IM patients compared with observation, some limitations should be noted. First, four of

the included studies selected for quantitative analysis, as shown in Figure 2, were retrospective studies. The results of these studies were subject to the selection bias of clinicians to some extent. The mean FU period was not mentioned in the study of Seifert (41), despite the range of FU being 4-242 months. Second, the definition of rapid tumor growth was not unified. Kim et al. and Jo et al. defined tumor progression by more than 30% or exceeding a 25% increase in tumor volume, respectively. Moreover, the studies of Seifert and Park et al. did not mention the criterion. Last but not least, there were only four studies consisting of SRS and observation treatment simultaneously, and the other 12 were single-arm studies. Despite the limitations of the present study, the findings indicate that SRS changes the natural course and lowers the risk of IM progression. There is an urgent need for more prospective random controlled trials for IM treated with SRS or observation.

#### CONCLUSION

SRS is a reasonable treatment strategy for IM in terms of higher tumor control and PFS rate compared with treatment with serial imaging FU. Some IM patients with potential rapid tumor growth benefit from early intervention with SRS. In addition, the morbidity of minimally invasive SRS is acceptable or even lower than that of observation or microsurgery. The absence of calcification, MRI T2 hyperintensity and initial large tumor diameter significantly contribute to the rapid growth of IM. Younger age is associated with the progression of IM, although the overall effect is not significant. Finally, by integrating the risk factors, proactive SRS may be a rational treatment for IM patients, especially for those with rapid growth.

#### ACKNOWLEDGMENTS

This work was supported by the second level of "333 Project" of Jiangsu Province (BRA2019026); Scientific Research Project of Health Committee of Jiangsu Province (H2018064); and Talent of Class A of Subei People's Hospital of Jiangsu Province (DTRA201802).

#### REFERENCES

1. Abi Jaoude S, Peyre M, Degos V, Goutagny S, Parfait B, Kalamirides M: Validation of a scoring system to evaluate the risk of rapid growth of intracranial meningiomas in neurofibromatosis type 2 patients. *J Neurosurg*, 2020 (Online ahead of print)
2. Behbahani M, Skeie GO, Eide GE, Hausken A, Lund-Johansen M, Skeie BS: A prospective study of the natural history of incidental meningioma-Hold your horses! *Neurooncol Pract* 6:438-50, 2019
3. Bloch O, Kaur G, Jian BJ, Parsa AT, Barani IJ: Stereotactic radiosurgery for benign meningiomas. *J Neurooncol* 107:13-20, 2012
4. Bondy M, Ligon BL: Epidemiology and etiology of intracranial meningiomas: a review. *J Neurooncol* 29:197-205, 1996



5. Bos D, Poels MM, Adams HH, Akoudad S, Creemers LG, Zonneveld HI, Hoogendam YY, Verhaaren BF, Verlinden VJ, Verbruggen JG, Peymani A, Hofman A, Krestin GP, Vincent AJ, Feelders RA, Koudstaal PJ, van der Lugt A, Ikram MA, Vernooij MW: Prevalence, clinical management, and natural course of incidental findings on brain MR images: The population-based rotterdam scan study. *Radiology* 281:507-515, 2016
6. Brugada-Bellsolà F, Teixidor Rodríguez P, Rodríguez-Hernández A, Garcia-Armengol R, Tardáguila M, González-Crespo A, Domínguez CJ, Rimbau JM: Growth prediction in asymptomatic meningiomas: The utility of the AIMSS score. *Acta Neurochir (Wien)* 161:2233-2240, 2019
7. Chamoun R, Krisht KM, Couldwell WT: Incidental meningiomas. *Neurosurg Focus* 31:E19, 2011
8. Chang JH, Chang JW, Choi JY, Park YG, Chung SS: Complications after gamma knife radiosurgery for benign meningiomas. *J Neurol Neurosurg Psychiatry* 74:226-230, 2003
9. Chuang CC, Chang CN, Tsang NM, Wei KC, Tseng CK, Chang JTC, Pai PC: Linear accelerator-based radiosurgery in the management of skull base meningiomas. *Journal of Neuro-Oncology* 66:241-249, 2004
10. Cohen-Inbar O, Tata A, Moosa S, Lee CC, Sheehan JP: Stereotactic radiosurgery in the treatment of parasellar meningiomas: Long-term volumetric evaluation. *J Neurosurg* 128:362-372, 2018
11. Compter I, Zaugg K, Houben RM, Dings JT, Bosmans G, Buescher C, Anten MM, Baumert BG: High symptom improvement and local tumor control using stereotactic radiotherapy when given early after diagnosis of meningioma. A multicentre study. *Strahlenther Onkol* 188:887-893, 2012
12. DiBiase SJ, Kwok Y, Yovino S, Arena C, Naqvi S, Temple R, Regine WF, Amin P, Guo C, Chin LS: Factors predicting local tumor control after gamma knife stereotactic radiosurgery for benign intracranial meningiomas. *Int J Radiat Oncol Biol Phys* 60:1515-1519, 2004
13. Flickinger JC, Kondziolka D, Maitz AH, Lunsford LD: Gamma knife radiosurgery of imaging-diagnosed intracranial meningioma. *Int J Radiat Oncol Biol Phys* 56:801-806, 2003
14. Gupta A, Xu Z, Cohen-Inbar O, Snyder MH, Hobbs LK, Li C, Nguyen QT, Sheehan JP: Treatment of asymptomatic meningioma with gamma knife radiosurgery: Long-term follow-up with volumetric assessment and clinical outcome. *Neurosurgery* 85:e889-e899, 2019
15. Hashiba T, Hashimoto N, Izumoto S, Suzuki T, Kagawa N, Maruno M, Kato A, Yoshimine T: Serial volumetric assessment of the natural history and growth pattern of incidentally discovered meningiomas. *J Neurosurg* 110:675-684, 2009
16. Herscovici Z, Rappaport Z, Sulkes J, Danaila L, Rubin G: Natural history of conservatively treated meningiomas. *Neurology* 63:1133-1134, 2004
17. Islim AI, Kolamunnage-Dona R, Mohan M, Moon RDC, Crofton A, Haylock BJ, Rathi N, Brodbelt AR, Mills SJ, Jenkinson MD: A prognostic model to personalize monitoring regimes for patients with incidental asymptomatic meningiomas. *Neuro Oncol* 22:278-289, 2020
18. Islim AI, Mohan M, Moon RDC, Srikandarajah N, Mills SJ, Brodbelt AR, Jenkinson MD: Incidental intracranial meningiomas: A systematic review and meta-analysis of prognostic factors and outcomes. *J Neurooncol* 142:211-221, 2019
19. Jadid KD, Feychting M, Höjjer J, Hylin S, Kihlström L, Mathiesen T: Long-term follow-up of incidentally discovered meningiomas. *Acta Neurochir (Wien)* 157:225-230; discussion 230, 2015
20. Jo KW, Kim CH, Kong DS, Seol HJ, Nam DH, Park K, Kim JH, Lee JI: Treatment modalities and outcomes for asymptomatic meningiomas. *Acta Neurochir (Wien)* 153:62-67; discussion 67, 2011
21. Kim KH, Kang SJ, Choi JW, Kong DS, Seol HJ, Nam DH, Lee JI: Clinical and radiological outcomes of proactive Gamma Knife surgery for asymptomatic meningiomas compared with the natural course without intervention. *J Neurosurg*:1-10, 2018
22. Kolakshyapati M, Ikawa F, Abiko M, Mitsuahara T, Kinoshita Y, Takeda M, Kurisu K: Multivariate risk factor analysis and literature review of postoperative deterioration in Karnofsky Performance Scale score in elderly patients with skull base meningioma. *Neurosurg Focus* 44:E14, 2018
23. Kuratsu J, Kochi M, Ushio Y: Incidence and clinical features of asymptomatic meningiomas. *J Neurosurg* 92:766-770, 2000
24. Lee EJ, Kim JH, Park ES, Kim YH, Lee JK, Hong SH, Cho YH, Kim CJ: A novel weighted scoring system for estimating the risk of rapid growth in untreated intracranial meningiomas. *J Neurosurg* 127:971-980, 2017
25. Manabe Y, Murai T, Ogino H, Tamura T, Iwabuchi M, Mori Y, Iwata H, Suzuki H, Shibamoto Y: Cyber knife stereotactic radiosurgery and hypofractionated stereotactic radiotherapy as first-line treatments for imaging-diagnosed intracranial meningiomas. *Neurologia Medico-Chirurgica* 57:627-633, 2017
26. Milker-Zabel S, Zabel A, Schulz-Ertner D, Schlegel W, Wannemacher M, Debus J: Fractionated stereotactic radiotherapy in patients with benign or atypical intracranial meningioma: Long-term experience and prognostic factors. *Int J Radiat Oncol Biol Phys* 61:809-816, 2005
27. Minniti G, Clarke E, Cavallo L, Osti MF, Esposito V, Cantore G, Cappabianca P, Enrici RM: Fractionated stereotactic conformal radiotherapy for large benign skull base meningiomas. *Radiat Oncol* 6:36, 2011
28. Nakamura M, Roser F, Michel J, Jacobs C, Samii M: The natural history of incidental meningiomas. *Neurosurgery* 53:62-70, 2003
29. Nakasu S, Nakasu Y: Natural history of meningiomas: Review with meta-analyses. *Neurol Med Chir (Tokyo)* 60:109-120, 2020
30. Nakasu S, Nakasu Y, Fukami T, Jito J, Nozaki K: Growth curve analysis of asymptomatic and symptomatic meningiomas. *J Neurooncol* 102:303-310, 2011
31. Nakasu S, Onishi T, Kitahara S, Oowaki H, Matsumura KI: CT Hounsfield unit is a good predictor of growth in meningiomas. *Neurol Med Chir (Tokyo)* 59:54-62, 2019

32. Navarria P, Pessina F, Cozzi L, Clerici E, Villa E, Ascolese AM, De Rose F, Comito T, Franzese C, D'Agostino G, Lobefalo F, Fogliata A, Reggiori G, Fornari M, Tomatis S, Bello L, Scorsetti M: Hypofractionated stereotactic radiation therapy in skull base meningiomas. *Journal of Neuro-Oncology* 124:283-289, 2015
33. Niiro M, Yatsushiro K, Nakamura K, Kawahara Y, Kuratsu J: Natural history of elderly patients with asymptomatic meningiomas. *J Neurol Neurosurg Psychiatry* 68:25-28, 2000
34. Oya S, Kim SH, Sade B, Lee JH: The natural history of intracranial meningiomas. *J Neurosurg* 114:1250-1256, 2011
35. Park CK, Jung HW, Kim JE, Paek SH, Kim DG: The selection of the optimal therapeutic strategy for petroclival meningiomas. *Surg Neurol* 66:160-165, 2006
36. Pollock BE, Stafford SL, Utter A, Giannini C, Schreiner SA: Stereotactic radiosurgery provides equivalent tumor control to Simpson Grade 1 resection for patients with small- to medium-size meningiomas. *Int J Radiat Oncol Biol Phys* 55:1000-1005, 2003
37. Reinert M, Babey M, Curschmann J, Vajtai I, Seiler RW, Mariani L: Morbidity in 201 patients with small sized meningioma treated by microsurgery. *Acta Neurochir (Wien)* 148:1257-1265; discussion 1266, 2006
38. Romani R, Ryan G, Benner C, Pollock J: Non-operative meningiomas: long-term follow-up of 136 patients. *Acta Neurochir (Wien)* 160:1547-1553, 2018
39. Rubin G, Herscovici Z, Laviv Y, Jackson S, Rappaport ZH: Outcome of untreated meningiomas. *Isr Med Assoc J* 13:157-160, 2011
40. Salvetti DJ, Nagaraja TG, Levy C, Xu Z, Sheehan J: Gamma Knife surgery for the treatment of patients with asymptomatic meningiomas. *J Neurosurg* 119:487-493, 2013
41. Seifert V: Clinical management of petroclival meningiomas and the eternal quest for preservation of quality of life: Personal experiences over a period of 20 years. *Acta Neurochir (Wien)* 152:1099-1116, 2010
42. Sughrue ME, Rutkowski MJ, Aranda D, Barani IJ, McDermott MW, Parsa AT: Treatment decision making based on the published natural history and growth rate of small meningiomas. *J Neurosurg* 113:1036-1042, 2010
43. Whittle IR, Smith C, Navoo P, Collie D: Meningiomas. *Lancet* 363:1535-1543, 2004
44. Wiemels J, Wrensch M, Claus EB: Epidemiology and etiology of meningioma. *J Neurooncol* 99:307-314, 2010
45. Yano S, Kuratsu J: Indications for surgery in patients with asymptomatic meningiomas based on an extensive experience. *J Neurosurg* 105:538-543, 2006
46. Yoneoka Y, Fujii Y, Tanaka R: Growth of incidental meningiomas. *Acta Neurochir (Wien)* 142:507-511, 2000