

NCBI Bookshelf. A service of the National Library of Medicine, National Institutes of Health.

PDQ Cancer Information Summaries [Internet]. Bethesda (MD): National Cancer Institute (US); 2002-.

## Childhood Astrocytomas Treatment (PDQ®)

### Health Professional Version

#### Authors

PDQ Pediatric Treatment Editorial Board.

Published online: April 5, 2022.

Created: August 21, 2009.

This PDQ cancer information summary for health professionals provides comprehensive, peer-reviewed, evidence-based information about the treatment of childhood astrocytomas. It is intended as a resource to inform and assist clinicians in the care of their patients. It does not provide formal guidelines or recommendations for making health care decisions.

This summary is reviewed regularly and updated as necessary by the PDQ Pediatric Treatment Editorial Board, which is editorially independent of the National Cancer Institute (NCI). The summary reflects an independent review of the literature and does not represent a policy statement of NCI or the National Institutes of Health (NIH).

### General Information About Childhood Astrocytomas

Primary brain tumors, including astrocytomas, are a diverse group of diseases that together constitute the most common solid tumors of childhood. Brain tumors are classified according to histology and molecular features, but tumor location and extent of spread are also important factors that affect treatment and prognosis.

Immunohistochemical analysis, cytogenetic and molecular genetic findings, and measures of mitotic activity are used in tumor diagnosis and classification.

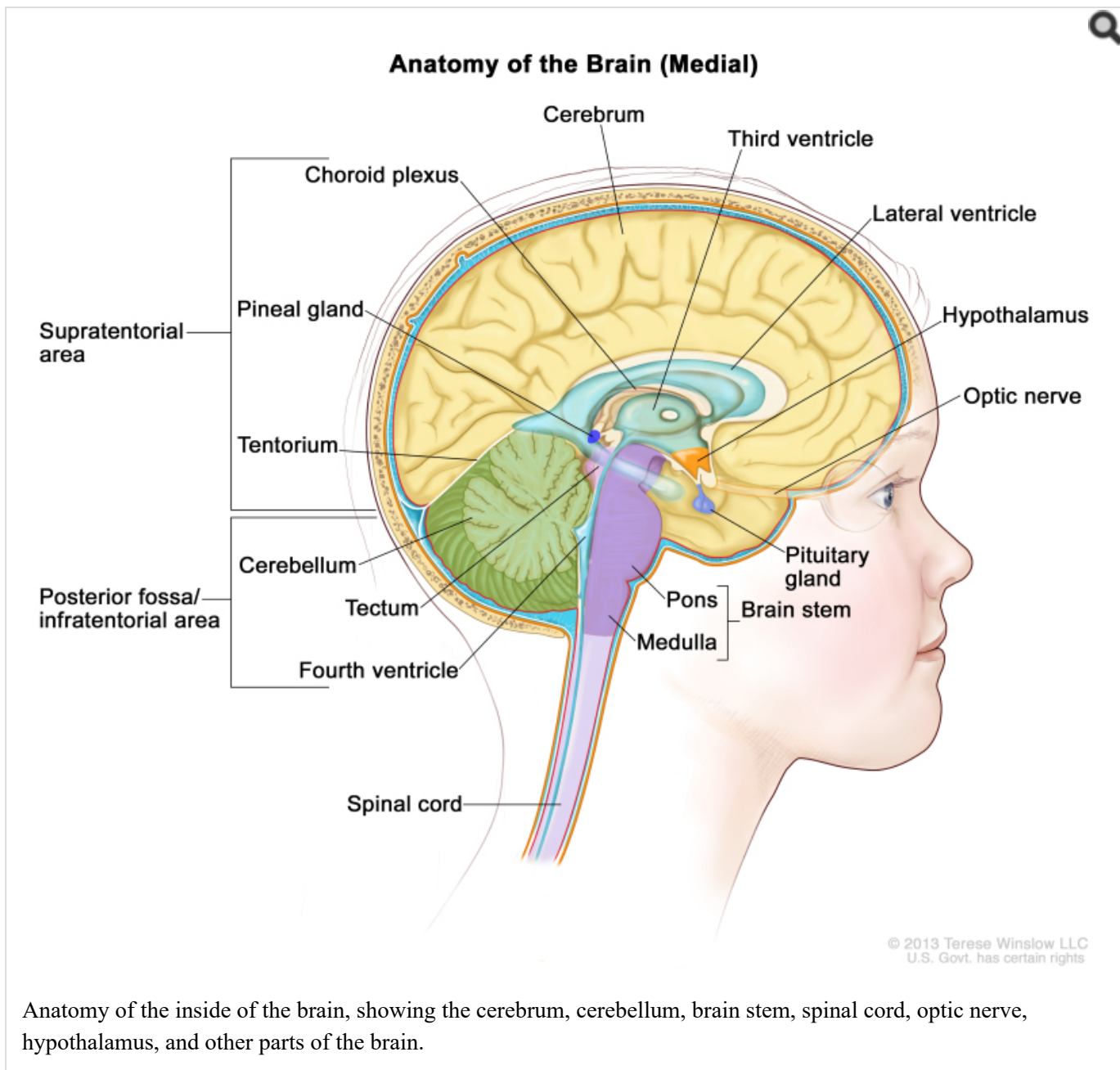
Gliomas are thought to arise from glial precursor cells that are present in the brain and spinal cord. Gliomas are named according to their presumed clinicopathological and histological subtype. Astrocytoma is the most commonly diagnosed type of glioma in children.

According to the World Health Organization (WHO) classification of brain tumors, gliomas are classified further as low-grade (grades I and II) or high-grade (grades III and IV) tumors. Children with low-grade tumors have a relatively favorable prognosis, especially when the tumors can be completely resected. Children with high-grade tumors generally have a less favorable prognosis, but this is somewhat dependent on subtype.

The PDQ childhood brain tumor treatment summaries are organized primarily according to the WHO classification of nervous system tumors.[1,2] For a full description of the classification of nervous system tumors and a link to the corresponding treatment summary for each type of brain tumor, refer to the PDQ summary on [Childhood Brain and Spinal Cord Tumors Treatment Overview](#).

### Anatomy

Childhood astrocytomas can occur anywhere in the central nervous system (CNS) (refer to the [Figure](#)). Refer to [Table 3](#) for the most common CNS location for each tumor type.



### Clinical Features

Presenting symptoms for childhood astrocytomas depend on the following:

- CNS location.
- Size of the tumor.
- Rate of tumor growth.
- Chronologic and developmental age of the child.

In infants and young children, low-grade astrocytomas presenting in the hypothalamus may result in diencephalic syndrome, which is manifested by failure to thrive in an emaciated, seemingly euphoric child. Such children may have little in the way of other neurologic findings, but can have macrocephaly, intermittent lethargy, and visual impairment.[3]

## Diagnostic Evaluation

The diagnostic evaluation for astrocytoma includes magnetic resonance imaging (MRI) of the brain or spine. For brain primary tumors, spinal MRI is usually performed in conjunction with the initial brain MRI to exclude neuraxis metastases.

Lumbar punctures examining the cerebrospinal fluid for circulating tumor cells are not commonly performed in children with this disease.

## Clinicopathological Classification of Childhood Astrocytomas and Other Tumors of Glial Origin

The pathological classification of pediatric brain tumors is a specialized area that is evolving. Examination of the diagnostic tissue by a neuropathologist who has particular expertise in this area is strongly recommended.

Tumor types are based on the putative glial cell type of origin, as follows:

- Astrocytomas (astrocytes).
- Oligodendroglial tumors (oligodendrocytes).
- Mixed gliomas (cell types of origin include oligodendrocytes, astrocytes, and ependymal cells).
- Mixed neuronal-glial tumors.

### WHO histological grade for astrocytic tumors

According to the WHO histological typing of CNS tumors, childhood astrocytomas and other tumors of glial origin are classified according to clinicopathological and histological subtype and are graded (grade I to IV).[1]

WHO histological grades are commonly referred to as low-grade gliomas or high-grade gliomas (refer to [Table 1](#)).

**Table 1. World Health Organization (WHO) Histological Grade and Corresponding Classification for Tumors of the Central Nervous System**

WHO Histological Grade	Grade Classification
I	Low grade
II	Low grade
III	High grade
IV	High grade

The 2016 WHO criteria began to utilize molecular data in the diagnosis of some tumors because of the accumulation of published evidence that tumor behavior is typically driven by common biological alterations (refer to [Table 2](#)). Within glial CNS tumors, this was most evident in changes in the classification of the diffuse gliomas, which were grouped together based on genetic driver mutations rather than histopathological similarities.[2] Two types of diffuse gliomas are no longer considered distinct entities: fibrillary astrocytoma and protoplasmic astrocytoma. Epithelioid glioblastoma is a new, provisionally included variant that is categorized as one subtype of *IDH*-wild-type glioblastoma.

**Table 2. 2016 World Health Organization (WHO) Classification and Histological Grade of Astrocytic Tumors<sup>a</sup>**

Type	WHO Histological Grade
<b>Diffuse Astrocytic Tumors:</b>	

Type	WHO Histological Grade
—Diffuse astrocytoma, <i>IDH</i> -mutant	II
—Anaplastic astrocytoma, <i>IDH</i> -mutant	III
—Glioblastoma, <i>IDH</i> -wild-type	IV
—Glioblastoma, <i>IDH</i> -mutant	IV
—Diffuse midline glioma, H3 K27M-mutant	IV
<b>Other Astrocytic Tumors:</b>	
—Pilocytic astrocytoma	I
—Pilomyxoid astrocytoma	Grade uncertain <sup>b</sup>
—Pilocytic astrocytoma with anaplasia	Grade uncertain <sup>c</sup>
—Pleomorphic xanthoastrocytoma	II
—Anaplastic pleomorphic xanthoastrocytoma	III
—Subependymal giant cell astrocytoma	I
<b>Other Gliomas:</b>	
—Angiocentric glioma	I
—Choroid glioma of the third ventricle	II
—Astroblastoma	Grade uncertain

<sup>a</sup>Adapted from Louis et al.[2]

<sup>b</sup>In 2007, the WHO determined that the pilomyxoid variant of pilocytic astrocytoma may be an aggressive variant that is more likely to disseminate, and it was reclassified as a grade II tumor.[1,2,4,5] In 2016, the WHO suggested not grading the pilomyxoid variant until further studies clarify its behavior.[1,2]

<sup>c</sup>In 2016, the WHO included this entity, which occurs most frequently in adults, to describe tumors harboring histological features of pilocytic astrocytoma, increased mitotic activity, and additional high-grade features. The grading and final nomenclature were not conclusively defined pending additional studies.[1,6]

### CNS location

Childhood astrocytomas and other tumors of glial origin can occur anywhere in the CNS, although each tumor type tends to have common CNS locations (refer to [Table 3](#)).

**Table 3. Common Central Nervous System (CNS) Locations for Childhood Astrocytomas and Other Tumors of Glial Origin**

Tumor Type	Common CNS Location
Pilocytic astrocytoma	Optic nerve, optic chiasm/hypothalamus, thalamus and basal ganglia, cerebral hemispheres, cerebellum, and brain stem; and spinal cord (rare)
Pleomorphic xanthoastrocytoma	Superficial location in cerebrum (temporal lobe preferentially)
Diffuse astrocytoma	Cerebrum (frontal and temporal lobes), brain stem, spinal cord, optic nerve, optic chiasm, optic pathway, hypothalamus, and thalamus
Anaplastic astrocytoma, glioblastoma	Cerebrum; occasionally cerebellum, brain stem, and spinal cord

Tumor Type	Common CNS Location
Diffuse midline glioma, H3 K27M-mutant	Pons, thalamus, spinal cord, and other midline structures

**Cerebellum:** More than 80% of astrocytomas located in the cerebellum are low grade (pilocytic grade I) and often cystic; most of the remainder are diffuse grade II astrocytomas. Malignant astrocytomas in the cerebellum are rare.[1,2] The presence of certain histological features (e.g., MIB-1 rate, anaplasia) has been used retrospectively to predict event-free survival for pilocytic astrocytomas arising in the cerebellum or other locations.[7-9]

**Brain stem:** Astrocytomas arising in the brain stem may be either high grade or low grade, with the frequency of either type being highly dependent on the location of the tumor within the brain stem.[10,11] Tumors not involving the pons are overwhelmingly low-grade gliomas (e.g., tectal gliomas of the midbrain), whereas tumors located exclusively in the pons without exophytic components are largely diffuse midline gliomas (e.g., diffuse intrinsic pontine gliomas with the H3 K27M-mutant genotype).[10,11] (Refer to the PDQ summary on [Childhood Brain Stem Glioma Treatment](#) for more information.)

**Cerebrum:** High-grade astrocytomas are often locally invasive and extensive and tend to occur above the tentorium in the cerebrum.[12] Spread via the subarachnoid space may occur. Metastasis outside of the CNS has been reported but is extremely infrequent until multiple local relapses have occurred.

**Gliomatosis cerebri** is no longer considered a distinct entity, but rather to be a growth pattern found in some diffuse astrocytic tumors and, occasionally, oligodendroglial tumors. The growth pattern encompasses widespread involvement of the cerebral hemispheres, often extending caudally to affect the brain stem, cerebellum, and/or spinal cord.[1] This pattern rarely arises in the cerebellum and spreads rostrally.[13] Patients with gliomatosis cerebri may respond to treatment initially, but overall have a poor prognosis.[14]

### Neurofibromatosis type 1 (NF1)

Children with NF1 have an increased propensity to develop WHO grade I and grade II astrocytomas in the visual (optic) pathway; up to 20% of patients with NF1 will develop an optic pathway glioma. In these patients, the tumor may be found on screening evaluations when the child is asymptomatic or has apparent static neurologic and/or visual deficits.

Pathological confirmation is frequently not obtained in asymptomatic patients; when biopsies have been performed, these tumors have been found to be predominantly pilocytic (grade I) rather than diffuse astrocytic tumors.[2,5,15]

In general, treatment is not required for incidental tumors found with surveillance neuroimaging. Symptomatic lesions, often causing vision impairment, or those that have radiographically progressed may require treatment.[16]

### Tuberous sclerosis

Patients with tuberous sclerosis have a predilection for low-grade glioma development, especially subependymal giant cell astrocytomas. Mutations in either *TSC1* or *TSC2* cause pathway alterations that impact the mammalian target of rapamycin (mTOR) pathway, leading to increases in proliferation. Subependymal giant cell astrocytomas have been sensitive to targeted approaches via inhibition of the mTOR pathway.[17]

## Genomic Alterations

### Molecular features of low-grade gliomas

#### *Pilocytic and diffuse astrocytomas*

Genomic alterations involving activation of *BRAF* and the ERK/MAPK pathway are very common in sporadic cases

of pilocytic astrocytoma, a type of low-grade glioma.

### *BRAF-KIAA1549 alterations*

*BRAF* activation in pilocytic astrocytoma occurs most commonly through a *BRAF-KIAA1549* gene fusion, producing a fusion protein that lacks the *BRAF* regulatory domain.[18-22] This fusion is seen in most infratentorial and midline pilocytic astrocytomas, but is present at lower frequency in supratentorial (hemispheric) tumors.[18,19,23-28]

Presence of the *BRAF-KIAA1549* fusion predicted a better clinical outcome (progression-free survival [PFS] and overall survival [OS]) in one report that described children with incompletely resected low-grade gliomas.[27] However, other factors such as *CDKN2A* deletion, whole chromosome 7 gain, and tumor location may modify the impact of the *BRAF* mutation on outcome.[29]; [30][Level of evidence: 3iiiDiii] Progression to high-grade glioma is rare for pediatric low-grade glioma with the *BRAF-KIAA1549* fusion.[31]

*BRAF* activation through the *BRAF-KIAA1549* fusion has also been described in other pediatric low-grade gliomas (e.g., pilomyxoid astrocytoma).[26,27] Other genomic alterations in pilocytic astrocytomas that can activate the ERK/MAPK pathway (e.g., alternative *BRAF* gene fusions, *RAF1* rearrangements, *RAS* mutations, and *BRAF* V600E point mutations) are less commonly observed.[19,21,22,32]

### *BRAF V600E mutations*

*BRAF* V600E point mutations are occasionally observed in pilocytic astrocytoma; the mutations are also observed in nonpilocytic pediatric low-grade gliomas, including ganglioglioma,[33] desmoplastic infantile ganglioglioma, and approximately two-thirds of pleomorphic xanthoastrocytomas.[34-36]

Studies have observed the following:

- In a retrospective series of more than 400 children with low-grade gliomas, 17% of tumors were *BRAF* V600E mutant. The 10-year PFS rate was 27% for *BRAF* V600E–mutant cases, compared with 60% for cases whose tumors did not harbor that mutation. Additional factors associated with this poor prognosis included subtotal resection and *CDKN2A* deletion.[37] Even in patients who underwent a gross-total resection, recurrence was noted in one-third of these cases, suggesting that *BRAF* V600E tumors have a more invasive phenotype than do other low-grade glioma variants.
- In a similar analysis, children with diencephalic low-grade astrocytomas with a *BRAF* V600E mutation had a 5-year PFS rate of 22%, compared with a PFS rate of 52% in children who were *BRAF* wild-type.[38][Level of evidence: 3iiiDiii]
- The frequency of the *BRAF* V600E mutation was significantly higher in pediatric low-grade glioma that transformed to high-grade glioma (8 of 18 cases) than was the frequency of the mutation in cases that did not transform to high-grade glioma (10 of 167 cases).[31]

### *Other mutations*

Activating mutations in *FGFR1*, *PTPN11*, and *NTRK2* fusion genes have also been identified in noncerebellar pilocytic astrocytomas.[39] In pediatric grade II diffuse astrocytomas, the most common alterations reported (up to 53% of tumors) are rearrangements in the *MYB* family of transcription factors.[40,41]

### *Angiocentric gliomas*

Angiocentric gliomas typically arise in children and young adults as cerebral tumors presenting with seizures.[2]

Two reports in 2016 identified *MYB* gene alterations as being present in almost all cases diagnosed as angiocentric glioma, with *QKI* being the primary fusion partner in cases where fusion-partner testing was possible.[42,43] While

angiocentric gliomas most commonly occur supratentorially, brain stem angiocentric gliomas with *MYB-QKI* fusions have also been reported.[44,45]

### **Astroblastomas**

Astroblastomas are defined histologically as glial neoplasms composed of GFAP-positive cells and contain astroblastic pseudorosettes that often demonstrate sclerosis. Astroblastomas are diagnosed primarily in childhood through young adulthood.[2]

The following studies have described genomic alterations associated with astroblastoma:

- A report describing a molecular classification of CNS primitive neuroectodermal tumors (PNETs) identified an entity termed *CNS high-grade neuroepithelial tumor with MNI alteration* (CNS HGNET-MN1) that was characterized by gene fusions involving *MNI*. [46] Most tumors with a histologic diagnosis of astroblastoma (16 of 23) belonged to this molecularly defined entity.
- A report of 27 histologically defined astroblastomas found that 10 cases had *MNI* rearrangements, 7 cases had *BRAF* rearrangements, and 2 cases had *RELA* rearrangements. [47] Methylation array analysis showed that the cases with *MNI* rearrangements clustered with CNS HGNET-MN1, the *BRAF*-mutated cases clustered with pleomorphic xanthoastrocytomas, and the *RELA* cases clustered with ependymomas.
- Genomic evaluation of eight cases of astroblastoma identified four with *MNI* alterations. Of the remaining four cases, two had genomic alterations consistent with high-grade glioma and two cases could not be classified on the basis of their molecular characteristics. [48]
- A study described eight cases of astroblastoma. All five cases that underwent fluorescence *in situ* hybridization analysis showed *MNI* rearrangements. [49]

These reports suggest that the histologic diagnosis of astroblastoma encompasses a heterogeneous group of genomically defined entities; astroblastomas with *MNI* fusions represent a distinctive subset of histologically diagnosed cases. [50]

### **Neurofibromatosis type 1 (NF1)**

Children with NF1-associated low-grade gliomas often have tumors in the optic pathway that are not biopsied. In a series of pediatric patients (n = 17; median age, 10 years) with NF1-associated low-grade gliomas in which tissue was collected and subjected to whole-exome sequencing, the number of mutations was very low (median, 6 per case). [51] Germline *NF1* mutations were observed in 88% of patients, and the most common somatic alteration was loss of heterozygosity for *NF1*, with a smaller number of cases showing inactivating mutations in the second *NF1* allele. *CDKN2A* loss was observed in 1 of 17 patients (6%). Alterations in *TP53* and *ATRX* were not observed among the 17 pediatric patients with NF1-associated low-grade gliomas. Activating *BRAF* genomic alterations are uncommon in pilocytic astrocytoma and other low-grade gliomas occurring in children with NF1. [25,51]

### **Tuberous sclerosis**

Most children with tuberous sclerosis have a germline mutation in one of two tuberous sclerosis genes (*TSC1* or *TSC2*). Either of these mutations results in activation of the mammalian target of rapamycin (mTOR) complex 1. These children are at risk of developing subependymal giant cell astrocytomas, cortical tubers, and subependymal nodules. Because subependymal giant cell astrocytomas are driven by mTOR activation, mTOR inhibitors are active agents that can induce tumor regression in children with these tumors. [52]

### **Molecular features of high-grade gliomas**

Pediatric high-grade gliomas, especially glioblastoma multiforme, are biologically distinct from those arising in adults.

[53-56]

*Subgroups identified using DNA methylation patterns*

Pediatric high-grade gliomas can be separated into distinct subgroups on the basis of epigenetic patterns (DNA methylation), and these subgroups show distinguishing chromosome copy number gains/losses and gene mutations in the tumor.[57-59] Particularly distinctive subtypes of pediatric high-grade gliomas are those with recurring mutations at specific amino acids in histone genes, and together these account for approximately one-half of pediatric high-grade gliomas.[59]

The following pediatric high-grade glioma subgroups were identified on the basis of their DNA methylation patterns, and they show distinctive molecular and clinical characteristics:[59]

1. **The histone K27 mutations: H3.3 (*H3F3A*) and H3.1 (*HIST1H3B* and, rarely, *HIST1H3C*) mutations at K27:** The histone K27–mutated cases occur predominantly in middle childhood (median age, approximately 10 years), are almost exclusively midline (thalamus, brain stem, and spinal cord), and carry a very poor prognosis. The 2016 WHO classification groups these cancers into a single entity—diffuse midline glioma, H3 K27M–mutant—although there are clinical and biological distinctions between cases with H3.3 and H3.1 mutations, as described below.[2] These cases can be diagnosed using immunohistochemistry to identify the presence of K27M.
  - **H3.3K27M:** H3.3K27M cases occur throughout the midline and pons, account for approximately 60% of cases in these locations, and commonly present between the ages of 5 and 10 years.[59] The prognosis for H3.3K27M patients is especially poor, with a median survival of less than 1 year; the 2-year survival is less than 5%.[59] Leptomeningeal dissemination is frequently observed in H3.3K27M patients.[60]
  - **H3.1K27M:** H3.1K27M cases are approximately fivefold less common than H3.3K27M cases. They occur primarily in the pons and present at a younger age than other H3.3K27M cases (median age, 5 years vs. 6–10 years). These cases have a slightly more favorable prognosis than do H3.3K27M cases (median survival, 15 months vs. 11 months). Mutations in *ACVRI*, which is also the mutation observed in the genetic condition fibrodysplasia ossificans progressiva, are present in a high proportion of H3.1K27M cases.[59,61,62]
  - **H3.2K27M:** Rarely, K27M mutations are also identified in H3.2 (*HIST2H3C*) cases.[59]
2. **H3.3 (*H3F3A*) mutation at G34:** The H3.3G34 subtype arises from H3.3 glycine 34 to arginine/valine (G34R/V) mutations.[57,58] This subtype presents in older children and young adults (median age, 14–18 years) and arises exclusively in the cerebral cortex.[57,58] H3.3G34 cases commonly have mutations in *TP53* and *ATRX* (95% and 84% of cases, respectively, in one large series) and show widespread hypomethylation across the whole genome. In a series of 95 patients with the H3.3G34 subtype, 44% of patients also had a mutation in *PDGFRA* at the time of diagnosis, and 81% of patients had *PDGFRA* mutations observed at relapse.[63]
 

Patients with *H3F3A* mutations are at high risk of treatment failure,[64] but the prognosis is not as poor as that of patients with histone 3.1 or 3.3 K27M mutations.[58] O-6-methylguanine-DNA methyltransferase (MGMT) methylation is observed in approximately two-thirds of cases, and aside from the *IDH1*-mutated subtype (see below), the H3.3G34 subtype is the only pediatric high-grade glioma subtype that demonstrates MGMT methylation rates exceeding 20%.[59]
3. ***IDH1* mutation:** *IDH1*-mutated cases represent a small percentage of pediatric high-grade gliomas (approximately 5%), and pediatric high-grade glioma patients whose tumors have *IDH1* mutations are almost exclusively older adolescents (median age in a pediatric population, 16 years) with hemispheric tumors.[59] *IDH1*-mutated cases often show *TP53* mutations, MGMT promoter methylation, and a glioma-CpG island methylator phenotype (G-CIMP).[57,58] Pediatric patients with *IDH1* mutations show a more favorable



prognosis than do other pediatric glioblastoma multiforme patients; 5-year overall survival (OS) rates exceed 60% for pediatric patients with *IDH1* mutations, compared with 5-year OS rates of less than 20% for patients with wild-type *IDH1*.<sup>[59]</sup>

4. **Pleomorphic xanthoastrocytoma (PXA)–like:** Approximately 10% of pediatric high-grade gliomas have DNA methylation patterns that are PXA-like.<sup>[58]</sup> PXA-like cases commonly have *BRAF* V600E mutations and a relatively favorable outcome (approximately 50% survival at 5 years).<sup>[59,64]</sup>
5. **Low-grade glioma–like:** A small subset of pediatric brain tumors with the histological appearance of high-grade gliomas show DNA methylation patterns like those of low-grade gliomas.<sup>[58,59]</sup> These cases are primarily observed in young patients (median age, 4 years); 10 of 16 infants with a glioblastoma multiforme diagnosis were in the low-grade glioma–like group.<sup>[59]</sup> The prognosis for these patients is much more favorable than for other pediatric high-grade glioma subtypes.<sup>[64]</sup> Refer below for additional discussion of glioblastoma multiforme in infants.
6. **Pilocytic astrocytoma with anaplasia:** This entity was included in the 2016 WHO classification to describe tumors with histological features of pilocytic astrocytoma, increased mitotic activity, and additional high-grade features. A more recent publication described a cohort of 83 cases with these histological features (referred to as *anaplastic astrocytoma with piloid features*) that shared a common DNA methylation profile, which is distinct from the methylation profiles of other gliomas. These tumors occurred more often in adults (median age, 41 years), and they harbored frequent deletions of *CDKN2A/B*, MAPK pathway alterations (most often in the *NFI* gene), and mutations or deletions of *ATRX*. They are associated with a clinical course that is intermediate between pilocytic astrocytoma and *IDH*–wild-type glioblastoma.<sup>[6]</sup>

#### Other mutations

Pediatric glioblastoma multiforme high-grade glioma patients whose tumors lack both histone mutations and *IDH1* mutations represent approximately 40% of pediatric glioblastoma multiforme cases.<sup>[59,65]</sup> This is a heterogeneous group, with higher rates of gene amplifications than other pediatric high-grade glioma subtypes. The most commonly amplified genes are *PDGFRA*, *EGFR*, *CCND/CDK*, and *MYC/MYC*N;<sup>[57,58]</sup> MGMT promoter methylation rates are low in this group.<sup>[65]</sup> One report divided this group into three subtypes. The subtype characterized by high rates of *MYCN* amplification showed the poorest prognosis, while the subtype characterized by *TERT* promoter mutations and *EGFR* amplification showed the most favorable prognosis. The third group was characterized by *PDGFRA* amplification.<sup>[65]</sup>

#### High-grade gliomas in infants

Infants and young children with high-grade gliomas appear to have tumors with distinctive molecular characteristics when compared with tumors of older children and adults with high-grade gliomas. An indication of this difference was noted with the application of DNA methylation analysis to pediatric high-grade tumors, which found that approximately 7% of pediatric patients with a histological diagnosis of high-grade glioma had tumors with methylation patterns more closely resembling those of low-grade gliomas.<sup>[59]</sup> Ten of 16 infants (younger than 1 year) with a high-grade glioma diagnosis were in this methylation array–defined group.<sup>[59]</sup> The 5-year survival rate for patients in this report diagnosed at younger than 1 year exceeded 60%, while the 5-year survival rate for patients aged 1 to 3 years and older was less than 20%.

Two studies of the molecular characteristics of high-grade gliomas in infants and young children have further defined the distinctive nature of tumors arising in children younger than 1 year. A key finding from both studies is the importance of gene fusions involving tyrosine kinases (e.g., *ALK*, *NTRK1*, *NTRK2*, *NTRK3*, and *ROS1*) in patients in this age group. Both studies also found that infants with high-grade gliomas whose tumors have these gene fusions have survival rates much higher than those of older children with high-grade gliomas.<sup>[66,67]</sup>

The first study presented data for 118 children younger than 1 year with a low-grade or high-grade glioma diagnosis who had tumor tissue available for genomic characterization.[66] Approximately 75% of the cases were classified as low grade, but the diminished utility of histological classification in this age group was illustrated by the relatively low OS rate for the low-grade cohort (71%) and the relatively favorable survival for the high-grade cohort (55%). Rates of surgical resection were higher for patients with high-grade tumors, a result of many of the low-grade tumors occurring in midline locations while the high-grade tumors were found in supratentorial locations; this finding may also help to explain the relative outcomes for the two groups. Genomic characterization divided the infant glioma population into the following three groups, the first of which included patients with high-grade gliomas:

- Group 1 tumors were receptor tyrosine kinase driven and primarily high grade (83%). These tumors harbored lesions in *ALK*, *ROS1*, *NTRK*, and *MET*. Median age at diagnosis was 3 months, and OS rates were approximately 60%.
- Group 2 tumors were RAS/MAPK driven and were all hemispheric low-grade gliomas, representing one-fourth of hemispheric gliomas in infants. *BRAF* V600E was the most common alteration, followed by *FGFR1* alterations and *BRAF* fusions. This group had a median age at presentation of 8 months and had the most favorable outcome (10-year OS rate, 93%).
- Group 3 tumors were RAS/MAPK driven with low-grade histology and midline presentation (approximately 80% optic pathway/hypothalamic gliomas). Most group 3 tumors showed either *BRAF* fusions or *BRAF* V600E. Median age at diagnosis was 7.5 months. The progression-free survival (PFS) rate at 5-years was approximately 20%, and the OS rate at 10 years was approximately 50% (far inferior to that of optic pathway/hypothalamic gliomas in children aged >1 year).

The second study focused on tumors from children younger than 4 years with a pathological diagnosis of WHO grades II, III, and IV gliomas, astrocytomas, or glioneuronal tumors. Among the 191 tumors studied that met inclusion criteria, 61 had methylation profiles consistent with glioma subtypes that occur in older children (e.g., *IDH1*, diffuse midline glioma K27M-mutant, subependymal giant cell astrocytoma, pleomorphic xanthoastrocytoma, etc.). The remaining 130 cases were termed the *intrinsic set* and were the focus of additional molecular characterization:[67]

- The *intrinsic set* contained most of the patients diagnosed before age 1 year (49 of 63 patients, 78%) and had a median age of 7.2 months. Tumors were frequently in a superficial hemispheric location, often involving the meninges, and had a well-defined border with adjacent normal brain.
- The methylation classifier placed most of these cases in either the desmoplastic infantile ganglioglioma/astrocytoma (DIGG/DIA) subgroup or in the infantile hemispheric glioma subgroup.
- For 41 tumors from the *intrinsic set* in which tissue was available for gene panel and RNA sequencing, 25 tumors had fusions involving either *ALK* (n = 10), *NTRK1* (n = 2), *NTRK2* (n = 2), *NTRK3* (n = 8), *ROS1* (n = 2), or *MET* (n = 1). *BRAF* mutations (n = 3) were observed in cases that were high scoring by methylation array for the DIGG/DIA or DIGG/DIA-like subgroups.
- For patients in the *intrinsic set*, the 5-year survival rate appeared higher for patients whose tumors had gene fusions when compared with patients whose tumors lacked fusions (approximately 80% vs. 60%, respectively); however, both of these groups of patients had much higher survival rates than did other children with high-grade gliomas.

### Secondary high-grade glioma

Childhood secondary high-grade glioma (high-grade glioma that is preceded by a low-grade glioma) is uncommon (2.9% in a study of 886 patients). No pediatric low-grade gliomas with the *BRAF-KIAA1549* fusion transformed to a high-grade glioma, whereas low-grade gliomas with the *BRAF* V600E mutations were associated with increased risk

of transformation. Seven of 18 patients (approximately 40%) with secondary high-grade glioma had *BRAF* V600E mutations, with *CDKN2A* alterations present in 8 of 14 cases (57%).[31]

### *Neurofibromatosis type 1 (NF1)*

High-grade gliomas can arise in children with NF1, although low-grade gliomas are much more common. When a high-grade tumor occurs, it is most often in adulthood. Genomic characterization of 23 patients with NF1-associated high-grade gliomas (median age, 38.8 years; 5 patients younger than 18 years) showed higher rates of mutations compared with NF1 patients who had low-grade gliomas (21.5 vs. 6 mutations, respectively).[51] The vast majority of patients showed *NF1* germline mutations, with either loss of heterozygosity or with an inactivating mutation in the second *NF1* allele. In contrast to NF1-associated low-grade gliomas, genomic alterations associated with high-grade gliomas were common (*CDKN2A* [58%], *ATRX* [38%], and *TP53* [29%]).[51]

### **Molecular features of neuronal and mixed neuronal-glia tumors**

Neuronal and mixed neuronal-glia tumors are generally low-grade tumors, with an exception of the grade III anaplastic gangliogliomas. The histologies recognized by the 2016 WHO classification include the following:[2]

- Dysembryoplastic neuroepithelial tumor.
- Gangliocytoma.
- Ganglioglioma.
- Anaplastic ganglioglioma.
- Dysplastic cerebellar gangliocytoma (Lhermitte-Duclos disease).
- Desmoplastic infantile astrocytoma and ganglioglioma.
- Papillary glioneuronal tumor.
- Rosette-forming glioneuronal tumor.
- Diffuse leptomeningeal glioneuronal tumor.
- Central neurocytoma.
- Extraventricular neurocytoma.
- Cerebellar liponeurocytoma.
- Paraganglioma.

### *Dysembryoplastic neuroepithelial tumor (DNET)*

DNET presents in children and adults, with the median age at diagnosis in mid-to-late adolescence. It is characterized histopathologically by the presence of columns of oligodendroglial-like cells and cortical ganglion cells floating in mucin.[1] The temporal lobe is the most common location, and it is associated with drug-refractory epilepsy.[68,69]

*FGFR1* alterations have been reported in 60% to 80% of DNETs, and include *FGFR1* activating point mutations, internal tandem duplication of the kinase domain, and activating gene fusions.[43,70,71] *BRAF* mutations are uncommon in DNET.

### *DNET of the septum pellucidum*

Septal DNET generally presents with symptoms related to obstructive hydrocephalus.[72,73] Septal DNET has an indolent clinical behavior, with most tumors not requiring treatment other than surgery. In a single-institution series

that incorporated other literature-reported cases, the median age at presentation was in the adolescent age range.[74] Mutations that are common in low-grade gliomas (e.g., *BRAF* V600E) and in cortical DNETs (*FGFR1* mutations) are uncommon in septal DNET.[73-75] Instead, mutations in *PDGFRA* at the K385 residue typify most cases of septal DNET.

A report of the molecular characterization of 18 septal DNETs showed that 14 had a *PDGFRA* mutation, with all but one being a mutation at the K385 residue,[74] which is in the extracellular region of *PDGFRA* that mediates the receptor-receptor interaction required for dimerization and activation upon binding of PDGFs. Among the remaining four cases, three had *FGFR1* mutations in line with those observed in cortical DNET. A second report observed *PDGFRA* mutations at K385 in each of four cases of septal DNET.[75] Combined, the two reports indicate that septal DNET is a distinct entity characterized by a stereotypic anatomic location and, in most cases, a *PDGFRA* mutation. Low-grade glioneuronal tumors with the K385 *PDGFRA* mutation have also been identified as arising in the corpus callosum and periventricular white matter of the lateral ventricle, leading to the proposal that *myxoid glioneuronal tumor; PDGFRA p.K385-mutant* be considered as a distinct central nervous system (CNS) tumor entity.[76]

### *Ganglioglioma*

Ganglioglioma presents during childhood and into adulthood. It most commonly arises in the cerebral cortex and is associated with seizures, but also presents in other sites, including the spinal cord.[68,77]

The unifying theme for the molecular pathogenesis of ganglioglioma is genomic alterations leading to MAPK pathway activation.[43,78] *BRAF* alterations are observed in approximately 50% of ganglioglioma cases, with V600E being by far the most common alteration; however, other *BRAF* mutations and gene fusions are also observed. Other less commonly altered genes in ganglioglioma include *KRAS*, *FGFR1/2*, *RAF1*, *NTRK2*, and *NF1*. [43,78]

### *Desmoplastic infantile astrocytomas (DIA) and desmoplastic infantile gangliogliomas (DIG)*

DIA and DIG most often present in the first year of life and show a characteristic imaging appearance in which a contrast-enhancing solid nodule accompanies a large cystic component.[79,80] DIG is more common than DIA,[79] and by methylation array analysis, both diagnoses cluster together.[81] Survival outcome is generally favorable with surgical resection.[79]

The most commonly observed genomic alterations in DIA and DIG are *BRAF* mutations involving V600; gene fusions involving kinase genes are observed less frequently.

- Among 16 cases confirmed by histology and DNA methylation profiling to be DIA and DIG, *BRAF* mutations were observed in seven cases (43.8%): four *BRAF* V600E mutations and three *BRAF* V600D mutations. One additional case had an *EML4-ALK* fusion. *BRAF* mutations were present in 4 of 12 (25%) DIG cases (with 3 of 4 mutated cases having *BRAF* V600D) and in 3 of 4 (75%) DIA cases (all 3 mutated cases with *BRAF* V600E).
- A study of seven DIG cases found MAPK pathway alterations in four (57%).[82] Three alterations involved *BRAF* (V600E, V600D, and one deletion/insertion centered at V600) and one was a *TPM3-NTRK1* in-frame fusion. Notably, the variant allele frequency was low (8%–27%), suggesting that DIG is characterized by a prominent nonneoplastic component resulting in low clonal driver mutation allele frequencies.
- Another report also described the *BRAF* V600D mutation in a DIG case.[83] As the V600D mutation is far less common than V600E in other cancers, its detection in multiple DIG cases suggests an association between the mutation and DIG.

### *Papillary glioneuronal tumor*

Papillary glioneuronal tumor is a low-grade biphasic neoplasm with astrocytic and neuronal differentiation that primarily arises in the supratentorial compartment.[2] The median age at presentation is in the early 20s, but it can be

observed during childhood through adulthood.

The primary genomic alteration associated with papillary glioneuronal tumor is a gene fusion, *SLC44A1-PRKCA*, that is associated with the t(9:17)(q31;q24) translocation.[84,85] In one study of 28 cases diagnosed histologically as papillary glioneuronal tumor using methylation arrays, 11 of the cases clustered in a distinctive methylation class, while the remaining cases showed methylation profiles typical for other tumor entities. Molecular analysis of the cases in the distinctive methylation cluster showed that all of them had the *SLC44A1-PRKCA* gene fusion except for a single case with a *NOTCH1-PRKCA* gene fusion.[86] This suggests that molecular methods for identifying the presence of a *PRKCA* fusion are less susceptible to misclassification in diagnosing papillary glioneuronal tumor than are morphology-based methods.

#### *Rosette-forming glioneuronal tumor (RGNT)*

RGNT presents in adolescents and adults, with tumors generally located infratentorially, although tumors can arise in mesencephalic or diencephalic regions.[87] The typical histological appearance shows both a glial component and a neurocytic component arranged in rosettes or perivascular pseudorosettes.[2] Outcome for patients with RGNT is generally favorable, consistent with the WHO grade I designation.[87]

DNA methylation profiling shows that RGNT has a distinct epigenetic profile that distinguishes it from other low-grade glial/glioneuronal tumor entities.[87] A study of 30 cases of RGNT observed *FGFR1* hotspot mutations in all analyzed tumors.[87] In addition, *PIK3CA* activating mutations were concurrently observed in 19 of 30 cases (63%). Missense or damaging mutations in *NF1* were identified in 10 of 30 cases (33%), with 7 tumors having mutations in *FGFR1*, *PIK3CA*, and *NF1*. The co-occurrence of mutations that activate both the MAPK pathway and the PI3K pathway makes the mutation profile of RGNT distinctive among astrocytic and glioneuronal tumors.

#### *Diffuse leptomeningeal glioneuronal tumor (DLGNT)*

DLGNT is a rare CNS tumor that has been characterized radiographically by leptomeningeal enhancement on magnetic resonance imaging (MRI) that may involve the posterior fossa, brain stem region, and spinal cord.[88] Intraparenchymal lesions, when present, typically involve the spinal cord;[88] localized intramedullary glioneuronal tumors without leptomeningeal dissemination and with histomorphologic, immunophenotypic, and genomic characteristics similar to DLGNT have been reported.[89]

DLGNT showed a distinctive epigenetic profile on DNA methylation arrays, and unsupervised clustering of array data applied to 30 cases defined two subclasses of DLGNT: methylation class (MC)-1 (n = 17) and MC-2 (n = 13).[88] Of note, many of the array-defined cases had originally been diagnosed as other entities (e.g., primitive neuroectodermal tumors, pilocytic astrocytoma, and anaplastic astrocytoma). Patients with DLGNT-MC-1 were diagnosed at an earlier age than were patients with DLGNT-MC-2 (5 years vs. 14 years, respectively). The 5-year overall survival rate was higher for patients with DLGNT-MC-1 than for those with DLGNT-MC-2 (100% vs. 43%, respectively). Genomic findings from the 30 methylation array-defined DLGNT cases are provided below:

- All 30 cases showed loss of chromosome 1p, but only 6 of 17 DLGNT-MC-1 cases showed additional gain of chromosome 1q, compared with all cases of DLGNT-MC-2.[88] A separate report found that chromosome 1q gain was an adverse prognostic factor in patients with DLGNT (including cases with localized disease),[90] which is consistent with the inferior outcome for patients with DLGNT-MC-2.
- Co-deletions of 1p/19q were more frequent in the DLGNT-MC-1 group (7 of 13, 54%) than in the DLGNT-MC-2 group (2 of 13, 15%). In contrast to oligodendroglioma, mutations of *IDH1* and *IDH2* were not identified.[88]
- MAPK pathway activation is common in DLGNT cases.[88] The *KIAA1549-BRAF* fusion was present in 11 of 15 DLGNT-MC-1 cases (65%) and in 9 of 13 DLGNT-MC-2 cases (69%). Fusions involving *NTRK1/2/3* were

present in one case each, and another case had a *TRIM33-RAF1* fusion.

### *Extraventricular neurocytoma*

Extraventricular neurocytoma is histologically similar to central neurocytoma, consisting of small uniform cells that demonstrate neuronal differentiation, but it arises in the brain parenchyma rather than in association with the ventricular system.[2] It presents during childhood through adulthood.

In a study of 40 tumors histologically classified as extraventricular neurocytoma and subjected to methylation array analysis, only 26 formed a separate cluster distinctive from reference tumors of other histologies.[91] Among cases with an extraventricular neurocytoma methylation array classification for which genomic characterization could be performed, 11 of 15 (73%) showed rearrangements affecting members of the FGFR family, with *FGFR1-TACCI* being the most common alteration.[91]

## Prognosis

### Low-grade astrocytomas

Low-grade astrocytomas (grade I [pilocytic] and grade II) have a relatively favorable prognosis, particularly for well-circumscribed lesions where complete excision may be possible.[12,92-95] Tumor spread, when it occurs, is usually by contiguous extension; dissemination to other CNS sites is uncommon, but does occur.[96,97] Although metastasis is uncommon, tumors may be of multifocal origin, especially when associated with NF1.

Unfavorable prognostic features for childhood low-grade astrocytomas include the following:[98-101]

- Young age.[101]
- Diffuse histology, especially *IDH* mutant.
- Inability to obtain a complete resection.
- Diencephalic syndrome.[101]
- Metastases. When metastasis does occur, it is associated with a poorer long-term outcome.[102] However, it is increasingly evident that prognosis is largely dependent on specific molecular features integrated with standard pathological grouping.

In patients with pilocytic astrocytoma, elevated MIB-1 labeling index, a marker of cellular proliferative activity, is associated with shortened PFS.[9] A *BRAF-KIAA1549* fusion, found in pilocytic tumors, confers a better clinical outcome.[27]

In children with tumors of the visual pathway, outcome is not only assessed by radiographic disease control or survival but also by visual outcome. Children with isolated optic nerve tumors have a better prognosis than do children with lesions that involve the chiasm or that extend along the optic pathway.[103,104]; [105][Level of evidence: 3iiC] Children with NF1 also have a better prognosis, especially when the tumor is found in asymptomatic patients at the time of screening.[106] Better visual acuity at diagnosis, older age at diagnosis, and presence of NF1 are associated with better visual outcomes.[107]

### High-grade astrocytomas

Although high-grade astrocytomas generally carry a poor prognosis in younger patients, those with anaplastic astrocytomas in whom a gross-total resection is possible may fare better,[93,108,109] as well as those with non-H3 K27M-mutant tumors.

Molecular subtypes of pediatric glioblastoma multiforme show prognostic significance.[58] Patients whose tumors

have histone K27M mutations have the poorest prognosis, with 3-year survival rates below 5%. In the thalamus, wild-type high-grade gliomas have a somewhat better prognosis than do those harboring an H3.3 mutation. For high-grade gliomas in the thalamus, patients with H3 wild-type tumors have a somewhat better prognosis (2-year overall survival [OS], 71%) than do patients who harbor H3 K27M mutations (2-year OS, 13%).<sup>[110]</sup> Patients whose tumors have *IDH1* mutations appear to have the most favorable prognosis among pediatric glioblastoma multiforme cases, while those with histone G34 mutations and those lacking both histone and *IDH1* mutations have an intermediate prognosis (3-year OS, approximately 30%). In a multivariate analysis that included both molecular and clinical factors, the presence of gene amplifications and K27M mutations were associated with a poorer prognosis, while the presence of *IDH1* mutations was associated with a more favorable prognosis.<sup>[58]</sup>

## References

1. Louis DN, Ohgaki H, Wiestler OD: WHO Classification of Tumours of the Central Nervous System. 4th rev.ed. IARC Press, 2016.
2. Louis DN, Perry A, Reifenberger G, et al.: The 2016 World Health Organization Classification of Tumors of the Central Nervous System: a summary. *Acta Neuropathol* 131 (6): 803-20, 2016. [PubMed: 27157931]
3. Kilday JP, Bartels U, Huang A, et al.: Favorable survival and metabolic outcome for children with diencephalic syndrome using a radiation-sparing approach. *J Neurooncol* 116 (1): 195-204, 2014. [PubMed: 24218181]
4. Louis DN, Ohgaki H, Wiestler OD, et al., eds.: WHO Classification of Tumours of the Central Nervous System. 4th ed. IARC Press, 2007. [PMC free article: PMC1929165] [PubMed: 17618441]
5. Komotar RJ, Burger PC, Carson BS, et al.: Pilocytic and pilomyxoid hypothalamic/chiasmatic astrocytomas. *Neurosurgery* 54 (1): 72-9; discussion 79-80, 2004. [PubMed: 14683543]
6. Reinhardt A, Stichel D, Schrimpf D, et al.: Anaplastic astrocytoma with piloid features, a novel molecular class of IDH wildtype glioma with recurrent MAPK pathway, CDKN2A/B and ATRX alterations. *Acta Neuropathol* 136 (2): 273-291, 2018. [PubMed: 29564591]
7. Tibbetts KM, Emmett RJ, Gao F, et al.: Histopathologic predictors of pilocytic astrocytoma event-free survival. *Acta Neuropathol* 117 (6): 657-65, 2009. [PubMed: 19271226]
8. Rodriguez FJ, Scheithauer BW, Burger PC, et al.: Anaplasia in pilocytic astrocytoma predicts aggressive behavior. *Am J Surg Pathol* 34 (2): 147-60, 2010. [PubMed: 20061938]
9. Margraf LR, Gargan L, Butt Y, et al.: Proliferative and metabolic markers in incompletely excised pediatric pilocytic astrocytomas--an assessment of 3 new variables in predicting clinical outcome. *Neuro Oncol* 13 (7): 767-74, 2011. [PMC free article: PMC3129272] [PubMed: 21653594]
10. Fried I, Hawkins C, Scheinemann K, et al.: Favorable outcome with conservative treatment for children with low grade brainstem tumors. *Pediatr Blood Cancer* 58 (4): 556-60, 2012. [PubMed: 21618421]
11. Fisher PG, Breiter SN, Carson BS, et al.: A clinicopathologic reappraisal of brain stem tumor classification. Identification of pilocystic astrocytoma and fibrillary astrocytoma as distinct entities. *Cancer* 89 (7): 1569-76, 2000. [PubMed: 11013373]
12. Pfister S, Witt O: Pediatric gliomas. *Recent Results Cancer Res* 171: 67-81, 2009. [PubMed: 19322538]
13. Rorke-Adams LB, Portnoy H: Long-term survival of an infant with gliomatosis cerebelli. *J Neurosurg Pediatr* 2 (5): 346-50, 2008. [PubMed: 18976105]
14. Armstrong GT, Phillips PC, Rorke-Adams LB, et al.: Gliomatosis cerebri: 20 years of experience at the Children's Hospital of Philadelphia. *Cancer* 107 (7): 1597-606, 2006. [PubMed: 16955507]
15. Allen JC: Initial management of children with hypothalamic and thalamic tumors and the modifying role of neurofibromatosis-1. *Pediatr Neurosurg* 32 (3): 154-62, 2000. [PubMed: 10867564]
16. Molloy PT, Bilaniuk LT, Vaughan SN, et al.: Brainstem tumors in patients with neurofibromatosis type 1: a distinct clinical entity. *Neurology* 45 (10): 1897-902, 1995. [PubMed: 7477989]
17. Franz DN, Weiss BD: Molecular therapies for tuberous sclerosis and neurofibromatosis. *Curr Neurol Neurosci Rep* 12 (3): 294-301, 2012. [PubMed: 22544507]
18. Bar EE, Lin A, Tihan T, et al.: Frequent gains at chromosome 7q34 involving BRAF in pilocytic astrocytoma. *J*

- Neuropathol Exp Neurol 67 (9): 878-87, 2008. [PubMed: 18716556]
19. Forshew T, Tatevossian RG, Lawson AR, et al.: Activation of the ERK/MAPK pathway: a signature genetic defect in posterior fossa pilocytic astrocytomas. *J Pathol* 218 (2): 172-81, 2009. [PubMed: 19373855]
  20. Jones DT, Kocialkowski S, Liu L, et al.: Tandem duplication producing a novel oncogenic BRAF fusion gene defines the majority of pilocytic astrocytomas. *Cancer Res* 68 (21): 8673-7, 2008. [PMC free article: PMC2577184] [PubMed: 18974108]
  21. Jones DT, Kocialkowski S, Liu L, et al.: Oncogenic RAF1 rearrangement and a novel BRAF mutation as alternatives to KIAA1549:BRAF fusion in activating the MAPK pathway in pilocytic astrocytoma. *Oncogene* 28 (20): 2119-23, 2009. [PMC free article: PMC2685777] [PubMed: 19363522]
  22. Pfister S, Janzarik WG, Remke M, et al.: BRAF gene duplication constitutes a mechanism of MAPK pathway activation in low-grade astrocytomas. *J Clin Invest* 118 (5): 1739-49, 2008. [PMC free article: PMC2289793] [PubMed: 18398503]
  23. Korshunov A, Meyer J, Capper D, et al.: Combined molecular analysis of BRAF and IDH1 distinguishes pilocytic astrocytoma from diffuse astrocytoma. *Acta Neuropathol* 118 (3): 401-5, 2009. [PubMed: 19543740]
  24. Horbinski C, Hamilton RL, Nikiforov Y, et al.: Association of molecular alterations, including BRAF, with biology and outcome in pilocytic astrocytomas. *Acta Neuropathol* 119 (5): 641-9, 2010. [PMC free article: PMC5859320] [PubMed: 20044755]
  25. Yu J, Deshmukh H, Gutmann RJ, et al.: Alterations of BRAF and HIPK2 loci predominate in sporadic pilocytic astrocytoma. *Neurology* 73 (19): 1526-31, 2009. [PMC free article: PMC2777068] [PubMed: 19794125]
  26. Lin A, Rodriguez FJ, Karajannis MA, et al.: BRAF alterations in primary glial and glioneuronal neoplasms of the central nervous system with identification of 2 novel KIAA1549:BRAF fusion variants. *J Neuropathol Exp Neurol* 71 (1): 66-72, 2012. [PMC free article: PMC4629834] [PubMed: 22157620]
  27. Hawkins C, Walker E, Mohamed N, et al.: BRAF-KIAA1549 fusion predicts better clinical outcome in pediatric low-grade astrocytoma. *Clin Cancer Res* 17 (14): 4790-8, 2011. [PubMed: 21610142]
  28. Becker AP, Scapulatempo-Neto C, Carloni AC, et al.: KIAA1549: BRAF Gene Fusion and FGFR1 Hotspot Mutations Are Prognostic Factors in Pilocytic Astrocytomas. *J Neuropathol Exp Neurol* 74 (7): 743-54, 2015. [PMC free article: PMC4470527] [PubMed: 26083571]
  29. Horbinski C, Nikiforova MN, Hagenkord JM, et al.: Interplay among BRAF, p16, p53, and MIB1 in pediatric low-grade gliomas. *Neuro Oncol* 14 (6): 777-89, 2012. [PMC free article: PMC3367847] [PubMed: 22492957]
  30. Roth JJ, Fierst TM, Waanders AJ, et al.: Whole Chromosome 7 Gain Predicts Higher Risk of Recurrence in Pediatric Pilocytic Astrocytomas Independently From KIAA1549-BRAF Fusion Status. *J Neuropathol Exp Neurol* 75 (4): 306-15, 2016. [PMC free article: PMC5009478] [PubMed: 26945035]
  31. Mistry M, Zhukova N, Merico D, et al.: BRAF mutation and CDKN2A deletion define a clinically distinct subgroup of childhood secondary high-grade glioma. *J Clin Oncol* 33 (9): 1015-22, 2015. [PMC free article: PMC4356711] [PubMed: 25667294]
  32. Janzarik WG, Kratz CP, Loges NT, et al.: Further evidence for a somatic KRAS mutation in a pilocytic astrocytoma. *Neuropediatrics* 38 (2): 61-3, 2007. [PubMed: 17712732]
  33. López GY, Van Ziffle J, Onodera C, et al.: The genetic landscape of gliomas arising after therapeutic radiation. *Acta Neuropathol* 137 (1): 139-150, 2019. [PMC free article: PMC6589431] [PubMed: 30196423]
  34. Dougherty MJ, Santi M, Brose MS, et al.: Activating mutations in BRAF characterize a spectrum of pediatric low-grade gliomas. *Neuro Oncol* 12 (7): 621-30, 2010. [PMC free article: PMC2940652] [PubMed: 20156809]
  35. Dias-Santagata D, Lam Q, Vernovsky K, et al.: BRAF V600E mutations are common in pleomorphic xanthoastrocytoma: diagnostic and therapeutic implications. *PLoS One* 6 (3): e17948, 2011. [PMC free article: PMC3066220] [PubMed: 21479234]
  36. Schindler G, Capper D, Meyer J, et al.: Analysis of BRAF V600E mutation in 1,320 nervous system tumors reveals high mutation frequencies in pleomorphic xanthoastrocytoma, ganglioglioma and extra-cerebellar pilocytic astrocytoma. *Acta Neuropathol* 121 (3): 397-405, 2011. [PubMed: 21274720]
  37. Lassaletta A, Zapotocky M, Mistry M, et al.: Therapeutic and Prognostic Implications of BRAF V600E in



- Pediatric Low-Grade Gliomas. *J Clin Oncol* 35 (25): 2934-2941, 2017. [PMC free article: PMC5791837] [PubMed: 28727518]
38. Ho CY, Mobley BC, Gordish-Dressman H, et al.: A clinicopathologic study of diencephalic pediatric low-grade gliomas with BRAF V600 mutation. *Acta Neuropathol* 130 (4): 575-85, 2015. [PubMed: 26264609]
39. Jones DT, Hutter B, Jäger N, et al.: Recurrent somatic alterations of FGFR1 and NTRK2 in pilocytic astrocytoma. *Nat Genet* 45 (8): 927-32, 2013. [PMC free article: PMC3951336] [PubMed: 23817572]
40. Zhang J, Wu G, Miller CP, et al.: Whole-genome sequencing identifies genetic alterations in pediatric low-grade gliomas. *Nat Genet* 45 (6): 602-12, 2013. [PMC free article: PMC3727232] [PubMed: 23583981]
41. Ramkissoon LA, Horowitz PM, Craig JM, et al.: Genomic analysis of diffuse pediatric low-grade gliomas identifies recurrent oncogenic truncating rearrangements in the transcription factor MYBL1. *Proc Natl Acad Sci U S A* 110 (20): 8188-93, 2013. [PMC free article: PMC3657784] [PubMed: 23633565]
42. Bandopadhyay P, Ramkissoon LA, Jain P, et al.: MYB-QKI rearrangements in angiocentric glioma drive tumorigenicity through a tripartite mechanism. *Nat Genet* 48 (3): 273-82, 2016. [PMC free article: PMC4767685] [PubMed: 26829751]
43. Qaddoumi I, Orisme W, Wen J, et al.: Genetic alterations in uncommon low-grade neuroepithelial tumors: BRAF, FGFR1, and MYB mutations occur at high frequency and align with morphology. *Acta Neuropathol* 131 (6): 833-45, 2016. [PMC free article: PMC4866893] [PubMed: 26810070]
44. D'Aronco L, Rouleau C, Gayden T, et al.: Brainstem angiocentric gliomas with MYB-QKI rearrangements. *Acta Neuropathol* 134 (4): 667-669, 2017. [PMC free article: PMC6556888] [PubMed: 28803398]
45. Chan E, Bollen AW, Sirohi D, et al.: Angiocentric glioma with MYB-QKI fusion located in the brainstem, rather than cerebral cortex. *Acta Neuropathol* 134 (4): 671-673, 2017. [PMC free article: PMC5693679] [PubMed: 28776091]
46. Sturm D, Orr BA, Toprak UH, et al.: New Brain Tumor Entities Emerge from Molecular Classification of CNS-PNETs. *Cell* 164 (5): 1060-72, 2016. [PMC free article: PMC5139621] [PubMed: 26919435]
47. Lehman NL, Usualieva A, Lin T, et al.: Genomic analysis demonstrates that histologically-defined astroblastomas are molecularly heterogeneous and that tumors with MN1 rearrangement exhibit the most favorable prognosis. *Acta Neuropathol Commun* 7 (1): 42, 2019. [PMC free article: PMC6419470] [PubMed: 30876455]
48. Wood MD, Tihan T, Perry A, et al.: Multimodal molecular analysis of astroblastoma enables reclassification of most cases into more specific molecular entities. *Brain Pathol* 28 (2): 192-202, 2018. [PMC free article: PMC5843525] [PubMed: 28960623]
49. Hirose T, Nobusawa S, Sugiyama K, et al.: Astroblastoma: a distinct tumor entity characterized by alterations of the X chromosome and MN1 rearrangement. *Brain Pathol* 28 (5): 684-694, 2018. [PMC free article: PMC8028274] [PubMed: 28990708]
50. Lucas CG, Solomon DA, Perry A: A review of recently described genetic alterations in central nervous system tumors. *Hum Pathol* 96: 56-66, 2020. [PubMed: 31678207]
51. D'Angelo F, Ceccarelli M, Tala, et al.: The molecular landscape of glioma in patients with Neurofibromatosis 1. *Nat Med* 25 (1): 176-187, 2019. [PMC free article: PMC6857804] [PubMed: 30531922]
52. Franz DN, Belousova E, Sparagana S, et al.: Efficacy and safety of everolimus for subependymal giant cell astrocytomas associated with tuberous sclerosis complex (EXIST-1): a multicentre, randomised, placebo-controlled phase 3 trial. *Lancet* 381 (9861): 125-32, 2013. [PubMed: 23158522]
53. Paugh BS, Qu C, Jones C, et al.: Integrated molecular genetic profiling of pediatric high-grade gliomas reveals key differences with the adult disease. *J Clin Oncol* 28 (18): 3061-8, 2010. [PMC free article: PMC2903336] [PubMed: 20479398]
54. Bax DA, Mackay A, Little SE, et al.: A distinct spectrum of copy number aberrations in pediatric high-grade gliomas. *Clin Cancer Res* 16 (13): 3368-77, 2010. [PMC free article: PMC2896553] [PubMed: 20570930]
55. Ward SJ, Karakoula K, Phipps KP, et al.: Cytogenetic analysis of paediatric astrocytoma using comparative genomic hybridisation and fluorescence in-situ hybridisation. *J Neurooncol* 98 (3): 305-18, 2010. [PubMed:

20052518]

56. Pollack IF, Hamilton RL, Sobol RW, et al.: IDH1 mutations are common in malignant gliomas arising in adolescents: a report from the Children's Oncology Group. *Childs Nerv Syst* 27 (1): 87-94, 2011. [PMC free article: [PMC3014378](#)] [PubMed: 20725730]
57. Sturm D, Witt H, Hovestadt V, et al.: Hotspot mutations in H3F3A and IDH1 define distinct epigenetic and biological subgroups of glioblastoma. *Cancer Cell* 22 (4): 425-37, 2012. [PubMed: 23079654]
58. Korshunov A, Ryzhova M, Hovestadt V, et al.: Integrated analysis of pediatric glioblastoma reveals a subset of biologically favorable tumors with associated molecular prognostic markers. *Acta Neuropathol* 129 (5): 669-78, 2015. [PubMed: 25752754]
59. Mackay A, Burford A, Carvalho D, et al.: Integrated Molecular Meta-Analysis of 1,000 Pediatric High-Grade and Diffuse Intrinsic Pontine Glioma. *Cancer Cell* 32 (4): 520-537.e5, 2017. [PMC free article: [PMC5637314](#)] [PubMed: 28966033]
60. Rodriguez Gutierrez D, Jones C, Varlet P, et al.: Radiological Evaluation of Newly Diagnosed Non-Brainstem Pediatric High-Grade Glioma in the HERBY Phase II Trial. *Clin Cancer Res* 26 (8): 1856-1865, 2020. [PubMed: 31924736]
61. Buczkowicz P, Hoeman C, Rakopoulos P, et al.: Genomic analysis of diffuse intrinsic pontine gliomas identifies three molecular subgroups and recurrent activating ACVR1 mutations. *Nat Genet* 46 (5): 451-6, 2014. [PMC free article: [PMC3997489](#)] [PubMed: 24705254]
62. Taylor KR, Mackay A, Truffaux N, et al.: Recurrent activating ACVR1 mutations in diffuse intrinsic pontine glioma. *Nat Genet* 46 (5): 457-61, 2014. [PMC free article: [PMC4018681](#)] [PubMed: 24705252]
63. Chen CCL, Deshmukh S, Jessa S, et al.: Histone H3.3G34-Mutant Interneuron Progenitors Co-opt PDGFRA for Gliomagenesis. *Cell* 183 (6): 1617-1633.e22, 2020. [PMC free article: [PMC7791404](#)] [PubMed: 33259802]
64. Mackay A, Burford A, Molinari V, et al.: Molecular, Pathological, Radiological, and Immune Profiling of Non-brainstem Pediatric High-Grade Glioma from the HERBY Phase II Randomized Trial. *Cancer Cell* 33 (5): 829-842.e5, 2018. [PMC free article: [PMC5956280](#)] [PubMed: 29763623]
65. Korshunov A, Schrimpf D, Ryzhova M, et al.: H3-/IDH-wild type pediatric glioblastoma is comprised of molecularly and prognostically distinct subtypes with associated oncogenic drivers. *Acta Neuropathol* 134 (3): 507-516, 2017. [PubMed: 28401334]
66. Guerreiro Stucklin AS, Ryall S, Fukuoka K, et al.: Alterations in ALK/ROS1/NTRK/MET drive a group of infantile hemispheric gliomas. *Nat Commun* 10 (1): 4343, 2019. [PMC free article: [PMC6761184](#)] [PubMed: 31554817]
67. Clarke M, Mackay A, Ismer B, et al.: Infant High-Grade Gliomas Comprise Multiple Subgroups Characterized by Novel Targetable Gene Fusions and Favorable Outcomes. *Cancer Discov* 10 (7): 942-963, 2020. [PMC free article: [PMC8313225](#)] [PubMed: 32238360]
68. Blumcke I, Spreafico R, Haaker G, et al.: Histopathological Findings in Brain Tissue Obtained during Epilepsy Surgery. *N Engl J Med* 377 (17): 1648-1656, 2017. [PubMed: 29069555]
69. Stone TJ, Keeley A, Virasami A, et al.: Comprehensive molecular characterisation of epilepsy-associated glioneuronal tumours. *Acta Neuropathol* 135 (1): 115-129, 2018. [PMC free article: [PMC5756244](#)] [PubMed: 29058119]
70. Rivera B, Gayden T, Carrot-Zhang J, et al.: Germline and somatic FGFR1 abnormalities in dysembryoplastic neuroepithelial tumors. *Acta Neuropathol* 131 (6): 847-63, 2016. [PMC free article: [PMC5039033](#)] [PubMed: 26920151]
71. Matsumura N, Nobusawa S, Ito J, et al.: Multiplex ligation-dependent probe amplification analysis is useful for detecting a copy number gain of the FGFR1 tyrosine kinase domain in dysembryoplastic neuroepithelial tumors. *J Neurooncol* 143 (1): 27-33, 2019. [PubMed: 30825062]
72. Baisden BL, Brat DJ, Melhem ER, et al.: Dysembryoplastic neuroepithelial tumor-like neoplasm of the septum pellucidum: a lesion often misdiagnosed as glioma: report of 10 cases. *Am J Surg Pathol* 25 (4): 494-9, 2001. [PubMed: 11257624]

73. Gessi M, Hattingen E, Dörner E, et al.: Dysembryoplastic Neuroepithelial Tumor of the Septum Pellucidum and the Supratentorial Midline: Histopathologic, Neuroradiologic, and Molecular Features of 7 Cases. *Am J Surg Pathol* 40 (6): 806-11, 2016. [PubMed: 26796505]
74. Chiang JCH, Harreld JH, Tanaka R, et al.: Septal dysembryoplastic neuroepithelial tumor: a comprehensive clinical, imaging, histopathologic, and molecular analysis. *Neuro Oncol* 21 (6): 800-808, 2019. [PMC free article: PMC6556860] [PubMed: 30726976]
75. Solomon DA, Korshunov A, Sill M, et al.: Myxoid glioneuronal tumor of the septum pellucidum and lateral ventricle is defined by a recurrent PDGFRA p.K385 mutation and DNT-like methylation profile. *Acta Neuropathol* 136 (2): 339-343, 2018. [PMC free article: PMC7787982] [PubMed: 30006677]
76. Lucas CG, Villanueva-Meyer JE, Whipple N, et al.: Myxoid glioneuronal tumor, PDGFRA p.K385-mutant: clinical, radiologic, and histopathologic features. *Brain Pathol* 30 (3): 479-494, 2020. [PMC free article: PMC7780370] [PubMed: 31609499]
77. Becker AJ: Ganglioglioma. In: Louis DN, Ohgaki H, Wiestler OD: WHO Classification of Tumours of the Central Nervous System. 4th rev.ed. IARC Press, 2016, pp 138-41.
78. Pekmezci M, Villanueva-Meyer JE, Goode B, et al.: The genetic landscape of ganglioglioma. *Acta Neuropathol Commun* 6 (1): 47, 2018. [PMC free article: PMC5992851] [PubMed: 29880043]
79. Bianchi F, Tamburrini G, Massimi L, et al.: Supratentorial tumors typical of the infantile age: desmoplastic infantile ganglioglioma (DIG) and astrocytoma (DIA). A review. *Childs Nerv Syst* 32 (10): 1833-8, 2016. [PubMed: 27659826]
80. Trehan G, Bruge H, Vinchon M, et al.: MR imaging in the diagnosis of desmoplastic infantile tumor: retrospective study of six cases. *AJNR Am J Neuroradiol* 25 (6): 1028-33, 2004 Jun-Jul. [PMC free article: PMC7975656] [PubMed: 15205142]
81. Wang AC, Jones DTW, Abecassis IJ, et al.: Desmoplastic Infantile Ganglioglioma/Astrocytoma (DIG/DIA) Are Distinct Entities with Frequent BRAFV600 Mutations. *Mol Cancer Res* 16 (10): 1491-1498, 2018. [PMC free article: PMC7269191] [PubMed: 30006355]
82. Blessing MM, Blackburn PR, Krishnan C, et al.: Desmoplastic Infantile Ganglioglioma: A MAPK Pathway-Driven and Microglia/Macrophage-Rich Neuroepithelial Tumor. *J Neuropathol Exp Neurol* 78 (11): 1011-1021, 2019. [PubMed: 31562743]
83. Greer A, Foreman NK, Donson A, et al.: Desmoplastic infantile astrocytoma/ganglioglioma with rare BRAF V600D mutation. *Pediatr Blood Cancer* 64 (6): , 2017. [PMC free article: PMC5589269] [PubMed: 27860162]
84. Pages M, Lacroix L, Tauziède-Espariat A, et al.: Papillary glioneuronal tumors: histological and molecular characteristics and diagnostic value of SLC44A1-PRKCA fusion. *Acta Neuropathol Commun* 3: 85, 2015. [PMC free article: PMC4681033] [PubMed: 26671581]
85. Bridge JA, Liu XQ, Sumegi J, et al.: Identification of a novel, recurrent SLC44A1-PRKCA fusion in papillary glioneuronal tumor. *Brain Pathol* 23 (2): 121-8, 2013. [PMC free article: PMC8029478] [PubMed: 22725730]
86. Hou Y, Pinheiro J, Sahm F, et al.: Papillary glioneuronal tumor (PGNT) exhibits a characteristic methylation profile and fusions involving PRKCA. *Acta Neuropathol* 137 (5): 837-846, 2019. [PubMed: 30759284]
87. Sievers P, Appay R, Schrimpf D, et al.: Rosette-forming glioneuronal tumors share a distinct DNA methylation profile and mutations in FGFR1, with recurrent co-mutation of PIK3CA and NF1. *Acta Neuropathol* 138 (3): 497-504, 2019. [PubMed: 31250151]
88. Deng MY, Sill M, Chiang J, et al.: Molecularly defined diffuse leptomeningeal glioneuronal tumor (DLGNT) comprises two subgroups with distinct clinical and genetic features. *Acta Neuropathol* 136 (2): 239-253, 2018. [PubMed: 29766299]
89. Chiang JCH, Harreld JH, Orr BA, et al.: Low-grade spinal glioneuronal tumors with BRAF gene fusion and 1p deletion but without leptomeningeal dissemination. *Acta Neuropathol* 134 (1): 159-162, 2017. [PMC free article: PMC5848506] [PubMed: 28547128]
90. Chiang J, Dalton J, Upadhyaya SA, et al.: Chromosome arm 1q gain is an adverse prognostic factor in localized and diffuse leptomeningeal glioneuronal tumors with BRAF gene fusion and 1p deletion. *Acta Neuropathol* 137

- (1): 179-181, 2019. [PubMed: 30465258]
91. Sievers P, Stichel D, Schrimpf D, et al.: FGFR1:TACC1 fusion is a frequent event in molecularly defined extraventricular neurocytoma. *Acta Neuropathol* 136 (2): 293-302, 2018. [PubMed: 29978331]
  92. Fisher PG, Tihan T, Goldthwaite PT, et al.: Outcome analysis of childhood low-grade astrocytomas. *Pediatr Blood Cancer* 51 (2): 245-50, 2008. [PubMed: 18386785]
  93. Qaddoumi I, Sultan I, Gajjar A: Outcome and prognostic features in pediatric gliomas: a review of 6212 cases from the Surveillance, Epidemiology, and End Results database. *Cancer* 115 (24): 5761-70, 2009. [PMC free article: PMC2794938] [PubMed: 19813274]
  94. Wisoff JH, Sanford RA, Heier LA, et al.: Primary neurosurgery for pediatric low-grade gliomas: a prospective multi-institutional study from the Children's Oncology Group. *Neurosurgery* 68 (6): 1548-54; discussion 1554-5, 2011. [PubMed: 21368693]
  95. Bandopadhyay P, Berghold G, London WB, et al.: Long-term outcome of 4,040 children diagnosed with pediatric low-grade gliomas: an analysis of the Surveillance Epidemiology and End Results (SEER) database. *Pediatr Blood Cancer* 61 (7): 1173-9, 2014. [PMC free article: PMC4657506] [PubMed: 24482038]
  96. von Hornstein S, Kortmann RD, Pietsch T, et al.: Impact of chemotherapy on disseminated low-grade glioma in children and adolescents: report from the HIT-LGG 1996 trial. *Pediatr Blood Cancer* 56 (7): 1046-54, 2011. [PubMed: 21319282]
  97. Mazloom A, Hodges JC, Teh BS, et al.: Outcome of patients with pilocytic astrocytoma and leptomeningeal dissemination. *Int J Radiat Oncol Biol Phys* 84 (2): 350-4, 2012. [PubMed: 22401918]
  98. Stokland T, Liu JF, Ironside JW, et al.: A multivariate analysis of factors determining tumor progression in childhood low-grade glioma: a population-based cohort study (CCLG CNS9702). *Neuro Oncol* 12 (12): 1257-68, 2010. [PMC free article: PMC3018938] [PubMed: 20861086]
  99. Mirow C, Pietsch T, Berkefeld S, et al.: Children <1 year show an inferior outcome when treated according to the traditional LGG treatment strategy: a report from the German multicenter trial HIT-LGG 1996 for children with low grade glioma (LGG). *Pediatr Blood Cancer* 61 (3): 457-63, 2014. [PubMed: 24039013]
  100. Rakotonjanahary J, De Carli E, Delion M, et al.: Mortality in Children with Optic Pathway Glioma Treated with Up-Front BB-SFOP Chemotherapy. *PLoS One* 10 (6): e0127676, 2015. [PMC free article: PMC4476571] [PubMed: 26098902]
  101. Gnekow AK, Walker DA, Kandels D, et al.: A European randomised controlled trial of the addition of etoposide to standard vincristine and carboplatin induction as part of an 18-month treatment programme for childhood ( $\leq 16$  years) low grade glioma - A final report. *Eur J Cancer* 81: 206-225, 2017. [PMC free article: PMC5517338] [PubMed: 28649001]
  102. Chamdine O, Broniscer A, Wu S, et al.: Metastatic Low-Grade Gliomas in Children: 20 Years' Experience at St. Jude Children's Research Hospital. *Pediatr Blood Cancer* 63 (1): 62-70, 2016. [PMC free article: PMC5122937] [PubMed: 26312767]
  103. Due-Tønnessen BJ, Helseth E, Scheie D, et al.: Long-term outcome after resection of benign cerebellar astrocytomas in children and young adults (0-19 years): report of 110 consecutive cases. *Pediatr Neurosurg* 37 (2): 71-80, 2002. [PubMed: 12145515]
  104. Massimi L, Tufo T, Di Rocco C: Management of optic-hypothalamic gliomas in children: still a challenging problem. *Expert Rev Anticancer Ther* 7 (11): 1591-610, 2007. [PubMed: 18020927]
  105. Campagna M, Opocher E, Viscardi E, et al.: Optic pathway glioma: long-term visual outcome in children without neurofibromatosis type-1. *Pediatr Blood Cancer* 55 (6): 1083-8, 2010. [PubMed: 20979170]
  106. Hernáiz Driever P, von Hornstein S, Pietsch T, et al.: Natural history and management of low-grade glioma in NF-1 children. *J Neurooncol* 100 (2): 199-207, 2010. [PubMed: 20352473]
  107. Falzon K, Drimtzias E, Picton S, et al.: Visual outcomes after chemotherapy for optic pathway glioma in children with and without neurofibromatosis type 1: results of the International Society of Paediatric Oncology (SIOP) Low-Grade Glioma 2004 trial UK cohort. *Br J Ophthalmol* 102 (10): 1367-1371, 2018. [PubMed: 29343527]

108. Finlay JL, Boyett JM, Yates AJ, et al.: Randomized phase III trial in childhood high-grade astrocytoma comparing vincristine, lomustine, and prednisone with the eight-drugs-in-1-day regimen. *Childrens Cancer Group. J Clin Oncol* 13 (1): 112-23, 1995. [PubMed: 7799011]
109. Villano JL, Seery TE, Bressler LR: Temozolomide in malignant gliomas: current use and future targets. *Cancer Chemother Pharmacol* 64 (4): 647-55, 2009. [PubMed: 19543728]
110. Karremann M, Gielen GH, Hoffmann M, et al.: Diffuse high-grade gliomas with H3 K27M mutations carry a dismal prognosis independent of tumor location. *Neuro Oncol* 20 (1): 123-131, 2018. [PMC free article: PMC5761525] [PubMed: 29016894]

## Stage Information for Childhood Astrocytomas

There is no recognized staging system for childhood astrocytomas. For the purposes of this summary, the treatment of childhood astrocytomas will be described using the following classifications:

- Low-grade astrocytoma—grades I and II (e.g., pilocytic astrocytomas and diffuse astrocytomas).
  - Newly diagnosed.
  - Progressive/recurrent.
- High-grade astrocytoma—grades III and IV (anaplastic astrocytomas and glioblastoma).
  - Newly diagnosed.
  - Recurrent.

## Treatment Option Overview for Childhood Astrocytomas

Dramatic improvements in survival have been achieved for children and adolescents with cancer. Between 1975 and 2010, childhood cancer mortality decreased by more than 50%.<sup>[1]</sup> Many of the improvements in survival in childhood cancer have been made as a result of clinical trials that have attempted to improve on the best available, accepted therapy. Clinical trials in pediatrics are designed to compare new therapy with therapy that is currently accepted as standard. This comparison may be done in a randomized study of two treatment arms or by evaluating a single new treatment and comparing the results with previously obtained results that assessed an existing therapy. Because of the relative rarity of cancer in children, all patients with brain tumors should be considered for entry into a clinical trial. Information about ongoing National Cancer Institute (NCI)–supported clinical trials is available from the [NCI website](#).

To determine and implement optimal treatment, planning by a multidisciplinary team of cancer specialists who have experience treating childhood brain tumors is required. Irradiation of pediatric brain tumors is technically very demanding and should be carried out in centers that have experience in that area to ensure optimal results.

Long-term management of patients with brain tumors is complex and requires a multidisciplinary approach. (Refer to the PDQ summary on [Late Effects of Treatment for Childhood Cancer](#) for specific information about the incidence, type, and monitoring of late effects in childhood and adolescent cancer survivors.)

[Table 4](#) describes the standard treatment options for low-grade and high-grade childhood astrocytomas.

**Table 4. Standard Treatment Options for Childhood Astrocytomas**

Treatment Group	Standard Treatment Options
<b>Childhood low-grade astrocytomas:</b>	
Newly diagnosed childhood low-grade	Observation without intervention

Treatment Group	Standard Treatment Options
astrocytomas	<a href="#">Surgery</a>
	Adjuvant therapy (for tumors that are incompletely resected):
	— <a href="#">Observation after surgery</a>
	— <a href="#">Chemotherapy</a>
	— <a href="#">Radiation therapy</a>
	— <a href="#">Targeted therapy</a>
Progressive/recurrent childhood low-grade astrocytomas	<a href="#">Second surgery</a>
	<a href="#">Radiation therapy</a>
	<a href="#">Chemotherapy</a>
	<a href="#">Targeted therapy with or without chemotherapy</a>
	<a href="#">Other targeted therapies</a>
<b>Childhood high-grade astrocytomas:</b>	
Newly diagnosed childhood high-grade astrocytomas	<a href="#">Surgery</a>
	Adjuvant therapy:
	— <a href="#">Radiation therapy</a>
	— <a href="#">Chemotherapy</a>
Recurrent childhood high-grade astrocytomas	<a href="#">Surgery (not considered standard treatment)</a>
	<a href="#">High-dose chemotherapy with stem cell transplant (SCT) (not considered standard treatment)</a>
	<a href="#">Radiation therapy (not considered standard treatment)</a>
	<a href="#">Targeted therapy with a BRAF inhibitor, for patients with a <i>BRAF</i> V600E mutation (not considered standard treatment)</a>
	<a href="#">Immunotherapy (not considered standard treatment)</a>

## References

- Smith MA, Altekrose SF, Adamson PC, et al.: Declining childhood and adolescent cancer mortality. *Cancer* 120 (16): 2497-506, 2014. [PMC free article: [PMC4136455](#)] [PubMed: [24853691](#)]

## Treatment of Childhood Low-Grade Astrocytomas

To determine and implement optimal management, treatment is often guided by a multidisciplinary team of cancer specialists who have experience treating childhood brain tumors.

For children with low-grade optic pathway astrocytomas, treatment options should be considered not only to improve survival but also to stabilize visual function.[1,2]

Standard treatment options for newly diagnosed childhood low-grade astrocytomas include the following:

- [Observation without intervention.](#)
- [Surgery.](#)

### 3. Adjuvant therapy (for tumors that are incompletely resected).

- Observation after surgery.
- Chemotherapy.
- Radiation therapy.
- Targeted therapy.

## Observation without Intervention

Observation, in the absence of any intervention, is an option for patients with neurofibromatosis type 1 (NF1) or incidentally found, asymptomatic masses.[3] Spontaneous regressions of optic pathway gliomas have been reported in children with and without NF1.[4,5]

## Surgery

Surgical resection is the primary treatment for childhood low-grade astrocytoma [6,7] and surgical feasibility is determined by tumor location. In infants and young children, low-grade astrocytomas presenting in the optic chiasm/hypothalamus make surgery difficult; consequently, biopsies are not always done. This is especially true in patients with NF1.[6] When tumors are associated with NF1, they may be of multifocal origin.

- **Cerebellum:** Complete or near-complete removal can be obtained in 90% to 95% of patients with pilocytic tumors that occur in the cerebellum.[7]
- **Optic nerve:** For children with isolated optic nerve lesions and progressive symptoms, complete surgical resection, while curative, generally results in blindness in the affected eye. In the absence of retained vision in the affected eye, complete surgical resection may be considered when cosmesis related to proptosis is of concern.
- **Midline structures (hypothalamus, thalamus, and brain stem):** Low-grade astrocytomas that occur in midline structures can sometimes be aggressively resected, with resultant long-term disease control.[4,8,9]; [10][Level of evidence: 3iiiA] Despite the increasing surgical accessibility of these tumors, such resection may result in significant neurologic sequelae, especially in children younger than 2 years at diagnosis.[11][Level of evidence: 3iC] Because of the infiltrative nature of some deep-seated lesions, extensive surgical resection may not be appropriate and biopsy only should be considered.[12][Level of evidence: 3iiiDiii]
- **Cerebrum:** Circumscribed, grade I hemispheric tumors are often amenable to complete surgical resection.
- **Spine:** Surgical resection for spinal tumors is generally attempted but it often cannot be completed. In a cohort of 128 patients with primary spinal cord low-grade gliomas, gross-total resection was achieved in a minority of the patients (24 of 128). For the entire cohort, long-term disease control was achieved in about 87% of patients, but subsequent treatment in the form of repeat resection, chemotherapy, and/or radiation therapy was frequently required. Notably, disease progression was common (51 of 128 patients), with late-progression events occurring often. Neurological sequelae and orthopedic complications were common.[13][Level of evidence: 3iiiDi]

After resection, immediate (within 48 hours of resection per Children's Oncology Group [COG] criteria) postoperative magnetic resonance imaging is obtained. Surveillance scans are then obtained periodically for completely resected tumors, although the value following the initial 3- to 6-month postoperative period is uncertain.[14]; [15][Level of evidence: 3iiDiii]

Factors related to outcome for children with low-grade gliomas treated with surgery followed by observation were identified in a COG study that included 518 evaluable patients.[7] Overall outcome for the entire group was a 78% progression-free survival (PFS) rate at 8 years and 96% overall survival (OS) rate at 8 years. The following factors

were related to prognosis:[7]

- **Tumor location:** Children with cerebellar and cerebral tumors showed a higher PFS rate at 8 years compared with patients with midline and chiasmatic tumors ( $84\% \pm 1.9\%$  vs.  $51\% \pm 5.9\%$ , respectively).
- **Histology:** Approximately three-fourths of patients had pilocytic astrocytoma; PFS and OS were superior for these patients when compared with children with nonpilocytic tumors.
- **Extent of resection:** Patients with gross-total resection had 8-year PFS rates exceeding 90% and OS rates of 99%. By comparison, approximately one-half of patients with any degree of residual tumor (as assessed by operative report and by postoperative imaging) showed disease progression by 8 years, although OS rates exceeded 90%.[7]

The extent of resection necessary for cure is unknown because patients with microscopic and even gross residual tumor after surgery may experience long-term PFS without postoperative therapy.[6,7]

- **Age:** Younger children (age <5 years) showed higher rates of tumor progression but there was no significant age effect for OS in multivariate analysis. In a retrospective review of a different series of pediatric patients, children younger than 1 year with low-grade glioma demonstrated an inferior PFS compared with children aged 1 year and older.[16]

A multivariate analysis examined 100 patients with confirmed diagnoses of World Health Organization (WHO) grade II diffuse gliomas treated in an International Society of Paediatric Oncology (SIOP) study. The extent of glioma resection had the greatest impact on patients' event-free survival (EFS) rates. The 5-year EFS rates were 75% to 76% for patients who underwent a complete or subtotal resection. In comparison, 5-year EFS rates were 56% for patients who had a partial resection and 19% for patients who had a biopsy.[17][Level of evidence: 2Di]

The long-term functional outcome of cerebellar pilocytic astrocytomas is relatively favorable. Full-scale mean intelligence quotients (IQs) of patients with low-grade gliomas treated with surgery alone are close to the normative population. However, long-term medical, psychological, and educational deficits may be present in these patients.[18]; [19,20][Level of evidence: 3iiiC]

## Adjuvant Therapy

Adjuvant therapy following complete resection of a low-grade glioma is generally not required unless there is a subsequent recurrence of disease. Treatment options for patients with incompletely resected tumor must be individualized and may include one or more of the following:

- Observation after surgery.
- Chemotherapy.
- Radiation therapy.
- Targeted therapy (for subependymal giant cell astrocytomas).

A shunt or other cerebrospinal fluid diversion procedure may be needed.

## Observation after surgery

In patients in whom a portion of the tumor has been resected, the patient may be observed without further disease-directed treatment, particularly if the pace of tumor regrowth is anticipated to be very slow. Approximately 50% of patients with less-than-gross total resection may have disease that remains progression-free at 5 to 8 years, supporting the observation strategy in selected patients.[7]



## Chemotherapy

Given the long-term side effects associated with radiation therapy, postoperative chemotherapy may be initially recommended.

Chemotherapy may result in objective tumor shrinkage and delay the need for radiation therapy in most patients. [21-24] Chemotherapy is also an option that may delay or avoid radiation therapy in adolescents with optic nerve pathway gliomas. [25] [Level of evidence: 3iiDii] Chemotherapy has been shown to shrink tumors in children with hypothalamic gliomas and the diencephalic syndrome, resulting in weight gain in those who respond to treatment. [26]

The most widely used regimens to treat tumor progression or symptomatic nonresectable, low-grade gliomas are the following:

- Carboplatin with or without vincristine. [21,22,27]; [28] [Level of evidence: 3iiiDiii]
- Combination of thioguanine, procarbazine, lomustine, and vincristine (TPCV). [24]; [29] [Level of evidence: 1iiA]

The COG reported the results of a randomized phase III trial (COG-A9952) that treated children younger than 10 years with low-grade chiasmatic/hypothalamic gliomas without NF1 using one of two regimens: carboplatin and vincristine (CV) or TPCV. The 5-year EFS rate was 39% ( $\pm$  4%) for the CV regimen and 52% ( $\pm$  5%) for the TPCV regimen. Toxicity rates between the two regimens were relatively comparable. [29] In the same study, children with NF1 were nonrandomly assigned to receive treatment with CV. The 5-year EFS rate for children with NF1 was markedly better, at 69% ( $\pm$  4%), than it was for children without NF1 who received CV. In multivariate analysis, NF1 was an independent predictor of better EFS but not OS. [30] In a separate study that included 100 patients with WHO grade II diffuse gliomas, a subset of patients (n = 16) were treated with carboplatin and vincristine; some patients also received etoposide. This subset of patients had a 5-year PFS rate of 38% when patients with *Histone3*-mutated tumors were excluded. [17] [Level of evidence: 2Di]

A multicenter, prospective, randomized trial that compared treatment with vincristine/carboplatin with vincristine/carboplatin plus etoposide in children with low-grade glioma failed to demonstrate a difference in PFS and OS between the two regimens. [31] [Level of evidence: 1iiD]

Other chemotherapy approaches have been employed to treat children with progressive or symptomatic nonresectable, low-grade astrocytomas, including the following:

- Multiagent, platinum-based regimens. [22,23,32]; [33] [Level of evidence: 2Diii]; [34] [Level of evidence: 3iiiB] Reported 5-year PFS rates have ranged from approximately 35% to 60% for children receiving platinum-based chemotherapy for optic pathway gliomas, [22,23] but most patients ultimately require further treatment. This is particularly true for children who initially present with hypothalamic/chiasmatic gliomas that have neuraxis dissemination. [35] [Level of evidence: 3iiiDiii]
- Vinblastine. [36,37]
- Temozolomide. [38,39]

Among children receiving chemotherapy for optic pathway gliomas, those without NF1 have higher rates of disease progression than those with NF1, and infants have higher rates of disease progression than do children older than 1 year. [22,23,32,37] Visual status (including acuity and field) is an important measure of outcome and response to treatment. Vision function can be impaired; it is variable even in patients with radiographic responses and is often less than optimal. More than one-third of patients *successfully* treated with chemotherapy have poor vision in one or both eyes, and some patients lose vision despite radiographic evidence of tumor control (response or stability). In most series, children with sporadic visual pathway gliomas have poorer visual outcomes than do children with NF1. [37];

[40,41][Level of evidence: 3iiiC] Better initial visual acuity, older age, and absence of postchiasmatic involvement are associated with improved or stable vision after chemotherapy.[42,43]

## Radiation therapy

Radiation therapy is usually reserved until progressive disease is documented [44,45] and may be further delayed through the use of chemotherapy.[21,22]

For children with low-grade gliomas for whom radiation therapy is indicated, approaches that contour the radiation distribution to the tumor and avoid normal brain tissue (3-D conformal radiation therapy, intensity-modulated radiation therapy (IMRT), stereotactic radiation therapy, and proton radiation therapy [charged-particle radiation therapy]) all appear effective and may potentially reduce the acute and long-term toxicities associated with these modalities.

[46,47]; [48][Level of evidence: 3iDiii] Radiation doses of 54 Gy in 1.8 Gy fractions are typically used.[49,50] In a prospective study of 174 patients treated with proton therapy, the 5-year actuarial rate of local control was 85% (95% confidence interval [CI], 78%–90%), the PFS rate was 84% (95% CI, 77%–89%), and the OS rate was 92% (95% CI, 85%–95%). Brain stem and spinal cord tumor locations and a dose of 54 Gy relative biological effectiveness (RBE) or less were associated with inferior local control ( $P < .01$  for both).[51] In a separate study that included 100 patients with WHO grade II diffuse gliomas, a subset of patients ( $n = 16$ ) were treated with radiation therapy. These patients had a 5-year PFS rate of 74% when patients with *Histone3*-mutated tumors were excluded.[17][Level of evidence: 2Di]

Subsequent to radiation therapy administration, care must be taken to distinguish radiation-induced imaging changes, termed *pseudoprogression* or *spurious progression*,[52] from disease progression. The peak time to radiation therapy–induced imaging changes, often presenting as an apparent enlargement of the irradiated mass, is 4 to 6 months, but they can manifest even later.[53–56]; [57][Level of evidence: 2A]; [58][Level of evidence: 2C]; [59][Level of evidence: 3iiiDi]; [60][Level of evidence: 3iiiDii]; [12,61][Level of evidence: 3iiiDiii] In a report of 83 patients with low-grade astrocytomas, pseudoprogression was more common after radiation doses of higher than 50.4 Gy (RBE) (hazard ratio [HR], 2.61;  $P = .16$ ). Pseudoprogression was also more common after proton radiation therapy than after photon IMRT (HR, 2.15;  $P = .048$ ), presumably because of increased effects on the vasculature. Patients with pilocytic histology had lower rates of pseudoprogression than those with nonpilocytic low-grade gliomas (HR, 0.47;  $P = .037$ ). There was no association with overall disease control.[52]

Radiation therapy results in long-term radiographic disease control for most children with chiasmatic and posterior pathway chiasmatic gliomas; however, despite radiographic control, visual outcomes are variable.

- A study from St. Jude Children’s Research Hospital reported on long-term visual acuity outcomes after radiation therapy. For the worse eye, the 5-year cumulative incidence of visual acuity decline was 17.9% and improvement was 13.5%. For the better eye, the 5-year cumulative incidence of visual acuity decline was 11.5% and improvement was 10.6%. After radiation therapy, most patients had stabilization of their vision. Visual change after radiation therapy was most likely to occur within 2 years, supporting the importance of visual assessments during this period.[62]
- Another study of 38 patients (mean age, 3 years; median follow-up, 8.5 years) with optic pathway gliomas treated between 2000 and 2018 complemented the previous data on preservation of long-term visual acuity. For patients treated with early radiation therapy (either up-front or as first salvage), blindness-free survival rates were 100% at 5 and 8 years. In comparison, blindness-free survival rates were 81% at 5 years and 60% at 8 years for patients treated primarily with chemotherapy.[63]
- Other sequelae include intellectual and endocrinologic deterioration, cerebrovascular damage, late death, and possibly an increased risk of secondary tumors.[64–66]; [58][Level of evidence: 2C] A population-based study identified radiation therapy as the most significant risk factor associated with late mortality, although the patients who required radiation therapy may have reflected a higher-risk population.[66]

Because the management of unresectable low-grade gliomas and glioneuronal tumors is controversial, the St. Jude Children's Research Hospital assessed negative prognostic factors in 150 children (median age, 8 years; range, 1.2–20 years) who were treated with radiation therapy and followed for a median of 11.4 years (range, 0.24–29.4 years). Recursive positioning analysis yielded low-risk and high-risk prognostic groups, with a 10-year OS rate of 95.6% (low-risk group) versus 76.4% (high-risk group). Low-risk tumors included pilocytic astrocytoma/ganglioglioma located outside of the midbrain/thalamus, while high-risk tumors included diffuse astrocytoma or those located in the midbrain/thalamus. Within the high-risk group of patients, delayed radiation therapy (defined as after at least one line of chemotherapy) was associated with a decrement in OS.[67]

Children with NF1 may be at higher risk of radiation-associated secondary tumors and morbidity resulting from vascular changes. Radiation therapy and alkylating agents are used as last resorts for these patients, given the theoretically heightened risk of inducing neurologic toxic effects and second malignancy.[68]

### Targeted therapy

For children with symptomatic subependymal giant cell astrocytomas (SEGAs), agents that inhibit mammalian target of rapamycin (mTOR) (e.g., everolimus and sirolimus) have been studied.

Evidence (treatment of SEGA with an mTOR inhibitor):

1. Small series have shown significant reductions in the size of these tumors after administration of everolimus or sirolimus, often eliminating the need for surgery.[69]; [70][Level of evidence: 2C]; [71][Level of evidence: 3iiDiv]; [72][Level of evidence: 3iiiC]
2. A multicenter, phase III, placebo-controlled trial of 117 patients confirmed these earlier findings.[73][Level of evidence: 1iDiv]
  - 35% of the patients in the everolimus group had at least a 50% reduction in the size of the SEGA, versus no reduction in the placebo group.
3. In a study of patients who were treated with everolimus for 5 years, the following results were observed:[74]
  - A reduction in the size of the mass was observed in about 50% of patients; in many cases, the reduction was sustained.
  - These patients also had a reduction in seizure frequency.

### Treatment Options Under Clinical Evaluation

Early-phase therapeutic trials may be available for selected patients. These trials may be available via the [COG](#), the [Pediatric Brain Tumor Consortium](#), or other entities. Information about National Cancer Institute (NCI)-supported clinical trials can be found on the [NCI website](#). For information about clinical trials sponsored by other organizations, refer to the [ClinicalTrials.gov website](#).

The following are examples of national and/or institutional clinical trials that are currently being conducted:

- **ACNS1831 (NCT03871257)** (A Study of the Drugs Selumetinib Versus Carboplatin/Vincristine in Patients With NF1 and Low-Grade Glioma): This phase III trial investigates the use of selumetinib compared with the standard treatment of CV for treating patients with NF1-associated low-grade gliomas, and improving vision in patients with low-grade gliomas of the optic pathway (vision nerves).
- **ACNS1833 (NCT04166409)** (A Study of the Drugs Selumetinib Versus Carboplatin and Vincristine in Patients With Low-Grade Glioma): This phase III trial compares the effect of selumetinib with the standard of care treatment using carboplatin and vincristine in treating patients with newly diagnosed or previously untreated low-grade glioma that does not have a *BRAF* V600E mutation and is not associated with systemic NF1.

## Current Clinical Trials

Use our advanced [clinical trial search](#) to find NCI-supported cancer clinical trials that are now enrolling patients. The search can be narrowed by location of the trial, type of treatment, name of the drug, and other criteria. [General information](#) about clinical trials is also available.

## References

1. Nicolin G, Parkin P, Mabbott D, et al.: Natural history and outcome of optic pathway gliomas in children. *Pediatr Blood Cancer* 53 (7): 1231-7, 2009. [PubMed: 19621457]
2. Kramm CM, Butenhoff S, Rausche U, et al.: Thalamic high-grade gliomas in children: a distinct clinical subset? *Neuro Oncol* 13 (6): 680-9, 2011. [PMC free article: PMC3107103] [PubMed: 21636712]
3. Listernick R, Ferner RE, Liu GT, et al.: Optic pathway gliomas in neurofibromatosis-1: controversies and recommendations. *Ann Neurol* 61 (3): 189-98, 2007. [PMC free article: PMC5908242] [PubMed: 17387725]
4. Albright AL: Feasibility and advisability of resections of thalamic tumors in pediatric patients. *J Neurosurg* 100 (5 Suppl Pediatrics): 468-72, 2004. [PubMed: 15287457]
5. Piccirilli M, Lenzi J, Delfinis C, et al.: Spontaneous regression of optic pathways gliomas in three patients with neurofibromatosis type I and critical review of the literature. *Childs Nerv Syst* 22 (10): 1332-7, 2006. [PubMed: 16639629]
6. Due-Tønnessen BJ, Helseth E, Scheie D, et al.: Long-term outcome after resection of benign cerebellar astrocytomas in children and young adults (0-19 years): report of 110 consecutive cases. *Pediatr Neurosurg* 37 (2): 71-80, 2002. [PubMed: 12145515]
7. Wisoff JH, Sanford RA, Heier LA, et al.: Primary neurosurgery for pediatric low-grade gliomas: a prospective multi-institutional study from the Children's Oncology Group. *Neurosurgery* 68 (6): 1548-54; discussion 1554-5, 2011. [PubMed: 21368693]
8. Tseng JH, Tseng MY: Survival analysis of 81 children with primary spinal gliomas: a population-based study. *Pediatr Neurosurg* 42 (6): 347-53, 2006. [PubMed: 17047414]
9. Ahmed R, Menezes AH, Torner JC: Role of resection and adjuvant therapy in long-term disease outcomes for low-grade pediatric intramedullary spinal cord tumors. *J Neurosurg Pediatr* 18 (5): 594-601, 2016. [PubMed: 27420482]
10. Milano MT, Johnson MD, Sul J, et al.: Primary spinal cord glioma: a Surveillance, Epidemiology, and End Results database study. *J Neurooncol* 98 (1): 83-92, 2010. [PubMed: 19898743]
11. Scheinemann K, Bartels U, Huang A, et al.: Survival and functional outcome of childhood spinal cord low-grade gliomas. *Clinical article. J Neurosurg Pediatr* 4 (3): 254-61, 2009. [PubMed: 19772410]
12. Sawamura Y, Kamada K, Kamoshima Y, et al.: Role of surgery for optic pathway/hypothalamic astrocytomas in children. *Neuro Oncol* 10 (5): 725-33, 2008. [PMC free article: PMC2666249] [PubMed: 18612049]
13. Perwein T, Benesch M, Kandels D, et al.: High frequency of disease progression in pediatric spinal cord low-grade glioma (LGG): management strategies and results from the German LGG study group. *Neuro Oncol* 23 (7): 1148-1162, 2021. [PMC free article: PMC8248857] [PubMed: 33346834]
14. Sutton LN, Cnaan A, Klatt L, et al.: Postoperative surveillance imaging in children with cerebellar astrocytomas. *J Neurosurg* 84 (5): 721-5, 1996. [PubMed: 8622142]
15. Dorward IG, Luo J, Perry A, et al.: Postoperative imaging surveillance in pediatric pilocytic astrocytomas. *J Neurosurg Pediatr* 6 (4): 346-52, 2010. [PubMed: 20887107]
16. Mirow C, Pietsch T, Berkefeld S, et al.: Children <1 year show an inferior outcome when treated according to the traditional LGG treatment strategy: a report from the German multicenter trial HIT-LGG 1996 for children with low grade glioma (LGG). *Pediatr Blood Cancer* 61 (3): 457-63, 2014. [PubMed: 24039013]
17. Falkenstein F, Gessi M, Kandels D, et al.: Prognostic impact of distinct genetic entities in pediatric diffuse glioma WHO-grade II-Report from the German/Swiss SIOP-LGG 2004 cohort. *Int J Cancer* 147 (8): 2159-2175, 2020. [PubMed: 32239677]

18. Beebe DW, Ris MD, Armstrong FD, et al.: Cognitive and adaptive outcome in low-grade pediatric cerebellar astrocytomas: evidence of diminished cognitive and adaptive functioning in National Collaborative Research Studies (CCG 9891/POG 9130). *J Clin Oncol* 23 (22): 5198-204, 2005. [PubMed: 16051961]
19. Turner CD, Chordas CA, Liptak CC, et al.: Medical, psychological, cognitive and educational late-effects in pediatric low-grade glioma survivors treated with surgery only. *Pediatr Blood Cancer* 53 (3): 417-23, 2009. [PubMed: 19479971]
20. Daszkiewicz P, Maryniak A, Roszkowski M, et al.: Long-term functional outcome of surgical treatment of juvenile pilocytic astrocytoma of the cerebellum in children. *Childs Nerv Syst* 25 (7): 855-60, 2009. [PubMed: 19418058]
21. Packer RJ, Ater J, Allen J, et al.: Carboplatin and vincristine chemotherapy for children with newly diagnosed progressive low-grade gliomas. *J Neurosurg* 86 (5): 747-54, 1997. [PubMed: 9126887]
22. Gnekow AK, Falkenstein F, von Hornstein S, et al.: Long-term follow-up of the multicenter, multidisciplinary treatment study HIT-LGG-1996 for low-grade glioma in children and adolescents of the German Speaking Society of Pediatric Oncology and Hematology. *Neuro Oncol* 14 (10): 1265-84, 2012. [PMC free article: PMC3452343] [PubMed: 22942186]
23. Laithier V, Grill J, Le Deley MC, et al.: Progression-free survival in children with optic pathway tumors: dependence on age and the quality of the response to chemotherapy--results of the first French prospective study for the French Society of Pediatric Oncology. *J Clin Oncol* 21 (24): 4572-8, 2003. [PubMed: 14673044]
24. Prados MD, Edwards MS, Rabbitt J, et al.: Treatment of pediatric low-grade gliomas with a nitrosourea-based multiagent chemotherapy regimen. *J Neurooncol* 32 (3): 235-41, 1997. [PubMed: 9049885]
25. Chong AL, Pole JD, Scheinemann K, et al.: Optic pathway gliomas in adolescence--time to challenge treatment choices? *Neuro Oncol* 15 (3): 391-400, 2013. [PMC free article: PMC3578487] [PubMed: 23295772]
26. Gropman AL, Packer RJ, Nicholson HS, et al.: Treatment of diencephalic syndrome with chemotherapy: growth, tumor response, and long term control. *Cancer* 83 (1): 166-72, 1998. [PubMed: 9655307]
27. Gururangan S, Cavazos CM, Ashley D, et al.: Phase II study of carboplatin in children with progressive low-grade gliomas. *J Clin Oncol* 20 (13): 2951-8, 2002. [PubMed: 12089224]
28. Dodgshun AJ, Maixner WJ, Heath JA, et al.: Single agent carboplatin for pediatric low-grade glioma: A retrospective analysis shows equivalent efficacy to multiagent chemotherapy. *Int J Cancer* 138 (2): 481-8, 2016. [PubMed: 26235348]
29. Ater JL, Zhou T, Holmes E, et al.: Randomized study of two chemotherapy regimens for treatment of low-grade glioma in young children: a report from the Children's Oncology Group. *J Clin Oncol* 30 (21): 2641-7, 2012. [PMC free article: PMC3413276] [PubMed: 22665535]
30. Ater JL, Xia C, Mazewski CM, et al.: Nonrandomized comparison of neurofibromatosis type 1 and non-neurofibromatosis type 1 children who received carboplatin and vincristine for progressive low-grade glioma: A report from the Children's Oncology Group. *Cancer* 122 (12): 1928-36, 2016. [PMC free article: PMC4892942] [PubMed: 27061921]
31. Gnekow AK, Walker DA, Kandels D, et al.: A European randomised controlled trial of the addition of etoposide to standard vincristine and carboplatin induction as part of an 18-month treatment programme for childhood ( $\leq 16$  years) low grade glioma - A final report. *Eur J Cancer* 81: 206-225, 2017. [PMC free article: PMC5517338] [PubMed: 28649001]
32. Massimino M, Spreafico F, Cefalo G, et al.: High response rate to cisplatin/etoposide regimen in childhood low-grade glioma. *J Clin Oncol* 20 (20): 4209-16, 2002. [PubMed: 12377964]
33. Massimino M, Spreafico F, Riva D, et al.: A lower-dose, lower-toxicity cisplatin-etoposide regimen for childhood progressive low-grade glioma. *J Neurooncol* 100 (1): 65-71, 2010. [PubMed: 20151174]
34. Mora J, Perez-Jaume S, Cruz O: Treatment of childhood astrocytomas with irinotecan and cisplatin. *Clin Transl Oncol* 20 (4): 500-507, 2018. [PubMed: 28828715]
35. von Hornstein S, Kortmann RD, Pietsch T, et al.: Impact of chemotherapy on disseminated low-grade glioma in children and adolescents: report from the HIT-LGG 1996 trial. *Pediatr Blood Cancer* 56 (7): 1046-54, 2011.

[PubMed: 21319282]

36. Bouffet E, Jakacki R, Goldman S, et al.: Phase II study of weekly vinblastine in recurrent or refractory pediatric low-grade glioma. *J Clin Oncol* 30 (12): 1358-63, 2012. [PubMed: 22393086]
37. Lassaletta A, Scheinemann K, Zelcer SM, et al.: Phase II Weekly Vinblastine for Chemotherapy-Naïve Children With Progressive Low-Grade Glioma: A Canadian Pediatric Brain Tumor Consortium Study. *J Clin Oncol* 34 (29): 3537-3543, 2016. [PubMed: 27573663]
38. Gururangan S, Fisher MJ, Allen JC, et al.: Temozolomide in children with progressive low-grade glioma. *Neuro Oncol* 9 (2): 161-8, 2007. [PMC free article: PMC1871667] [PubMed: 17347491]
39. Khaw SL, Coleman LT, Downie PA, et al.: Temozolomide in pediatric low-grade glioma. *Pediatr Blood Cancer* 49 (6): 808-11, 2007. [PubMed: 17588234]
40. Moreno L, Bautista F, Ashley S, et al.: Does chemotherapy affect the visual outcome in children with optic pathway glioma? A systematic review of the evidence. *Eur J Cancer* 46 (12): 2253-9, 2010. [PubMed: 20400294]
41. Shofty B, Ben-Sira L, Freedman S, et al.: Visual outcome following chemotherapy for progressive optic pathway gliomas. *Pediatr Blood Cancer* 57 (3): 481-5, 2011. [PubMed: 21241008]
42. Falzon K, Drimtzias E, Picton S, et al.: Visual outcomes after chemotherapy for optic pathway glioma in children with and without neurofibromatosis type 1: results of the International Society of Paediatric Oncology (SIOP) Low-Grade Glioma 2004 trial UK cohort. *Br J Ophthalmol* 102 (10): 1367-1371, 2018. [PubMed: 29343527]
43. Rakotonjanahary J, Gravier N, Lambron J, et al.: Long-term visual acuity in patients with optic pathway glioma treated during childhood with up-front BB-SFOP chemotherapy-Analysis of a French pediatric historical cohort. *PLoS One* 14 (3): e0212107, 2019. [PMC free article: PMC6407847] [PubMed: 30849081]
44. Fisher BJ, Leighton CC, Vujovic O, et al.: Results of a policy of surveillance alone after surgical management of pediatric low grade gliomas. *Int J Radiat Oncol Biol Phys* 51 (3): 704-10, 2001. [PubMed: 11597812]
45. Tsang DS, Murphy ES, Merchant TE: Radiation Therapy for Optic Pathway and Hypothalamic Low-Grade Gliomas in Children. *Int J Radiat Oncol Biol Phys* 99 (3): 642-651, 2017. [PubMed: 29280458]
46. Greenberger BA, Pulsifer MB, Ebb DH, et al.: Clinical outcomes and late endocrine, neurocognitive, and visual profiles of proton radiation for pediatric low-grade gliomas. *Int J Radiat Oncol Biol Phys* 89 (5): 1060-8, 2014. [PubMed: 25035209]
47. Paulino AC, Mazloom A, Terashima K, et al.: Intensity-modulated radiotherapy (IMRT) in pediatric low-grade glioma. *Cancer* 119 (14): 2654-9, 2013. [PubMed: 23633429]
48. Müller K, Gnekow A, Falkenstein F, et al.: Radiotherapy in pediatric pilocytic astrocytomas. A subgroup analysis within the prospective multicenter study HIT-LGG 1996 by the German Society of Pediatric Oncology and Hematology (GPOH). *Strahlenther Onkol* 189 (8): 647-55, 2013. [PubMed: 23831852]
49. Bitterman DS, MacDonald SM, Yock TI, et al.: Revisiting the Role of Radiation Therapy for Pediatric Low-Grade Glioma. *J Clin Oncol* 37 (35): 3335-3339, 2019. [PubMed: 31498029]
50. Cherlow JM, Shaw DWW, Margraf LR, et al.: Conformal Radiation Therapy for Pediatric Patients with Low-Grade Glioma: Results from the Children's Oncology Group Phase 2 Study ACNS0221. *Int J Radiat Oncol Biol Phys* 103 (4): 861-868, 2019. [PMC free article: PMC6548322] [PubMed: 30419305]
51. Indelicato DJ, Rotondo RL, Uezono H, et al.: Outcomes Following Proton Therapy for Pediatric Low-Grade Glioma. *Int J Radiat Oncol Biol Phys* 104 (1): 149-156, 2019. [PubMed: 30684665]
52. Ludmir EB, Mahajan A, Paulino AC, et al.: Increased risk of pseudoprogression among pediatric low-grade glioma patients treated with proton versus photon radiotherapy. *Neuro Oncol* 21 (5): 686-695, 2019. [PMC free article: PMC6502497] [PubMed: 30753704]
53. Chawla S, Korones DN, Milano MT, et al.: Spurious progression in pediatric brain tumors. *J Neurooncol* 107 (3): 651-7, 2012. [PubMed: 22237949]
54. Marcus KJ, Goumnerova L, Billett AL, et al.: Stereotactic radiotherapy for localized low-grade gliomas in children: final results of a prospective trial. *Int J Radiat Oncol Biol Phys* 61 (2): 374-9, 2005. [PubMed:

15667955]

55. Combs SE, Schulz-Ertner D, Moschos D, et al.: Fractionated stereotactic radiotherapy of optic pathway gliomas: tolerance and long-term outcome. *Int J Radiat Oncol Biol Phys* 62 (3): 814-9, 2005. [PubMed: 15936565]
56. Naftel RP, Pollack IF, Zuccoli G, et al.: Pseudoprogession of low-grade gliomas after radiotherapy. *Pediatr Blood Cancer* 62 (1): 35-9, 2015. [PubMed: 25213668]
57. Merchant TE, Kun LE, Wu S, et al.: Phase II trial of conformal radiation therapy for pediatric low-grade glioma. *J Clin Oncol* 27 (22): 3598-604, 2009. [PMC free article: PMC3525947] [PubMed: 19581536]
58. Merchant TE, Conklin HM, Wu S, et al.: Late effects of conformal radiation therapy for pediatric patients with low-grade glioma: prospective evaluation of cognitive, endocrine, and hearing deficits. *J Clin Oncol* 27 (22): 3691-7, 2009. [PMC free article: PMC2799064] [PubMed: 19581535]
59. Kano H, Niranjana A, Kondziolka D, et al.: Stereotactic radiosurgery for pilocytic astrocytomas part 2: outcomes in pediatric patients. *J Neurooncol* 95 (2): 219-29, 2009. [PubMed: 19468692]
60. Hallemeier CL, Pollock BE, Schomberg PJ, et al.: Stereotactic radiosurgery for recurrent or unresectable pilocytic astrocytoma. *Int J Radiat Oncol Biol Phys* 83 (1): 107-12, 2012. [PubMed: 22019245]
61. Mansur DB, Rubin JB, Kidd EA, et al.: Radiation therapy for pilocytic astrocytomas of childhood. *Int J Radiat Oncol Biol Phys* 79 (3): 829-34, 2011. [PubMed: 20421157]
62. Acharya S, Quesada S, Coca K, et al.: Long-term visual acuity outcomes after radiation therapy for sporadic optic pathway glioma. *J Neurooncol* 144 (3): 603-610, 2019. [PubMed: 31414376]
63. Hanania AN, Paulino AC, Ludmir EB, et al.: Early radiotherapy preserves vision in sporadic optic pathway glioma. *Cancer* 127 (13): 2358-2367, 2021. [PubMed: 33739455]
64. Jenkin D, Angyalfi S, Becker L, et al.: Optic glioma in children: surveillance, resection, or irradiation? *Int J Radiat Oncol Biol Phys* 25 (2): 215-25, 1993. [PubMed: 8420869]
65. Khafaga Y, Hassounah M, Kandil A, et al.: Optic gliomas: a retrospective analysis of 50 cases. *Int J Radiat Oncol Biol Phys* 56 (3): 807-12, 2003. [PubMed: 12788189]
66. Krishnatry R, Zhukova N, Guerreiro Stucklin AS, et al.: Clinical and treatment factors determining long-term outcomes for adult survivors of childhood low-grade glioma: A population-based study. *Cancer* 122 (8): 1261-9, 2016. [PubMed: 26970559]
67. Acharya S, Liu JF, Tatevossian RG, et al.: Risk stratification in pediatric low-grade glioma and glioneuronal tumor treated with radiation therapy: an integrated clinicopathologic and molecular analysis. *Neuro Oncol* 22 (8): 1203-1213, 2020. [PMC free article: PMC7594561] [PubMed: 32052049]
68. Grill J, Couanet D, Cappelli C, et al.: Radiation-induced cerebral vasculopathy in children with neurofibromatosis and optic pathway glioma. *Ann Neurol* 45 (3): 393-6, 1999. [PubMed: 10072056]
69. Franz DN, Agricola KD, Tudor CA, et al.: Everolimus for tumor recurrence after surgical resection for subependymal giant cell astrocytoma associated with tuberous sclerosis complex. *J Child Neurol* 28 (5): 602-7, 2013. [PubMed: 22805244]
70. Krueger DA, Care MM, Holland K, et al.: Everolimus for subependymal giant-cell astrocytomas in tuberous sclerosis. *N Engl J Med* 363 (19): 1801-11, 2010. [PubMed: 21047224]
71. Weidman DR, Pole JD, Bouffet E, et al.: Dose-level response rates of mTor inhibition in tuberous sclerosis complex (TSC) related subependymal giant cell astrocytoma (SEGA). *Pediatr Blood Cancer* 62 (10): 1754-60, 2015. [PubMed: 25929843]
72. Franz DN, Leonard J, Tudor C, et al.: Rapamycin causes regression of astrocytomas in tuberous sclerosis complex. *Ann Neurol* 59 (3): 490-8, 2006. [PubMed: 16453317]
73. Franz DN, Belousova E, Sparagana S, et al.: Efficacy and safety of everolimus for subependymal giant cell astrocytomas associated with tuberous sclerosis complex (EXIST-1): a multicentre, randomised, placebo-controlled phase 3 trial. *Lancet* 381 (9861): 125-32, 2013. [PubMed: 23158522]
74. Franz DN, Agricola K, Mays M, et al.: Everolimus for subependymal giant cell astrocytoma: 5-year final analysis. *Ann Neurol* 78 (6): 929-38, 2015. [PMC free article: PMC5063160] [PubMed: 26381530]

## Treatment of Progressive/Recurrent Childhood Low-Grade Astrocytomas

To determine and implement optimal management, treatment is often guided by a multidisciplinary team of cancer specialists who have experience treating childhood brain tumors.

For children with low-grade optic pathway astrocytomas, treatment options should be considered not only to improve survival but also to stabilize visual function.[1,2]

Childhood low-grade astrocytomas may progress or recur many years after initial presentation and treatment.

An individual plan needs to be tailored on the basis of the following:

- Patient age.
- Tumor location.
- Prior treatment.

Recurrent disease is usually at the primary tumor site, although multifocal or widely disseminated disease to other intracranial sites and to the spinal leptomeninges has been documented.[3,4] Most children whose low-grade diffuse fibrillary astrocytomas recur will harbor low-grade lesions; however, transformation into a higher grade tumor is possible. Surveillance imaging will frequently identify asymptomatic recurrences.[5] At the time of recurrence, a complete evaluation to determine the extent of the relapse is indicated.

Standard treatment options for progressive/recurrent childhood low-grade astrocytomas include the following:

1. Second surgery.
2. Radiation therapy.
3. Chemotherapy.
4. Targeted therapy with or without chemotherapy.
5. Other targeted therapies.

### Second Surgery

Patients with low-grade astrocytomas who relapse after being treated with surgery alone may be candidates for another surgical resection.[6] The need for surgical intervention must be individualized on the basis of the following:

- Initial tumor type.
- Length of time between initial treatment and the reappearance of the mass lesion.
- Clinical picture.

Utility of second surgery is impacted by site of recurrence and the probability of obtaining a near-total resection/gross-total resection without significant neurologic injury.[7]

### Radiation Therapy

The rationale for the use of radiation therapy is essentially the same when utilized as first-line therapy or at the time of recurrence (refer to the Radiation therapy subsection of the Treatment of Childhood Low-Grade Astrocytomas section of this summary). If the child has never received radiation therapy, local radiation therapy may be a treatment option, although chemotherapy in lieu of radiation may be considered, depending on the child's age and the extent and location of the tumor.[8][Level of evidence: 3iA]; [9][Level of evidence: 3iiiDi]



For children with low-grade gliomas for whom radiation therapy is indicated, conformal radiation therapy approaches appear effective and offer the potential for reducing the acute and long-term toxicities associated with this modality. [10-13]

## Chemotherapy

If there is recurrence at an unresectable site, chemotherapy should be considered.

Chemotherapy may result in relatively long-term disease control.[14,15] The choice of regimen depends on whether previous chemotherapy has been utilized. Numerous options can be considered, including carboplatin and vincristine (CV); thioguanine, procarbazine, lomustine, and vincristine (TPCV); vinblastine alone; temozolomide alone; or temozolomide in combination with carboplatin and vincristine.[14-17]

## Targeted Therapy With or Without Chemotherapy

Antitumor activity has also been observed for bevacizumab given in combination with irinotecan, which, in some cases, also results in clinical or visual improvement.[18]

Evidence (targeted therapy [bevacizumab]):

1. In a phase II study of bevacizumab plus irinotecan for children with recurrent low-grade gliomas, the following results were observed:[19]
  - Sustained partial responses were observed in only two patients (5.7%).
  - The 6-month progression-free survival (PFS) rate was 85.4% (standard error [SE] ± 5.96%).
  - The 2-year PFS rate was 47.8% (SE ± 9.27%).
2. A pilot study of 14 patients with recurrent low-grade gliomas also evaluated bevacizumab-based therapies and observed the following:[20][Level of evidence: 3iiDi]; [21][Level of evidence: 3iiiDiv]
  - Objective responses were seen in 12 patients (86%).
  - No patients progressed on therapy (median treatment duration, 12 months), but 13 of 14 progressed after stopping bevacizumab at a median of 5 months.
3. Bevacizumab has also been employed for children with low-grade gliomas and symptomatic radiation-induced tumor enlargement.[22,23]
  - Treatment with bevacizumab produced radiographic improvement (five of five patients) and allowed weaning off steroids (four of four patients).

With the identification of *BRAF* mutations driving a significant proportion of low-grade gliomas, inhibition of various elements of this molecular pathway (e.g., MEK and BRAF) are actively being tested in ongoing clinical trials, with early reports suggesting substantial activity. While first-generation BRAF inhibitors like vemurafenib and dabrafenib are active against *BRAF* V600E–mutated tumors, they are contraindicated for tumors with *BRAF* gene fusions because of the potential for paradoxical activation of the MAPK pathway.[24,25]

Studies of BRAF and MEK inhibitors include the following:

1. For patients whose tumors have *BRAF* V600E mutations, the focus of clinical research efforts is on the evaluation of BRAF inhibitors in combination with MEK inhibitors. Such combinations are approved for the treatment of adult cancers with *BRAF* V600E mutations and are more effective than either BRAF inhibitors or MEK inhibitors used as single agents.[26]

- Results on the use of the BRAF V600E inhibitor dabrafenib demonstrated a 44% overall response rate (1 complete response and 13 partial responses) by central review in children with *BRAF* V600–mutated relapsed or refractory low-grade gliomas. The median duration of response was 26 months. Disease control (complete response plus partial response plus stable disease) was 78%. The therapy was well tolerated, although 91% of patients had some side effects such as fatigue (34%), rash (31%), and pyrexia (28%). Nine of 32 patients had grade 3 to grade 4 toxicities, 10 patients required dose modifications, and 2 patients discontinued treatment, including 1 child who had disseminated intravascular coagulation with hypertension. In this pediatric study, no cases of squamous cell carcinoma of the skin or keratoacanthoma were encountered.[27]
  - Case reports have also documented activity for BRAF inhibitors such as vemurafenib and for BRAF inhibitors in combination with MEK inhibitors for children, adolescents, and young adults with *BRAF* V600–mutated low-grade gliomas.[28-32]
2. The MEK inhibitor selumetinib has been studied in a phase I/II clinical trial for children with low-grade gliomas (PBTC-029 [NCT01089101]).
- a. The phase I component of the PBTC-029 trial showed the following results:[33]
    - Selumetinib was tolerated at a daily dose of 25 mg/m<sup>2</sup>.
    - The most common adverse events leading to patient discontinuation of treatment were rash, paronychia, and asymptomatic creatine phosphokinase (CPK) elevation.
  - b. Stratum 1 of the phase II component of this trial was for patients with *BRAF* genomic alterations.[34,35]
    - Nine of 25 patients (36%) achieved a partial response, with responses occurring for both *BRAF* V600E patients and for patients with *BRAF* gene fusions.
    - The 2-year PFS rate was 70% for stratum 1 patients.
  - c. Stratum 3 of the phase II component of this trial was for patients with NF1-associated low-grade gliomas.[35]
    - The 2-year event-free survival rate for this group was 96%.
    - 10 of 25 patients (40%) achieved partial responses.

The most common toxicities across all strata were grade 1 and grade 2 CPK elevation, diarrhea, hypoalbuminemia, elevated aspartate aminotransferase (AST), and rash. Rare grade 3 and grade 4 toxicities included elevated CPK, rash, neutropenia, emesis, and paronychia.

### Other Targeted Therapies

In a series of 23 patients with recurrent low-grade gliomas, everolimus demonstrated modest activity, with a 2-year PFS rate of 39% and an overall survival rate of 93%.[36] A companion study completed by the Neurofibromatosis Clinical Trials Consortium evaluated 23 children with NF1 and progressive low-grade gliomas. Of the 22 evaluable patients, 15 demonstrated either a partial response or tumor stabilization, 10 of whom remained free of progression for a median follow-up of 33 months.[37]

### Treatment Options Under Clinical Evaluation

Early-phase therapeutic trials may be available for selected patients. These trials may be available via the [COG](#), the [Pediatric Brain Tumor Consortium](#), or other entities. Information about National Cancer Institute (NCI)–supported clinical trials can be found on the [NCI website](#). For information about clinical trials sponsored by other organizations,

refer to the [ClinicalTrials.gov](https://clinicaltrials.gov) website.

The following are examples of national and/or institutional clinical trials that are currently being conducted:

- **ACNS1931 (NCT04576117)** (A Study to Compare Treatment With the Drug Selumetinib Alone Versus Selumetinib and Vinblastine in Patients With Recurrent or Progressive Low-Grade Glioma): This phase III trial is investigating the best dose of vinblastine in combination with selumetinib and the benefit of adding vinblastine to selumetinib compared with selumetinib alone in treating children and young adults with progressive or recurrent low-grade glioma.
- **APEC1621 (NCT03155620)** (Pediatric MATCH: Targeted Therapy Directed by Genetic Testing in Treating Pediatric Patients with Relapsed or Refractory Advanced Solid Tumors, Non-Hodgkin Lymphomas, or Histiocytic Disorders): NCI-COG Pediatric Molecular Analysis for Therapeutic Choice (MATCH), referred to as Pediatric MATCH, will match targeted agents with specific molecular changes identified in a patient's tumor (refractory or recurrent). Children and adolescents aged 1 to 21 years are eligible for the trial.

Patients with tumors that have molecular variants addressed by treatment arms included in the trial will be offered treatment on Pediatric MATCH. Additional information can be obtained on the [NCI website](https://www.nci.nih.gov) and [ClinicalTrials.gov](https://clinicaltrials.gov) website.

### Current Clinical Trials

Use our [advanced clinical trial search](#) to find NCI-supported cancer clinical trials that are now enrolling patients. The search can be narrowed by location of the trial, type of treatment, name of the drug, and other criteria. [General information](#) about clinical trials is also available.

### References

1. Nicolin G, Parkin P, Mabbott D, et al.: Natural history and outcome of optic pathway gliomas in children. *Pediatr Blood Cancer* 53 (7): 1231-7, 2009. [PubMed: 19621457]
2. Kramm CM, Butenhoff S, Rausche U, et al.: Thalamic high-grade gliomas in children: a distinct clinical subset? *Neuro Oncol* 13 (6): 680-9, 2011. [PMC free article: PMC3107103] [PubMed: 21636712]
3. Perilongo G, Carollo C, Salviati L, et al.: Diencephalic syndrome and disseminated juvenile pilocytic astrocytomas of the hypothalamic-optic chiasm region. *Cancer* 80 (1): 142-6, 1997. [PubMed: 9210720]
4. Leibel SA, Sheline GE, Wara WM, et al.: The role of radiation therapy in the treatment of astrocytomas. *Cancer* 35 (6): 1551-7, 1975. [PubMed: 1148989]
5. Udaka YT, Yeh-Nayre LA, Amene CS, et al.: Recurrent pediatric central nervous system low-grade gliomas: the role of surveillance neuroimaging in asymptomatic children. *J Neurosurg Pediatr* 11 (2): 119-26, 2013. [PubMed: 23157391]
6. Austin EJ, Alvord EC: Recurrences of cerebellar astrocytomas: a violation of Collins' law. *J Neurosurg* 68 (1): 41-7, 1988. [PubMed: 3335911]
7. Bowers DC, Krause TP, Aronson LJ, et al.: Second surgery for recurrent pilocytic astrocytoma in children. *Pediatr Neurosurg* 34 (5): 229-34, 2001. [PubMed: 11423771]
8. Scheinemann K, Bartels U, Tsangaris E, et al.: Feasibility and efficacy of repeated chemotherapy for progressive pediatric low-grade gliomas. *Pediatr Blood Cancer* 57 (1): 84-8, 2011. [PubMed: 21557457]
9. de Haas V, Grill J, Raquin MA, et al.: Relapses of optic pathway tumors after first-line chemotherapy. *Pediatr Blood Cancer* 52 (5): 575-80, 2009. [PubMed: 19148944]
10. Merchant TE, Conklin HM, Wu S, et al.: Late effects of conformal radiation therapy for pediatric patients with low-grade glioma: prospective evaluation of cognitive, endocrine, and hearing deficits. *J Clin Oncol* 27 (22): 3691-7, 2009. [PMC free article: PMC2799064] [PubMed: 19581535]
11. Marcus KJ, Goumnerova L, Billett AL, et al.: Stereotactic radiotherapy for localized low-grade gliomas in

- children: final results of a prospective trial. *Int J Radiat Oncol Biol Phys* 61 (2): 374-9, 2005. [PubMed: 15667955]
12. Bitterman DS, MacDonald SM, Yock TI, et al.: Revisiting the Role of Radiation Therapy for Pediatric Low-Grade Glioma. *J Clin Oncol* 37 (35): 3335-3339, 2019. [PubMed: 31498029]
  13. Cherlow JM, Shaw DWW, Margraf LR, et al.: Conformal Radiation Therapy for Pediatric Patients with Low-Grade Glioma: Results from the Children's Oncology Group Phase 2 Study ACNS0221. *Int J Radiat Oncol Biol Phys* 103 (4): 861-868, 2019. [PMC free article: PMC6548322] [PubMed: 30419305]
  14. Packer RJ, Lange B, Ater J, et al.: Carboplatin and vincristine for recurrent and newly diagnosed low-grade gliomas of childhood. *J Clin Oncol* 11 (5): 850-6, 1993. [PubMed: 8487049]
  15. Gnekow AK, Falkenstein F, von Hornstein S, et al.: Long-term follow-up of the multicenter, multidisciplinary treatment study HIT-LGG-1996 for low-grade glioma in children and adolescents of the German Speaking Society of Pediatric Oncology and Hematology. *Neuro Oncol* 14 (10): 1265-84, 2012. [PMC free article: PMC3452343] [PubMed: 22942186]
  16. Gururangan S, Fisher MJ, Allen JC, et al.: Temozolomide in children with progressive low-grade glioma. *Neuro Oncol* 9 (2): 161-8, 2007. [PMC free article: PMC1871667] [PubMed: 17347491]
  17. Lassaletta A, Scheinemann K, Zelcer SM, et al.: Phase II Weekly Vinblastine for Chemotherapy-Naïve Children With Progressive Low-Grade Glioma: A Canadian Pediatric Brain Tumor Consortium Study. *J Clin Oncol* 34 (29): 3537-3543, 2016. [PubMed: 27573663]
  18. Avery RA, Hwang EI, Jakacki RI, et al.: Marked recovery of vision in children with optic pathway gliomas treated with bevacizumab. *JAMA Ophthalmol* 132 (1): 111-4, 2014. [PubMed: 24232489]
  19. Gururangan S, Fangusaro J, Poussaint TY, et al.: Efficacy of bevacizumab plus irinotecan in children with recurrent low-grade gliomas--a Pediatric Brain Tumor Consortium study. *Neuro Oncol* 16 (2): 310-7, 2014. [PMC free article: PMC3895377] [PubMed: 24311632]
  20. Hwang EI, Jakacki RI, Fisher MJ, et al.: Long-term efficacy and toxicity of bevacizumab-based therapy in children with recurrent low-grade gliomas. *Pediatr Blood Cancer* 60 (5): 776-82, 2013. [PubMed: 22976922]
  21. Packer RJ, Jakacki R, Horn M, et al.: Objective response of multiply recurrent low-grade gliomas to bevacizumab and irinotecan. *Pediatr Blood Cancer* 52 (7): 791-5, 2009. [PubMed: 19165892]
  22. Foster KA, Ares WJ, Pollack IF, et al.: Bevacizumab for symptomatic radiation-induced tumor enlargement in pediatric low grade gliomas. *Pediatr Blood Cancer* 62 (2): 240-245, 2015. [PubMed: 25382690]
  23. Zhukova N, Rajagopal R, Lam A, et al.: Use of bevacizumab as a single agent or in adjunct with traditional chemotherapy regimens in children with unresectable or progressive low-grade glioma. *Cancer Med* 8 (1): 40-50, 2019. [PMC free article: PMC6346232] [PubMed: 30569607]
  24. Sievert AJ, Lang SS, Boucher KL, et al.: Paradoxical activation and RAF inhibitor resistance of BRAF protein kinase fusions characterizing pediatric astrocytomas. *Proc Natl Acad Sci U S A* 110 (15): 5957-62, 2013. [PMC free article: PMC3625308] [PubMed: 23533272]
  25. Karajannis MA, Legault G, Fisher MJ, et al.: Phase II study of sorafenib in children with recurrent or progressive low-grade astrocytomas. *Neuro Oncol* 16 (10): 1408-16, 2014. [PMC free article: PMC4165419] [PubMed: 24803676]
  26. Odogwu L, Mathieu L, Blumenthal G, et al.: FDA Approval Summary: Dabrafenib and Trametinib for the Treatment of Metastatic Non-Small Cell Lung Cancers Harboring BRAF V600E Mutations. *Oncologist* 23 (6): 740-745, 2018. [PMC free article: PMC6067947] [PubMed: 29438093]
  27. Hargrave DR, Bouffet E, Tabori U, et al.: Efficacy and Safety of Dabrafenib in Pediatric Patients with BRAF V600 Mutation-Positive Relapsed or Refractory Low-Grade Glioma: Results from a Phase I/IIa Study. *Clin Cancer Res* 25 (24): 7303-7311, 2019. [PubMed: 31811016]
  28. Rush S, Foreman N, Liu A: Brainstem ganglioglioma successfully treated with vemurafenib. *J Clin Oncol* 31 (10): e159-60, 2013. [PubMed: 23358987]
  29. del Bufalo F, Carai A, Figà-Talamanca L, et al.: Response of recurrent BRAFV600E mutated ganglioglioma to Vemurafenib as single agent. *J Transl Med* 12: 356, 2014. [PMC free article: PMC4279809] [PubMed: 24803676]

25524464]

30. Aguilera D, Janss A, Mazewski C, et al.: Successful Retreatment of a Child with a Refractory Brainstem Ganglioglioma with Vemurafenib. *Pediatr Blood Cancer* 63 (3): 541-3, 2016. [PubMed: 26579623]
31. Marks AM, Bindra RS, DiLuna ML, et al.: Response to the BRAF/MEK inhibitors dabrafenib/trametinib in an adolescent with a BRAF V600E mutated anaplastic ganglioglioma intolerant to vemurafenib. *Pediatr Blood Cancer* 65 (5): e26969, 2018. [PubMed: 29380516]
32. Touat M, Gratioux J, Condette Auliac S, et al.: Vemurafenib and cobimetinib overcome resistance to vemurafenib in BRAF-mutant ganglioglioma. *Neurology* 91 (11): 523-525, 2018. [PubMed: 30120137]
33. Banerjee A, Jakacki RI, Onar-Thomas A, et al.: A phase I trial of the MEK inhibitor selumetinib (AZD6244) in pediatric patients with recurrent or refractory low-grade glioma: a Pediatric Brain Tumor Consortium (PBTC) study. *Neuro Oncol* 19 (8): 1135-1144, 2017. [PMC free article: PMC5570236] [PubMed: 28339824]
34. Fangusaro JR, Onar-Thomas A, Young-Poussaint T, et al.: A phase II prospective study of selumetinib in children with recurrent or refractory low-grade glioma (LGG): a Pediatric Brain Tumor Consortium (PBTC) study. [Abstract] *J Clin Oncol* 35 (Suppl 15): A-10504, 2017. Also available online. Last accessed February 1, 2022.
35. Fangusaro J, Onar-Thomas A, Young Poussaint T, et al.: Selumetinib in paediatric patients with BRAF-aberrant or neurofibromatosis type 1-associated recurrent, refractory, or progressive low-grade glioma: a multicentre, phase 2 trial. *Lancet Oncol* 20 (7): 1011-1022, 2019. [PMC free article: PMC6628202] [PubMed: 31151904]
36. Wright KD, Yao X, London WB, et al.: A POETIC Phase II study of continuous oral everolimus in recurrent, radiographically progressive pediatric low-grade glioma. *Pediatr Blood Cancer* 68 (2): e28787, 2021. [PubMed: 33140540]
37. Ullrich NJ, Prabhu SP, Reddy AT, et al.: A phase II study of continuous oral mTOR inhibitor everolimus for recurrent, radiographic-progressive neurofibromatosis type 1-associated pediatric low-grade glioma: a Neurofibromatosis Clinical Trials Consortium study. *Neuro Oncol* 22 (10): 1527-1535, 2020. [PMC free article: PMC7566451] [PubMed: 32236425]

## Treatment of Childhood High-Grade Astrocytomas

To determine and implement optimal management, treatment of childhood high-grade astrocytomas should be guided by a multidisciplinary team of cancer specialists who have experience treating childhood brain tumors.

Outcomes in high-grade gliomas occurring in childhood are often more favorable than that in adults. It is not clear whether this difference is caused by biologic variations in tumor characteristics, therapies used, tumor resectability, or other factors.

The therapy for both children and adults with supratentorial high-grade astrocytoma includes surgery, radiation therapy, and chemotherapy.

Standard treatment options for newly diagnosed childhood high-grade astrocytomas include the following:

1. Surgery.
2. Adjuvant therapy.
  - Radiation therapy.
  - Chemotherapy.

### Surgery

The ability to obtain a complete resection is associated with a better prognosis.[1,2] Among patients treated with surgery, radiation therapy, and nitrosourea (lomustine)-based chemotherapy, the 5-year progression-free survival rate was 19% (± 3%); the survival rate was 40% in those who had total resections.[3] Similarly, in a trial of multiagent

chemoradiation therapy and adjuvant chemotherapy in addition to valproic acid, the overall 5-year event-free survival (EFS) rate was 13%, but for children with a complete resection of their tumor, the EFS rate was 48%.<sup>[4]</sup><sup>[Level of evidence: 2A]</sup>

## Adjuvant Therapy

### Radiation therapy

Radiation therapy is routinely administered to a field that widely encompasses the entire tumor. The radiation therapy dose to the tumor bed is usually at least 54 Gy. Despite such therapy, overall survival (OS) rates remain poor. Similarly poor survival is seen in children with spinal cord primaries and children with thalamic high-grade gliomas (i.e., diffuse midline gliomas, H3 K27M-mutant tumors) treated with radiation therapy.<sup>[5,6]</sup>; <sup>[7,8]</sup><sup>[Level of evidence: 3iiiA]</sup>

### Chemotherapy

In one trial, children with glioblastoma who were treated on a prospective randomized trial with adjuvant lomustine, vincristine, and prednisone fared better than children treated with radiation therapy alone.<sup>[9]</sup> Furthermore, children who received lomustine in addition to temozolomide for subtotally resected tumors, especially glioblastoma with methylated O-6-methylguanine-DNA-methyltransferase (MGMT) overexpression, had a slightly improved outcome.<sup>[10]</sup> Patients with *IDH1* mutations had an improved 1-year OS rate (100%) when compared with *IDH1*-wild-type tumors (1-year OS rate, 81%), highlighting the potential importance of underlying biological characteristics.<sup>[11]</sup>

The use of temozolomide to treat glioblastoma was initially investigated in adults. In this population, the addition of temozolomide during and after radiation therapy resulted in improved 2-year EFS compared with treatment with radiation therapy alone. Adult patients with glioblastoma with an MGMT promoter benefitted from temozolomide, whereas those who did not have a methylated MGMT promoter did not.<sup>[12,13]</sup> The role of temozolomide given concurrently with radiation therapy for children with supratentorial high-grade glioma appears comparable to the outcome seen in children treated with nitrosourea-based therapy <sup>[14]</sup> and again demonstrated an EFS advantage for those children without MGMT overexpression.

The use of adjuvant bevacizumab after radiation therapy did not prolong OS or progression-free survival in pediatric patients with newly diagnosed high-grade gliomas.<sup>[15]</sup>

Younger children may benefit from chemotherapy or consolidation with high-dose chemotherapy to delay, modify, or, in selected cases, obviate the need for radiation therapy.<sup>[16-18]</sup>

## Treatment Options Under Clinical Evaluation

Early-phase therapeutic trials may be available for selected patients. These trials may be available via the [Children's Oncology Group \(COG\)](#), the [Pediatric Brain Tumor Consortium](#), or other entities. Information about National Cancer Institute (NCI)-supported clinical trials can be found on the [NCI website](#). For information about clinical trials sponsored by other organizations, refer to the [ClinicalTrials.gov website](#).

The following are examples of national and/or institutional clinical trials that are currently being conducted:

- **ACNS1721 (NCT03581292)** (Veliparib, Radiation Therapy, and Temozolomide in Treating Participants With Newly Diagnosed Malignant Glioma Without H3 K27M or *BRAF* V600E Mutations): This phase II trial investigates the use of veliparib, radiation therapy, and temozolomide in treating patients with newly diagnosed malignant glioma without H3 K27M or *BRAF* V600E mutations.
- **ACNS1723 (NCT03919071)** (Dabrafenib Combined With Trametinib After Radiation Therapy in Treating Patients With Newly-Diagnosed High-Grade Glioma): This phase II trial investigates the use of the combination of dabrafenib and trametinib after radiation therapy in children and young adults with high-grade gliomas who

have a *BRAF* V600 mutation.

## Current Clinical Trials

Use our [advanced clinical trial search](#) to find NCI-supported cancer clinical trials that are now enrolling patients. The search can be narrowed by location of the trial, type of treatment, name of the drug, and other criteria. [General information](#) about clinical trials is also available.

## References

1. Wisoff JH, Boyett JM, Berger MS, et al.: Current neurosurgical management and the impact of the extent of resection in the treatment of malignant gliomas of childhood: a report of the Children's Cancer Group trial no. CCG-945. *J Neurosurg* 89 (1): 52-9, 1998. [PubMed: 9647172]
2. Yang T, Temkin N, Barber J, et al.: Gross total resection correlates with long-term survival in pediatric patients with glioblastoma. *World Neurosurg* 79 (3-4): 537-44, 2013 Mar-Apr. [PubMed: 23017588]
3. Fouladi M, Hunt DL, Pollack IF, et al.: Outcome of children with centrally reviewed low-grade gliomas treated with chemotherapy with or without radiotherapy on Children's Cancer Group high-grade glioma study CCG-945. *Cancer* 98 (6): 1243-52, 2003. [PubMed: 12973849]
4. Wolff JE, Driever PH, Erdlenbruch B, et al.: Intensive chemotherapy improves survival in pediatric high-grade glioma after gross total resection: results of the HIT-GBM-C protocol. *Cancer* 116 (3): 705-12, 2010. [PubMed: 19957326]
5. Kramm CM, Butenhoff S, Rausche U, et al.: Thalamic high-grade gliomas in children: a distinct clinical subset? *Neuro Oncol* 13 (6): 680-9, 2011. [PMC free article: PMC3107103] [PubMed: 21636712]
6. Tendulkar RD, Pai Panandiker AS, Wu S, et al.: Irradiation of pediatric high-grade spinal cord tumors. *Int J Radiat Oncol Biol Phys* 78 (5): 1451-6, 2010. [PMC free article: PMC5095924] [PubMed: 20346593]
7. Wolff B, Ng A, Roth D, et al.: Pediatric high grade glioma of the spinal cord: results of the HIT-GBM database. *J Neurooncol* 107 (1): 139-46, 2012. [PubMed: 21964697]
8. Ononiwu C, Mehta V, Bettogowda C, et al.: Pediatric spinal glioblastoma multiforme: current treatment strategies and possible predictors of survival. *Childs Nerv Syst* 28 (5): 715-20, 2012. [PubMed: 22307824]
9. Sposto R, Ertel IJ, Jenkin RD, et al.: The effectiveness of chemotherapy for treatment of high grade astrocytoma in children: results of a randomized trial. A report from the Childrens Cancer Study Group. *J Neurooncol* 7 (2): 165-77, 1989. [PubMed: 2550594]
10. Jakacki RI, Cohen KJ, Buxton A, et al.: Phase 2 study of concurrent radiotherapy and temozolomide followed by temozolomide and lomustine in the treatment of children with high-grade glioma: a report of the Children's Oncology Group ACNS0423 study. *Neuro Oncol* 18 (10): 1442-50, 2016. [PMC free article: PMC5035517] [PubMed: 27006176]
11. Pollack IF, Hamilton RL, Sobol RW, et al.: IDH1 mutations are common in malignant gliomas arising in adolescents: a report from the Children's Oncology Group. *Childs Nerv Syst* 27 (1): 87-94, 2011. [PMC free article: PMC3014378] [PubMed: 20725730]
12. Stupp R, Mason WP, van den Bent MJ, et al.: Radiotherapy plus concomitant and adjuvant temozolomide for glioblastoma. *N Engl J Med* 352 (10): 987-96, 2005. [PubMed: 15758009]
13. Hegi ME, Diserens AC, Gorlia T, et al.: MGMT gene silencing and benefit from temozolomide in glioblastoma. *N Engl J Med* 352 (10): 997-1003, 2005. [PubMed: 15758010]
14. Cohen KJ, Pollack IF, Zhou T, et al.: Temozolomide in the treatment of high-grade gliomas in children: a report from the Children's Oncology Group. *Neuro Oncol* 13 (3): 317-23, 2011. [PMC free article: PMC3064602] [PubMed: 21339192]
15. Grill J, Massimino M, Bouffet E, et al.: Phase II, Open-Label, Randomized, Multicenter Trial (HERBY) of Bevacizumab in Pediatric Patients With Newly Diagnosed High-Grade Glioma. *J Clin Oncol* 36 (10): 951-958, 2018. [PubMed: 29412784]

16. Duffner PK, Horowitz ME, Krischer JP, et al.: Postoperative chemotherapy and delayed radiation in children less than three years of age with malignant brain tumors. *N Engl J Med* 328 (24): 1725-31, 1993. [PubMed: 8388548]
17. Dufour C, Grill J, Lellouch-Tubiana A, et al.: High-grade glioma in children under 5 years of age: a chemotherapy only approach with the BBSFOP protocol. *Eur J Cancer* 42 (17): 2939-45, 2006. [PubMed: 16962317]
18. Espinoza JC, Haley K, Patel N, et al.: Outcome of young children with high-grade glioma treated with irradiation-avoiding intensive chemotherapy regimens: Final report of the Head Start II and III trials. *Pediatr Blood Cancer* 63 (10): 1806-13, 2016. [PMC free article: PMC5598351] [PubMed: 27332770]

## Treatment of Recurrent Childhood High-Grade Astrocytomas

To determine and implement optimal management, treatment of childhood high-grade astrocytomas should be guided by a multidisciplinary team of cancer specialists who have experience treating childhood brain tumors.

Most patients with high-grade astrocytomas or gliomas will eventually have tumor recurrence. Recurrences usually occur within 3 years of original diagnosis, but some patients recur many years after initial treatment. Disease may recur at the primary tumor site, at the margin of the resection/radiation bed, or at noncontiguous central nervous system sites. Systemic relapse rarely occurs.

At the time of recurrence, a complete evaluation for extent of relapse is indicated for all malignant tumors. Biopsy or surgical resection may be necessary for confirmation of relapse because other entities, such as secondary tumor and treatment-related brain necrosis, may be clinically indistinguishable from tumor recurrence.

Treatment options for recurrent childhood high-grade astrocytomas include the following:

1. Surgery.
2. High-dose chemotherapy with stem cell transplant (SCT).<sup>[1]</sup>
3. Radiation therapy.
4. Targeted therapy with a BRAF inhibitor, for patients with a *BRAF* V600E mutation.<sup>[2]</sup>
5. Immunotherapy.

## Surgery

The utility of surgical intervention must be individualized on the basis of the following:

- Initial tumor type.
- Length of time between initial treatment and the reappearance of the mass lesion.
- Location of the recurrent tumor.
- Consideration of therapeutics based on the requirement for fresh tumor tissue or to deliver therapy to the operative bed.

## High-dose Chemotherapy With SCT

High-dose, marrow-ablative chemotherapy with hematopoietic SCT may be effective in a highly selected subset of patients with minimal residual disease at time of recurrence.<sup>[1]</sup>[Level of evidence: 3iiiA] However, the results of previous clinical trials that tested various targeted and combination chemotherapies have largely failed to demonstrate convincing benefits for enrolled patients.<sup>[3-5]</sup>



## Radiation Therapy

Radiation therapy is appropriate for patients who have not previously been irradiated. Radiation doses and volumes are similar to those used for newly diagnosed patients. Generally, this is limited to young children initially treated with radiation-avoiding strategies.

For previously irradiated patients, reirradiation has been used, although the data demonstrating benefit are sparse. Stereotactic radiosurgery (SRS) or stereotactic radiation therapy (SRT) techniques using either hypofractionated radiation therapy or standard fraction sizes may be considered. For small volume distinct lesions, SRS allows for maximum sparing of normal tissues. For more infiltrative lesions, fractionated radiation therapy may better spare normal tissues.[6]

## Targeted Therapy

Molecular targets for recurrent high-grade gliomas are limited. *BRAF* V600E mutations are present in a small subset of these patients, and a small number of cases have responded to BRAF inhibitors.

A case report documented a complete response to the BRAF inhibitor vemurafenib in a patient with recurrent *BRAF* V600-mutated glioblastoma.[7] A phase I study reported in an abstract that eight children with progressive *BRAF* V600E high-grade gliomas were treated with dabrafenib and demonstrated three complete responses, three partial responses, and two progressive disease responses.[8]

A small percentage of children with high-grade gliomas have gene fusions involving tyrosine kinases (e.g., *ALK*, *NTRK1*, *NTRK2*, *NTRK3*, *ROS1*, and *MET*).[9,10] Kinase gene fusions account for a high percentage of cases among children younger than 1 year, but they can occur throughout childhood. Case reports have described responses to kinase inhibitors for patients with relapsed or refractory high-grade gliomas who have these gene fusions.[11,12]

## Immunotherapy

Numerous studies are investigating a variety of immunotherapy strategies, including checkpoint inhibitors, oncolytic viruses, and other immune-modulating strategies. The utility of such strategies in the treatment of patients with recurrent childhood high-grade astrocytomas is unproven, with only preliminary evidence of activity in some settings.[13]

## Treatment Options Under Clinical Evaluation

The role of immune checkpoint inhibition in the treatment of children with recurrent high-grade astrocytoma is currently under study. Children with biallelic mismatch repair deficiency have a very high mutational burden and neoantigen expression and are at risk of developing a variety of cancers, including hematologic malignancies, gastrointestinal cancers, and brain tumors. The high mutation and neoantigen load has been correlated with improved response to immune checkpoint inhibition. Early case reports have demonstrated clinical and radiographic responses in children who are treated with an anti-programmed death-1 (anti-PD-1) inhibitor.[14]

Patients for whom initial treatment fails may benefit from additional treatment, including entry into clinical trials of novel therapeutic approaches.[15] Early-phase therapeutic trials may be available for selected patients. These trials may be available via the [Children's Oncology Group \(COG\)](#), the [Pediatric Brain Tumor Consortium](#), or other entities. Information about NCI-supported clinical trials can be found on the [NCI website](#). For information about clinical trials sponsored by other organizations, refer to the [ClinicalTrials.gov website](#).

The following is an example of a national and/or institutional clinical trial that is currently being conducted:

- **APEC1621 (NCT03155620)** (Pediatric MATCH: Targeted Therapy Directed by Genetic Testing in Treating Pediatric Patients with Relapsed or Refractory Advanced Solid Tumors, Non-Hodgkin Lymphomas, or Histiocytic Disorders): NCI-COG Pediatric Molecular Analysis for Therapeutic Choice (MATCH), referred to

as Pediatric MATCH, will match targeted agents with specific molecular changes identified in a patient's tumor (refractory or recurrent). Children and adolescents aged 1 to 21 years are eligible for the trial.

Patients with tumors that have molecular variants addressed by treatment arms included in the trial will be offered treatment on Pediatric MATCH. Additional information can be obtained on the [NCI website](#) and [ClinicalTrials.gov website](#).

## Current Clinical Trials

Use our [advanced clinical trial search](#) to find NCI-supported cancer clinical trials that are now enrolling patients. The search can be narrowed by location of the trial, type of treatment, name of the drug, and other criteria. [General information](#) about clinical trials is also available.

## References

1. Finlay JL, Dhall G, Boyett JM, et al.: Myeloablative chemotherapy with autologous bone marrow rescue in children and adolescents with recurrent malignant astrocytoma: outcome compared with conventional chemotherapy: a report from the Children's Oncology Group. *Pediatr Blood Cancer* 51 (6): 806-11, 2008. [PMC free article: [PMC2844080](#)] [PubMed: [18802947](#)]
2. Hargrave DR, Moreno L, Broniscer A, et al.: Dabrafenib in pediatric patients with BRAF V600–positive high-grade glioma (HGG). [Abstract] *J Clin Oncol* 36 (Suppl 15): A-10505, 2018. Also available online. Last accessed February 1, 2022.
3. Fouladi M, Nicholson HS, Zhou T, et al.: A phase II study of the farnesyl transferase inhibitor, tipifarnib, in children with recurrent or progressive high-grade glioma, medulloblastoma/primitive neuroectodermal tumor, or brainstem glioma: a Children's Oncology Group study. *Cancer* 110 (11): 2535-41, 2007. [PubMed: [17932894](#)]
4. Nicholson HS, Kretschmar CS, Krailo M, et al.: Phase 2 study of temozolomide in children and adolescents with recurrent central nervous system tumors: a report from the Children's Oncology Group. *Cancer* 110 (7): 1542-50, 2007. [PubMed: [17705175](#)]
5. Wetmore C, Daryani VM, Billups CA, et al.: Phase II evaluation of sunitinib in the treatment of recurrent or refractory high-grade glioma or ependymoma in children: a children's Oncology Group Study ACNS1021. *Cancer Med* 5 (7): 1416-24, 2016. [PMC free article: [PMC4944867](#)] [PubMed: [27109549](#)]
6. Tsang DS, Oliveira C, Bouffet E, et al.: Repeat irradiation for children with supratentorial high-grade glioma. *Pediatr Blood Cancer* 66 (9): e27881, 2019. [PubMed: [31207154](#)]
7. Robinson GW, Orr BA, Gajjar A: Complete clinical regression of a BRAF V600E-mutant pediatric glioblastoma multiforme after BRAF inhibitor therapy. *BMC Cancer* 14: 258, 2014. [PMC free article: [PMC3996187](#)] [PubMed: [24725538](#)]
8. Kieran MW, Hargrave DR, Cohen KJ, et al.: Phase 1 study of dabrafenib in pediatric patients (pts) with relapsed or refractory BRAF V600E high- and low-grade gliomas (HGG, LGG), Langerhans cell histiocytosis (LCH), and other solid tumors (OST). [Abstract] *J Clin Oncol* 33 (15 Suppl): A-10004, 2015.
9. Torre M, Vasudevaraja V, Serrano J, et al.: Molecular and clinicopathologic features of gliomas harboring NTRK fusions. *Acta Neuropathol Commun* 8 (1): 107, 2020. [PMC free article: [PMC7362646](#)] [PubMed: [32665022](#)]
10. Clarke M, Mackay A, Ismer B, et al.: Infant High-Grade Gliomas Comprise Multiple Subgroups Characterized by Novel Targetable Gene Fusions and Favorable Outcomes. *Cancer Discov* 10 (7): 942-963, 2020. [PMC free article: [PMC8313225](#)] [PubMed: [32238360](#)]
11. Ziegler DS, Wong M, Mayoh C, et al.: Brief Report: Potent clinical and radiological response to larotrectinib in TRK fusion-driven high-grade glioma. *Br J Cancer* 119 (6): 693-696, 2018. [PMC free article: [PMC6173734](#)] [PubMed: [30220707](#)]
12. Desai AV, Robinson GW, Basu EM, et al.: Updated entrectinib data in children and adolescents with recurrent or refractory solid tumors, including primary CNS tumors. [Abstract] *J Clin Oncol* 38 (Suppl 15): A-107, 2020.

Also available online. Last accessed February 1, 2022.

13. Friedman GK, Johnston JM, Bag AK, et al.: Oncolytic HSV-1 G207 Immunovirotherapy for Pediatric High-Grade Gliomas. *N Engl J Med* 384 (17): 1613-1622, 2021. [PMC free article: PMC8284840] [PubMed: 33838625]
14. Bouffet E, Larouche V, Campbell BB, et al.: Immune Checkpoint Inhibition for Hypermutant Glioblastoma Multiforme Resulting From Germline Biallelic Mismatch Repair Deficiency. *J Clin Oncol* 34 (19): 2206-11, 2016. [PubMed: 27001570]
15. Warren KE, Gururangan S, Geyer JR, et al.: A phase II study of O6-benzylguanine and temozolomide in pediatric patients with recurrent or progressive high-grade gliomas and brainstem gliomas: a Pediatric Brain Tumor Consortium study. *J Neurooncol* 106 (3): 643-9, 2012. [PMC free article: PMC3518022] [PubMed: 21968943]

## Changes to This Summary (04/05/2022)

The PDQ cancer information summaries are reviewed regularly and updated as new information becomes available. This section describes the latest changes made to this summary as of the date above.

### Treatment of Childhood Low-Grade Astrocytomas

Added text to state that surgical resection for spinal tumors is generally attempted but it often cannot be completed. Also added text about the results of a study that included 128 patients with primary spinal cord low-grade gliomas, including information about treatment, outcomes, and complications (cited Perwein et al. as reference 13 and level of evidence 3iiiDi).

Added text to state that a multivariate analysis examined 100 patients with confirmed diagnoses of World Health Organization (WHO) grade II diffuse gliomas treated in an International Society of Paediatric Oncology study. The extent of glioma resection had the greatest impact on patients' event-free survival (EFS) rates. The 5-year EFS rates were 75% to 76% for patients who underwent a complete or subtotal resection. In comparison, 5-year EFS rates were 56% for patients who had a partial resection and 19% for patients who had a biopsy (cited Falkenstein et al. as reference 17 and level of evidence 2Di).

Added text to state that in a separate study that included 100 patients with WHO grade II diffuse gliomas, a subset of patients were treated with carboplatin and vincristine; some patients also received etoposide. This subset of patients had a 5-year progression-free survival (PFS) rate of 38% when patients with *Histone3*-mutated tumors were excluded.

Added text to state that in a separate study that included 100 patients with WHO grade II diffuse gliomas, a subset of patients were treated with radiation therapy. These patients had a 5-year PFS rate of 74% when patients with *Histone3*-mutated tumors were excluded.

This summary is written and maintained by the [PDQ Pediatric Treatment Editorial Board](#), which is editorially independent of NCI. The summary reflects an independent review of the literature and does not represent a policy statement of NCI or NIH. More information about summary policies and the role of the PDQ Editorial Boards in maintaining the PDQ summaries can be found on the [About This PDQ Summary and PDQ® - NCI's Comprehensive Cancer Database](#) pages.

## About This PDQ Summary

### Purpose of This Summary

This PDQ cancer information summary for health professionals provides comprehensive, peer-reviewed, evidence-based information about the treatment of childhood astrocytomas. It is intended as a resource to inform and assist clinicians in the care of their patients. It does not provide formal guidelines or recommendations for making health care decisions.

## Reviewers and Updates

This summary is reviewed regularly and updated as necessary by the [PDQ Pediatric Treatment Editorial Board](#), which is editorially independent of the National Cancer Institute (NCI). The summary reflects an independent review of the literature and does not represent a policy statement of NCI or the National Institutes of Health (NIH).

Board members review recently published articles each month to determine whether an article should:

- be discussed at a meeting,
- be cited with text, or
- replace or update an existing article that is already cited.

Changes to the summaries are made through a consensus process in which Board members evaluate the strength of the evidence in the published articles and determine how the article should be included in the summary.

The lead reviewers for Childhood Astrocytomas Treatment are:

- Kenneth J. Cohen, MD, MBA (Sidney Kimmel Comprehensive Cancer Center at Johns Hopkins Hospital)
- Louis S. Constine, MD (James P. Wilmot Cancer Center at University of Rochester Medical Center)
- Karen J. Marcus, MD, FACR (Dana-Farber Cancer Institute/Boston Children's Hospital)
- Roger J. Packer, MD (Children's National Hospital)
- D. Williams Parsons, MD, PhD
- Malcolm A. Smith, MD, PhD (National Cancer Institute)

Any comments or questions about the summary content should be submitted to [Cancer.gov](#) through the NCI website's [Email Us](#). Do not contact the individual Board Members with questions or comments about the summaries. Board members will not respond to individual inquiries.

## Levels of Evidence

Some of the reference citations in this summary are accompanied by a level-of-evidence designation. These designations are intended to help readers assess the strength of the evidence supporting the use of specific interventions or approaches. The PDQ Pediatric Treatment Editorial Board uses a [formal evidence ranking system](#) in developing its level-of-evidence designations.

## Permission to Use This Summary

PDQ is a registered trademark. Although the content of PDQ documents can be used freely as text, it cannot be identified as an NCI PDQ cancer information summary unless it is presented in its entirety and is regularly updated. However, an author would be permitted to write a sentence such as “NCI’s PDQ cancer information summary about breast cancer prevention states the risks succinctly: [include excerpt from the summary].”

The preferred citation for this PDQ summary is:

PDQ® Pediatric Treatment Editorial Board. PDQ Childhood Astrocytomas Treatment. Bethesda, MD: National Cancer Institute. Updated <MM/DD/YYYY>. Available at: <https://www.cancer.gov/types/brain/hp/child-astrocytoma-treatment-pdq>. Accessed <MM/DD/YYYY>. [PMID: 26389382]

Images in this summary are used with permission of the author(s), artist, and/or publisher for use within the PDQ summaries only. Permission to use images outside the context of PDQ information must be obtained from the owner(s)

and cannot be granted by the National Cancer Institute. Information about using the illustrations in this summary, along with many other cancer-related images, is available in [Visuals Online](#), a collection of over 2,000 scientific images.

### **Disclaimer**

Based on the strength of the available evidence, treatment options may be described as either “standard” or “under clinical evaluation.” These classifications should not be used as a basis for insurance reimbursement determinations. More information on insurance coverage is available on Cancer.gov on the [Managing Cancer Care](#) page.

### **Contact Us**

More information about contacting us or receiving help with the Cancer.gov website can be found on our [Contact Us for Help](#) page. Questions can also be submitted to Cancer.gov through the website’s [Email Us](#).

### Copyright Notice

Bookshelf ID: NBK65944 PMID: [26389382](#)