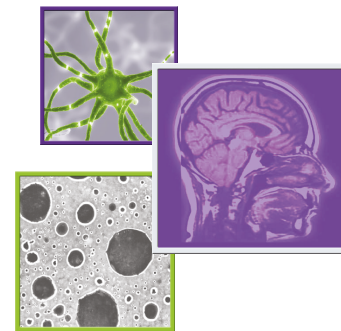









Prolonged response of recurrent *IDH*-wild-type glioblastoma to laser interstitial thermal therapy with pembrolizumab

Helen Hwang¹ , Jiayi Huang² , Karam Khaddour^{3,4} , Omar H Butt¹ , George Ansstas³ , Jie Chen^{5,6}, Ruth GN Katumba³ , Albert H Kim⁷ , Eric C Leuthardt⁷ & Jian L Campian^{*,3} 

¹Department of Neurology, Washington University School of Medicine, Saint Louis, MO 63110, USA

²Department of Radiation Oncology, Washington University School of Medicine, Saint Louis, MO 63110, USA

³Department of Medicine, Division of Oncology, Washington University School of Medicine, Saint Louis, MO 63110, USA

⁴Department of Medicine, Division of Hematology & Oncology, University of Illinois at Chicago, Chicago, IL 60607, USA

⁵Department of Pathology, Washington University School of Medicine, Saint Louis, MO 63110, USA

⁶Department of Pathology & Microbiology, University of Nebraska Medical Center, Omaha, NE 68198, USA

⁷Department of Neurosurgery, Washington University School of Medicine, Saint Louis, MO 63110, USA

*Author for correspondence: Campian.Jian@wustl.edu

Practice points

- The overall survival in glioblastoma remains dismal despite several ongoing clinical trials to evaluate approaches to improve outcomes.
- Clinical trials with immune checkpoint inhibitors have not demonstrated significant efficacy; however, research is ongoing to test novel approaches using immune checkpoint inhibitors.
- The combination of laser interstitial thermal therapy with immune checkpoint inhibitors might offer a benefit to patients with recurrent glioblastoma. However, further prospective trials (which are ongoing) are essential to validate this approach.

Despite the improved understanding of the molecular and genetic heterogeneity of glioblastoma, there is still an unmet need for better therapeutics, as treatment approaches have remained unchanged in recent years. Research into the role of the immune microenvironment has generated enthusiasm for testing immunotherapy (specifically, immune checkpoint inhibitors). However, to date, trials of immunotherapy in glioblastoma have not demonstrated a survival advantage. Combination approaches aimed at optimally inducing response to immune checkpoint inhibitors with radiotherapy are currently being investigated. Herein, the authors describe their experience of the potential benefit and clinical outcomes of using combination pembrolizumab (an immune checkpoint inhibitor) and laser interstitial thermal therapy in a case series of patients with recurrent *IDH*-wild-type glioblastoma.

First draft submitted: 13 August 2021; Accepted for publication: 15 December 2021; Published online: 19 January 2022

Keywords: glioblastoma • immune checkpoint inhibitors • immunotherapy • laser interstitial thermal therapy • pembrolizumab

Background

Glioblastoma (GBM) is considered one of the deadliest malignancies, with a median overall survival (OS) of less than 1 year [1]. The current standard of care for newly diagnosed GBM is maximal resection, followed by radiation therapy (RT) and temozolomide (TMZ) [2]. However, GBM ultimately recurs in all patients. To date, there is no standard of care therapy for recurrent GBM, and thus there is an unmet need for new, effective therapies. Immune checkpoint inhibitors (ICIs) are a class of medications that targets checkpoint proteins responsible for

Table 1. Patient and molecular characteristics.

	Patient 1	Patient 2	Patient 3
Age at diagnosis	60	59	58
KPS	90	90	70
Tumor type	GBM	GBM	GBM
<i>IDH1</i>	Wild-type (IHC and NGS)	Wild-type (IHC)	Wild-type (NGS)
<i>MGMT</i>	Methylated	Unmethylated	Methylated
TMB (mutations/Mb)	Unknown (28 at second biopsy 18 months after treatment)	Unknown	6
PD-L1 expression	Unknown	Unknown	100%
Initial systemic therapy	RT/TMZ	RT/TMZ and 1 cycle of adjuvant TMZ	RT/TMZ and 12 cycles of adjuvant TMZ
Second-line treatment	LITT and pembrolizumab	LITT and pembrolizumab	LITT and doxorubicin
Third-line treatment	N/A	N/A	LITT and pembrolizumab
Dexamethasone dose before LITT and pembrolizumab (mg/day)	1	0	0

GBM: Glioblastoma; IHC: Immunohistochemistry; KPS: Karnofsky Performance Status Scale; LITT: Laser interstitial thermal therapy; Mb: Megabase; N/A: No additional treatment; NGS: Next-generation sequencing; RT: Radiation therapy; TMB: Tumor mutational burden; TMZ: Temozolomide.

tumor evasion from immune surveillance. Pembrolizumab is a monoclonal antibody checkpoint inhibitor that blocks PD-1, a membrane receptor expressed on activated T-lymphocytes that induces anergy when bound to PD-L1 on tumor cells. This blockage leads to an enhanced anti-tumor response and has been shown to improve survival in multiple tumors such as melanoma and lung cancer, prompting further investigation of ICI efficacy in other tumors, including GBM [3,4]. However, the results of ICI treatment in primary and recurrent GBM have been disappointing [5–7]. Several factors have been implicated in this failure, including limited drug penetrance due to the blood–brain barrier (BBB), an immunosuppressive microenvironment and tumor heterogeneity in GBM. Therefore, ongoing research is trying to circumvent these obstacles by combining ICI with other treatment modalities [8]. Laser interstitial thermal therapy (LITT) is a minimally invasive neurosurgical technique that can achieve tumor cytoreduction by delivering thermal ablation [9]. LITT can also cause BBB disruption, which could allow tumor antigens to cross into peripheral blood and increase effector T-cell trafficking and infiltration into the tumor as well as allow otherwise impermeant drugs to enter the brain [9,10]. LITT has demonstrated immunostimulatory effects on the tumor microenvironment through the release of cytokines from tumor and immune cells, enhancement of antigen presentation and the improved function of cytotoxic CD8⁺ T-cells [11,12]. Here, the authors report their initial experience of three patients with recurrent *IDH*-wild-type GBM who were treated with LITT followed by pembrolizumab as compassionate use (Table 1).

Case series

Patient 1

A 60-year-old male presented with headache and nausea. Brain MRI showed a left temporal enhancing mass, for which the patient underwent left craniotomy with gross total resection and histopathology was consistent with GBM, *MGMT* promoter methylated, *IDH1* R132H negative by immunohistochemistry (IHC). He received standard RT (60 Gy in 30 fractions) with concurrent TMZ but did not receive adjuvant TMZ due to prolonged, severe cytopenia. After 18 months, he had disease progression shown on a brain MRI. The patient received LITT followed by 29 cycles of pembrolizumab (200 mg every 3 weeks for 22 weeks). The patient's follow-up brain MRI showed increased enhancing mass with edema concerning for tumor progression, which was biopsied (Figure 1). Pathology showed mixed pleomorphic tumor cells as well as hyalinized vessels consistent predominantly with treatment effect (Figure 2). Next-generation sequencing (NGS) was performed using the Foundation One CDx test (Foundation Medicine). NGS confirmed an *IDH*-wild-type tumor and revealed a hypermutated status with 28 mutations per megabase (Table 1). Therefore, the patient was restarted on pembrolizumab after LITT and received an additional 18 cycles. He later had another recurrence, so bevacizumab was added. However, he continued to deteriorate clinically, was placed on hospice care and passed away 4 months later.

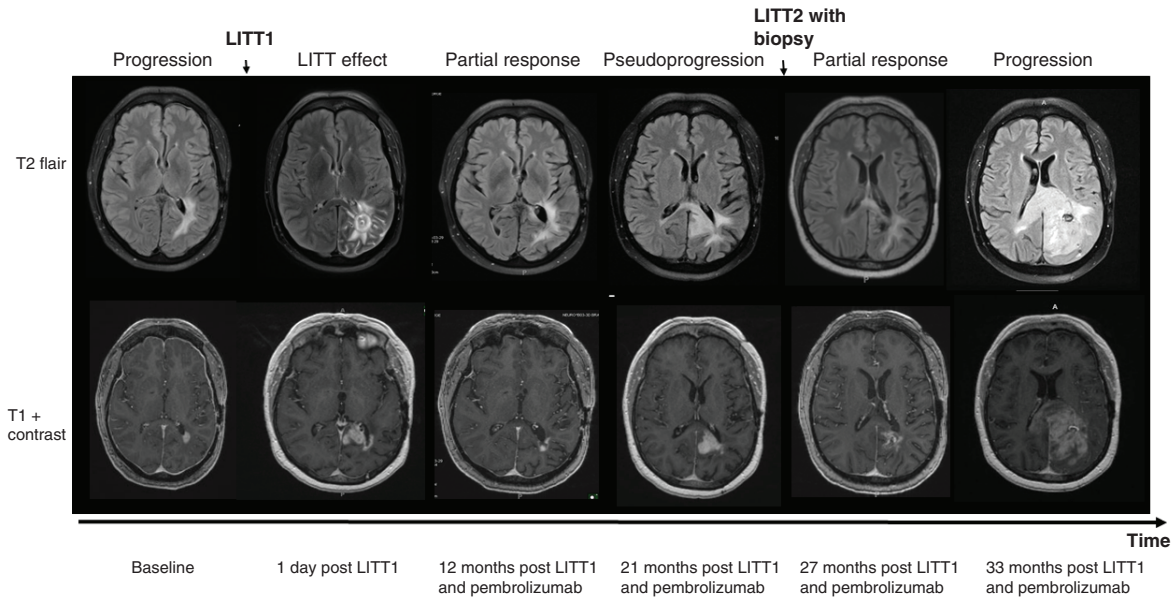


Figure 1. T2-weighted-Fluid-Attenuated Inversion Recovery (T2/FLAIR) (upper panel) and T1 weighted contrast enhancement (lower panel) brain MRI images taken at different times before and after laser interstitial thermal therapy treatment for patient 1. The patient’s baseline scan showed tumor progression. He received LITT followed by pembrolizumab. Pseudoprogession was noted and tested by repeat LITT with biopsy. Partial response was seen in the subsequent scans. The patient’s last MRI showed further progression of disease. LITT: Laser interstitial thermal therapy.

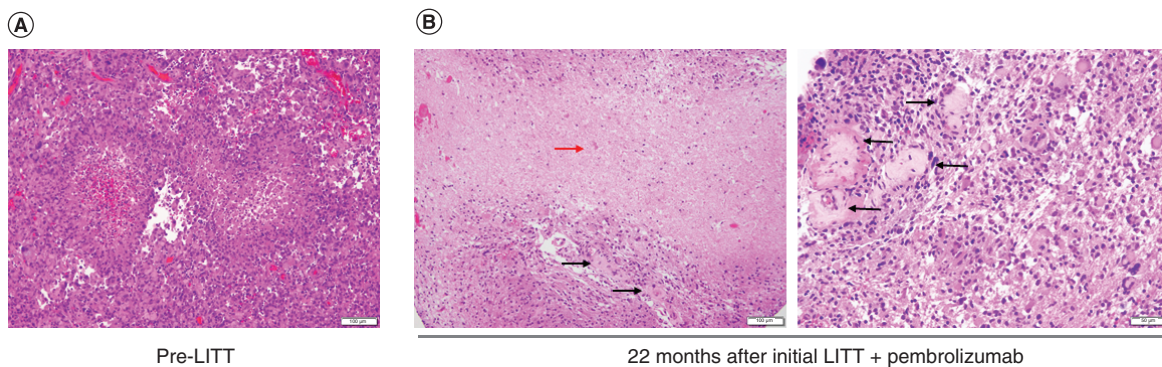


Figure 2. A representative image of the resection specimen at initial diagnosis of patient 1 showing pleomorphic glial cells with palisading necrosis consistent with glioblastoma. (A) A biopsy taken after recurrence (22 months after the initial LITT treatment) shows large areas of geographic necrosis (red arrows) and many hyalinized vessels (black arrows) consistent with treatment effect. **(B)** Tumor cells are also present. LITT: Laser interstitial thermal therapy.

Patient 2

A 59-year-old woman presented with partial seizures, expressive aphasia and numbness in her left upper extremity. Brain MRI showed a right frontal lobe enhancing mass. She had total resection with histopathology consistent with GBM, *MGMT* promoter unmethylated, *IDH1* R132H negative by IHC. She received standard RT and concurrent TMZ, followed by adjuvant TMZ. Her tumor progressed after 2 months and she underwent LITT followed by pembrolizumab (200 mg every 3 weeks). Her treatment course was complicated by hypertension and deep vein thrombosis. Pembrolizumab was stopped after 8 cycles, as the patient opted out of receiving treatment. At the time of stopping pembrolizumab, there was no clinical or radiological evidence of progression. She passed away 12 months after recurrence.

Table 2. Response and clinical outcomes.

	Patient 1	Patient 2	Patient 3
Number of pembrolizumab cycles received after LITT	47	8	7
Reason to stop	Progression	Patient choice	Progression versus pseudoprogression
Best response	Partial response	Partial response	Stable disease
Salvage therapy after LITT and pembrolizumab	Bevacizumab	N/A	RT and TMZ
PFS since treatment with LITT and pembrolizumab (months)	33	12	7
OS since LITT and pembrolizumab (months)	40	12	NR (>29 months at data cut-off)

LITT: Laser interstitial thermal therapy; N/A: No additional treatment; NR: No recurrence; OS: Overall survival; PFS: Progression-free survival; RT: Radiation therapy; TMZ: Temozolomide.

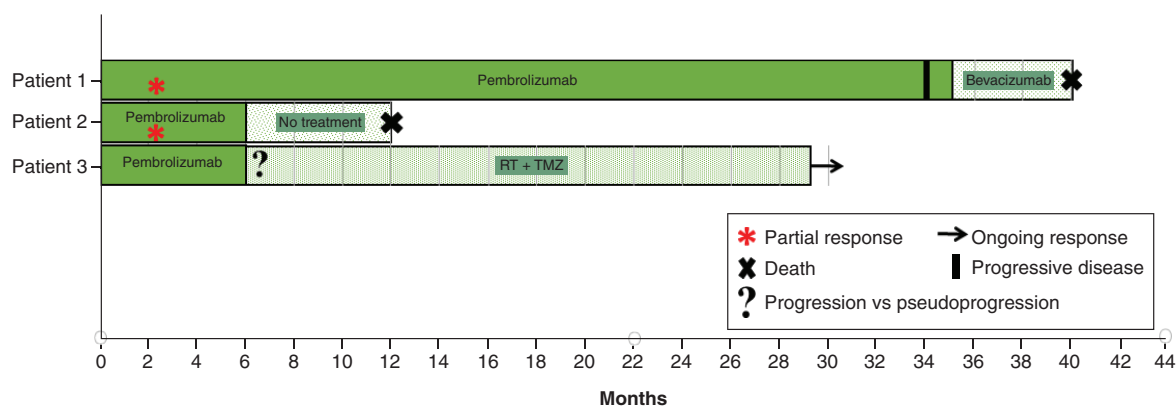


Figure 3. Swimmer plots for recurrent glioblastoma patients receiving laser interstitial thermal therapy and pembrolizumab. Bar length indicates duration of response and survival since receiving treatment at recurrence. RT: Radiation therapy; TMZ: Temozolomide.

Patient 3

A 58-year-old woman presented with left-side numbness and difficulty with coordination. Brain MRI showed an enhancing mass in the right parietal lobe. She had a craniotomy with subtotal resection and debulking of the tumor. Pathology showed GBM, *MGMT* promoter methylated, *IDH*-wild-type by NGS. She received standard RT and concurrent TMZ, followed by adjuvant TMZ for 12 cycles. She had disease progression after 22 months. She was enrolled in an institutional study, which included laser ablation followed by 6 cycles of weekly doxorubicin, but was found to have disease progression during treatment. After the second recurrence, the patient was treated with LITT followed by 8 cycles of pembrolizumab (200 mg every 3 weeks) as compassionate use. A follow-up brain MRI demonstrated tumor progression versus pseudoprogression. At that time, the patient decided to discontinue pembrolizumab and was re-treated with RT and TMZ. To date, she has remained clinically and radiologically stable and is doing well (29 months since LITT and pembrolizumab).

Discussion

In this report, three patients diagnosed with recurrent *IDH*-wild-type GBM were treated with LITT followed by pembrolizumab until progression (Table 1). Two of three patients had partial responses and showed promising progression-free survival (PFS) (Table 2). PFS ranged from 7 to 33 months, versus 2.9 to 4 months reported by previous studies that combined surgery with anti-PD-1 immunotherapy [13,14]. Likewise, OS for the patients in the current study were 12 months, 40 months and not reached (still living >29 months). In contrast, the Checkmate-143 trial demonstrated a median OS of 9.8 months in patients with recurrent GBM who were treated with nivolumab (another PD-1 inhibitor) [5], and another trial of pembrolizumab in the recurrent setting reported a median OS of 8.8 months [7]. These patients highlight three examples of impressive, prolonged and durable response with LITT followed by pembrolizumab in patients with recurrent GBM (Figure 3). Furthermore, standard dosing of pembrolizumab appeared to be safe after LITT without any unexpected toxicity. Together these findings suggest that a larger prospective trial is warranted to investigate the immunological effects of LITT on recurrent GBM.

Currently, it remains unclear which patients with CNS tumors will benefit most from PD-1 inhibitors. Tissue PD-L1 expression and tumor mutational burden (TMB) are two possible candidates, with correlation observed in certain tumors [15]. Unfortunately, in the present study, PD-L1 expression and TMB were only known for one patient, limiting further inferences of association. This is a major limitation of the study and highlights the critical need for validated predictive biomarkers for response in GBM patients.

A well-established biomarker for response to alkylating chemotherapy is a GBM's *MGMT* promoter methylation status. *MGMT* is crucial for DNA repair and methylation of its promoter region can predict sensitivity to TMZ [16]. In the present study, patients 1 and 3 with *MGMT* promoter methylation had much longer OS than patient 2, who was *MGMT* promoter unmethylated. Whether improved survival was a consequence of earlier treatment with alkylating chemotherapy or possible increased mutation burden [17–19] remains unknown and is a second major limitation of the study. Future studies may need to investigate if *MGMT* promoter methylation may also predispose recurrent GBM to anti-PD-1-mediated immune response.

Finally, the mechanism underlying improved survival when combining LITT with anti-PD-1 immunotherapy remains unknown. LITT is based on highly localized thermal ablation of target lesions using an MRI-guided, minimally invasive procedure [20–24]. Following LITT, prolonged permeability changes to the BBB in the peritumoral region have been reported [9,10,25]. This may improve immune cell infiltration and promote maturation [11] or improve CNS drug delivery [9,10], though further studies are needed. Interestingly, it has been suggested that LITT can enhance *in situ* immunization in GBM and potentiate the anti-tumor effect conferred by ICI [26].

Conclusion

This case series describes three patients who had exceptional clinical and radiographic responses with the combination of LITT and pembrolizumab. These findings suggest that PD-1 inhibition in combination with LITT is a promising, innovative treatment for recurrent GBM in a subset of patients. The authors' institution is leading an ongoing phase 2 study using LITT and pembrolizumab for patients with recurrent GBM (ClinicalTrials.gov identifier: NCT02311582), which will provide further insight into the safety and efficacy of this approach.

Author contributions

H Hwang, K Khaddour and JL Campian conceptualized the manuscript. H Hwang, OH Butt, K Khaddour and JL Campian revised the manuscript. H Hwang, K Khaddour and OH Butt performed chart review and collected data. OH Butt, H Hwang, J Huang, G Anstas, J Chen, RGN Katumba, AH Kim, EC Leuthardt and JL Campian took care of patients. H Hwang, J Huang, K Khaddour, OH Butt and JL Campian supervised the work.

Financial & competing interests disclosure

The authors have no relevant affiliations or financial involvement with any organization or entity with a financial interest in or financial conflict with the subject matter or materials discussed in the manuscript. This includes employment, consultancies, honoraria, stock ownership or options, expert testimony, grants or patents received or pending, or royalties.

No writing assistance was utilized in the production of this manuscript.

Ethical conduct of research

The authors state that they have obtained verbal and written informed consent from the patient/patients for the inclusion of their medical and treatment history within this case report.

Open access

This work is licensed under the Attribution-NonCommercial-NoDerivatives 4.0 Unported License. To view a copy of this license, visit <http://creativecommons.org/licenses/by-nc-nd/4.0/>

References

Papers of special note have been highlighted as: ● of interest; ●● of considerable interest

1. Ostrom QT, Gittleman H, Xu J *et al.* CBTRUS statistical report: primary brain and other central nervous system tumors diagnosed in the United States in 2009–2013. *Neuro. Oncol.* 18(Suppl. 5), v1–v75 (2016).
2. Stupp R, Mason WP, van den Bent MJ *et al.* Radiotherapy plus concomitant and adjuvant temozolomide for glioblastoma. *N. Engl. J. Med.* 352(10), 987–996 (2005).
3. Hui E. Immune checkpoint inhibitors. *J. Cell Biol.* 218(3), 740–741 (2019).

4. Matias D, Balça-Silva J, da Graça GC *et al.* Microglia/astrocytes-glioblastoma crosstalk: crucial molecular mechanisms and microenvironmental factors. *Front. Cell Neurosci.* 12, 235 (2018).
5. Reardon DA, Brandes AA, Omuro A *et al.* Effect of nivolumab vs bevacizumab in patients with recurrent glioblastoma: the CheckMate 143 phase 3 randomized clinical trial. *JAMA Oncol.* 6(7), 1–8 (2020).
 - **A randomized trial of nivolumab versus bevacizumab in recurrent glioblastoma, which showed lower objective response rates in patients receiving nivolumab and similar median overall survival compared to the bevacizumab arm.**
6. Sampson JH, Omuro AM, Preusser M *et al.* A randomized, phase 3, open-label study of nivolumab versus temozolomide (TMZ) in combination with radiotherapy (RT) in adult patients (pts) with newly diagnosed, O-6-methylguanine DNA methyltransferase (MGMT)-unmethylated glioblastoma (GBM): CheckMate-498. *J. Clin. Oncol.* TPS2079 (2016).
 - **An ongoing, randomized clinical trial to assess the efficacy of nivolumab versus temozolomide and radiotherapy in the front-line setting of glioblastoma with MGMT unmethylation.**
7. Reardon DA, Nayak L, Peters KB *et al.* Phase II study of pembrolizumab or pembrolizumab plus bevacizumab for recurrent glioblastoma (rGBM) patients. *J. Clin. Oncol.* 2006 (2018).
8. Khaddour K, Johanns TM, Anstas G. The landscape of novel therapeutics and challenges in glioblastoma multiforme: contemporary state and future directions. *Pharmaceuticals* 13(11), E389 (2020).
 - **A review of immunotherapy in glioblastoma and current approaches being utilized to test the efficacy of immune checkpoint inhibitors in glioblastoma.**
9. Leuthardt EC, Duan C, Kim MJ *et al.* Hyperthermic laser ablation of recurrent glioblastoma leads to temporary disruption of the peritumoral blood brain barrier. *PLoS One* 11(2), e0148613 (2016).
 - **A pilot study providing a proof of concept on the utility of hyperthermic laser ablation in peritumoral blood–brain barrier disruption, which could offer a window of opportunity in administering impermeable anti-glioblastoma medication.**
10. Salehi A, Paturu MR, Patel B *et al.* Therapeutic enhancement of blood–brain and blood–tumor barriers permeability by laser interstitial thermal therapy. *Neurooncol. Adv.* 2(1), vdaa071 (2020).
 - **A study in mouse models showing that laser interstitial thermal therapy can increase blood–brain barrier permeability to systemic therapy.**
11. Srinivasan ES, Sankey EW, Grabowski MM, Chongsathidkiet P, Fecci PE. The intersection between immunotherapy and laser interstitial thermal therapy: a multipronged future of neuro-oncology. *Int. J. Hyperthermia* 37(2), 27–34 (2020).
 - **A review article of the possible advantage of combination therapy of laser interstitial therapy with immune checkpoint inhibitors.**
12. Vogl TJ, Naguib NN, Zangos S, Eichler K, Hedayati A, Nour-Eldin NE. Liver metastases of neuroendocrine carcinomas: interventional treatment via transarterial embolization, chemoembolization and thermal ablation. *Eur. J. Radiol.* 72(3), 517–528 (2009).
13. Cloughesy TF, Mochizuki AY, Orpilla JR *et al.* Neoadjuvant anti-PD-1 immunotherapy promotes a survival benefit with intratumoral and systemic immune responses in recurrent glioblastoma. *Nat. Med.* 25(3), 477–486 (2019).
14. Schalper KA, Rodriguez-Ruiz ME, Diez-Valle R *et al.* Neoadjuvant nivolumab modifies the tumor immune microenvironment in resectable glioblastoma. *Nat. Med.* 25(3), 470–476 (2019).
15. Riviere P, Goodman AM, Okamura R *et al.* High tumor mutational burden correlates with longer survival in immunotherapy-naïve patients with diverse cancers. *Mol. Cancer Ther.* 19(10), 2139–2145 (2020).
16. Hegi ME, Diserens AC, Gorlia T *et al.* MGMT gene silencing and benefit from temozolomide in glioblastoma. *N. Engl. J. Med.* 352, 997–1003 (2005).
17. Johnson BE, Mazon T, Hong C *et al.* Mutational analysis reveals the origin and therapy-driven evolution of recurrent glioma. *Science* 343(6167), 189–193 (2014).
18. Hunter C, Smith R, Cahill DP *et al.* A hypermutation phenotype and somatic MSH6 mutations in recurrent human malignant gliomas after alkylator chemotherapy. *Cancer Res.* 66(8), 3987–3991 (2006).
19. Wang J, Cazzato E, Ladewig E *et al.* Clonal evolution of glioblastoma under therapy. *Nat. Genet.* 48(7), 768–776 (2016).
20. Bastos DCA, Rao G, Oliva ICG *et al.* Predictors of local control of brain metastasis treated with laser interstitial thermal therapy. *Neurosurgery* 87(1), 112–122 (2020).
21. Hernandez RN, Carminucci A, Patel P, Hargreaves EL, Danish SF. Magnetic resonance-guided laser-induced thermal therapy for the treatment of progressive enhancing inflammatory reactions following stereotactic radiosurgery, or PEIRs, for metastatic brain disease. *Neurosurgery* 85(1), 84–90 (2019).
22. Kamath AA, Friedman DD, Hacker CD *et al.* MRI-guided interstitial laser ablation for intracranial lesions: a large single-institution experience of 133 cases. *Stereotact. Funct. Neurosurg.* 95(6), 417–428 (2017).
23. Kim AH, Tatter S, Rao G *et al.* Laser ablation of abnormal neurological tissue using robotic NeuroBlate system (LAANTERN): 12-month outcomes and quality of life after brain tumor ablation. *Neurosurg.* 87(3), e338–e346 (2020).
24. Shao J, Radakovich NR, Grabowski M *et al.* Lessons learned in using laser interstitial thermal therapy for treatment of brain tumors: a case series of 238 patients from a single institution. *World Neurosurg.* 139, e345–e354 (2020).

- **A case series providing insight into the efficacy of laser interstitial therapy in the field of neuro-oncology.**
- 25. Butt OH, Zhou AY, Huang J *et al.* A Phase II study of laser interstitial thermal therapy combined with doxorubicin in patients with recurrent glioblastoma. *Neurooncol. Adv.* 3(1), vtab164 (2021).
- **A prospective clinical trial showing that recurrent glioblastoma treated with laser interstitial thermal therapy (LITT) and brain impenetrant doxorubicin is associated with improved survival compared to LITT alone.**
- 26. Shin DH, Melnick KF, Tran DD, Ghiaseddin AP. *In situ* vaccination with laser interstitial thermal therapy augments immunotherapy in malignant gliomas. *J. Neurooncol.* 151(1), 85–92 (2021).
- **A review providing insight into the possible immunogenic effect intratumorally of laser interstitial therapy.**