

Case Report

# BRAF V600E-Mutant Glioblastoma with Extracranial Metastases Responsive to Combined BRAF and MEK Targeted Inhibition: A Case Report

Vasu Munjapara<sup>a</sup> Thatcher Heumann<sup>a</sup> Karisa C. Schreck<sup>a, b</sup>  
John M. Gross<sup>c</sup> Carlos Perez-Heydrich<sup>a</sup> Sachin K. Gujar<sup>d</sup>  
Charles G. Eberhart<sup>c</sup> Matthias Holdhoff<sup>a, b</sup>

<sup>a</sup>Department of Oncology, The Johns Hopkins University School of Medicine, Baltimore, MD, USA; <sup>b</sup>Department of Neurology, The Johns Hopkins University School of Medicine, Baltimore, MD, USA; <sup>c</sup>Department of Pathology, The Johns Hopkins University School of Medicine, Baltimore, MD, USA; <sup>d</sup>Department of Radiology, The Johns Hopkins University School of Medicine, Baltimore, MD, USA

## Keywords

Glioblastoma · BRAF V600E-mutant · Metastatic · Targeted therapy · Actionable mutation

## Abstract

Recent advancements in understanding the biology of glioblastomas (GBM) and increasing adoption of genomic sequencing in oncology practice have led to the discovery of several targetable mutations in these cancers. Among them, the BRAF V600E mutation can be found in approximately 3% of GBM. Despite the aggressive nature of GBM, metastatic disease is rarely observed. While there are growing data utilizing BRAF-targeting strategies in patients with GBM, data examining their efficacy in cases of metastatic GBM are lacking. We present the case of a 46-year-old female with GBM, isocitrate dehydrogenase (IDH)-wildtype and O<sup>6</sup>-methylguanine-DNA methyltransferase promoter (MGMT) unmethylated, BRAF V600E-mutant, and MYC amplified with extra-central nervous system spread to the spine and lung. Four months after completion of treatment with standard chemoradiation and temozolomide, the patient developed severe back pain, leading to the eventual discovery of her metastatic disease. Based on the presence of the BRAF V600E mutation, the patient was treated with and achieved an intracranial and systemic response to combination BRAF-MEK targeted inhibition for 9 months before evidence of progression.

© 2022 The Author(s).  
Published by S. Karger AG, Basel

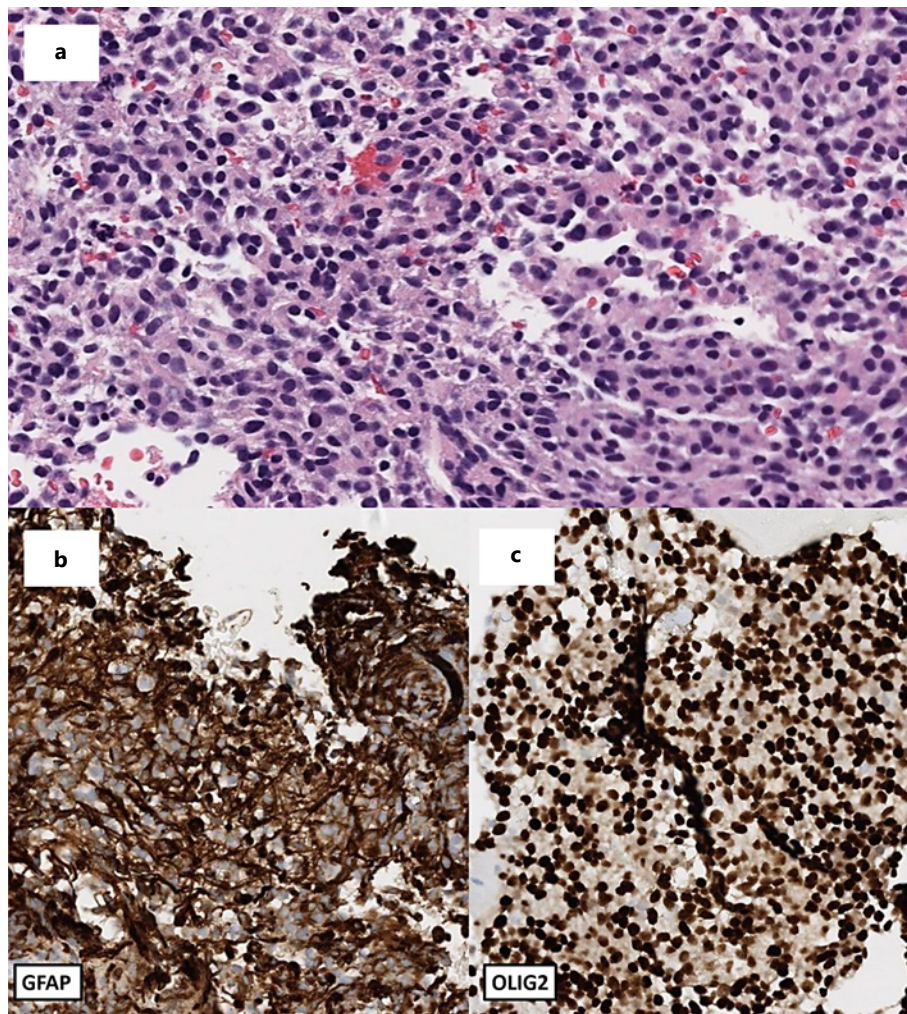
Correspondence to:  
Matthias Holdhoff, [mholdho1@jhmi.edu](mailto:mholdho1@jhmi.edu)

## Introduction

Glioblastoma (GBM) is the most frequently occurring malignant primary adult brain cancer. Despite aggressive treatment with surgery, radiation, and temozolomide and decades of clinical research, the prognosis of these patients has remained poor, and virtually all patients die of their disease. Over the past decade, there have been multiple studies identifying the genetic landscape of GBMs; however, only few potentially targetable genetic alterations have been identified. Importantly, 3% of GBMs harbor a mutation in BRAF V600E. The clinical benefit of targeting BRAF V600E with small molecule tyrosine kinase inhibitors has been demonstrated across a number of solid tumors, including melanoma, lung, and colon cancers [1, 2]. Here we present a case of a 46-year-old female with an IDH-wildtype, O<sup>6</sup>-methylguanine-DNA methyltransferase promoter (MGMT) unmethylated GBM that was found to be BRAF V600E-mutant and MYC amplified, with osseous and pulmonary metastases treated with BRAF/MEKi combination therapy.

## Case Report

The patient is a 46-year-old previously healthy female who initially presented with loss of consciousness and in status epilepticus. Head CT revealed a left parietal intraparenchymal hematoma (5.3 × 4.1 × 4.1 cm) with an underlying well-circumscribed hyperdensity suggestive of a mass with associated edema, causing 8 mm midline shift and left uncal herniation. The patient was taken for emergent surgery for hematoma evacuation and partial resection of her left parafalcine parieto-occipital mass. Post-op brain MRI showed a residual 3.2 × 2.7 × 3.8 cm enhancing mass. Pathology revealed a densely cellular, astrocytic infiltrative tumor consistent with a diagnosis of WHO grade IV glioma, IDH-wildtype, MGMT promoter unmethylated. Subsequent chromosomal microarray and sequencing studies revealed a BRAF V600E mutation, TERT and MYC amplifications, and CDKN2A/B loss. She received standard-of-care concurrent chemoradiation (ccRT) with 60 Gy in 30 fractions and temozolomide 75 mg/m<sup>2</sup> daily during radiation for a total of 6 weeks. After discussion with the patient, given her IDH-wildtype status and unmethylated MGMT promoter, consideration of toxicities, and in the context of the COVID-19 pandemic, she did not receive further adjuvant temozolomide. In the months that followed, her brain imaging remained stable and, with intensive rehabilitation, the patient experienced significant motor and cognitive recovery. At 8 months from her diagnosis, she began experiencing focal mid-level back pain that progressed over the next 2 months despite physical therapy and conventional symptomatic management. Spinal MR imaging showed diffuse tumor involvement of the C6, T2, T6, T9, T11, and L3 vertebrae with pathologic fractures and epidural extension with thecal sac compression at T6, T9. The patient subsequently underwent palliative kyphoplasty, diagnostic biopsy, and microwave ablation. Pathology from a right T11 pedicle lesion was consistent with metastasis from her GBM with immunohistochemistry showing positivity for GFAP, OLIG2, and BRAF V600E (Fig. 1, 2). She was later readmitted for pain control via palliative radiation to her thoracic spine (30 Gy in 10 fractions). Interval brain and spinal imaging demonstrated progressive disease. PET-CT revealed additional FDG-avid foci in the hip and right lung consistent with additional extracranial GBM metastases. Because of the targetable nature of BRAF V600E, she was initiated on combination BRAF/MEK inhibition with dabrafenib 150 mg twice daily and trametinib 2 mg daily, 11 months after her initial diagnosis. First on-treatment interval scans demonstrated partial radiographic response with interval reduction in tumor volumes within the brain and throughout the spine (Fig. 3). Additionally, the right lung lesion was no longer present. She tolerated therapy well without adverse symptoms. A single dose reduction was required for grade 3 neutropenia. Approximately 9 months into her targeted therapy course, her brain parenchyma remained stable, but, unfortunately, she developed a new

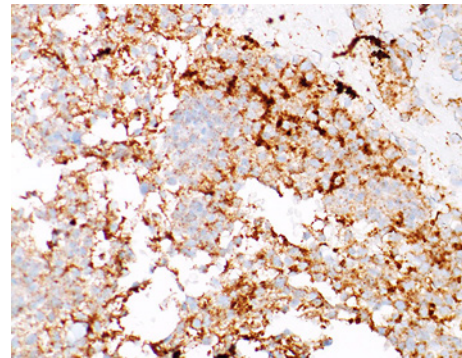


**Fig. 1.** **a** Histologic section from a biopsy of a right T11 pedicle lesion revealing a primitive neoplasm with smooth chromatin and fine fibrillary background. Immunohistochemistry shows positivity for GFAP and OLIG2 (**b, c**). Additionally, the same cells were negative for desmin, CD99, CD138, CD45, synaptophysin, and chromogranin. WT-1 revealed cytoplasmic expression and cytokeratin AE1/AE3 showed variable reactivity representing aberrant antigen cross-reactivity.

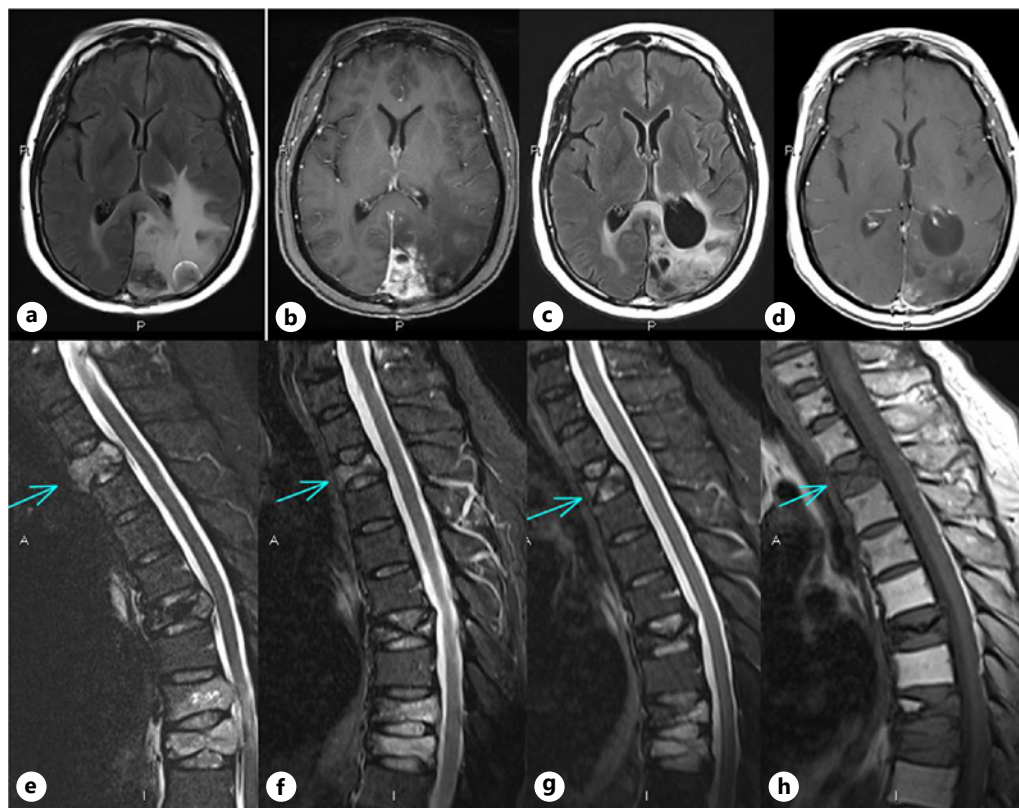
L5 vertebral metastasis extending laterally into her left psoas muscle. Despite a course of focal palliative radiation to this area and one cycle on single agent temozolomide, her metastatic burden quickly progressed with diffuse osseous infiltration, recurrence in the cerebral resection cavity, as well as worsening pulmonary metastases. Given her unmethylated status, disease burden, and rate of progression, the patient opted for a transition to hospice care. She died 13.5 months after initiating targeted therapy and 24 months after her original diagnosis.

### Discussion

This case report documents a rare presentation of a metastatic BRAF V600E-mutant GBM with extracranial spread that is responsive to combination BRAF/MEK inhibition therapy. This case is unique due to extracranial metastases of a GBM and the presence of



**Fig. 2.** Histologic section from biopsy of a right T11 pedicle lesion (biopsy sample same as in Fig. 2) with immunohistochemistry showing positivity for BRAF V600E.



**Fig. 3.** MR images of the brain (upper panel) and sections of the spine (lower panel) demonstrating a radiographic response to combined BRAF and MEK targeted inhibition with dabrafenib and trametinib. T2/FLAIR (a, c) and T1 post-contrast (b, d) images of the brain show reduction in both extent of T2/FLAIR signal and contrast enhancement in response to treatment. A response to treatment was also seen in the thoracic spine (e-h). A measurable lesion is marked with an arrow. Note that the more caudal lesions had been previously irradiated, rendering assessment of response to dabrafenib and trametinib inconclusive.

a BRAF V600E mutation. Her clinical course highlights the potential benefit of BRAF-targeted therapy in advanced GBM, and we discuss here the potential effect of MYC amplification on response and progression.

While seemingly rare, extracranial metastases in GBM are an ominous portent [3]. The method of extracranial spread is largely unknown. Risk factors include surgical intervention, younger age at diagnosis, and increased time since diagnosis. Potential mechanisms include

hematogenous spread via tumorous neovascularization and lymphatic spread [4]. The most common areas of extracranial spread include bone (38%), lymph nodes (37%), lungs (32%), and liver (18%), with a median survival time from diagnosis to death of 13 months [3]. While most cases of osseous metastases are asymptomatic, our patient developed multiple osseous lesions that presented as arthralgias in the thoracic spine and progressed into crippling back pain. In addition to diffuse vertebral involvement, our patient also developed a lung metastasis. In a retrospective study that evaluated survival in 83 patients with extracranial metastases, 25 had lung metastases and their presence was associated with inferior prognosis when compared to other extracranial metastases of GBM [5].

While uncommon in GBM, BRAF V600E mutations are increasingly detected given the growing ubiquity of genomic sequencing; only approximately 3% of all GBM harbor BRAF V600E alterations; BRAF mutations in GBM are more commonly found in adults <45 years of age [6]. In young adults, aged 17–35 a retrospective study demonstrated a median survival of 43.2 months for BRAF-mutated GBM compared to 13.2 months for BRAF wildtype [7]. Similar data, though smaller in sample size, have been seen in adults >35 years with a median survival of  $34.5 \pm 12.1$  months compared to 18 months in case-matched controls [8].

Responses to BRAF or BRAF/MEK inhibitors in GBM have been previously reported, but published data are rare, and there has to-date only been 1 case of metastatic BRAF-mutant GBM treated with BRAF-targeted therapy. This was a patient with BRAF-mutant epithelioid GBM with evidence of bilateral lung metastases who responded to vemurafenib therapy within a week, as evidenced by a reduction in paramediastinal and perihilar opacities, though brain MRI revealed worsening brain disease and the patient passed shortly thereafter [9]. It is currently unclear what, if any, relationship exists between BRAF mutations and the metastatic potential of GBM.

A notable aspect of this patient's tumor genetics was the amplification of MYC. While not specified in the gene sequencing report, the patient likely had an amplification of c-MYC given 8q amplification. MYC acts as a protooncogene due to its effects on cellular proliferation, halting differentiation, increasing cell migration, and inducing angiogenesis, among other functions. There are no cases of BRAF V600E and MYC amplification in the records of 730 GBM in cBioPortal; however, 8/730 (1.1%) harbored the BRAF V600E mutation and 12/730 (1.64%) harbored MYC amplification [10, 11]. Interestingly, MYC amplification is more common in GBM with a primitive neuronal component, a sub-type of GBM with relatively high rates of spinal metastasis and CSF dissemination [12]. In melanoma, MYC activation is necessary and sufficient for resistance to BRAFi/MEKi. Preclinical work combining BRAFi and MYC suppression resulted in delayed BRAFi resistance in *in vivo* models of melanoma [13]. While our patient initially responded to BRAFi, the emergent resistance could be related to MYC amplification, among other possible mechanisms [1].

Optimal implementation of targeted treatment for BRAF-mutant GBM is an area of ongoing clinical research. Early basket studies in recurrent GBM and other BRAF-mutant primary brain tumors demonstrated encouraging clinical benefit. VE-BASKET, a study evaluating vemurafenib monotherapy included 6 patients with GBM, with a best response of stable disease in 1 patient for 12.9 months and two others with brief responses [14]. ROAR, a basket study of dabrafenib and trametinib, is the largest reported cohort of BRAF-mutant GBM/HGG. In an interim analysis of 45 adult patients with high-grade gliomas (HGG), treatment with dabrafenib (150 mg twice daily) and trametinib (2 mg daily) resulted in an overall response rate of 33% (including 3 complete responses, 12 partial responses) [15]. A compilation of ongoing clinical trials evaluating combination BRAF/MEKi therapy in HGG can be found in Table 1. There are ongoing studies examining BRAF-targeted therapy combined with XRT (NCT03919071) and adding autophagy inhibitors (NCT04201457) as a possible strategy for overcoming secondary targeted therapy resistance. Examining the timing of targeted therapy utilization, assessing possible additive benefits to the frontline standard of care, and testing next generation TKIs

**Table 1.** Current and ongoing studies evaluating combination BRAF/MEKi therapy in HGG

Study title	NCT	Primary outcome	Treatment	Stage
A Phase II Study of Binimetinib in Combination With Encorafenib in Adults With Recurrent BRAF V600-Mutated High-Grade Astrocytoma or Other Primary Brain Tumor	NCT03973918	Tumor radiographic response per RANO for 3 treatment cohorts	Encorafenib 450 mg QD 28 day cycle Binimetinib 45 mg BID 28 day cycle	Recruitment: Estimated 62 participants
A Phase 2 Study of Dabrafenib With Trametinib After Local Irradiation in Newly-Diagnosed BRAF V600-Mutant High-Grade Glioma (HGG)	NCT03919071	Event-free survival	Four weeks after completion of RT, patients receive dabrafenib mesylate PO BID and trametinib dimethyl sulfoxide PO QD on days 1–28 Treatment repeats every 28 days for up to 24 cycles in the absence of disease progression or unacceptable toxicity	Recruitment: Estimated 58 participants
A Phase II, Open-label, Study in Subjects With BRAF V600E-Mutated Rare Cancers With Several Histologies to Investigate the Clinical Efficacy and Safety of the Combination Therapy of Dabrafenib and Trametinib	NCT02034110	ORR	Dabrafenib 150 mg twice daily orally Trametinib 2 mg once daily Treatment cycles 28 days	Estimated primary completion date: August 27, 2021
Phase II Open-label Global Study to Evaluate the Effect of Dabrafenib in Combination With Trametinib in Children and Adolescent Patients With BRAF v600 Mutation Positive Low Grade Glioma (LGG) or Relapsed or Refractory High-Grade Glioma (HGG)	NCT02684058	HGG cohort: ORR	Dabrafenib oral, twice daily Trametinib oral, once daily	Active: 150 participants
Phase I/II Trial of Dabrafenib, Trametinib, and Hydroxychloroquine (HCQ) for BRAF V600E-mutant or Trametinib and HCQ for BRAF Fusion/Duplication Positive or NF1-associated Recurrent or Progressive Gliomas in Children and Young Adults	NCT04201457	Maximum tolerated dose (MTD)/Recommended phase 2 dose (RP2D) (Time frame: approximately 28 days from start of therapy) Maximum plasma concentration (Time frame: 1–4 days) Area under the curve (AUC) (Time frame: 1–4 days) Phase II: sustained objective response rate. (Time frame: up to approximately 2 years from the start of therapy)	Dabrafenib Trametinib Hydroxychloroquine	Recruiting: Estimated 75 participants

**Table 1** (continued)

Study title	NCT	Primary outcome	Treatment	Stage
Molecularly-Driven Doublet Therapy for All Children With Refractory or Recurrent CNS Malignant Neoplasms and Young Adults With Refractory or Recurrent SHH Medulloblastoma	NCT03434262	Estimate the maximum tolerated dose (MTD)/Recommended phase 2 dose (RP2D) of each doublet by stratum Pharmacokinetics of combination treatment	Ribociclib Trametinib	Recruiting: Estimated 108 participants
ORR: overall response rate.				

to overcome resistance mechanisms will be important areas of research in the years to come for patients with BRAF-mutated HGG.

## Conclusion

We present a rare case of a patient with metastatic GBM containing BRAF V600E mutation and MYC amplification who responded to a combination of dabrafenib and trametinib for 9 months before evidence of progression. While the potential links between BRAF mutation and the metastatic potential of GBM remain unknown, our patient's initial radiographic response to targeted therapy demonstrates that targeted therapy can be beneficial in advanced, extracranially disseminated GBM. This case, along with early phase clinical trial experiences, has instilled hope in improving standard-of-care treatment options for this subset of GBM patients. The patient's emergent resistance highlights the importance of ongoing work to understand mechanisms of resistance and develop further lines of treatment.

## Statement of Ethics

This case report was acknowledged by the Institutional Review Board at the Johns Hopkins Medical Institutions (IRB00317558; acknowledged 1/25/2022). Written informed consent was obtained from the patient's next of kin for publication of the details of their medical case and any accompanying images.

## Conflict of Interest Statement

The authors declare that they have no competing interests.

## Funding Sources

This work was supported by the Sidney Kimmel Comprehensive Cancer Center Core Grant P30CA006973. The funders had no role in study design, data collection and analysis, decision to publish, or preparation of the manuscript.

## Author Contributions

Vasu Munjapara, Matthias Holdhoff, and Thatcher Heumann: data collection, data analysis, literature review, writing of manuscript; reading, editing and approval of final manuscript. Karisa C. Schreck, Carlos Perez-Heydrich, and Charles G. Eberhart: data analysis, literature review, editing of manuscript; reading, editing and approval of final manuscript. John M. Gross and Sachin K. Gujar: data collection, data analysis; reading, editing and approval of final manuscript.

## Data Availability Statement

All data generated or analyzed during this study are included in this article. Further inquiries can be directed to the corresponding author.



## References

- Schreck KC, Morin A, Zhao G, Allen AN, Flannery P, Glantz M, et al. Deconvoluting mechanisms of acquired resistance to RAF inhibitors in BRAFV600E-mutant human glioma. *Clin Cancer Res*. 2021 Nov 15;27(22):6197–208.
- Halle BR, Johnson DB. Defining and targeting BRAF mutations in solid tumors. *Curr Treat Options Oncol*. 2021 Feb 27;22(4):30.
- Kalokhe G, Grimm SA, Chandler JP, Helenowski I, Rademaker A, Raizer JJ. Metastatic glioblastoma: case presentations and a review of the literature. *J Neurooncol*. 2012 Mar;107(1):21–7.
- Müller C, Holtschmidt J, Auer M, Heitzer E, Lamszus K, Schulte A, et al. Hematogenous dissemination of glioblastoma multiforme. *Sci Transl Med*. 2014 Jul 30;6(247):247ra101.
- Lun M, Lok E, Gautam S, Wu E, Wong ET. The natural history of extracranial metastasis from glioblastoma multiforme. *J Neurooncol*. 2011 Nov;105(2):261–73.
- Ferguson SD, Xiu J, Weathers SP, Zhou S, Kesari S, Weiss SE, et al. GBM-associated mutations and altered protein expression are more common in young patients. *Oncotarget*. 2016 Oct 25;7(43):69466–78.
- Zhang RQ, Shi Z, Chen H, Chung NYF, Yin Z, Li KKW, et al. Biomarker-based prognostic stratification of young adult glioblastoma. *Oncotarget*. 2016 Jan 26;7(4):5030–41.
- Schreck K, Vera E, Aboud O, Acquaye A, Boris L, Briceno N, et al. The natural history of BRAF V600E-mutated glioblastomas in adults. *Neuro Oncol*. 2018;20(Suppl 6):vi164.
- Leaver KE, Zhang N, Ziskin JL, Vogel H, Recht L, Thomas RP. Response of metastatic glioma to vemurafenib. *Neurooncol Pract*. 2016 Dec;3(4):268–71.
- Cerami E, Gao J, Dogrusoz U, Gross BE, Sumer SO, Aksoy BA, et al. The cBio cancer genomics portal: an open platform for exploring multidimensional cancer genomics data. *Cancer Discov*. 2012 May;2(5):401–4.
- Gao J, Aksoy BA, Dogrusoz U, Dresdner G, Gross B, Sumer SO, et al. Integrative analysis of complex cancer genomics and clinical profiles using the cBioPortal. *Sci Signal*. 2013 Apr 2;6(269):p11.
- Shayganfar A, Ebrahimian S, Mahzouni P, Shirani F, Aalinezhad M. A review of glioblastoma tumors with primitive neuronal component and a case report of a patient with this uncommon tumor at a rare location. *Clin Case Rep*. 2020 Aug 12;8(12):2600–4.
- Singleton KR, Crawford L, Tsui E, Manchester HE, Maertens O, Liu X, et al. Melanoma therapeutic strategies that select against resistance by exploiting MYC-driven evolutionary convergence. *Cell Rep*. 2017 Dec 5;21(10):2796–812.
- Kaley T, Touat M, Subbiah V, Hollebecque A, Rodon J, Lockhart AC, et al. BRAF inhibition in BRAFV600-mutant gliomas: results from the VE-BASKET study. *J Clin Oncol*. 2018 Dec 10;36(35):3477–84.
- Wen PY, Stein A, van den Bent M, De Greve J, Wick A, de Vos FYFL, et al. Dabrafenib plus trametinib in patients with BRAFV600E-mutant low-grade and high-grade glioma (ROAR): a multicentre, open-label, single-arm, phase 2, basket trial. *Lancet Oncol*. 2022 Jan;23(1):53–64.