



Case Report

# Multifocal glioblastoma and hormone replacement therapy in a transgender female

Jose Omar Santellan-Hernandez<sup>1</sup>, José Alfonso Alvarez-Castro<sup>1</sup>, Keren Magaly Aguilar-Hidalgo<sup>1</sup>, Fernando Castro Soto<sup>2</sup>, Jonathan Ramos Escalante<sup>3</sup>, Eduardo Ichikawa-Escamilla<sup>3</sup>, Maria Jose Alvarez Silva<sup>4</sup>, Sonia Iliana Mejia-Perez<sup>1</sup>

<sup>1</sup>Department of Neurosurgical Oncology, <sup>2</sup>Department of Radio-Neurosurgery, <sup>3</sup>Department of Neurosurgery, National Institute of Neurology and Neurosurgery "Manuel Velasco Suarez", <sup>4</sup>Department of Neurosurgery, University of La Salle, Mexico City, Mexico.

E-mail: Jose Omar Santellan-Hernandez - omarsantellan@gmail.com; José Alfonso Alvarez-Castro - alfonso.alvarez@inn.edu.mx; Keren Magaly Aguilar-Hidalgo - magalyaguilar@inn.edu.mx; Fernando Castro Soto - fcastrosoto331@gmail.com; Jonathan Ramos Escalante - jonathanramos.10@hotmail.com; Eduardo Ichikawa-Escamilla - eichikawae@gmail.com; Maria Jose Alvarez Silva - majaoasil@gmail.com; \*Sonia Iliana Mejia-Perez - soniamejia@inn.edu.mx



**\*Corresponding author:**

Sonia Iliana Mejia-Perez,  
Department of Neurosurgical  
Oncology, National Institute of  
Neurology and Neurosurgery,  
Mexico City, Mexico.

soniamejia@inn.edu.mx

Received : 02 February 2023

Accepted : 11 March 2023

Published : 24 March 2023

**DOI**

10.25259/SNI\_104\_2023

**Quick Response Code:**



## ABSTRACT

**Background:** Glioblastoma multiforme represents approximately 60% of all brain tumors in adults. This malignancy shows a high level of biological and genetic heterogeneity associated with exceptional aggressiveness, leading to poor patient survival. One of the less common presentations is the appearance of primary multifocal lesions, which are linked with a worse prognosis. Among the multiple triggering factors in glioma progression, the administration of sex steroids and their analogs has been studied, but their role remains unclear to date.

**Case Description:** A 43-year-old transgender woman who has a personal pathological history of receiving intramuscular (IM) hormone treatment for 27 years based on algestone/estradiol 150 mg/10 mg/mL. Three months ago, the patient suddenly experienced hemiplegia and hemiparesis in her right lower extremity, followed by a myoclonic focal epileptic seizure, vertigo, and a right frontal headache with a visual analog scale of 10/10. Magnetic resonance imaging images revealed an intra-axial mass with poorly defined, heterogeneous borders, and thick borders with perilesional edema in the left parietal lobe, as well as a rounded hypodense image with well-defined walls in the right internal capsule. The tumor was resected, and samples were sent to the pathology department, which confirmed the diagnosis of wild-type glioblastoma.

**Conclusion:** This report identifies prolonged use of steroid-based hormone replacement therapy as the only predisposing factor in the oncogenesis of multifocal glioblastoma. It is an example that highlights the importance for physicians not to consider pathologies related to the human immunodeficiency virus rather than neoplasms in transgender patients in view of progressive neurological deterioration.

**Keywords:** Gender, Glioblastoma, Multicentric, Neurosurgery, Transgender

## INTRODUCTION

Glioblastoma is a highly malignant type of tumor that originates from neuroglial cells in the central nervous system. It is commonly seen in people aged between 45 and 70 years old<sup>[15]</sup> and accounts for 54% of all gliomas, making it one of the most frequent and lethal primitive tumors due to its rapid growth.<sup>[12]</sup> Patients with this pathology have an overall survival rate of 12 months and a survival rate of 10% after 2 years of evolution. Multifocal gliomas are tumor masses that are separated by white matter tracts within the same cerebral hemisphere, while multicentric gliomas

This is an open-access article distributed under the terms of the Creative Commons Attribution-Non Commercial-Share Alike 4.0 License, which allows others to remix, transform, and build upon the work non-commercially, as long as the author is credited and the new creations are licensed under the identical terms.

©2023 Published by Scientific Scholar on behalf of Surgical Neurology International

are tumors that are in opposite hemispheres or are separated by tentorium, and usually have different histologic lineages, making them difficult to distinguish from metastases.<sup>[11]</sup>

According to the United Nations, transgender people have a gender identity different from the sex that they were assigned at birth. This gender identity is distinct from sexual orientation, as the former refers to how someone identifies themselves, and the latter refers to emotional and sexual attraction to another person of the same or different sex. To affirm their gender identity, trans people often undergo surgeries and hormone treatments, commonly with estrogen and cyproterone acetate.<sup>[19]</sup> After gender-affirming genital surgery, it is only necessary to continue estrogen therapy. Cross-sex hormone therapy is an important component of treatment for many transgender patients, but it is not without adverse effects.<sup>[6]</sup>

Cancer progression after cross-sex therapy has been reported in different tissues. Mortality rates for lung and hematological malignancies have been identified as being increased after hormone replacement therapy (HRT); moreover, there are estrogen-sensitive breast carcinomas and a few cases of prostate carcinomas reported in transwomen who started cross-sex therapy after the age of 50.<sup>[11]</sup> However, it is uncertain whether the condition was present before the initiation of hormone treatment. Focusing on central nervous system neoplasms, it has been reported that 20% of transwomen who use estrogens have increased levels of prolactin associated with prolactinomas, as the lactotroph pituitary cells have estrogen receptors. Furthermore, five cases of prolactinomas have been described in transwomen who self-medicate with supraphysiological doses of estrogen. In addition, two cases of meningioma after 5 years of hormonal treatment with estrogens and cyproterone acetate, and one case of meningioma in a transwoman treated with estradiol for more than 10 years have also been reported.<sup>[3]</sup>

Regarding glioblastomas, there are cases of pregnant women between 20 and 40 years old, where progesterone levels reach serum levels up to 200-fold higher than baseline; they presented the first clinical manifestation or acceleration of symptoms due to brain tumors, among which 55 of 119 cases were gliomas (31% with estrogen receptors and 31% with progesterone receptors) with a poor postpartum amelioration.<sup>[4,18]</sup> The large Million Women Study showed a small but significant increase in risk (Relative risk (RR) 1.34; 1.05–1.72) with the use of estrogen-only hormone therapy with glioma, predominantly in those who had <5 years of treatment, based on conjugated equine estrogens.<sup>[5]</sup>

Given that cross-hormonal therapy is an ongoing therapy for these patients, vigilance for possible side effects such as those mentioned above is essential. However, since there is no specific screening for the early identification of brain tumors, including glioblastomas, it is possible that there is an underestimation of the actual prevalence of these tumors in transgender patients receiving such treatment.

## CASE PRESENTATION

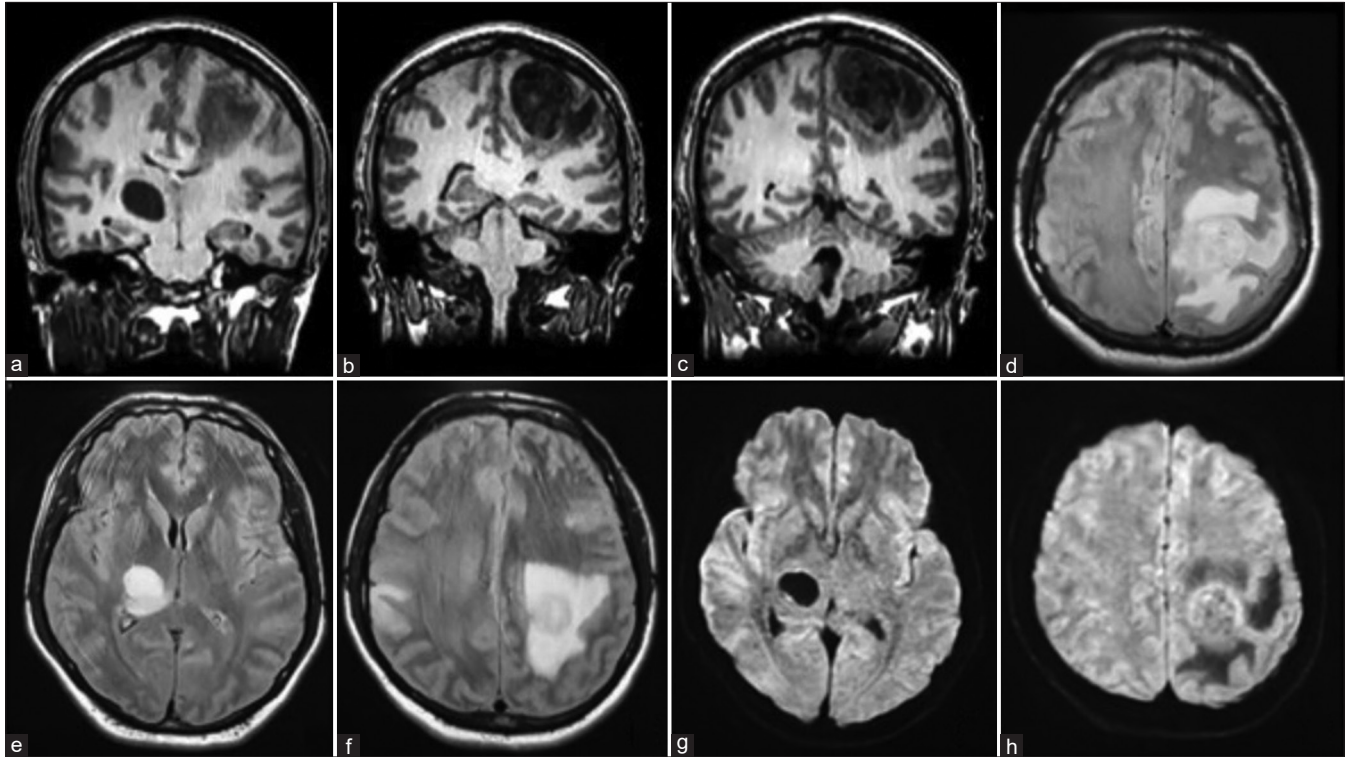
A 43-year-old, right-handed transgender woman from the State of Mexico is a housewife and professes the Catholic religion. Three months ago, the patient suddenly experienced hemiplegia and hemiparesis in her right lower extremity, followed by a myoclonic focal epileptic seizure, vertigo, and a right frontal headache with a visual analog scale of 10/10. In the past month, the patient reported drowsiness, urinary sphincter loss, diplopia for 1 week, three daily focal epileptic seizures in the right arm and leg with tonic-clonic characteristics, without alterations of the mental status, and postictal weakness.

The patient has a personal pathological history of receiving intramuscular (IM) hormone treatment for 27 years based on algestone/estradiol 150 mg/10 mg/mL, which is currently suspended. She has been vaccinated against COVID on three occasions with the Pfizer brand and has not contracted the disease. In addition, she has undergone several surgical interventions, such as rhinoplasty 25 years ago, breast implants 20 years ago, and other cosmetic surgeries on the face. With a significant family history of illness, her mother has been diagnosed with Parkinson's disease; her father suffered from diabetes mellitus and died of liver cancer, and her brother has a history of deep vein thrombosis of the lower extremities.

During the clinical examination, right eye exotropia, bradykinesia, anisocoria with the right miosis, right-side spasticity, and left side exteroceptive hypoesthesia were noted. To treat her adjustment disorder with depressive symptoms due to dysplastic hyperthymia, a tendency to cry, and ideas of worthlessness and ruin, she started on mirtazapine at 15 mg daily.

She was admitted to a private hospital and started on carbamazepine 200 mg every 8 h as symptomatic treatment. However, 9 days later, her condition had not improved, so a computerized axial tomography was requested. This showed encephalic volume with structural changes according to age and a lesion of primary neoplastic aspect, likely a glioblastoma, in the left parietal lobe subcortical towards the convexity.

On arrival at our institution, magnetic resonance imaging image studies were performed [Figure 1], revealing an intra-axial mass with poorly defined, heterogeneous borders and thick borders with perilesional edema in the left parietal lobe, as well as a rounded hypodense image with well-defined walls in the right internal capsule. A hypointense lesion is observed in the right thalamic region on T1 and hyperintense on T2, with a cystic-type appearance, which restricts diffusion. In the right parietal cortex, there is a diffuse lesion that is hypointense on T1 and hyperintense on T2. On the contralateral hemisphere, in the left frontotemporal region, there is a heterogeneous lesion that is hypointense on T1 and hyperintense on T2, with abundant perilesional edema. Due to the characteristics of the lesions, a tumor or infectious process may be suspected.



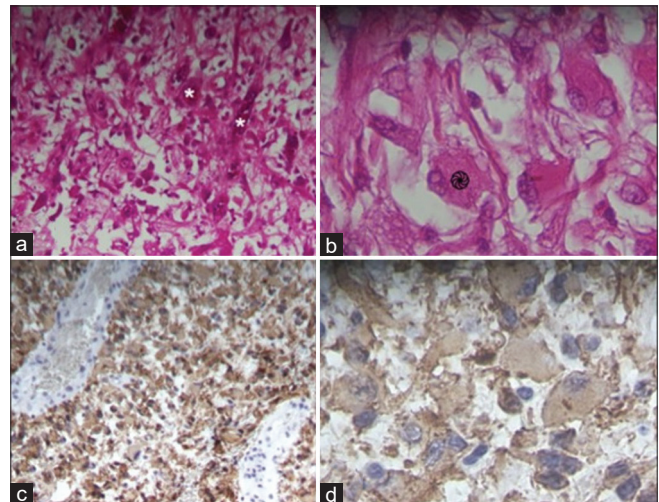
**Figure 1:** Skull magnetic resonance imaging (MRI). December 04, 2022. Preoperative. (a-c) Coronal axis T1 MRI, (d-f) coronal axis T2 MRI, and (g and h) coronal axis diffusion sequence.

After establishing the diagnosis and determining the surgical strategy, the patient was transferred to the operating room under anesthesia and placed in a supine decubitus position with Mayfield-Kees cranial fixation. A craniotomy-guided horseshoe incision centered on the lesion was made, with intraoperative ultrasonographic tracing to confirm the lesion below the craniotomy. A lesion was identified from the subcortical region with a soft, friable consistency, and yellowish appearance, measuring approximately  $3.5 \times 4.5$  cm in diameter. Due to its friability, fragmentary resection was performed, with the lesion being devastated using Mallis forceps and suction. Samples from the resected tumor were sent to the pathology department, which confirmed the diagnosis of wild-type glioblastoma [Figure 2].

The patient was discharged from the operating room in a hemodynamically stable state and with a functioning ventilator. Postoperative imaging studies were conducted [Figures 3 and 4], however, due to the patient's deteriorating alertness and persistent headaches that did not respond to medication, a second surgery was scheduled.

## DISCUSSION

Although there are no similar cases reported of multifocal glioblastomas in transgender people, it is essential to acknowledge that transgender people represent a heterogeneous

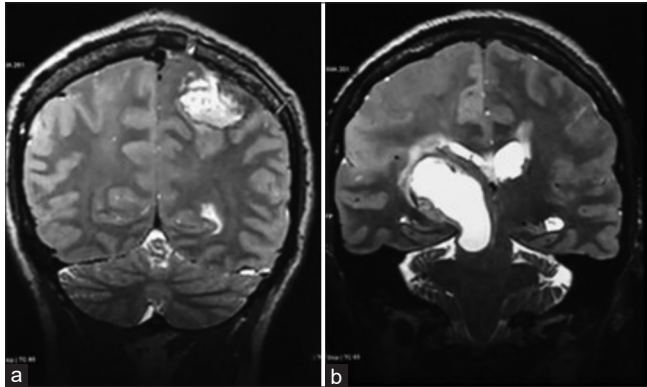


**Figure 2:** Histopathological findings of the resected tumor. A left frontoparietal lesion with a grayish-brown, hemorrhagic appearance is observed. (a and b) Hematoxylin and eosin staining reveal giant cells (\* - ⊗) with an infiltrative growth pattern, nuclear atypia, mitotic activity, and microvascular proliferation. (c and d) Immunohistochemical staining is positive for isocitrate dehydrogenase wild type and negative for ATRX. Original magnifications: (a and c)  $\times 200$ ; (b and d)  $\times 1000$ .

population group and that cancer risks, hormone use, and the prevalence of non-hormonal risk factors may vary widely



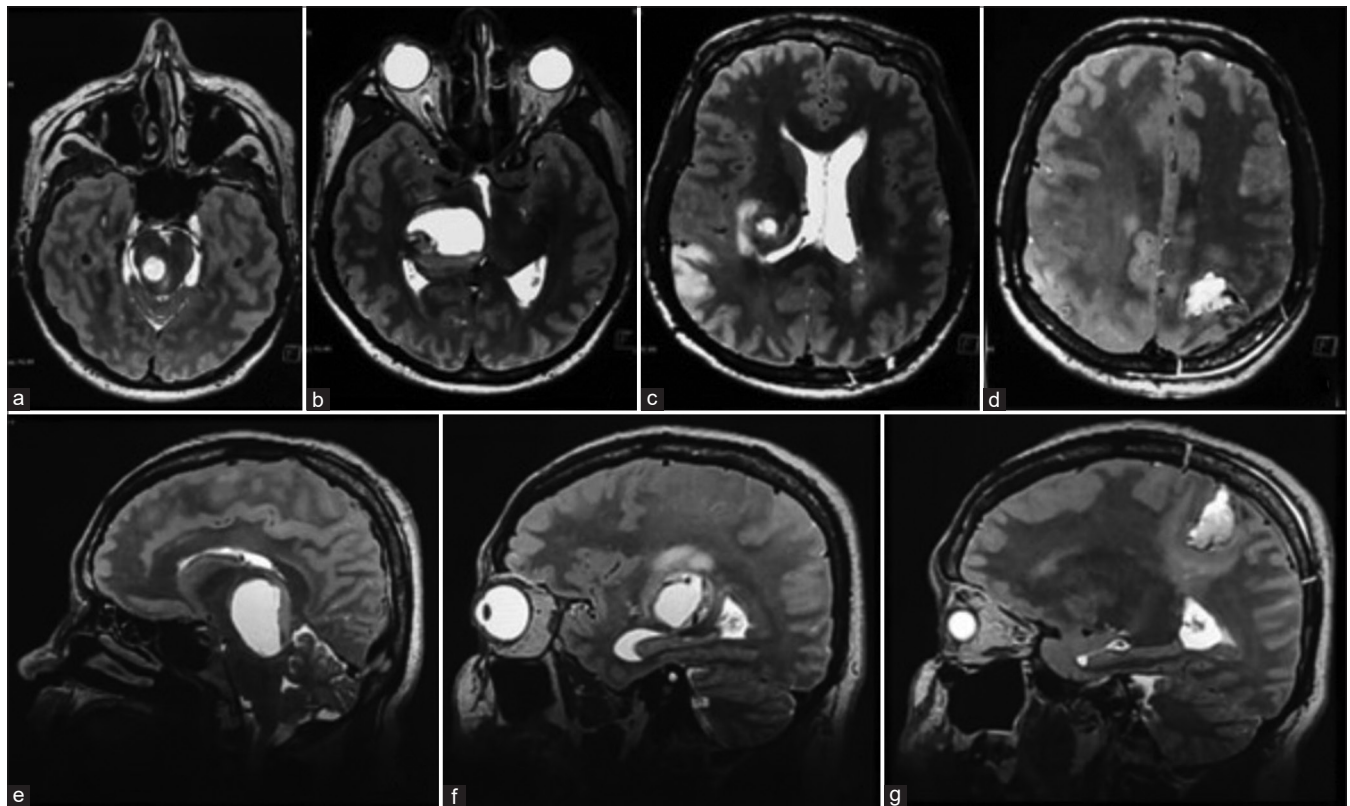
across the gender identity spectrum.<sup>[7]</sup> Nevertheless, multifocal glioblastoma, as a rare type of glioblastoma, is associated with a worse prognosis compared with solitary ones,<sup>[1]</sup> and a reported incidence ranging from 0.5% to 20%.<sup>[4]</sup> Multiple lesions present



**Figure 3:** Skull magnetic resonance imaging (MRI). December 15, 2022. Postoperative. (a and b) Coronal axis T2 MRI sequence. Post-surgical changes are observed in the left frontotemporal region, with a well-defined post-surgical space present in 90% of resections. In addition, the right thalamic lesion is larger in size and is compressing the lateral ventricle of the same hemisphere.

significant challenges and hazards to surgeons, forcing them to make difficult decisions. It was unusual to accomplish resection of numerous tumors, and 70% of patients had just one lesion removed.<sup>[8]</sup> As was observed in this case, the deeper lesion could not be resected due to its location in an eloquent area that would impair the patient's quality of life.

The patient, in this case, used algestone and estradiol as dual HRT for a prolonged period. Therefore, it is essential to emphasize the role of sex hormones such as androgens, estrogens, and progestogens as possible factors in the development and progression of glioblastoma. Otherwise, there is a historical context that has associated the use of androgens with the incidence of cancers of different histological lineages, the most related being prostate cancer. In addition, there has been an interest in researching treatments that antagonize the effects of this type of hormonal therapy. An example of this is the interest in investigating androgen receptor (AR) positivity and subsequent treatment with androgen antagonists.<sup>[13]</sup> This has been attempted to be reproduced in glioblastoma multiforme (GBM) and other intracranial tumors. Specifically, preclinical studies have identified that the use of testosterone stimulates the proliferation of GBM cell lines.<sup>[16]</sup> Likewise, Ware *et al.* (2014) documented AR positivity in different



**Figure 4:** Skull magnetic resonance imaging (MRI), January 09, 2023, postoperative. Axial axis T2 MRI sequence (a-d) and sagittal axis T2 MRI sequence (e-g) show a right thalamic lesion beginning to invade the pons from the midbrain and extending to the corpus callosum, with perilesional edema covering much of the frontal lobe. In addition, a larger area of hyperintensity is observed in the right parietal cortical lesion. The left frontoparietal post-surgical space is well-demarcated.

tumors studied, occurring in 40% of GBM, 28% of grade I/II astrocytomas, and 75% of anaplastic astrocytomas.<sup>[20]</sup> Similarly, McNamara *et al.* (2014) identified AR positivity in 42% of patients with meningioma.<sup>[14]</sup>

Among the hormonal factors associated with glioblastoma development and progression are estrogens. These hormones activate the G protein-coupled receptor (GPER1), which interacts with hypoxia-inducible factor-1 $\alpha$  to promote the expression of genes encoding growth factors such as connective tissue growth factor, vascular endothelial growth factor (VEGF), and interleukin 6, which are related to oncogenesis in different tissues. The regulatory role of GPER1 in glioma progression could be a promising area of research. On the other hand, estrogen receptor alpha (ER $\alpha$ ) has a low expression in adult neural stem cells, but its isoform ER $\alpha$ 36 is expressed in glioblastoma cell lines and is related to tamoxifen resistance.<sup>[17]</sup> Therefore, a tumor-promoting role and a potential therapeutic target are often proposed for this receptor.

Finally, progestins are another type of sex hormone thought to be associated with glioblastoma. Specifically, it has been reported that they can increase glial tumor cell proliferation at low doses, although they also induce cell differentiation and apoptosis at higher doses. In murine models, low-dose administration of progesterone (10 nM) significantly increased glioblastoma tumor area and infiltration length. This hormone induces that the synthesis of cyclin D1, epidermal growth factor receptor, progesterone-induced blocking factor, and steroid receptor coactivator-1, is involved in the induction of VEGF in human glioma cells, and activates cofilin, a protein that promotes the formation of free barbed ends and tumor invasion.<sup>[2]</sup>

Despite mentioning several variables that may be associated with the development of gliomas, the only established risk factors are high doses of ionizing radiation and certain rare genetic conditions. However, the use of exogenous hormones may also have a potential role in the etiology. Studies such as that of Gonzalez *et al.* (2021) reaffirm the importance of the hormonal context in glioblastoma.<sup>[9]</sup> In this research, it was reported that HRT with estrogen increases the risk of gliomas, while HRT with progestin increases the incidence of meningiomas. In addition, it should be noted that the patient in our case received dual HRT, so the risk could indeed come from a hormonal situation.<sup>[10]</sup> However, it is important to note that there is limited research available on the relationship between HRT and glioblastoma, and further studies are needed to fully understand the potential risks or benefits of HRT for transgender individuals.

## CONCLUSION

Glioblastoma is a high-grade tumor that occurs in both male and female patients. In this case of a transgender female who has undergone HRT, there may be a potential risk of

developing multiple glioblastomas due to the increased levels of hormones that can stimulate the growth of cancer cells. Although several studies suggest the use of progestins and their analogs as protective factors in brain tumors, this case leans more toward the role of estrogens and progestins in tumor progression. However, further research is needed to confirm this conclusion.

From an ethical standpoint, physicians must have an objective assessment when diagnosing patients with a transgender role, since it is common for physicians to orient toward pathologies related to the human immunodeficiency virus rather than neoplasms. This case exemplifies the appearance of a primary tumor of the central nervous system without bias in the diagnosis after understanding the patient's clinical history.

## Acknowledgment

This paper and the research behind it would not have been possible without the exceptional support, of Dr. Sonia Mejía, and Dr. Omar Santellán, as well as all the colleagues who helped write this paper, Dr. Alfonso Alvarez, Dr. Magaly Aguilar, Dr. Fernando Castro, Dr. Jonathan Ramos, Dr. Eduardo Ichikawa, and Dr. María José Alvarez.

## Declaration of patient consent

Patient's consent not required as patient's identity is not disclosed or compromised.

## Financial support and sponsorship

Nil.

## Conflicts of interest

There are no conflicts of interest.

## REFERENCES

1. Abou-El-Ardat K, Seifert M, Becker K, Eisenreich S, Lehmann M, Hackmann K, *et al.* Comprehensive molecular characterization of multifocal glioblastoma proves its monoclonal origin and reveals novel insights into clonal evolution and heterogeneity of glioblastomas. *Neuro Oncol* 2017;19:546-57.
2. Altinoz MA, Ozpinar A, Elmaci I. Reproductive epidemiology of glial tumors may reveal novel treatments: High-dose progestins or progesterone antagonists as endocrine-immune modifiers against glioma. *Neurosurg Rev* 2019;42:351-69.
3. Asscheman H, Giltay EJ, Megens JA, de Ronde WP, van Trotsenburg MA, Gooren LJ. A long-term follow-up study of mortality in transsexuals receiving treatment with cross-sex hormones. *Eur J Endocrinol* 2011;164:635-42.
4. Barnard RO, Geddes JF. The incidence of multifocal cerebral gliomas. A histologic study of large hemisphere sections.

- Cancer 1987;60:1519-31.
5. Benson VS, Pirie K, Green J, Bull D, Casabonne D, Reeves GK, *et al.* Hormone replacement therapy and incidence of central nervous system tumors in the Million Women Study. *Int J Cancer* 2010;127:1692-8.
  6. Boer M, Moernaut L, Van Calenbergh F, Lapauw B, T'Sjoen G. Variation of meningioma in response to cyproterone acetate in a trans woman. *Int J Transgend* 2018;19:92-4.
  7. Braun H, Nash R, Tangpricha V, Brockman J, Ward K, Goodman M. Cancer in transgender people: Evidence and methodological considerations. *Epidemiol Rev* 2017;39:93-107.
  8. Di Carlo DT, Cagnazzo F, Benedetto N, Morganti R, Perrini P. Multiple high-grade gliomas: Epidemiology, management, and outcome. A systematic review and meta-analysis. *Neurosurg Rev* 2019;42:263-75.
  9. González-Mora AM, Garcia-Lopez P. Estrogen receptors as molecular targets of endocrine therapy for Glioblastoma. *Int J Mol Sci* 2021;22:12404.
  10. Kabat GC, Park Y, Hollenbeck AR, Schatzkin A, Rohan TE. Reproductive factors and exogenous hormone use and risk of adult glioma in women in the NIH-AARP diet and health study. *Int J Cancer* 2011;128:944-50.
  11. Khandwala K, Mubarak F, Minhas K. The many faces of glioblastoma: Pictorial review of atypical imaging features. *Neuroradiol J* 2021;34:33-41.
  12. Li Y, Zhang ZX, Huang GH, Xiang Y, Yang L, Pei YC, *et al.* A systematic review of multifocal and multicentric glioblastoma. *J Clin Neurosci* 2021;83:71-6.
  13. Loblaw DA, Virgo KS, Nam R, Somerfield MR, Ben-Josef E, Mendelson DS, *et al.* Initial hormonal management of androgen-sensitive metastatic, recurrent, or progressive prostate cancer: 2006 update of an American Society of Clinical Oncology Practice Guideline. *J Clin Oncol* 2007;25:1596-605.
  14. McNamara KM, Moore NL, Hickey TE, Sasano H, Tilley WD. Complexities of androgen receptor signaling in breast cancer. *Endocr Relat Cancer* 2014;21:T161-81.
  15. Meriggiola MC, Gava G. Endocrine care of transpeople Part II. A review of cross-sex hormonal treatments, outcomes, and adverse effects in transwomen. *Clin Endocrinol (Oxf)* 2015;83:607-15.
  16. Naderi A, Chia KM, Liu J. Synergy between inhibitors of androgen receptor and MEK has therapeutic implications in estrogen receptor-negative breast cancer. *Breast Cancer Res* 2011;13:R36.
  17. Reyes GA. Gliomas del adulto: Acercamiento al diagnóstico y tratamiento. *Acta Neurol Colomb* 2009;25:34-41.
  18. Roelvink NC, Kamphorst W, van Alphen HA, Rao BR. Pregnancy-related primary brain and spinal tumors. *Arch Neurol* 1987;44:209-15.
  19. United Nations Human Rights Office. Transgender. United Nations Free and Equal. 2019. Available from: <https://www.unfe.org/wp-content/uploads/2017/05/unfe-transgender.pdf> [Last accessed on 2023 Jan 23].
  20. Ware KE, Garcia-Blanco MA, Armstrong AJ, Dehm SM. Biologic, and clinical significance of androgen receptor variants in castration-resistant prostate cancer. *Endocr Relat Cancer* 2014;21:T87-103.

**How to cite this article:** Santellan-Hernandez JO, Alvarez-Castro JA, Aguilar-Hidalgo K, Castro Soto F, Ramos Escalante J, Ichikawa-Escamilla E, *et al.* Multifocal glioblastoma and hormone replacement therapy in a transgender female. *Surg Neurol Int* 2023;14:106.

### Disclaimer

The views and opinions expressed in this article are those of the authors and do not necessarily reflect the official policy or position of the Journal or its management. The information contained in this article should not be considered to be medical advice; patients should consult their own physicians for advice as to their specific medical needs.