

## Super selective intra-arterial cerebral infusion (SSIACI) for newly diagnosed and recurrent glioblastoma

Syed Sarmad Bukhari<sup>1</sup>, Noman Ahmed<sup>2</sup>, Muhammad Shahzad Shamim<sup>3</sup>

### Introduction

Chemotherapy with various modalities is the standard of care in the management of newly diagnosed and recurrent glioblastoma. Current guidelines recommend intravenous administration of systemic chemotherapy. However, the blood brain barrier (BBB) restricts ionized molecules larger than 180 Da (Daltons) while most chemotherapeutic agents are between 200-1200 Da (TMZ [194 Da]). The doses administered are restricted by their systemic toxicity. Super selective intra-arterial cerebral infusion (SSIACI) can administer a localized regular or higher dose of chemotherapy that circumvents the systemic circulation. This is accompanied by disruption of the BBB (BBBd) which can be achieved in a number of ways (IV mannitol, MRIgFUS and bradykinins etc). With super selective catheterization, the drug's volume of distribution (Vd) is restricted to a targetted area. Additionally, following drug delivery, flow may be arrested to prevent drug washout with blood flow.<sup>1</sup>

### Review of Evidence

Glioblastoma is the most common primary brain malignancy which accounts for almost 50% of malignant brain tumours. The current standard of care in glioblastoma management is maximum safe resection of the enhancing lesion with or without resection of the FLAIR abnormality, followed by 60 Gy of radiation given in 2 fractions daily, 5 days a week for 6 weeks with concomitant temozolamide given 7 days a week at a dose of 75 mg/m<sup>2</sup>. This is followed up with 6 adjuvant cycles consisting of 150-200 mg/m<sup>2</sup> for 5 days in a 28-day cycle.<sup>2</sup>

Newton et al., performed the first pilot study for administration of intra-arterial (IA) cisplatin through the internal carotid artery. Twelve patients received a total of 24 infusions with poor response and high rate of complications.<sup>3</sup> Madejewicz et al., published a trial of 83 patients with higher grade gliomas (HGGs) in which non-selective IA cisplatin and etoposide were administered prior to or with concomitant radiation therapy in two separate groups. They reported significant improvement in

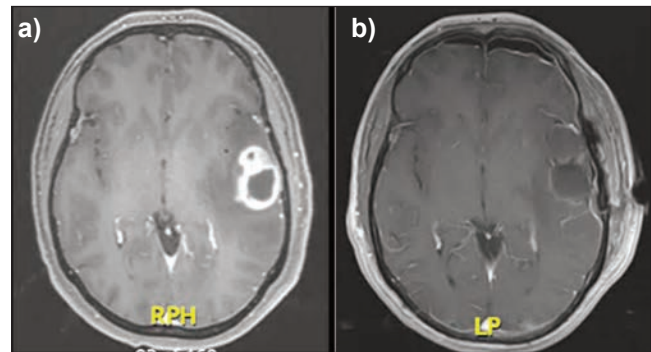
<sup>1</sup>Northwest School of Medicine, Peshawar, Pakistan;

<sup>2,3</sup>Aga Khan University Hospital, Karachi, Pakistan

**Correspondence:** Muhammad Shahzad Shamim.

e-mail: shahzad.shamim@aku.edu

ORCID ID: 0000-0001-8305-8854



**Figure:** MRI T1WI post contrast, a) pre and b) post images showing gross total resection of a left frontal glioblastoma.

survival in patients receiving IA therapy prior to radiation therapy (RT) and in conclusion noted that this was the best therapy available at the time. They also postulated that concomitant or prior RT reduces the penetration of chemotherapeutic drugs into the tumour bed by damaging the vasculature of the tumour.<sup>4</sup>

Nimustine is a nitrosurea alkylating agent. Imbesi et al., performed a phase II clinical trial to compare IA vs. IV administration of nimustine in the management of newly diagnosed glioblastoma and found no improvement in progression free survival.<sup>5</sup> Kochii et al., reported similar findings.<sup>6</sup> Burkhardt et al., performed a single center prospective phase II trial with IA bevacizumab after BBB disruption with mannitol with a reported progression free survival (PFS) of 10 months and an overall survival (OS) of 8.8 months.<sup>7</sup>

Patel et al., have evaluated the efficacy of IA bevacizumab after disruption of the BBB for treatment of newly diagnosed glioblastoma after surgery. In their study SSIACI was utilized. The results were encouraging with PFS being 11.5 months and OS being 23.1 months. More importantly, PFS at 24 months was 32.5% compared to 26.5% for the Stupp protocol.<sup>8</sup> For recurrent glioblastoma, IA bevacizumab with BBBd using mannitol showed significant improvement in PFS of 10 months compared to IV bevacizumab with a PFS between 3.7 and 4.2 months.<sup>9</sup> IA administration of temozolamide is not feasible due to its proven brain toxicity in its currently available formulation.<sup>10</sup>

## Conclusion

SSIACI appears to be a promising avenue with some studies demonstrating benefit over the standard of care. However initial studies also reported a significant complication rate. There are several ongoing studies which are actively recruiting patients and until more results are published, the risk benefit ratio remains inconclusive.

**DOI:** <https://doi.org/10.47391/JPMA.24-55>

## References

1. D'Amico RS, Khatri D, Reichman N, Patel NV, Wong T, Fralin SR, Li M, Ellis JA, Ortiz R, Langer DJ, Boockvar JA. Super selective intra-arterial cerebral infusion of modern chemotherapeutics after blood-brain barrier disruption: where are we now, and where we are going. *J Neurooncol.* 2020;147:261-278. doi: 10.1007/s11060-020-03435-6. Epub 2020 Feb 19. Erratum in: *J Neurooncol.* 2020 Mar 13; PMID: 32076934.
2. Stupp R, Mason WP, van den Bent MJ, Weller M, Fisher B, Taphoorn MJ, Belanger K, Brandes AA, Marosi C, Bogdahn U, et al. Radiotherapy plus concomitant and adjuvant temozolomide for glioblastoma. *N Engl J Med.* 2005;352:987-996. <https://doi.org/10.1056/NEJMoa043330>
3. Newton HB, Page MA, Junck L, Greenberg HS. Intra-arterial cisplatin for the treatment of malignant gliomas. *J Neurooncol.* 1989;7:39-45. <https://doi.org/10.1007/BF00149377>
4. Madajewicz S, Chowhan N, Tfayli A, Roque C, Meek A, Davis R, Wolf W, Cabahug C, Roche P, Manzione J, et al. Therapy for patients with high grade astrocytoma using intraarterial chemotherapy and radiation therapy. *Cancer.* 2000;88:2350-2356.
5. Imbesi F, Marchioni E, Benericetti E, Zappoli F, Galli A, Corato M, Ceroni M. A randomized phase III study: comparison between intravenous and intraarterial ACNU administration in newly diagnosed primary glioblastomas. *Anticancer Res.* 2006;26:553-558
6. Kochii M, Kitamura I, Goto T, Nishi T, Takeshima H, Saito Y, Yamamoto K, Kimura T, Kino T, Tada K, et al. Randomized comparison of intra-arterial versus intravenous infusion of ACNU for newly diagnosed patients with glioblastoma. *J Neurooncol.* 2000;49:63-70. <https://doi.org/10.1023/a:1006457502972>
7. Burkhardt J, Riina H, Shin BJ, Christos P, Kesavabhotla K, Hofstetter CP, Tsiouris AJ, Boockvar JA. Intra-arterial delivery of bevacizumab after blood brain barrier disruption for the treatment of recurrent glioblastoma: progression-free survival and overall survival. *World Neurosurg.* 2012;77:130-134.
8. Patel NV, Wong T, Fralin SR, Li M, McKeown A, Gruber D, D'Amico RS, Patsalides A, Tsiouris A, Stefanov DG, et al. Repeated superselective intraarterial bevacizumab after blood brain barrier disruption for newly diagnosed glioblastoma: a phase I/II clinical trial. *J Neurooncol.* 2021;155:117-124. <https://doi.org/10.1007/s11060-021-03851-2>
9. Boockvar JA, Tsiouris AJ, Hofstetter CP, Kovanlikaya I, Fralin S, Kesavabhotla K, Seedial SM, Pannullo SC, Schwartz TH, Stieg P, et al. Safety and maximum tolerated dose of superselective intraarterial cerebral infusion of bevacizumab after osmotic blood-brain barrier disruption for recurrent malignant glioma. Clinical article. *J Neurosurg.* 2011;114:624-632. <https://doi.org/10.3171/2010.9.JNS101223>
10. Muldoon LL, Pagel MA, Netto JP, Neuwelt EA. Intra-arterial administration improves temozolomide delivery and efficacy in a model of intracerebral metastasis, but has unexpected brain toxicity. *J Neurooncol.* 2016;126:447-54. doi: 10.1007/s11060-015-2000-1