



Determining Progressive Disease Using RANO 2.0—Further Clarifications and Explanations

Ji Eun Park^{1*}, Yae Won Park^{2*}, Young-Hoon Kim³, Sang Woo Song³, Chang-Ki Hong³, Jeong Hoon Kim³, Ho Sung Kim¹

¹Department of Radiology and Research Institute of Radiology, University of Ulsan College of Medicine, Asan Medical Center, Seoul, Republic of Korea

²Department of Radiology and Research Institute of Radiological Science and Center for Clinical Imaging Data Science, Yonsei University College of Medicine, Seoul, Republic of Korea

³Department of Neurosurgery, University of Ulsan College of Medicine, Asan Medical Center, Seoul, Republic of Korea

Keywords: Glioma; Response assessment in neuro-oncology 2.0; Progression

We have read the article by Won et al. [1], titled “Summary of Key Points of the Response Assessment in Neuro-Oncology (RANO) 2.0,” with great interest. They suggested three key points from RANO 2.0: 1) the use of standardized brain tumor imaging protocols is recommended, 2) tumor measurement methods are expanded to volumetry, and 3) the timing of baseline magnetic resonance imaging (MRI) and the confirmation process of progression are specified. While the summary highlights the contrast with previous response criteria and underscores the current scheme of RANO 2.0, it over-condenses the definitions of progression and baseline MRI. This brevity may mislead readers who have not read

Received: May 21, 2024 **Accepted:** June 10, 2024

*These authors contributed equally to this work.

Corresponding author: Ji Eun Park, MD, PhD, Department of Radiology and Research Institute of Radiology, University of Ulsan College of Medicine, Asan Medical Center, 88 Olympic-ro 43-gil, Songpa-gu, Seoul 05505, Republic of Korea

• E-mail: jieunp@gmail.com

This is an Open Access article distributed under the terms of the Creative Commons Attribution Non-Commercial License (<https://creativecommons.org/licenses/by-nc/4.0>) which permits unrestricted non-commercial use, distribution, and reproduction in any medium, provided the original work is properly cited.

the full RANO 2.0 update [2]. Therefore, we aimed to provide additional clarity and necessary details on the criteria for determining progressive diseases (PDs) in RANO 2.0.

The most distinct aspects of RANO 2.0, as compared to the previously released RANO statement for high-grade gliomas (RANO-HGG) [3] and low-grade gliomas (RANO-LGG) [4] are as follows: 1) the first post-radiotherapy MRI, rather than the post-surgical MRI, is used as baseline imaging and 2) repeat MRI is mandatory to confirm progression within 12 weeks after radiotherapy. These criteria were adopted from a modified RANO statement released in 2017 [5]. The reasons for excluding immediate post-surgical imaging as the baseline were the presence of postoperative changes (i.e., blood products and edema), variable corticosteroid use before clinical trial enrollment, and variability in imaging techniques and timing—as the patients had not yet been enrolled in a clinical trial, it may be inconsistent with trial recommendations. For the confirmatory scan, repeat MRI or histopathological evidence of an “unequivocal recurrent tumor” should be acquired to confirm progression within 12 weeks of radiotherapy, as the incidence of pseudoprogression is high during this period (up to 30%–40% of patients) [6-8].

For glioblastoma, isocitrate dehydrogenase (IDH)-wildtype, central nervous system World Health Organization (WHO) grade 4 [9], a nonenhancing disease, is no longer to be evaluated except when assessing the response to anti-angiogenic agents. Glioblastoma, IDH-wildtype, WHO grade 4, can manifest as a non-enhancing disease or as a disease without internal necrosis. This constricts the previous distinction between HGG as enhancing tumors evaluated by RANO-HGG and LGG as non-enhancing tumors evaluated by RANO-LGG [10]. Another reason for not evaluating a non-enhancing disease is the difficulty in quantitatively measuring previous non-enhancing diseases and differentiating them from various treatment-related changes (i.e., edema and radiation effects).

PD in RANO 2.0 can be defined based on: 1) the presence of measurable disease on baseline imaging (post-radiation therapy imaging), 2) presence of measurable disease on current imaging, 3) timing of current imaging (within or more than 12 weeks after radiation therapy), and 4) a comparison between the baseline and current imaging. The most important determinant is the timing of imaging. The details are summarized as “response criteria for enhancing tumors” and “summary of overall response status” in RANO

2.0 [2]. Here, we provide details focusing on PD, especially for glioblastoma, IDH-wildtype (Table 1).

Response assessment is straightforward if “current imaging” is performed 12 weeks after radiation. When measurable contrast-enhancing target lesions ($\geq 10 \times 10$ mm) are observed on baseline imaging, 1) an additional $\geq 25\%$ increase in the area or $\geq 40\%$ increase in volume (“target increase”) on current imaging and 2) any new measurable enhancing lesion ($\geq 10 \times 10$ mm) are considered as PD. If there is uncertainty in studies associated with a high incidence of pseudoprogression (i.e., immunotherapy), the patient may continue treatment and remain under close observation; the lesion may be added to the target lesion and followed up. When there is no measurable enhancing disease on baseline imaging, any new measurable ($\geq 10 \times 10$ mm) enhancing lesions are considered as PD.

In contrast, response assessments in the time window within 12 weeks of radiotherapy should always consider the possibility of pseudoprogression. When measurable contrast-enhancing target lesions ($\geq 10 \times 10$ mm) are observed on baseline imaging, with an additional $\geq 25\%$ increase in the

area or $\geq 40\%$ increase in volume (“target increase”), then at least two sequential scans separated by ≥ 4 weeks of target increase are required for the diagnosis of PD. This ‘two sequential scans’ refers to the current/original scan (N) and a second scan (N+1) in a sequential manner. If the second scan shows stable disease (SD) or a partial or complete response (PR/CR), the previous scan is denoted as pseudoprogression; the patient should then continue therapy. However, the appearance of a new measurable enhancing lesion ($\geq 10 \times 10$ mm) should not be immediately considered as PD; rather, it should be added to the sum of the products or total volume, followed by mandatory scans for confirmation. A new measurable lesion will be considered PD if: 1) it is clearly outside the radiation field (e.g., beyond the high-dose region or 80% isodose line), 2) there is pathologic confirmation, and 3) it is confirmed by a subsequent scan showing an increase in the sum of products or total volume.

Notably, a clear progression of non-measurable lesions (5×5 mm to $\geq 10 \times 10$ mm) does not solely indicate PD, and thus should be added to the sum of the target lesions

Table 1. Definition of PD for glioblastoma, IDH-wildtype (enhancing tumors) in RANO 2.0

Baseline imaging		Current imaging		Overall response status
Presence of measurable disease ($\geq 10 \times 10$ mm)	Timing of current imaging	Target size or volume increase*	New measurable lesion	Is it PD?
Yes	>12 weeks	Yes	No	PD. However, if there is uncertainty, the patient may continue on treatment and the lesion can be summed up to total size or volume and determine PD on subsequent follow-up
Yes	>12 weeks	No	Yes	PD. However, if there is uncertainty, the patient may continue on treatment and the lesion can be summed up to total size or volume and determine PD on subsequent follow-up
No (nonmeasurable)	>12 weeks	No	Yes	PD
Yes	Within 12 weeks [†]	Yes	No	No, assign it as preliminary PD and perform confirmatory scan (sequential with at least ≥ 4 weeks of target increase)
Yes	Within 12 weeks [†]	No	Yes	No, assign it as preliminary PD and perform confirmatory scan. Should be summed up to total size or volume and determine PD
No (nonmeasurable)	Within 12 weeks [†]	No	Yes	No, assign it as preliminary PD. Should be summed up to total size or volume and determine PD at confirmatory scan [‡]

*Size and volume increase indicates an additional $\geq 25\%$ increase in area or $\geq 40\%$ increase in volume, [†]Within 12 weeks after completion of radiotherapy, progression clearly outside the radiation field (e.g., beyond the high-dose region or 80% isodose line) or pathologic confirmation does not require subsequent scans for confirmation, [‡]New sites of measurable disease constitute PD in cases of non-measurable disease at baseline or with the best response. If confirmatory scans are required, new sites are added to the sum of the bi-dimensional products or the total lesion volume. The new lesion may be considered as PD if confirmed by a subsequent scan performed ≥ 4 weeks later.

PD = progressive disease, IDH = isocitrate dehydrogenase, RANO = Response Assessment in Neuro-Oncology

(measurable lesions) for PD confirmation. Furthermore, the appearance of definite leptomeningeal disease was considered PD.

We provided two illustrations to demonstrate PD for glioblastoma, IDH-wildtype. Figure 1 demonstrates a case in which current imaging was acquired 12 weeks after the completion of concurrent chemoradiation therapy (CCRT), when pseudoprogression rarely occurred. According to RANO 2.0, in presence of a measurable enhancing lesion in the baseline imaging, an increase in the size of a measurable enhancing lesion or any new measurable enhancing lesion on current imaging is designated as PD. Moreover, when there is no enhancing disease on baseline imaging (0), any new measurable ($\geq 10 \times 10$ mm) enhancing lesions are considered PD. The date of progression was the date of the current imaging (N). Figure 2 shows a case in which imaging was performed within 12 weeks of CCRT, when the rate of pseudoprogression was high. When measurable contrast-enhancing target lesions ($\geq 10 \times 10$ mm) are

visualized on baseline imaging (0) and the size of the measurable enhancing lesion increases on current imaging (N), then at least two sequential scans (N+1 after N) performed separated by ≥ 4 weeks of target increase are required for the diagnosis of PD. At this point, the date of progression is N. Moreover, the appearance of a new measurable enhancing lesion ($\geq 10 \times 10$ mm) in this period (pseudoprogression period) should not be immediately considered as PD. Instead, it should be added to the sum of the target measurable diseases, and a confirmatory scan is required. If the second scan exhibits SD or PR/CR, the previous scan is denoted as pseudoprogression, and the patient should continue temozolomide therapy.

Notably, when utilizing the tables in RANO 2.0, we recommend the use of “Criteria for Enhancing Tumors” for glioblastoma, IDH-wildtype and “Criteria for Non-enhancing Tumors” for IDH-mutated, non-enhancing gliomas. “Criteria for Both Enhancing and Nonenhancing Components” can be used for tumors with a mixture of both components,

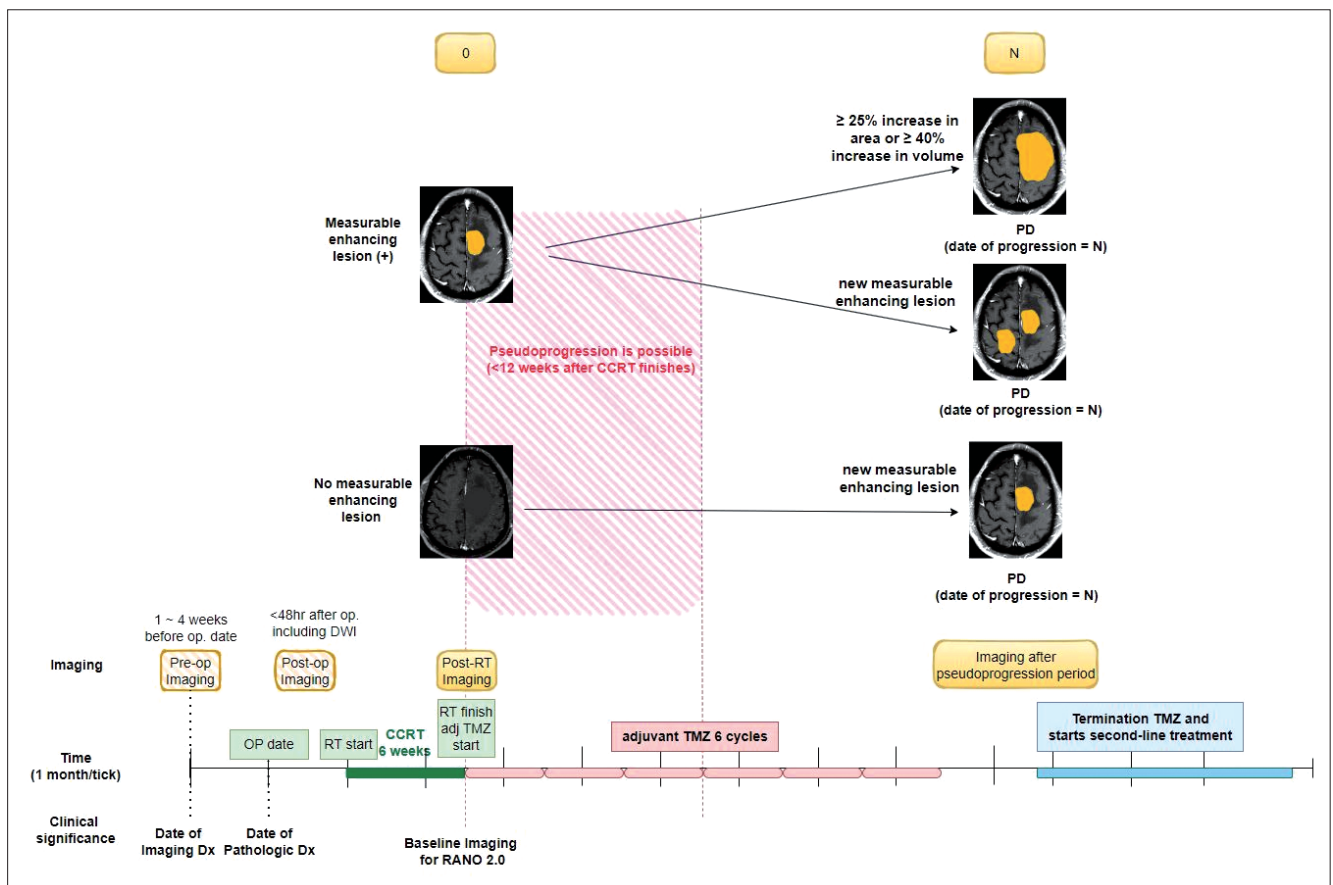


Fig. 1. Response assessment according to RANO 2.0, when current imaging is obtained after the pseudoprogression period (>12 weeks after completion of post-RT or CCRT). RANO = Response Assessment in Neuro-Oncology, RT = radiation therapy, CCRT = concurrent chemoradiation therapy, OP = operation, Dx = diagnosis, DWI = diffusion-weighted imaging, adj = adjuvant, TMZ = temozolomide, PD = progressive disease

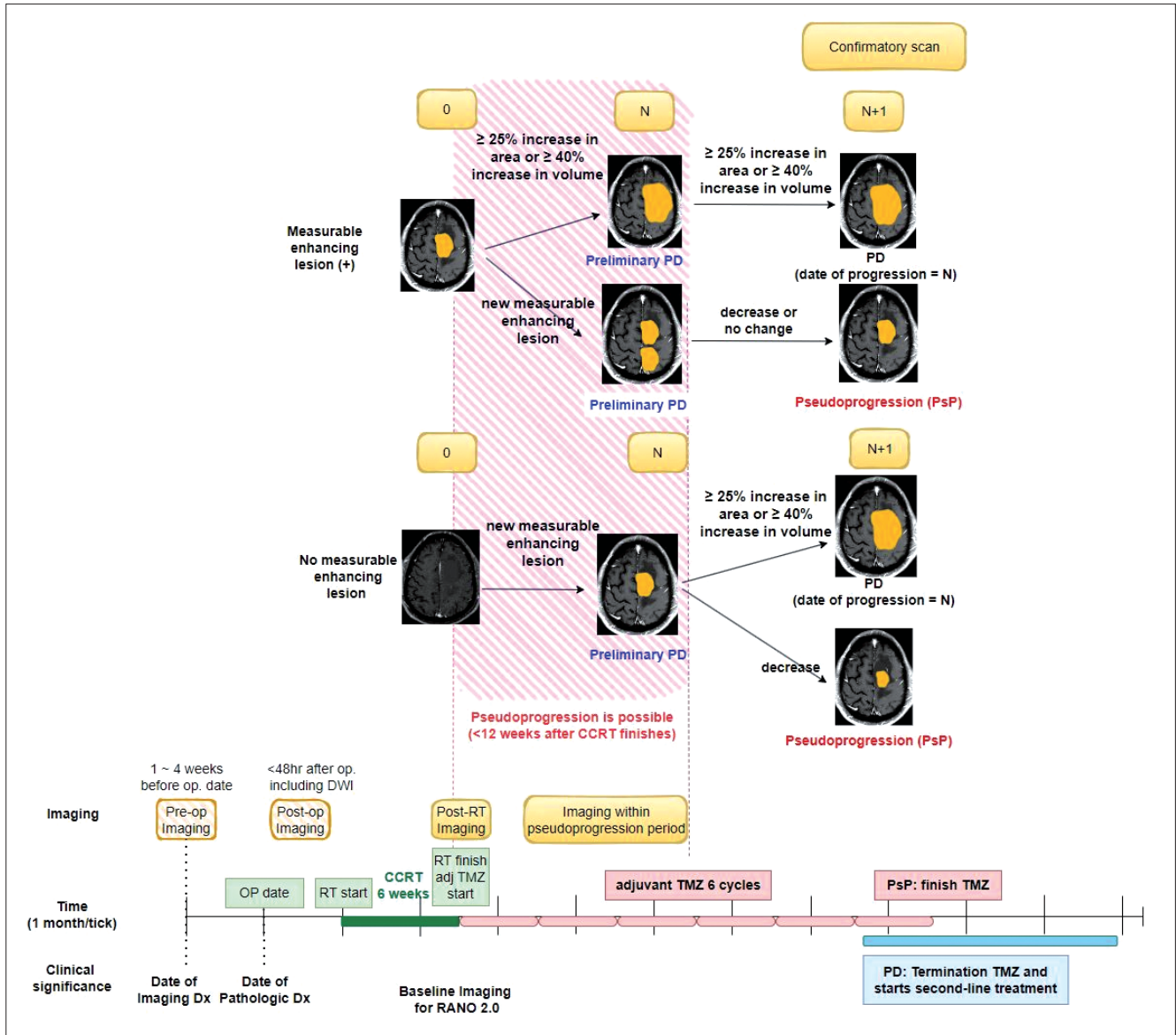


Fig. 2. Response assessment according to RANO 2.0, when current imaging is obtained within the pseudoprogression period (within 12 weeks after completion of post-RT or CCRT). RANO = Response Assessment in Neuro-Oncology, RT = radiation therapy, CCRT = concurrent chemoradiation therapy, OP = operation, Dx = diagnosis, DWI = diffusion-weighted imaging, adj = adjuvant, TMZ = temozolomide, PD = progressive disease

including diffuse midline gliomas, H3K27-altered, IDH-wildtype glioblastoma with ongoing anti-angiogenic therapy, and high-grade IDH-mutated gliomas.

Using these details, we can refine some of the statements made by Won et al. [1] from KJR summary as follows:

1) "Progressive disease (PD) is defined as an increase of $\geq 25\%$ in the sum of the product of the perpendicular diameters of all measurable target lesions, or a volume increase of $\geq 40\%$ compared to the smallest tumor measurements at baseline or after the start of treatment. The discovery of new measurable

lesions is also considered PD."

This statement can mislead the determination of PD because response assessment is vastly different according to the timing of imaging, visualized within 12 weeks and >12 weeks after the completion of radiation therapy. In cases where the patient has undergone imaging more than 12 weeks after radiation therapy, the definition of PD is correct. Moreover, the appearance of a new measurable lesion, when the baseline scan demonstrated no measurable enhancing disease, was considered PD. However, these rules are not applicable in cases where imaging is performed

within 12 weeks of radiotherapy, thus necessitating a subsequent confirmatory scan.

2) *“In this case, they are added to the sum of the existing target lesions, and if the area increases by $\geq 25\%$ or the volume increases by $\geq 40\%$ in subsequent repeat images, PD can be confirmed.”*

This statement is overly simplified and may be misconstrued by readers; this criterion is applicable only when the patient requires a confirmatory scan (within 12 weeks of radiotherapy). Within 12 weeks of radiotherapy completion, a new lesion was added to the target lesion and thus, PD was confirmed by an increase in size or volume. On the other hand, when a new measurable lesion observed >12 weeks after the completion of radiotherapy can confirm PD.

3) *“Additionally, if nonmeasurable lesions increase by a minimum of 5 x 5 mm or become measurable ($\geq 10 \times 10$ mm) and if nontarget lesions increase by 25% in area or 40% in volume, it can also be defined as clear PD. In this case, they are added to the sum of existing target lesions, and if the total sum of the product of the perpendicular diameters in the target lesions exceeds 25% in area or 40% in volume compared to the previous measurement, it is considered PD-confirmed. This analysis is performed to distinguish between pseudoprogession and true PD. If PD is confirmed on subsequent images, the PD date is retroactively set to the point at which initial tumor progression was recorded.”*

Unfortunately, this statement seems incorrect because clear progression of a non-measurable lesion constitutes the progression of a non-target lesion, not PD (i.e., overall response status of a patient). According to RANO 2.0, the sole progression of a non-target lesion cannot determine the patient’s response status. Instead, progressed, non-measurable lesions (i.e., lesions that have increased by a minimum of 5 x 5 mm or have become measurable [$\geq 10 \times 10$ mm]) are added to the target lesion; PD is then confirmed by the increase in size or volume of the target lesion. The authors also state the following: “This analysis was performed to distinguish between pseudoprogession and true PD.” However, progression of non-target lesions is not necessarily associated with pseudoprogession; rather, the time window (within 12 weeks vs. >12 weeks) is related to pseudoprogession.

In conclusion, we aimed to provide details of PD, especially in glioblastoma, IDH-wildtype in this letter. We hope that this letter will serve as a useful reference for

clinical trials.

Conflicts of Interest

Ji Eun Park and Ho Sung Kim, who hold respective positions on the Editorial Board Member and Section Editor of the *Korean Journal of Radiology*, were not involved in the editorial evaluation or decision to publish this article. The remaining author has declared no conflicts of interest.

Author Contributions

Conceptualization: Ji Eun Park, Yae Won Park. Funding acquisition: Ji Eun Park, Ho Sung Kim. Investigation: Ji Eun Park, Yae Won Park. Supervision: Young-Hoon Kim, Sang Woo Song, Chang-Ki Hong, Jeong Hoon Kim. Validation: Young-Hoon Kim, Sang Woo Song, Chang-Ki Hong, Jeong Hoon Kim, Ho Sung Kim. Visualization: Ji Eun Park, Yae Won Park. Writing—original draft: Ji Eun Park, Yae Won Park. Writing—review & editing: Young-Hoon Kim, Sang Woo Song, Chang-Ki Hong, Jeong Hoon Kim, Ho Sung Kim.

ORCID IDs

Ji Eun Park
<https://orcid.org/0000-0002-4419-4682>
 Yae Won Park
<https://orcid.org/0000-0001-8907-5401>
 Young-Hoon Kim
<https://orcid.org/0000-0002-8852-6503>
 Sang Woo Song
<https://orcid.org/0000-0002-5523-3798>
 Chang-Ki Hong
<https://orcid.org/0000-0002-2761-0373>
 Jeong Hoon Kim
<https://orcid.org/0000-0001-7131-4523>
 Ho Sung Kim
<https://orcid.org/0000-0002-9477-7421>

Funding Statement

This research was supported by the National Research Foundation of Korea (NRF) grant funded by the Korean government (MSIP) (grant number: RS-2023-00208227 and RS-2023-00305153).

REFERENCES

1. Won SE, Suh CH, Kim S, Park HJ, Kim KW. Summary of key points of the response assessment in neuro-oncology (RANO) 2.0. *Korean J Radiol* 2024;25:407-411

2. Wen PY, van den Bent M, Youssef G, Cloughesy TF, Ellingson BM, Weller M, et al. RANO 2.0: update to the response assessment in neuro-oncology criteria for high- and low-grade gliomas in adults. *J Clin Oncol* 2023;41:5187-5199
3. Wen PY, Macdonald DR, Reardon DA, Cloughesy TF, Sorensen AG, Galanis E, et al. Updated response assessment criteria for high-grade gliomas: response assessment in neuro-oncology working group. *J Clin Oncol* 2010;28:1963-1972
4. van den Bent MJ, Wefel JS, Schiff D, Taphoorn MJ, Jaeckle K, Junck L, et al. Response assessment in neuro-oncology (a report of the RANO group): assessment of outcome in trials of diffuse low-grade gliomas. *Lancet Oncol* 2011;12:583-593
5. Ellingson BM, Wen PY, Cloughesy TF. Modified criteria for radiographic response assessment in glioblastoma clinical trials. *Neurotherapeutics* 2017;14:307-320
6. Ellingson BM, Gerstner ER, Lassman AB, Chung C, Colman H, Cole PE, et al. Hypothetical generalized framework for a new imaging endpoint of therapeutic activity in early phase clinical trials in brain tumors. *Neuro Oncol* 2022;24:1219-1229
7. Shidoh S, Savjani RR, Cho NS, Ullman HE, Hagiwara A, Raymond C, et al. Relapse patterns and radiation dose exposure in IDH wild-type glioblastoma at first radiographic recurrence following chemoradiation. *J Neurooncol* 2022;160:115-125
8. Taal W, Brandsma D, de Bruin HG, Bromberg JE, Swaak-Kragten AT, Smitt PA, et al. Incidence of early pseudo-progression in a cohort of malignant glioma patients treated with chemoirradiation with temozolomide. *Cancer* 2008;113:405-410
9. Louis DN, Perry A, Wesseling P, Brat DJ, Cree IA, Figarella-Branger D, et al. The 2021 WHO classification of tumors of the central nervous system: a summary. *Neuro Oncol* 2021;23:1231-1251
10. Wen PY, van den Bent M, Vogelbaum MA, Chang SM. RANO 2.0: the revised response assessment in neuro-oncology (RANO) criteria for high- and low-grade glial tumors in adults designed for the future. *Neuro Oncol* 2024;26:2-4