

Case Report

# Diagnostic and Therapeutic Challenges of Rare Concurrent Intracranial Meningioma and Oligodendroglioma

Ali Shoushtari<sup>a</sup> Lorraina Robinson<sup>b</sup> Qinwen Mao<sup>b</sup> Lubdha M. Shah<sup>c</sup>  
Karen L. Salzman<sup>c</sup> Sarah T. Menacho<sup>d</sup>

<sup>a</sup>Monash University School of Medicine, Melbourne, VIC, Australia; <sup>b</sup>Department of Pathology, University of Utah, Salt Lake City, UT, USA; <sup>c</sup>Department of Radiology, University of Utah, Salt Lake City, UT, USA; <sup>d</sup>Department of Neurosurgery, Clinical Neurosciences Center, University of Utah, Salt Lake City, UT, USA

## Keywords

Brain tumor · Case report · Meningioma · Oligodendroglioma

## Abstract

**Introduction:** Concurrent primary brain tumors are rare clinical entities, with a prevalence ranging from 0.1 to 0.5% of all diagnosed brain tumors. The co-occurrence of meningioma and oligodendroglioma is particularly uncommon, posing unique diagnostic and therapeutic challenges. We describe the case of a patient diagnosed with concurrent meningioma and oligodendroglioma and review the existing literature on this rare phenomenon. **Case Presentation:** A 55-year-old female patient with a history of seizures presented to the emergency department with worsening headaches, nausea, and vomiting. She had a known right frontoparietal intracranial mass but had previously declined surgery. Magnetic resonance imaging revealed extensive fluid-attenuated inversion recovery /T2 hyperintensity around the lesion, which had slowly increased over 5 years; the growth of the lesion was producing a mass effect with a significant midline shift. The patient underwent urgent hemicraniectomy with subsequent resection. Clinical evaluation, imaging studies, and histopathological examination were conducted to confirm the diagnosis. Genetic and molecular analyses were also performed to explore potential underlying mechanisms. Histopathological findings confirmed a diagnosis of an isocitrate dehydrogenase-mutated World Health Organization Grade II oligodendroglioma with 1p/19q codeletion, along with a Grade I meningioma. **Conclusion:** The coexistence of meningioma and oligodendroglioma represents a rare clinical event. Surgical management remains the

cornerstone of treatment. Further investigation into the genetic and environmental factors that contribute to the co-occurrence of such tumors could pave the way for more targeted therapeutic strategies.

© 2024 The Author(s).  
Published by S. Karger AG, Basel

## Introduction

Concurrent primary brain tumors have been previously associated with cranial radiation and neurocutaneous syndromes but remain a rare clinical phenomenon [1]. The prevalence of coexisting brain tumors is exceedingly low, with an incidence reported to range from 0.1 to 0.5% of all diagnosed brain tumors [2]. The rarity of this condition is further underscored when examining specific tumor combinations, such as the co-occurrence of meningioma and oligodendrogliomas, which has only been reported in 6 cases to date (Table 1) [2–6].

Together, meningiomas and oligodendrogliomas constitute 45% of diagnosed primary brain tumors but generally present independently [7]. Their simultaneous presence poses unique challenges in both diagnosis and treatment modalities. In this report, we describe the case of a patient with biopsy-proven concurrent meningioma and oligodendroglioma and present a comprehensive review of the relevant literature. Written informed consent was obtained from the patient for publication of this case report and any accompanying images. The CARE Checklist has been completed by the authors for this report, attached as online supplementary material (for all online suppl. material, see <https://doi.org/10.1159/000539850>).

## Case Presentation

### *Clinical Presentation*

A 55-year-old woman with medically controlled seizures (levetiracetam) presented with acute worsening of her chronic headache, accompanied by nausea and vomiting. She had a known intracranial mass and had previously declined surgery in favor of serial imaging, with a presumed diagnosis of meningioangiomatosis based on radiographic findings alone (Fig. 1a–c).

### *Surgical Management*

Upon clinical evaluation, the patient was notably somnolent and had an initial Glasgow Coma Scale (GCS) score of 12. A head computed tomography scan demonstrated a calcified right frontoparietal mass with 13 mm of midline shift, effacement of the third ventricle and basal cisterns, and concern for right uncal herniation (Fig. 1d, e). In light of her neurologic examination, the patient was taken for an emergent right decompressive hemicraniectomy. Intraoperatively, the brain was noted to be extremely swollen. Two separate areas of the mass were biopsied, and the craniotomy flap was left off. The patient was admitted to the neurocritical care unit and recovered to GCS 15. Postoperative imaging at 24 h showed decreased mass effect and midline shift (Fig. 2a). Tumor resection was planned for a second-stage operation.

Preoperative magnetic resonance imaging of the brain demonstrated a heterogeneously enhancing right frontoparietal mass that appeared predominantly intra-axial with a possible extra-axial component at its most superior aspect. There was extensive surrounding fluid-attenuated inversion recovery/T2 hyperintensity with gyriform gradient susceptibility related to

**Table 1.** Concurrent meningioma and oligodendroglioma cases reported in the literature

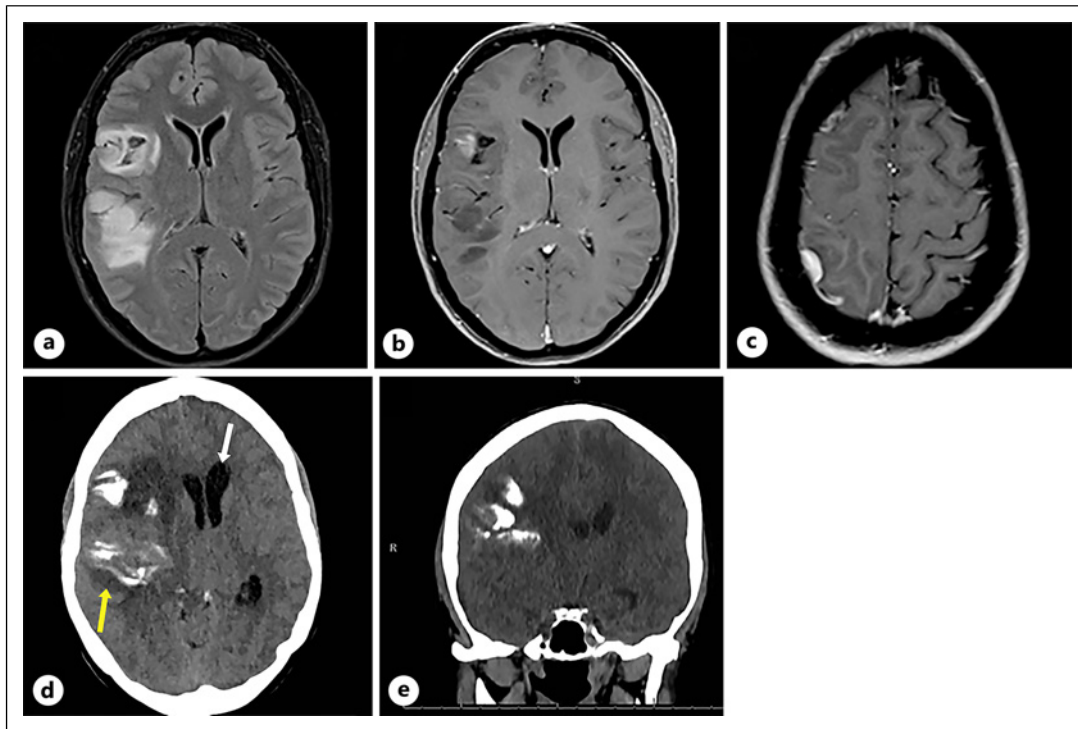
Author	Age/ sex	Presentation	Location	Other pertinent details
Gass and Van Wagenen [2] (1950)	56/F	Grand mal seizure	Right frontoparietal lobe	Remained seizure-free for 6 years postoperatively
Schulze [3] (1959)	22 M	Seizures	Left parietal	No follow-up given
Elam and McLaren [15] (1961)	25/F	Headaches, blurry vision	Left frontal, extending into the ventricle	Survived to 19 years post-resection
Tanaka et al. [4] (1975)	40/F	Nausea, headaches, papilledema	Left frontal, extending into the ventricle	Required a shunt postoperatively, no follow-up after 9 months
Solmaz et al. [5] (2012)	55/F	Chronic headache, urinary incontinence	Right frontal lobe and vertex	Gross-total resection followed by radiation (54 Gy), followed by surveillance imaging
Munjal et al. [6] (2019)	51/M	Grand mal seizure	Right temporal lobe and adjacent right insula	No patient follow-up available

calcification and dystrophic mineralization. The lesion caused a significant mass effect, closely approximating and medially displacing the posterior limb of the internal capsule (Fig. 2b, c). The planned second-stage procedure was performed on postoperative day 12 by reopening the existing hemicraniectomy incision, and both neuronavigation and neuromonitoring were used to ensure a maximal safe resection. The bone flap was not replaced at the end of the case because of ongoing cerebral edema. Postoperative imaging demonstrated a near-total resection of the lesion with no evidence of acute postsurgical complications (Fig. 2d, e). The patient made an excellent recovery after a stay in inpatient rehabilitation and tolerated her autologous cranioplasty without incident. She was started on concomitant radiation with temozolomide for a World Health Organization (WHO) Grade II oligodendroglioma.

#### *Histopathology and Ancillary Testing*

Histopathological and ancillary tests were done on both samples (Fig. 3). Histopathological examination of the first resected dural-based right frontal lobe mass revealed a meningothelial meningioma with frequent, scattered psammoma bodies (Fig. 3a). No necrosis, sheet-like growth, increased cellularity, prominent nucleoli, or small cell change was observed. The mitotic index was 0/10 high-power fields (HPFs). No brain parenchyma or brain invasion was identified. The MIB-1 proliferation index was approximately 1%. Immunohistochemistry staining with somatostatin receptor 2 (Fig. 3c) and epithelial membrane antigen (Fig. 3e) demonstrated strong diffuse positivity and weak, patchy positivity in the meningothelial tumor cells, respectively.

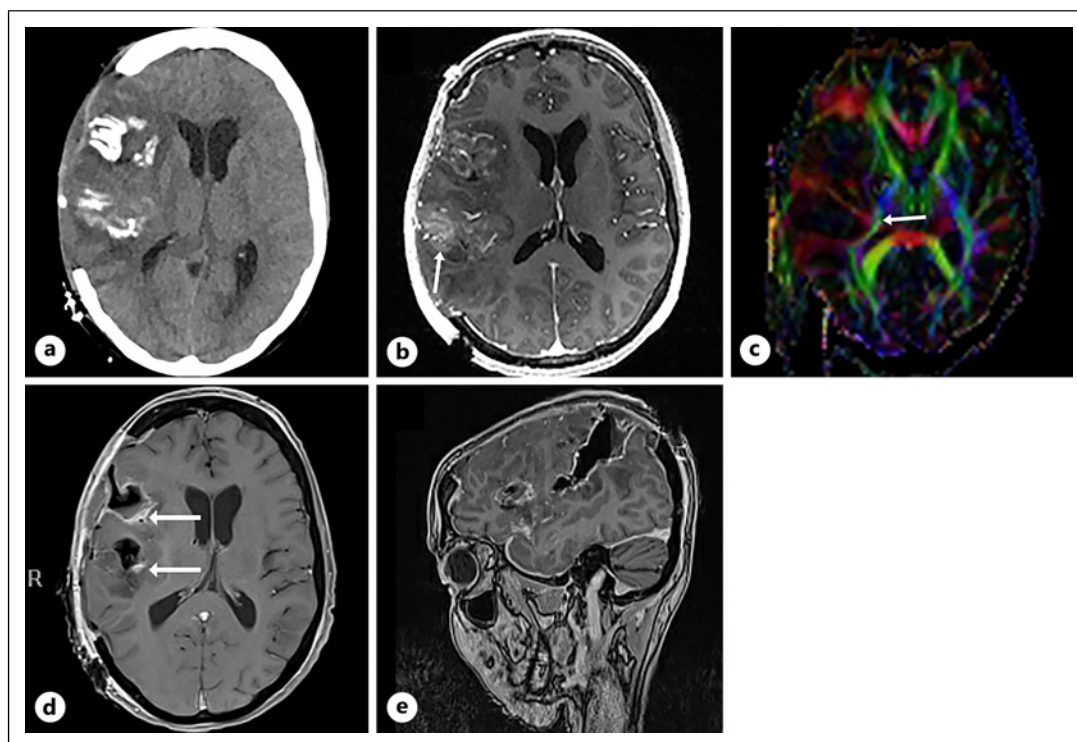
Sections of the specimen were sent for DNA methylation-based tumor profiling at the National Institutes of Health (NIH) using versions 11b6 and 12b6 of the Heidelberg classifier and the National Cancer Institute/Bethesda classifier. The methylation-based tumor profiling indicated a consensus match within the meningioma subclass with a high confidence score. The final integrated diagnosis for this initial specimen was a meningioma, central nervous system WHO Grade I.



**Fig. 1.** **a** Axial FLAIR MRI showing a heterogeneous mass involving the right frontal and parietal lobes. **b** Axial T1-weighted MRI with contrast showing mild enhancement along the more anterior portion of the mass. **c** Axial T1-weighted MRI with contrast showing dural enhancement along the superior portion of the mass. Axial (**d**) and coronal (**e**) head CT at presentation demonstrating a large right frontal and parietal mass with gyriform calcification (yellow arrow) and new mass effect with midline shift and early hydrocephalus (white arrow). FLAIR, fluid-attenuated inversion recovery.

Histopathological examination of the second resected right frontal mass showed an infiltrating glioma with tumor cells displaying rounded, hyperchromatic nuclei, and perinuclear halos (Fig. 3b). The mitotic index was 2/10 HPFs. No high-grade features were identified (i.e., necrosis, microvascular proliferation). Abundant psammomatous calcifications were noted. Immunohistochemistry demonstrated the following tumor immunoprofile: positive glial-fibrillary acidic protein (Fig. 3d), positive isocitrate dehydrogenase (IDH)1-R132H (Fig. 3f), ATRX expression retained, p53 positive in 5% of tumor cell nuclei, and an MIB-1 proliferation index of approximately 5%.

Sections of the second resected tumor were sent for  $O^6$  methylguanine-DNA methyltransferase (MGMT) promoter methylation, epidermal growth factor receptor (EGFR) gene amplification, 1p/19q codeletion, and DNA methylation tumor profiling. MGMT promoter methylation was detected via droplet digital polymerase chain reaction. EGFR gene amplification by fluorescent in situ hybridization (FISH) showed that the tumor cells were non-amplified. 1p/19q chromosome evaluation by FISH studies revealed the tumor cells were 1p/19q codeleted. Methylation-based tumor profiling was performed at the NIH, which used the same classifiers as previously described. The composite methylation profile indicated a consensus match within the IDH glioma subclass 1p/19q codeleted oligodendroglioma with a high confidence score. The final integrated diagnosis for the second resected tumor was an oligodendroglioma, IDH-mutant, and 1p/19q codeleted, central nervous system WHO Grade II.



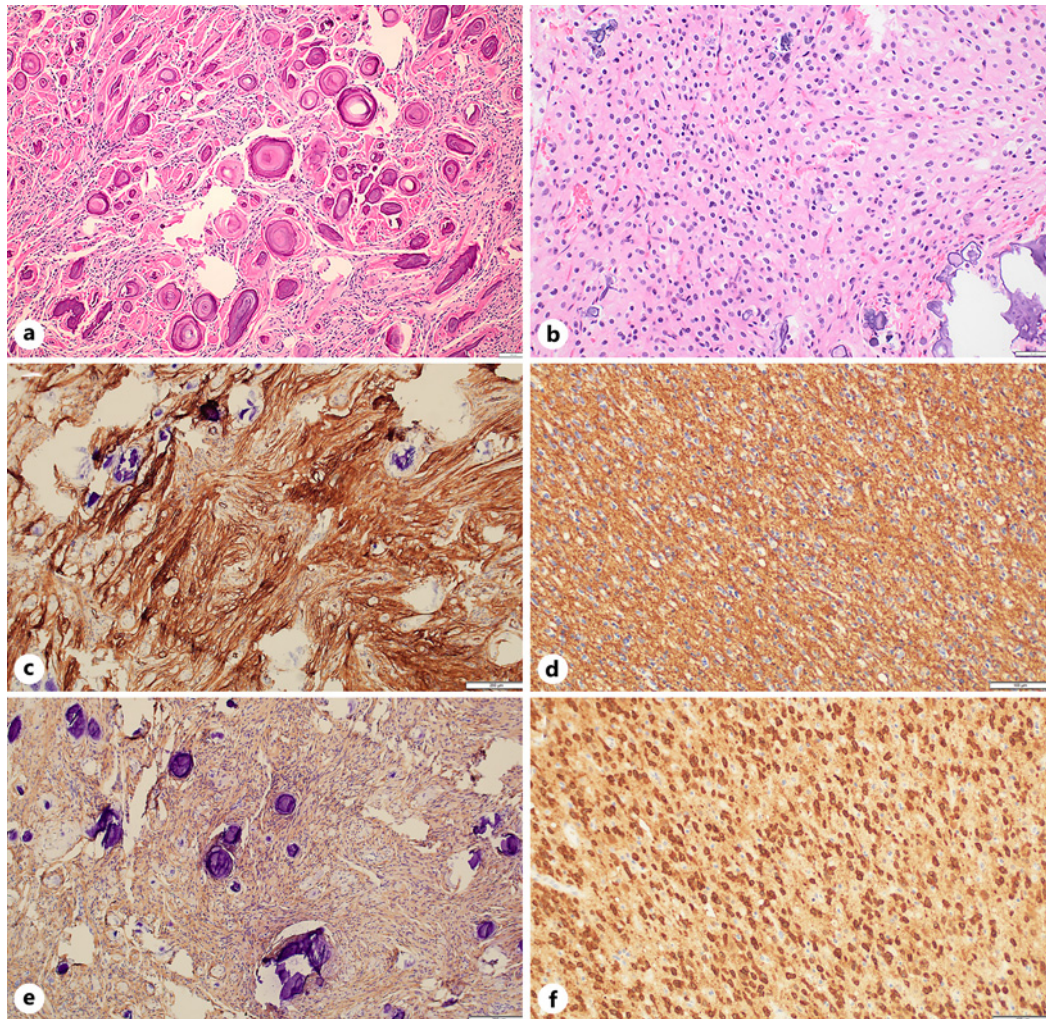
**Fig. 2.** **a** Axial head CT postoperative day 1 after craniectomy. **b** Axial T1-weighted stereotactic postcontrast MRI showing the heterogeneous mass with gyriform calcification (white arrow) and mild enhancement. **c** Axial diffusion tensor imaging demonstrating the right corticospinal tract is medially deviated by the mass (arrow). Postoperative axial (**d**) and sagittal (**e**) MRI with contrast.

## Discussion

The coexistence of oligodendroglioma and meningioma as concurrent primary brain tumors is rare, with only a handful of cases previously reported in the literature (Table 1) [6]. The incidence of concurrent primary brain tumors is only 0.3% of cases, with meningioma and glioma being the most common combination [1]. One plausible cause of the pathogenesis of multiple primary brain tumors of different histological types is genetic predisposition. Certain individuals, such as those with neurofibromatosis type 2 or tuberous sclerosis, may harbor germline mutations or genetic alterations that predispose them to the development of multiple primary brain tumors [8]. Specific gene mutations, such as disruptions in p53 and receptor tyrosine kinase signaling pathways that express platelet-derived growth factor receptors (PDGFRs), have been identified. Although PDGF plays a pivotal role in angiogenesis and may facilitate tumorigenesis, existing studies have not provided consistent evidence to substantiate this hypothesis [9]. Extensive genetic workup of our patient revealed no predisposing factors for concurrent primary brain lesions.

PDGFR consists of alpha- and beta-subunits, encoded by genes located on q11-q12 of chromosome 4 and 5q13-32 of chromosome 5, respectively [10]. One would expect that coexisting tumors like meningioma and oligodendroglioma would exhibit mutations at both loci; however, genetic analyses in studies examining glioblastoma and meningioma have revealed disparate genetic mutations, thereby challenging the notion of a common genetic pathway as the underlying mechanism for concurrent tumors [9].





**Fig. 3.** Immunohistochemical evaluation and ancillary testing of meningioma (**a, c, e**) and oligodendroglioma (**b, d, f**). **a** Hematoxylin and eosin (H&E) stain of the dural-based right frontal mass. Scale bar: 100 µm. **b** H&E stain of right frontal mass. Scale bar: 50 µm. **c** Somatostatin receptor 2 stain showing strong, diffuse positivity in the meningothelial tumor cells. Scale bar: 200 µm. **d** Glial fibrillary acidic protein (GFAP) stain highlighting diffuse positive cytoplasmic staining in all of the oligodendroglioma tumor cells. Scale bar: 100 µm. **e** Epithelial membrane antigen stain highlighting weak, patchy positivity in the meningothelial tumor cells. Scale bar: 200 µm. **f** Isocitrate dehydrogenase IDH1(R132H) stain showing intense cytoplasmic reactivity in all of the oligodendroglioma tumor cells. Scale bar: 100 µm.

Other potential causes of concurrent primary brain tumors include exposure to ionizing radiation, neurocutaneous syndromes, and trauma, which have all been implicated as causal factors for tumorigenesis [1, 4, 11]. Other environmental contributors, such as chemical exposures or viral infections, may also play a role, although further investigation is required to elucidate these mechanisms in the context of concurrent primary brain tumors [1, 4].

Another hypothesis relates to local tissue irritation, specifically perilesional edema, which could induce astrocyte and arachnoid cell transformation, thereby promoting neoplastic transformation of adjacent cells. This theory is limited in scope because it fails to account for topographically disconnected concurrent tumors [12].

Lastly, the association between the two primary tumors may simply be coincidental. This is likely not the case because the incidence of the co-occurrence of some tumors (e.g.,

meningioma and gliomas) is twice that of when these tumors develop as single lesions on their own [7]. Conversely, tumors such as oligodendrogliomas, ependymomas, and cranio-pharyngiomas occur more frequently as single lesions, and their occurrence in conjunction with another primary brain tumor is rare.

### *Meningioangiomatosis*

Initially, imaging of gyriform parenchymal calcification on computed tomography led to a presumed diagnosis of meningioangiomatosis in our patient. Meningioangiomatosis is a rare intracranial hamartomatous entity that can occur sporadically or in the setting of neurofibromatosis type 2 [13]. Sporadic meningioangiomatosis often presents with seizures and headaches, both of which our patient exhibited. Meningioangiomatosis can be variable in appearance but is characterized radiographically by evidence of calcification in over 90% of cases [14]. Enhancement patterns vary widely, with the majority of lesions showing some enhancement after contrast administration.

### *Management*

One of the main questions that arises in the management of multiple primary brain tumors is whether to resect the tumors in a single surgery or to perform the resection over multiple operations. The consensus from the literature suggests that if the lesions are contiguous, as was the case in the patient presented here, a single operation may be performed to resect both tumors [11]. However, a staged operation is likely the preferred option in cases where the tumors are topographically disconnected and cannot be accessed through a single craniotomy. In our case, the surgery was staged because the patient presented in neurologic extremis and was not likely to tolerate a lengthy tumor resection at the time of the emergent hemicraniectomy.

Primary malignant tumors such as gliomas should be removed as a matter of priority because they are the main indicator of the patient's prognosis. The second tumor may be observed with or without adjuvant treatment if it is benign, asymptomatic, or slow growing [11]. Given her age and the fact that there was a small amount of tumor remaining in her eloquent cortex, the patient in this case required adjuvant chemoradiation for the WHO Grade II oligodendroglioma.

On the basis of the available literature and the imaging appearance, it does not seem feasible to diagnose two separate primary tumors at adjacent sites preoperatively [6]. Instead, there should be a high index of suspicion if, intraoperatively, the tumor does not seem to correlate with radiographic imaging in terms of the extent of perilesional edema. Obtaining tissue via biopsy or resection is the definitive way to diagnose concurrent primary brain tumors, and treatment decisions should be based on the pathology. Unfortunately, there is not currently sufficient literature available to discuss outcomes in patients with this rare combination of a simultaneous meningioma and oligodendroglioma. The patient is treated via the pathology with the higher grade; for example, our patient is undergoing adjuvant therapies for the oligodendroglioma and the meningioma will be followed with surveillance imaging.

### **Conclusion**

In this study, we describe a rare case of a patient with concurrent meningioma and oligodendroglioma. The underlying pathophysiology for the coexistence of these distinct tumors remains elusive. Surgical intervention remains the cornerstone of treatment, particularly when the tumors are contiguous, as in the case presented. The decision to opt

for a single or staged surgical approach depends on various factors, including the topographical relationship between the tumors and their respective malignancy grades. Although surgical management is currently the mainstay of treatment, a deeper understanding of the genetic and environmental factors contributing to this phenomenon is imperative. Future studies should aim to unravel the complex interplay of genetic and environmental factors, which could pave the way for more targeted therapeutic strategies.

## Acknowledgments

We thank Kristin Kraus and Cortlynd Olsen for editorial assistance.

## Statement of Ethics

Written informed consent was obtained from the patient for publication of this case report and any accompanying images. This study protocol was reviewed, and the need for approval was waived by the University of Utah Institutional Review Board.

## Conflict of Interest Statement

The authors have no conflicts of interest to report.

## Funding Sources

This research did not receive grants from any funding agency in the public, commercial, or not-for-profit sectors.

## Author Contributions

A.S: manuscript writing, research, and literature review. L.R and Q.M: pathology images and manuscript writing. L.M.S and K.L.S: radiology images and manuscript writing. S.T.M: manuscript writing and editing, research, and literature review.

## Data Availability Statement

All data generated or analyzed during this study are included in this article. Further inquiries can be directed to the corresponding author.

## References

- 1 Kan P, Gottfried O, Blumenthal DT, Townsend JJ, Drozd-Borysiuk E, Brothman AR, et al. Oligodendroglioma and juvenile pilocytic astrocytoma presenting as synchronous primary brain tumors. Case report with histological and molecular differentiation of the tumors and review of the literature. *J Neurosurg.* 2004;100(4):700–5. <https://doi.org/10.3171/jns.2004.100.4.0700>



- 2 Gass H, Van Wagenen WP. Meningioma and oligodendroglioma adjacent in the brain; case report. *J Neurosurg.* 1950;7(5):440–3. <https://doi.org/10.3171/jns.1950.7.5.0440>
- 3 Schulze A. Histologically different multiple brain tumors. *Acta Neurochir Suppl.* 1959;6:219–26.
- 4 Tanaka J, Garcia JH, Netsky MG, Williams JP. Late appearance of meningioma at the site of partially removed oligodendroglioma. Case report. *J Neurosurg.* 1975;43(1):80–5. <https://doi.org/10.3171/jns.1975.43.1.0080>
- 5 Solmaz İ, Pusat S, Kural C, Onguru O, Gönül E, Izci Y. Simultaneously occurring oligodendroglioma and meningioma: a rare synchronous primary brain tumors: case report and literature review. *Neurosurg Q.* 2012; 22(2):133–6. <https://doi.org/10.1097/wnq.0b013e318256efeb>
- 6 Munjal S, Kumar J, Jain S, Mehta VS. Glioma simultaneously present with adjacent meningioma: case report and literature review. *Asian J Neurosurg.* 2019;14(1):272–4. [https://doi.org/10.4103/ajns.AJNS\\_308\\_17](https://doi.org/10.4103/ajns.AJNS_308_17)
- 7 Ostrom QT, Price M, Neff C, Cioffi G, Waite KA, Kruchko C, et al. CBTRUS statistical report: primary brain and other central nervous system tumors diagnosed in the United States in 2015–2019. *Neuro Oncol.* 2022; 24(Suppl 5):v1–95. <https://doi.org/10.1093/neuonc/noac202>
- 8 Zülch K. *Brain tumors: their biology and pathology.* Springer Science and Business Media; 2012.
- 9 Nestler U, Schmidinger A, Schulz C, Huegens-Penzel M, Gamerdinger UA, Koehler A, et al. Glioblastoma simultaneously present with meningioma: report of three cases. *Zentralbl Neurochir.* 2007;68(3):145–50. <https://doi.org/10.1055/s-2007-981673>
- 10 Gronwald RG, Adler DA, Kelly JD, Distechi CM, Bowen-Pope DF. The human PDGF receptor alpha-subunit gene maps to chromosome 4 in close proximity to c-kit. *Hum Genet.* 1990;85(3):383–5. <https://doi.org/10.1007/BF00206767>
- 11 Tunthanathip T, Kanjanapradit K, Ratanalert S, Phuenpathom N, Oearsakul T, Kaewborisutsakul A. Multiple, primary brain tumors with diverse origins and different localizations: case series and review of the literature. *J Neurosci Rural Pract.* 2018;9(4):593–607. [https://doi.org/10.4103/jnrp.jnrp\\_82\\_18](https://doi.org/10.4103/jnrp.jnrp_82_18)
- 12 Davis GA, Fabinyi GC, Kalnins RM, Brazenor GA, Rogers MA. Concurrent adjacent meningioma and astrocytoma: a report of three cases and review of the literature. *Neurosurgery.* 1995;36(3):599–605. <https://doi.org/10.1227/00006123-199503000-00023>
- 13 Chen YY, Tiang XY, Li Z, Luo BN, Huang Q. Sporadic meningioangiomas-associated atypical meningioma mimicking parenchymal invasion of brain: a case report and review of the literature. *Diagn Pathol.* 2010;5:39. <https://doi.org/10.1186/1746-1596-5-39>
- 14 Tomkinson C, Lu JQ. Meningioangiomas: a review of the variable manifestations and complex pathophysiology. *J Neurol Sci.* 2018;392:130–6. <https://doi.org/10.1016/j.jns.2018.07.018>
- 15 Elam EB, McLaurin R. Multiple primary intracranial tumors. Case report. *J Neurosurg.* 1961;18:388–92. <https://doi.org/10.3171/jns.1961.18.3.0388>