

Radiological Response Assessment of Intracranial Meningioma after Cyberknife Stereotactic Radiosurgery

Hania Siddiqui¹, Shaista Shaukat¹, Shazia Kadri², Kamran Saeed² and Tariq Mehmood²

¹Department of Radiology, Jinnah Postgraduate Medical Centre, Karachi, Pakistan

²Department of Cyberknife Radiosurgery, Jinnah Postgraduate Medical Centre, Karachi, Pakistan

ABSTRACT

Objective: To evaluate the impact of stereotactic radiosurgery (SRS) with a cyberknife system on intracranial meningioma in terms of disease control / clinical outcome and radiological assessment according to the site and histological grading.

Study Design: Observational study.

Place and Duration of the Study: Cyberknife Department, Jinnah Postgraduate Medical Centre, Karachi, Pakistan, from March 2023 to May 2024.

Methodology: The study comprised 196 patients, out of which 138 were preoperative and 58 were postoperative patients. Inclusion criteria were biopsy-proven patients or those confirmed *via* imaging having lesions either unsuitable for surgery or having residual disease after surgery. Patients with atypical features of meningioma / asymptomatic were excluded from the study. The 3D T1 contrast and FLAIR sequence were used for preoperative planning; BTFE sequence was also used in cases of CP angle meningioma. Mean radiation dosage 24.3 ± 23.0 Gy was used in 3-5 fractions. Following radiosurgery, all patients underwent six months of clinical and radiological follow-up with contrast-enhanced MRI of brain.

Results: The mean age of patients was found to be 47.25 ± 13.91 years (10-81 years). Female gender was more frequently reported ($n = 126, 64.29\%$) as compared to males ($n = 70, 35.71\%$). The right side of the brain was more involved than the left. The most common sites were cerebellopontine angles in 61 (31.1%). The most common symptom was headache in 84 (42.85%) patients. About 32 (16.32%) cases were biopsy-proven Grade I and 14 (7.14%) cases were Grade II, while the rest 150 (76.53%) were selected on imaging. On follow-up imaging, radiological findings on MRI showed that the disease was stable in 126 (65.0%) patients and reduced in 64 (33.0%) patients with no oedema.

Conclusion: This study concluded that radiosurgery is a safe option for treating intracranial meningioma with a satisfactory radiological response and clinical improvement.

Key Words: Intracranial meningioma, Radiosurgery, Magnetic resonance imaging.

How to cite this article: Siddiqui H, Shaukat S, Kadri S, Saeed K, Mehmood T. Radiological Response Assessment of Intracranial Meningioma after Cyberknife Stereotactic Radiosurgery. *J Coll Physicians Surg Pak* 2025; **35(03)**:274-277.

INTRODUCTION

Overall, meningiomas represent 36.6% of all adult brain tumours and 54.5% of non-malignant brain tumours in accordance with the Central Brain Tumour Registry of the United States (CBTRUS). In Pakistan, meningiomas constitute 15.6% of all intracranial tumours making them one of the prevalent tumours.¹ It occurs more frequently in females than in males and if left untreated it can grow and affect various areas of the brain causing severe disease.^{1,2} Some patients exhibit symptoms upon initial diagnosis such as seizures, headache, vision abnormalities, and extremity weakness. Many are without symptoms, making them one of the most frequently discovered incidental brain tumours on imaging.³

The gold standard for categorising histological and aetiological meningioma factors is the World Health Organization's (WHO) grading system which divides the meningiomas into three grades: Benign (grade I), atypical (grade II), and anaplastic (grade III), further comprised 15 subtypes.^{4,5}

The conventional recommendation for small, asymptomatic meningiomas is to wait and observe. However, surgical procedures are the preferred method for treating symptomatic meningiomas. Even though meningiomas are benign tumours, the high incidence rates and complicated surgical interventions present challenges for practitioners.^{6,7} Stereotactic radiosurgery (SRS) is a distinct discipline which is now more frequently being conducted as compared to the past, predominantly for residual / recurrent disease after surgical removal and difficult areas of the brain where surgery is not possible.⁸ It utilises highly accurate, ablative cancer-killing doses of radiation to inactivate or eradicate a defined target without the need to make an incision while minimising radiation to healthy tissue and critical structures.⁹

Therefore, the aim of this study was to assess the response of SRS to meningioma radiologically and clinically in patients attending the Radiology Department.

Correspondence to: Dr. Hania Siddiqui, Department of Radiology, Jinnah Postgraduate Medical Centre, Karachi, Pakistan

E-mail: siddiquihania@gmail.com

Received: September 30, 2024; Revised: February 02, 2025;

Accepted: February 22, 2025

DOI: <https://doi.org/10.29271/jcpsp.2025.03.274>

METHODOLOGY

This prospective observational study was conducted from March 2023 to May 2024 at the Department of Cyberknife, Jinnah Postgraduate Medical Centre (JPMC), Karachi, Pakistan, using a consecutive non-probability sampling method. The study was approved by the Institutional Review Board (IRB) of the JPMC. One hundred and ninety-six patients were included in the study, out of which 138 were preoperative (such as cavernous sinus meningioma, those in supra sellar location or close to optic chiasm) with either difficult surgical approach / inoperable due to closely abutting importing anatomical structures/vessels and 58 were postoperative patients' majority biopsy-proven Grade I meningiomas and residual tumours were included in the study. Patients with atypical features of meningioma / asymptomatic were excluded from the study due to variations in the grade and separate radiation dose requirements.

All patients signed an informed consent that permitted the use of clinical, pathological, and imaging data with confidentiality at the time of hospitalisation. The planning involved the use of 3D T1 contrast and the FLAIR sequence, although some patients underwent BTFE sequence use, particularly in cases of CP angle meningioma. The mean radiation dosage was 24.3 ± 23.0 Gy (18-30 Gy), used in 3-5 fractions. Following radiosurgery, all patients underwent six months and one year of clinical and radiological follow-up, including an MRI of the brain with contrast. After five years, patients who still showed no symptoms were scheduled for annual follow-up examination for observation only. The age and gender of the patients were noted in medical charts that were checked and entered into an identified database. Seizures, loss of memory, visual disturbances, migraines, nausea, vomiting, cranial neuropathy, hearing impairment, ataxia, and paresthesia were among the symptoms that were examined.

The data were analysed using the software SPSS version 20.0. Means and standard deviations were used to express age and radiation dosage. Demographic features, including gender, side involvement in meningioma, distribution of tumour location, presenting signs and symptoms, grading, and clinical outcome after radiosurgery, were expressed as frequencies and percentages.

RESULTS

Out of 196 patients, the mean age was 47.25 ± 13.91 years, with female predominance (F>M), i.e., 126 (64.29%) females and 70 (35.71%) males. The right side of the brain was more frequently involved in 110 (56.12%) cases than the left side in 86 (43.88%) cases.

The distribution of tumour location revealed that the most common sites were cerebellopontine angle in 61 (31.1%) cases, parasagittal/parafalcine in 30 (15.3%), temporal in 20 (10.2%), parietal region in 20 (10.2%) cases, sphenoid wing in 32 (16.32%) cases and optic canal 5 (2.55%) each, and the rest of

the 23 (11.73%) included frontal, cavernous, choroid, olfactory groove, petroclival, and suprasellar regions.

As far as the presenting complaint of meningioma is concerned, the most common symptom was headache in 84 (42.85%) patients, vertigo in 38 (19.4%), visual symptoms in 35 (17.85%), body weakness was reported in 18 (9.2%) patients, fits in 14 (7.1%), and 7 (3.57%) patients had other symptoms such as hearing loss, facial palsy, and vomiting, according to the pressure effect and site of the tumour.

It was established that approximately 58 (29.6%) patients had undergone previous surgery and were referred to radiosurgery for residual/recurrent disease while 138 (70.4%) patients had no history of surgery and were selected on imaging. About 32 (16.32%) cases were biopsy-proven Grade I, and 14 (7.14%) cases were Grade II, while the rest were not proven by histopathology. The mean radiation dosage was 24.3 ± 23.0 Gy (range 18-30 Gy), offered in 3-5 fractions. On follow-up imaging, radiological findings on MRI showed that the disease was stable in 126 (65.0%) patients, reduced in 64 (33.0%) patients with no oedema and reduced enhancement and necrosis, and had clinically improved symptoms, while 4 (2.0%) patients showed mild or moderate oedema after radiosurgery, which resolved on subsequent follow-up imaging. Clinically, the disease was stable in 32 (16.0%) patients and reduced in 160 (82.0%) patients. Clinically, four cases, and radiologically, two cases of Grade II meningioma were seen with the progression of the disease as shown in Figure 1.

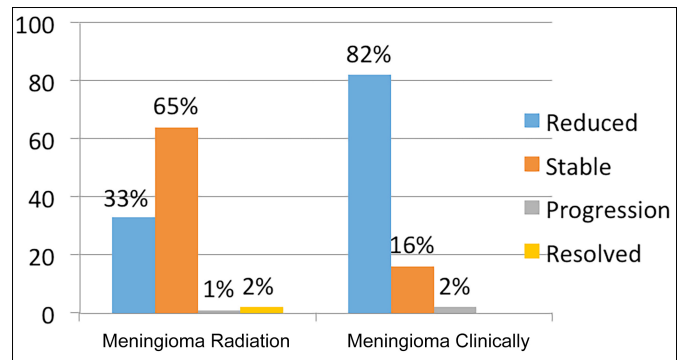


Figure 1: Illustration of outcomes of SRS on intracranial meningioma.

DISCUSSION

Cyberknife stereotactic radiosurgery is the preferred treatment option globally. In Pakistan, it is gaining popularity and is considered in the management of meningioma. It ablates tumours while minimising radiation to healthy tissue and critical structures.^{10,11} The main reason for conducting this study was limited local data on SRS response to meningioma in Pakistan. The results of the current study have shown commendatory outcomes of SRS with no presentation of complications. A thorough review of the literature revealed below-mentioned similar data from Pakistan.

Shah *et al.* in a cohort sub-analysis included 32 centres which indicated that meningiomas represent 15.6% of all intracranial

tumours in Pakistan with more occurrence in the female population (236, 55%) than in males. The mean age at diagnosis was 43.7 ± 19.9 years. Meningiomas had a predominance for the right hemisphere of the brain at 203 (47.32%) tumours and 267 (62.2%) of the tumours in the frontal and parietal lobes. The study found that 174 (61.3%) of all meningiomas diagnosed in Pakistan in 2019 were Grade I tumours, which was also the most commonly occurring tumour grade.^{12,13} The demographics of the present study are partially consistent with this study and revealed that the mean age of the meningioma patients was 47.25 ± 13.91 years, with female predilection 126 (64.29%) over males 70 (35.71%). About 32 (16.32%) cases were biopsy-proven Grade I and 14 (7.14%) cases were Grade II. As far as the location of meningioma was concerned, the most common sites in the study were the cerebellopontine angle in 61 (31.1%) cases, parasagittal /parafalcine 30 (15.3%), however, according to Shah *et al.*, frontal region is most-commonly affected.

Several studies identified the benefits and complications of radiosurgery in patients with meningiomas.

In Pakistan, the treatment response of SRS on different benign as well as malignant tumours has been reported as Saeed *et al.* discussed the outcomes of SRS on pituitary adenoma, nevertheless, SRS response on meningioma has only been reported in international journals.¹⁴

Huang *et al.* found effective and well-tolerated outcomes in intracranial meningioma without significant side effects. The planning was done on 3DT1 contrast and FLAIR sequences. SRS with a mean radiation dose of 12–22 Gy (mean 15 Gy) was given to 26 lesions. Contrast-enhanced MRI was utilised in the follow-up of the patients. The tumour control rate was 92.3% in SRS group, with 2 patients in the SRS group suffering from worsening neurological deficits.^{15,16} In the current study, the mean radiation dosage was 24.3 ± 23.0 Gy (range 18–30 Gy), offered in 3–5 fractions. In planning additional BTFE sequence was utilised, especially in CP angle meningioma to assess cranial nerves and follow-up after SRS was done on MRI brain with gadolinium as in the above study. On follow-up imaging, the disease was stable in 126 (65.0%) patients, reduced in 64 (33.0%) patients with no oedema and reduced enhancement and necrosis, and had clinically improved symptoms. Four (2.0%) patients showed mild or moderate oedema after radiosurgery which resolved on subsequent follow-up imaging.

Pollock *et al.* reported radiation-related complications in 4.8% of patients and Hanna *et al.* reported a complication rate in 8% of their patients.^{17,18} However, in the present study complication rate is as low as 2%.

There are a few limitations of this study. For instance, tumour size was assessed but not included in the variables. Furthermore, the follow-up assessment period was limited to one year in the current study. Despite these limitations, there are many benefits of this study. Firstly, this study has reported a significant number of meningioma cases, undergone SRS treatment and follow-up.^{19–21}

Very few patients reported radiation-induced complications in this study, which proves that cyberknife stereotactic radiosurgery is the preferred treatment, especially for patients with recurrent / residual diseases. Finally, this study provides data from one of the largest tertiary care hospital of Pakistan that offers robotic surgery free-of-cost.

CONCLUSION

This study concluded that radiosurgery is a safe option for treating intracranial meningioma with good radiological response and clinical improvement and a good palliative modality for recurrent disease. MRI brain with contrast is found to be helpful in radiological assessment. Longer follow-up with conventional MRI is mandatory.

ETHICAL APPROVAL:

Ethical approval was obtained from the JPMC prior to conducting the study. (Ethical Approval Number: NO.F.2.81/2023-GEN-L/34/JPMC).

PATIENTS' CONSENT:

Signed consents were taken from all eligible study participants.

COMPETING INTEREST:

The authors declared no conflict of interest.

AUTHORS' CONTRIBUTION:

HS: Contributed to data entry and article text writing.

SS: Contributed to abstract writing and references.

SK: Interpreted data and results.

KS: Provided patients' data whose follow-up was done and helped in calculating the exact dose used in SRS.

TM: Provided the resources for research work.

All authors approved the final version of the manuscript to be published.

REFERENCES

1. Yarabarla V, Mylarapu A, Han TJ, McGovern SL, Raza SM, Beckham TH. Intracranial meningiomas: An update of the 2021 World Health Organization classifications and review of management with a focus on radiation therapy. *Front Oncol* 2023; **13**:1137849. doi: 10.3389/fonc.2023.1137849.
2. Nausheen S, Ahmed N, Arifuzzaman; Muhammad AG, Saeed K, Mahmood T. Experience of CyberKnife Robotic Radiosurgery in treating intra and extra-cranial tumours: A review of outcomes. *J Pak Med Assoc* 2015; **65(4)**:374-9. Available from: <https://pubmed.ncbi.nlm.nih.gov/25976570/>.
3. Perini Z, Casentini LS, Fornezza U. (2021). CyberKnife treatment of atypical meningiomas (GII). In: Longhi M, Motti EDF, Nicolato A, Picozzi P. (Eds) stereotactic radiosurgery for the treatment of central nervous system meningiomas. Springer, Cham; 2021, p. 99-105. doi: 10.1007/978-3-030-79419-4_11.
4. Memon B, Kadri S, Sultana N, Saeed K, Ahmed N, Mahmood T. Cyberknife radiosurgery in hepatocellular carcinoma. *J Coll Physicians Surg Pak* 2021; **31(05)**:532-6. doi: 10.29271/jcsp.2021.05.532.
5. Milano MT, Grimm J, Niemierko A, Soltys SG, Moiseenko V, Redmond KJ, *et al.* Single and multifraction stereotactic

- radiosurgery dose/volume tolerances of the brain. *Int J Radiat Oncol Biol Phys* 2021; **110(1)**:68-86. doi: 10.1016/j.ijrobp.2020.08.013.
6. Hafez RFA, Morgan MS, Fahmy OM, Riyad YO, Zakaria WK, Hassan HT. Gamma knife radiosurgery in the management of benign skull base meningioma; long-term outcome, possible prognostic factors and literature review. *World J Surg Surgical Res* 2021; **4(1)**:1348. doi: 10.25107/2637-4625.1348.
 7. Sumaida AB, Shanbhag NM, Balaraj K. Evaluating the efficacy and safety of cyberknife for meningiomas: A systematic review. *Cureus* 2024; **16(3)**:e56848. doi: 10.7759/cureus.56848.
 8. Liu J, Rojas R, Lam FC, Mirza FA, Mahadevan A, Kasper EM. Indications, feasibility, safety, and efficacy of cyberknife radiotherapy for the treatment of olfactory groove meningiomas: A single institutional retrospective series. *Radiat Oncol* 2020; **15(1)**:63. doi: 10.1186/s13014-020-01506-6.
 9. Shanbhag NM, Antypas C, Msaddi AK, Murphy SC, Singh TT. Meningioma treated with hypofractionated stereotactic radiotherapy using cyberknife®: First in the United Arab Emirates. *Cureus* 2022; **14(2)**:e21821. doi: 10.7759/cureus.21821.
 10. Song Y, Go KO. Clinical experiences using cyberknife for large-volume meningiomas: A preliminary study. *Brain Tumor Res Treat* 2024; **12(4)**:230-6. doi: 10.14791/btrt.2024.0030.
 11. Di Franco R, Borzillo V, Ravo V, Falivene S, Romano FJ, Muto M, et al. Radiosurgery and stereotactic radiotherapy with cyberknife system for meningioma treatment. *Neuroradiol J* 2018; **31(1)**:18-26. doi: 10.1177/1971400917744885.
 12. Shah MM, Khalid MU, Bajwa MH, Bakhshi SK, Anis SB, Akhonzada NZ, et al. Pakistan brain tumour consortium group names. Meningioma - defining characteristics of the affected Pakistani population. *J Pak Med Assoc* 2022; **72 (Suppl 4)(11)**:S51-6. doi: 10.47391/JPMA.11-S4-AKUB08.
 13. Rueß D, Fritsche F, Grau S, Treur H, Hoevens M, Kocher M, et al. Stereotactic radiosurgery of cavernous sinus meningiomas. *J Neurol Surg B Skull Base* 2020; **81(2)**: 158-64. doi: 10.1055/s-0039-1683430.
 14. Saeed K, Siddiqui K, Aziz HF, Shaukat F, Kadri S, Muhammad AG, et al. Outcomes following cyberknife robotic radiosurgery for pituitary adenomas—A large single-center study. *Ecancermedicalscience* 2024; **18**:1803. doi: 10.3332/ecancer.2024.1803.
 15. Huang SH, Wang CC, Wei KC, Chang CN, Chuang CC, Chen HC, et al. Treatment of intracranial meningioma with single-session and fractionated radiosurgery: A propensity score matching study. *Sci Rep* 2020; **10(1)**:18500. doi: 10.1038/s41598-020-75559-8.
 16. Manabe Y, Murai T, Ogino H, Tamura T, Iwabuchi M, Mori Y, et al. Cyberknife stereotactic radiosurgery and hypofractionated stereotactic radiotherapy as first-line treatments for imaging-diagnosed intracranial meningiomas. *Neurol Med Chir (Tokyo)* 2017; **57(12)**:627-33. doi: 10.2176/nmc.oa.2017-0115.
 17. Pollock BE, Stafford SL, Link MJ, Garces YI, Foote RL. Single-fraction radiosurgery for presumed intracranial meningiomas: Efficacy and complications from a 22-year experience. *Int J Radiat Oncol Biol Phys* 2012; **83(5)**: 1414-8. doi: 10.1016/j.ijrobp.2011.10.033.
 18. Hanna C Jr, Willman M, Cole D, Mehkri Y, Liu S, Willman J. Review of meningioma diagnosis and management. *Egypt J Neurosurg* 2023; **38**:16. doi: 10.1186/s41984-023-00195-z.
 19. Goldbrunner R, Minniti G, Preusser M, Jenkinson MD, Sallabanda K, Houdart E, et al. EANO guidelines for the diagnosis and treatment of meningiomas. *Lancet Oncol* 2016; **17(9)**:e383-91. doi: 10.1016/S1470-2045(16)30321-7.
 20. Unger KR, Lominska CE, Chanyasulkit J, Jackson PR, White RL, Aulisi E, et al. Risk factors for posttreatment edema in patients treated with stereotactic radiosurgery for meningiomas. *Neurosurgery* 2012; **70(3)**:639-45. doi: 10.1227/NEU.0b013e3182351ae7.
 21. Buerki RA, Horbinski CM, Kruser T, Horowitz PM, James CD, Lukas RV. An overview of meningiomas. *Future Oncol* 2018; **14(21)**:2161-77. doi: 10.2217/fon-2018-0006.

